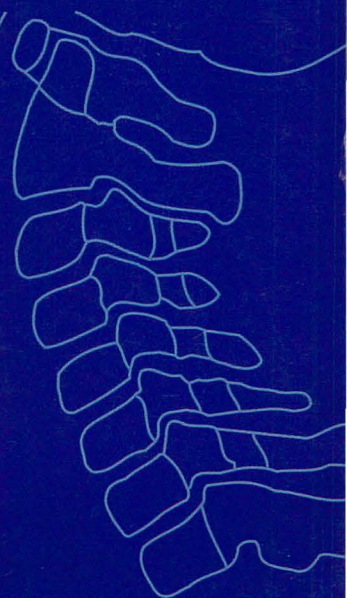
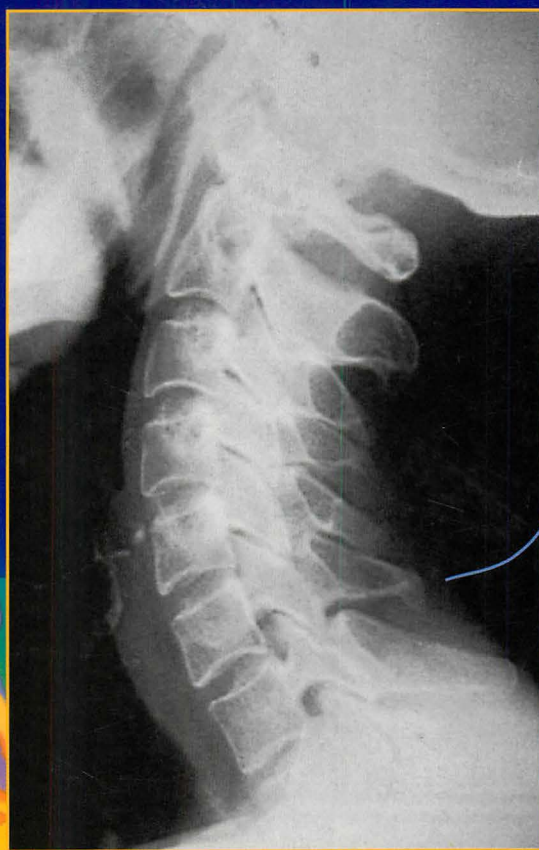


FIFTH EDITION

CLINICAL ORTHOPAEDIC EXAMINATION

Ronald McRae



CHURCHILL
LIVINGSTONE

Summary of joint movements (Main screening tests are in italics)

Cervical spine

flexion	80°	<i>limit, chin touching chest</i>
extension	50°	
total flexion/extension	130°	
lateral flexion to each side	45°	
rotation to each side	80°	

Shoulder

abduction	170°	
flexion	165°	
extension	60°	
internal rotation at 90° abduction	70°	
external rotation at 90° abduction	100°	<i>hand can be placed behind head</i>
internal rotation in extension		<i>hand should be able to touch opposite shoulder blade</i>

Elbow

flexion	145°	<i>fingertips should be able to touch shoulder</i>
pronation	75°	
supination	80°	

Wrist

dorsiflexion	75°	<i>normal 'prayer' position of hands</i>
palmar flexion	75°	<i>ability to place backs of hands together</i>
radial deviation	20°	
ulnar deviation	35°	
pronation	75°	
supination	80°	

Thumb

IP joint flexion	80°	
IP joint extension	20°	
MP joint flexion	55°	
MP joint extension, passive	5°	
carpo-metacarpal abduction	20°	
carpo-metacarpal flexion	15°	
carpo-metacarpal abduction in a plane at right angles to the palm opposition	60°	<i>the thumb should be able to touch the tip of the little finger</i>

Continued on inside back cover

CLINICAL ORTHOPAEDIC EXAMINATION

CLINICAL
CHILD PSYCHOLOGY
EXAMINATIONS

Commissioning Editor: Michael Parkinson
Project Development Manager: Barbara Simmons
Project Manager: Frances Affleck
Designer: Erik Bigland

CLINICAL ORTHOPAEDIC EXAMINATION

Ronald McRae

FRCS (Eng, Glas) FChS (Hon) AIMBI, Fellow of the British Orthopaedic Association

With original drawings by the author

FIFTH EDITION



EDINBURGH LONDON NEW YORK OXFORD PHILADELPHIA ST LOUIS SYDNEY TORONTO 2004

CHURCHILL LIVINGSTONE
An imprint of Elsevier Limited

© Longman Group Limited 1976, 1983
© Longman Group UK Limited 1990, assigned to Pearson Professional 1995
© Pearson Professional Limited 1997
© 2004, Elsevier Limited. All rights reserved.

The right of Ronald McRae to be identified as editor of this work has been asserted by him in accordance with the Copyright, Designs and Patents Act 1988

No part of this publication may be reproduced, stored in a retrieval system, or transmitted in any form or by any means, electronic, mechanical, photocopying, recording or otherwise, without either the prior permission of the publishers or a licence permitting restricted copying in the United Kingdom issued by the Copyright Licensing Agency, 90 Tottenham Court Road, London W1T 4LP. Permissions may be sought directly from Elsevier's Health Sciences Rights Department in Philadelphia, USA: phone: (+1) 215 238 7869, fax: (+1) 215 238 2239, e-mail: healthpermissions@elsevier.com. You may also complete your request on-line via the Elsevier homepage (<http://www.elsevier.com>), by selecting 'Customer Support' and then 'Obtaining Permissions'.

First edition 1976
Second edition 1983
Third edition 1990
Fourth edition 1997
Fifth edition 2004

ISBN 0 443 07407 0
Reprinted 2005 (twice)

International Student Edition ISBN 0 443 07408 9
Reprinted 2004, 2005

British Library Cataloguing in Publication Data

A catalogue record for this book is available from the British Library

Library of Congress Cataloging in Publication Data

A catalog record for this book is available from the Library of Congress

Note

Medical knowledge is constantly changing. Standard safety precautions must be followed, but as new research and clinical experience broaden our knowledge, changes in treatment and drug therapy may become necessary or appropriate. Readers are advised to check the most current product information provided by the manufacturer of each drug to be administered to verify the recommended dose, the method and duration of administration, and contraindications. It is the responsibility of the practitioner, relying on experience and knowledge of the patient, to determine dosages and the best treatment for each individual patient. Neither the Publisher nor the author assumes any liability for any injury and/or damage to persons or property arising from this publication.

The Publisher

Working together to grow
libraries in developing countries

www.elsevier.com | www.bookaid.org | www.sabre.org

ELSEVIER

BOOK AID
International

Sabre Foundation

ELSEVIER

your source for books,
journals and multimedia
in the health sciences

www.elsevierhealth.com

Printed in China
C/03/03

The
publisher's
policy is to use
paper manufactured
from sustainable forests

PREFACE

The ability to make a good clinical examination can only be mastered by practice, and I have no doubt that the basic techniques are best learned by performance under supervision. Unfortunately, the size of student classes in relation to teaching staff, and the not infrequent dearth of an adequate range of suitable clinical cases, makes this ideal difficult to achieve in practice. Many students may acquire only a sketchy knowledge of the techniques of examination, which are fundamental to diagnosis and treatment. It is hoped that this book may help to fill some of these inevitable gaps until sound practice based on experience is achieved.

The text

It is assumed that the value of good history-taking is appreciated and practised.

Patients parade their complaints on an anatomical basis, and the text has been arranged accordingly. The emphasis in each section is on the common rather than the rare conditions to be found in the region. Although this approach is open to criticism, it is nevertheless true to say that although the obscure will tax the most experienced, the most frequent mistake is a failure to diagnose the common. An encyclopaedic text, commendable on the ground of completeness, may nevertheless often confuse, especially where no indication is given of the incidence of the conditions observed. I have purposely avoided detail, and where this is required a fuller orthopaedic textbook must be consulted. In some areas too I have made deliberate simplifications where a blight of terminology suggests the independence of a number of conditions that cannot be distinguished by symptomatology or investigation.

The illustrations

The illustrations dealing with the practical aspects of clinical examination have been arranged in an essentially linear sequence following the traditional lines of inspection, palpation, and the examination of movements and pertinent anatomical structures. In practice, this logical order is often altered by the experienced examiner to avoid undue movement of the patient. It must be stressed that not all the tests described need be carried out routinely. Many are performed only when a specific condition is suspected,

and it is assumed that this will be obvious to the reader. In particular, in any joint assessment, it is necessary to discover if there is any restriction of movement. In many cases simple screening tests will suffice, and these are highlighted in most sections. The more detailed examination and recording of movement are generally reserved for cases under lengthy continuous observation and for medico-legal work.

Radiographic examination plays an essential part in the investigation of most orthopaedic cases, and to aid the inexperienced I have made some observations regarding the views normally taken and how they may be interpreted. Only a fraction of the possible pathology can be illustrated in a small work, but I have concentrated on the common or informative.

The spatial requirements of the captions have set some restriction on their content; this discipline has resulted in brevity at the expense in places of completeness. Nevertheless, wherever possible I have tried to show not only how each test should be carried out, but also its significance.

I have taken the opportunity that this new fifth edition has afforded of reworking all of the previous drawings. These I have digitized, tidied up where necessary, and used a variety of grey fills to improve their clarity. In addition, the text has been updated and reorganized in many places, and a number of new tests have been included.

Conventions and references

For clarity in illustrating the techniques of examination, the patient and the examiner are shown in shades of light and dark grey respectively.

Where two limbs are illustrated, the pathology is shown on the patient's right side.

Where several conditions are described, and one representative illustration only is given, it refers to the first condition mentioned.

When joint movements are being considered, the patient's normal side should if possible be used for comparison. Angular measurement is an approximation, and the figures quoted are in most cases values rounded to the nearest 5° from figures published by the American Academy of Orthopedic Surgeons¹, Kapandji², Lusted and Keats³ or Boone and Azen⁴.

References

1. American Academy of Orthopedic Surgeons 1965 Joint motion: method of measuring and recording. Churchill Livingstone, Edinburgh
2. Kapandji A 1974 The physiology of the joints. Churchill Livingstone, Edinburgh
3. Lusted L B, Keats T E 1972 Atlas of roentgenographic measurement. Year Book Medical Publishers, London
4. Boone C D, Azen P S 1979 Normal range of motion of joints in male subjects. Journal of Bone and Joint Surgery 61A/5: 756-9

R. McR

Gourock, 2003

Abbreviations

L & R = left and right

L & M = lateral and medial

A & P = anterior and posterior

CONTENTS

- 1.** General principles in the examination of a patient with an orthopaedic problem 1
- 2.** Segmental and peripheral nerves of the limbs 11
- 3.** The cervical spine 33
- 4.** The shoulder 49
- 5.** The elbow 73
- 6.** The wrist 89
- 7.** The hand 109
- 8.** The thoracic and lumbar spine 129
- 9.** The hip 165
- 10.** The knee 201
- 11.** The tibia 245
- 12.** The ankle 255
- 13.** The foot 271
- Index 307

CHAPTER

1

General principles in the examination of a patient with an orthopaedic problem

Step 1: Inspection	2
Step 2: Palpation	3
Step 3: Movements	4
Step 4: Conduction of special tests	6
Step 5: Examination of radiographs	6
Step 6: Arranging further investigations	7
Additional imaging techniques	7
Functional imaging techniques	8
Arthroscopy	8
Equipment requirements	8

In practice, the primary area of interest of the orthopaedic surgeon is in the joints of the limbs and spine, and how well they function. The major part of most orthopaedic examinations is therefore centred on the joint that troubles the patient, but the examination must often be extended to include the nerves and muscles that are responsible for movements in the joint; some of the patient's other joints may also have to be checked to see if they are affected as well.

Joints possess a remarkable degree of individuality, and it follows that the techniques for examining one joint may have to be varied when it comes to look at another. However, a common sequence is followed, and it may be helpful to keep it in mind. (It is assumed that a full, relevant history has been obtained, and any general physical examination has been carried out.) The examination of the joint itself may be broken down into six distinct steps:

1. Inspection
2. Palpation
3. Examination of movements
4. Conduction of special tests
5. Examination of radiographs
6. Arranging further investigations.

It is not always necessary to keep strictly to this order, or indeed to carry out all of these procedures.

The contents of each chapter of this book are generally ordered in this sequence unless special circumstances dictate otherwise.

STEP 1: INSPECTION

Look carefully at the joint, paying particular attention to the following points:

1. Is there swelling? If so, is the swelling diffuse or localized? If the swelling is diffuse, does it seem confined to the joint or does it extend beyond it? Swelling confined to the joint suggests distension of the joint with (a) excess synovial fluid (effusion), e.g. from trauma or a non-pyogenic inflammatory process (such as rheumatoid or osteoarthritis); (b) blood (haemarthrosis), e.g. from recent acute injury or a blood coagulation defect; or (c) pus (pyarthrosis), e.g. from an acute pyogenic infection. Swelling extending beyond the confines of the joint may occur with major infections in a limb, tumours, and problems of lymphatic and venous drainage.

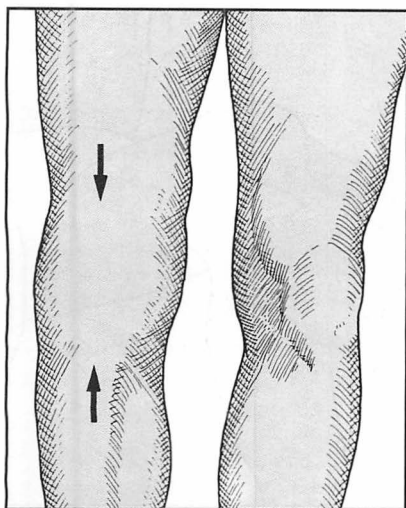
If there is a localized swelling, note its position in relation to the underlying anatomical structures, as this may give a clue to its possible nature or identity.

2. Is there bruising? This might suggest trauma, with a point of impact or gravitational or other spread.

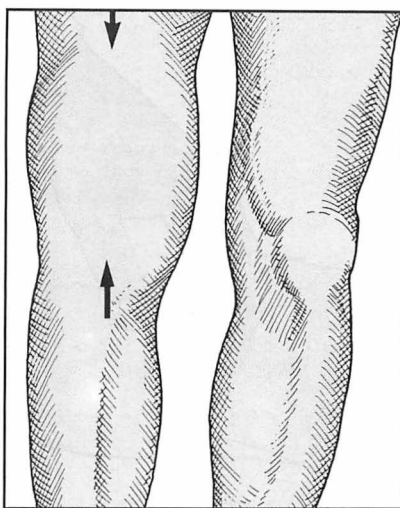
3. Is there any other discoloration, or oedema? This might occur as a localized response to trauma or infection.

4. Is there muscle wasting? This usually occurs as a result of disuse, from pain or other incapacity, or from denervation of the muscles affected.

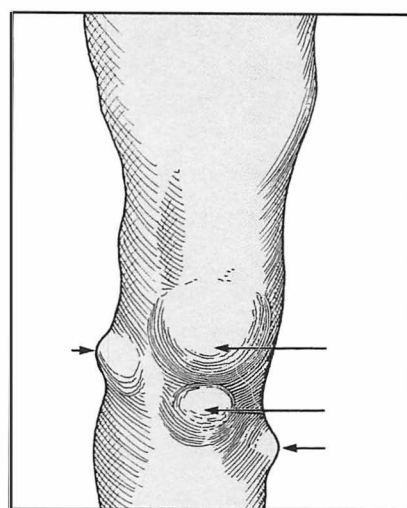
5. Is there any alteration in shape or posture, or is there evidence of shortening? There are many possible causes for each of these abnormalities (including congenital abnormalities, past trauma, disturbances of bone mineralization and destructive joint disease); their presence should be noted, and explored in further detail during the course of the examination.



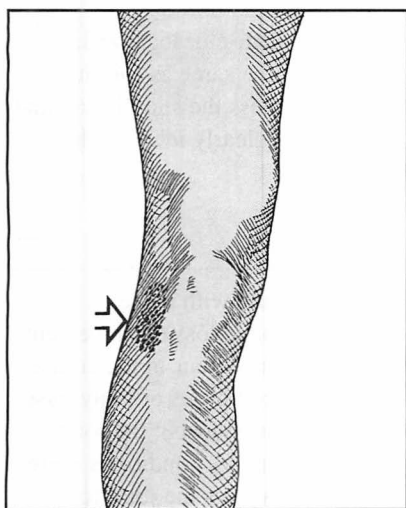
1.1. Note any swelling confined to the joint.



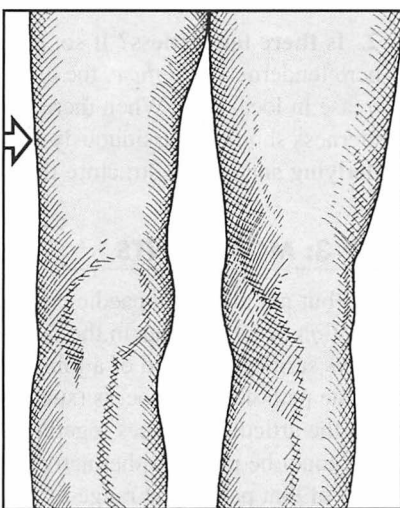
1.2. Note any swelling extending beyond the joint.



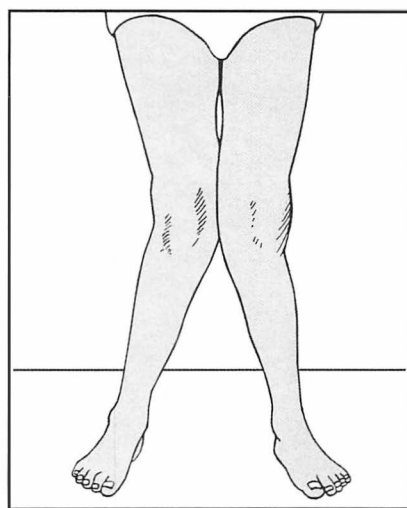
1.3. Note any localized swelling(s).



1.4. Note any bruising or oedema.



1.5. Note any muscle wasting.

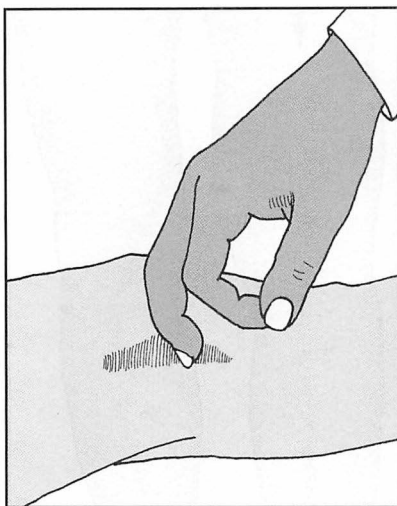


1.6. Note any alteration of shape or posture.

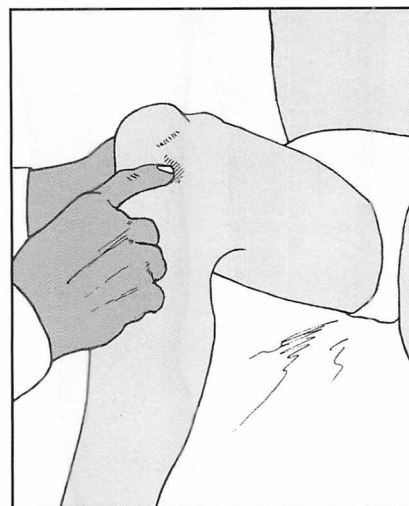
STEP 2: PALPATION

Some of the points you should note include the following:

1. **Is the joint warm?** If so, note whether the temperature increase is diffuse or localized, always bearing in mind the false impression that may be caused by the effects of local bandaging. A *diffuse* increase in heat occurs when a substantial tissue mass is involved, and is seen most commonly in joints involved in pyogenic and non-pyogenic inflammatory processes, and in cases where there is anastomotic dilatation proximal to an arterial block. Away from the joints themselves, infection and tumour should be borne in mind. A *localized* increase in temperature generally pinpoints an inflammatory process in the underlying anatomical structure. Asymmetrical *coldness* of a limb commonly occurs where the limb circulation is impaired, e.g. from atherosclerosis.



1.7. Note any increased local heat.

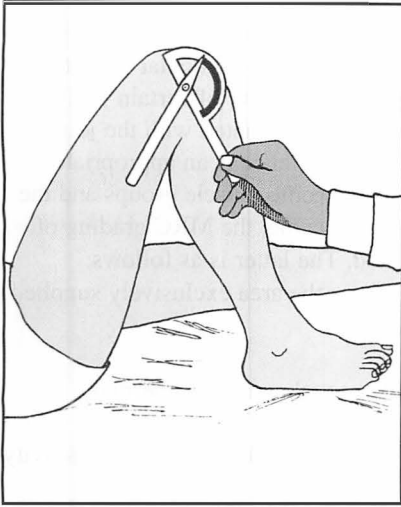

1.8. Note any tenderness, and whether localized or diffuse.

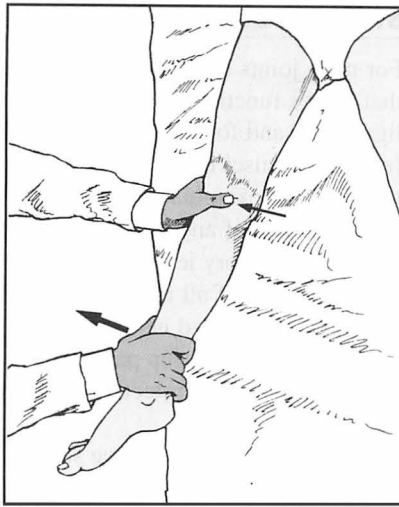
2. Is there tenderness? If so, note whether it is diffuse or localized. Where tenderness is *diffuse*, the cause is likely to be the same as for an increase in local heat. When there is *localized* tenderness the site of maximal tenderness should be assiduously sought, as this may clearly identify the underlying anatomical structure that is involved.

STEP 3: MOVEMENTS

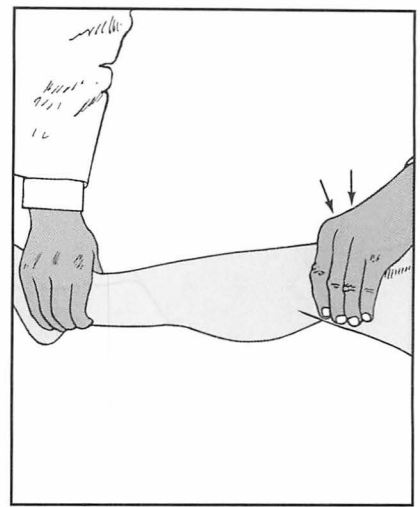
Most (but not all), orthopaedic conditions are associated with some restriction of movements in the related joint(s). Complete loss of movements follows surgical ablation of a joint (arthrodesis), or may occur in the course of some pathological process (such as infection) where fibrous or bony tissue binds the articular surfaces together (fibrous or bony ankylosis): the joint then cannot be moved either actively or passively. In many conditions there is loss of that part of the range of movements which allows the joint to be brought into its neutral position. The commonest loss of this type prevents the joint from being fully extended; this is known as a fixed flexion deformity. *Fixed deformities* may be caused for example by the contraction of joint capsules, muscles and tendons, or by the interposition of soft tissues or bone between the articular surfaces (e.g. torn menisci, loose bodies). Estimation of the *range of movements in the joint* is an essential part of any orthopaedic examination. To assess any deviation from normal the good side may be compared with the bad; where this is not suitable (e.g. when both sides are involved) resort must be made to published figures of *calculated* average ranges. *Restriction of the range of movements in a joint* is nearly always due to mechanical causes and is consequently a sure indicator of pathology. If the muscles controlling a joint are paralysed, then the *passive range of movements* must be assessed; occasionally pain or other factors may restrict the *active range of movements* to a range that is less than the passive. Sometimes a partly or totally paralysed joint can be persuaded to move by invoking gravity or movement elsewhere (*trick movements*), and the confirmation of paralysis generally begs the determination of its cause.



1.9. Measure the range of movements and record any fixed deformities.



1.10. Test for movement in abnormal planes.



1.11. Note any joint crepitus.

In many joints it is also mandatory to look for evidence of *movements in an abnormal plane*. To do this the joint is generally stressed in a particular plane and excessive movements are assessed by inspection or by the examination of radiographs. Other accompaniments of movement may require assessment. Rough articular surfaces will produce grating sensations (*crepitus*) when the joint is moved, and this may be detected by palpation or auscultation. *Clicks coming from the joint on movement* may be produced through soft tissues moving over bony prominences (generally of little importance), from soft tissues within the joint (e.g. displaced menisci), or from disturbances in bony contours (e.g. from irregularities in a joint surface following a fracture involving the joint).

The *strength of muscle contraction* (and hence the strength of each joint movement) must be carefully assessed, and especially if found reduced, recorded on the Medical Research Council (MRC) scale:

M0 No active contraction can be detected.

M1 A flicker of contraction can be seen or found by palpation over the muscle, but the activity is insufficient to cause any joint movement.

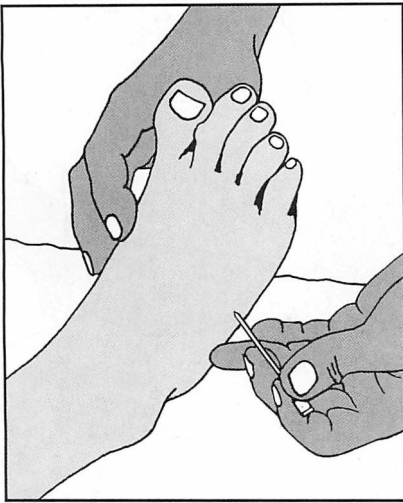M2 Contraction is very weak, but can just produce movement so long as the weight of the part can be countered by careful positioning of the limb.

M3 Contraction is still very weak, but can produce movement against gravitational resistance (e.g. the quadriceps being able to extend the knee with the patient in a sitting position).

M4 Strength is not full, but can produce movement against gravity and added resistance).

M5 Normal power is present.

Muscle strength may be impaired by pain, wasting from disuse, disease or denervation. Finally, attention should be paid to any impairment of overall function in the affected limb as a result of disturbance of movement or muscle power: in the case of the legs, this implies an assessment of the *gait*. Many tests are available to detect disturbance of separate aspects of upper limb function.



1.12. Test for sensory loss and any other neurological defect.

STEP 4: CONDUCTION OF SPECIAL TESTS

For most joints there are a number of specific tests for particular aspects of that joint's function. These include tests for the integrity of certain joint ligaments, and for the examination of structures associated with the joint (e.g. the menisci in the knee). Of particular importance is an appropriate neurological examination (e.g. the testing of specific muscle groups and the determination of any sensory loss). When applicable, the MRC grading of motor and sensory levels should be recorded. The latter is as follows:

- S0** Absence of all modalities of sensation in the area exclusively supplied by the affected nerve.
- S1** Recovery of deep pain sensation.
- S2** Recovery of protective sensation (skin touch, pain and thermal sensation).
- S3** Recovery of protective sensation with accurate localization. Sensitivity (and hypersensitivity) to cold is usual.
- S3+** Recovery of ability to recognize objects and texture; any residual cold sensitivity and hypersensitivity should now be minimal. In the case of the hand, recovery of two-point discrimination to less than 8 mm.
- S4** Normal sensation.

STEP 5: EXAMINATION OF RADIOGRAPHS

When a radiograph is requested, in most cases the standard views comprising an anteroposterior (AP) and a lateral projection will be provided.

Someone experienced in looking at radiographs will recognize the main pathology at a glance without following any analytical procedure, just as a familiar face is identified without apparently paying conscious attention to the relevant position and size of its main features. Until such skills are developed, it may be helpful for the student to have some simple scheme to follow. One such is to look at each radiograph as though in the cinematic sequence of long shot, medium shot and close-up. In the long (wide-angle) shot a scene is established and the overall relationship of the important features is made clear. Start by looking at the radiograph in a general, unfocused way, as though you were standing well back from it; ask yourself the following questions:

1. Are the bones of normal shape, size and contour, or are they thicker or thinner than normal, shorter or longer than usual, or abnormally curved or angled?
2. At the joints themselves, are the bony components in correct alignment, or are they displaced or angled?

Looking a little more closely, note whether the bone texture appears normal or disturbed, such as in osteoporosis, Paget's disease, avascular necrosis, osteoporosis etc. Note if there are any areas of new bone, such as exostoses, subperiosteal new bone formation etc. Note whether there are any areas of bone destruction, such as may be found in the presence of many tumours.

Examination of the bone in close-up may be done in two ways: either trace methodically round the contours of the bone, noting any abnormality en route, or go through a checklist of your own making; checklists can have different bases, and can be used in combination. A list may be based on *pathology*: you might then look for evidence of congenital abnormality, infection (or an inflammatory process), trauma, neoplasm, metabolic

disturbance, degeneration; a list may have an *anatomical base*: you might then assess ligamentous attachments, joint margins, the joint space, and the cortical and cancellous bone elements.

In some situations radiographs additional to the standard AP and lateral projections may be required. These may include:

- **Comparison films** Here films of the other limb may be taken so that the two sides may be compared; this may be indicated where there is some difficulty in interpreting the radiographs (for example in the elbow region in children, where the epiphyseal structures are continually changing, or where there is some unexplained shadow or a congenital abnormality).
- **Oblique projections** In the case of the hand and foot an oblique projection may be helpful, especially when the normal lateral view gives rise to confusion owing to the superimposition of many bone structures. Such oblique projections may have to be specifically requested when they are not part of an X-ray department's routine.
- **Localized views** Where there is marked local tenderness, but routine films are normal, coned-down localized views may give sufficient gain in detail to reveal, for example, a hairline fracture.
- **Stress films** Stress films can be of value in certain situations, especially when a substantial tear of a major ligament is suspected. For example, where the lateral ligament of the ankle is thought to be torn, radiographs of the joint taken with the foot in forced inversion may demonstrate instability of the talus in the ankle mortice.

STEP 6: ARRANGING FURTHER INVESTIGATIONS

This last stage is not always required, but the indications are usually quite clear. The clinical and radiological examinations may have resulted in a differential diagnosis that requires additional tests to allow a firm diagnosis to be made; in many cases the additional tests serve to confirm a strong impression. Occasionally clinical examination fails to clarify the problem and one remains baffled by the cause of the complaint: further investigation may throw some light on the situation, perhaps indicating an area that should be concentrated upon, or suggesting that temporization and observation may be embarked upon with safety; or occasionally it may suggest that some at least of the complaint may have a functional basis.

The commonest screening tests include the following:

1. Erythrocyte sedimentation rate (ESR) (and, in certain cases, C-reactive protein)
2. Full blood count with differential
3. Estimation of rheumatoid factor
4. Serum calcium, phosphate and alkaline phosphatase
5. Serum uric acid
6. Chest X-ray.

Other regional investigations include the following:

ADDITIONAL IMAGING TECHNIQUES

1. **CT scans** These can show tissue slices in any plane, but characteristically in the median sagittal, parasagittal, coronal and, most importantly, the transverse planes. The last projection cannot be readily obtained with plain X-rays, and can often provide useful additional

information which is not otherwise available. In addition, in the CT scan there is a greater range of grey-scale separation, allowing a greater differentiation of tissue types.

2. AP and lateral tomography In this X-ray technique the tube and film are rotated (or slid) in opposite directions during the exposure. Their positions relative to one another and the part being examined determine the tissue slice being clearly visualized. The results are inferior to those obtained by CT scanning, but may be helpful if the latter is not available.

3. MRI scans These avoid any exposure to X-irradiation and produce image cuts as in CT scans, with a greater ability to distinguish between different soft tissues. They are of particular value in assessing neurological structures within the skull and spinal canal, and meniscal and ligamentous structures about the knee and shoulder.

4. Ultrasound Ultrasound imaging, which is generally regarded as being hazard free, readily available and inexpensive, has great sensitivity and is of value in assessing the presence of fluid (e.g. blood) within and around joints, as well as discontinuities in soft tissue structures. It is frequently used in evaluating cases of developmental dysplasia of the hip.

FUNCTIONAL IMAGING TECHNIQUES

1. Technetium bone scans Bone scans may be performed after the injection of technetium-tagged methylene diphosphonate (^{99m}Tc -methylene diphosphonate (MDP)). The facility is widely available, inexpensive, and gives rapid results. In the trauma field such scans may assist in the diagnosis of hairline fractures (e.g. of the scaphoid, shin, or neck of femur). They may assist in gauging the age of a fracture, and in detecting avascular necrosis of bone. They are of value in the investigation of unexplained pain in the long bones and spine, infections in bone and in the region of prostheses, and in assessing Sudeck's atrophy (complex regional pain syndrome).

2. SPECT (single-photon emission controlled tomography) This technique may be used to give better localization and assessment of an active area discovered by a technetium bone scan. It is of particular value in the investigation of back pain.

3. PET (fluorodeoxyglucose (FDG)-positron emission tomography) may be of value in localizing infection within a bone. Other methods in the investigation of suspected infections include the use of gallium, or direct labelling of the patient's own leukocytes with indium or technetium. Leukocyte labelling is of particular value in the evaluation of infection round implants, but requires special facilities.

ARTHROSCOPY

Methods for the examination of all the major joints have been developed and allow direct visualization of the articular surfaces, the joint capsule, many associated ligaments and, in the case of the knee, the menisci. At the same session biopsy samples may be taken if required, and sometimes treatment procedures may be carried out.

EQUIPMENT REQUIREMENTS

The special tools required for the clinical examination of a patient with an orthopaedic complaint are modest in character. Four are desirable:

- 1. A tape measure** (preferably of the type used by tailors) for measuring such things as limb lengths and girths (for evidence of inequality in

length, or evidence of muscle wasting), and sometimes for assessing movement (e.g. in the spine, knee and rib cage).

2. A **goniometer**, preferably with an easily read scale with reciprocals, for measuring the range of movements in a joint.
3. A **tendon hammer** for eliciting limb reflexes.
4. A **disposable sharp point** (by default a hypodermic needle), fresh for each case, for assessing any disturbance of sensation to pinprick.

CHAPTER

2

Segmental and peripheral nerves of the limbs

Brachial plexus

- Cervical part 12
- Branches from roots 13
- Branches from trunks 14
- Axillary part 14
- Branches from cords 14

Upper limb myotomes 15

Upper limb dermatomes 16

Types of brachial plexus injury 16

Assessment of brachial plexus lesions 17–18

Axillary nerve 19

Radial nerve 19–21

Ulnar nerve 21–24

Median nerve 24–27

Lower limb myotomes 27

Lower limb dermatomes 27

Lumbosacral plexus 28

Femoral nerve 29

Common peroneal nerve 29

Tibial nerve 30–31

Sciatic nerve 31

Lateral cutaneous nerve of thigh 32

Neurological control of the bladder 32

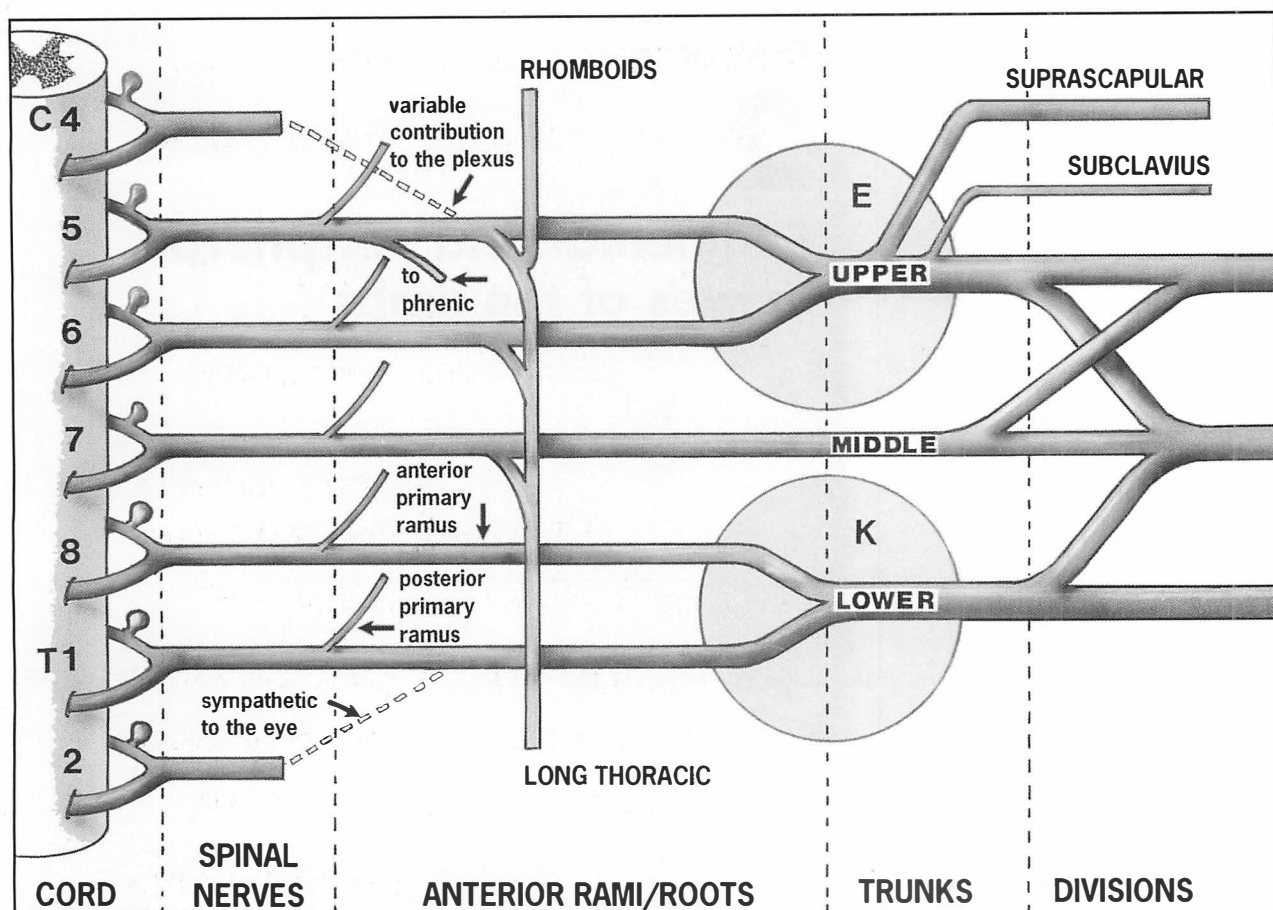
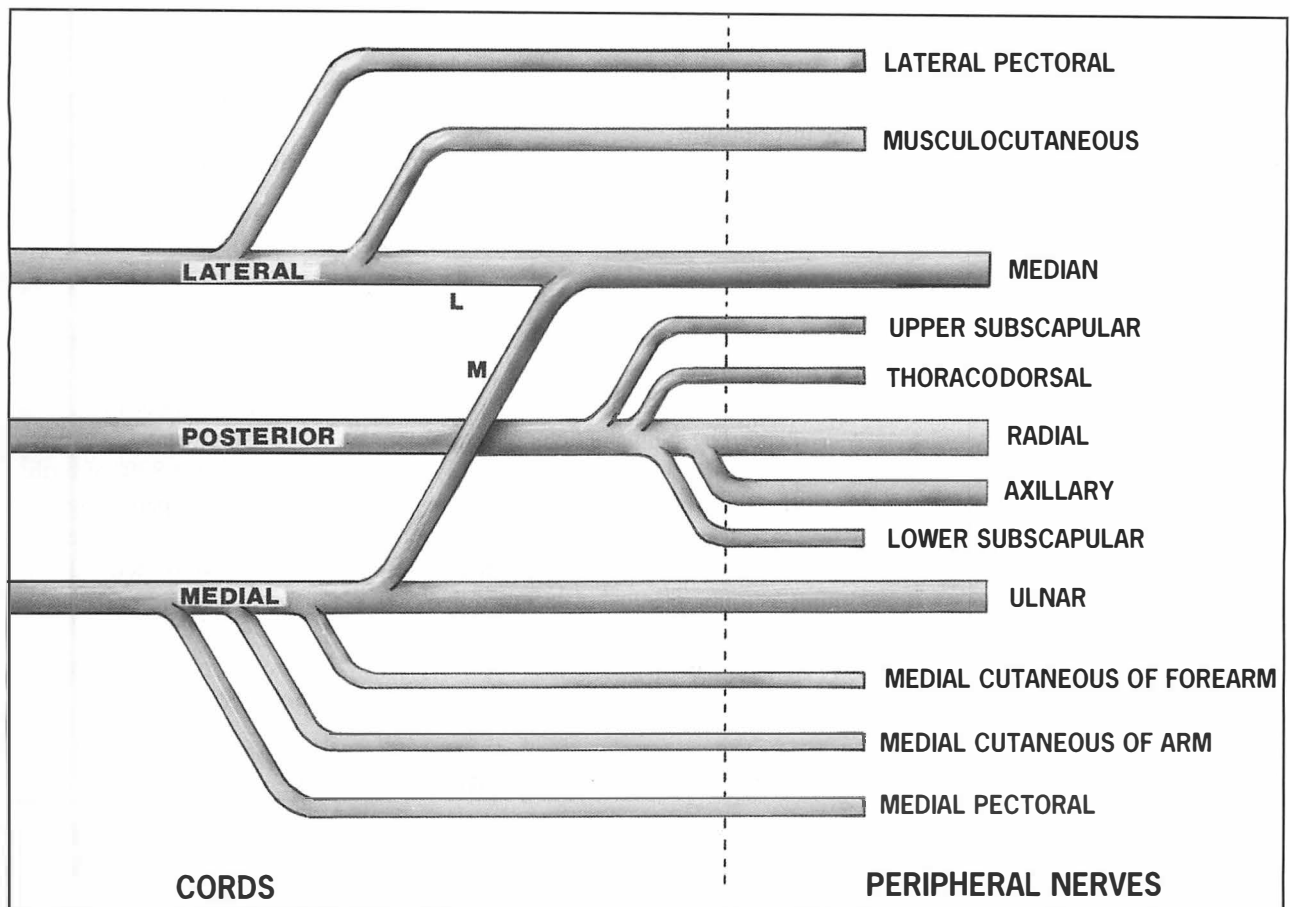


Fig 2.1

THE BRACHIAL PLEXUS: CERVICAL PART

The *roots* of the brachial plexus are formed by the anterior primary rami of C5–T1 inclusive, with occasional contributions from C4 and T2. The roots lie between the scalene muscles in the neck. (Do not confuse the roots of the *plexus* with the roots of the *segmental spinal nerves*, which are intrathecal). C5 and C6 form the *upper trunk*, C7 forms the *middle trunk*, and C8 and T1 form the *lower trunk*. (Preganglionic sympathetic nerve fibres to the upper limb arise from T2–T6, ascend in the sympathetic trunk, synapse in cervicothoracic ganglia, and pass to the upper limb mainly through the lower trunk of the plexus. An important localizing point to note is that preganglionic fibres en route to the eye via the stellate ganglion arise from T1.) The trunks are found in the posterior triangle of the neck. The subclavian artery lies in front of the lower trunk.

Each trunk forms an anterior and a posterior division. The *divisions* lie behind the clavicle. The three posterior divisions form the *posterior cord*, the anterior divisions of the upper and middle trunks form the *lateral cord*, and the anterior division of the lower trunk continues as the *medial cord*. The divisions and commencement of the cords lie in the posterior triangle of the neck.



The brachial plexus has a most extensive distribution, and the order in which the nerves come off is of value in determining the site of any lesion. This is of particular importance in traumatic lesions, where the prognosis and treatment are closely related to the level of injury.

BRANCHES FROM NERVE ROOTS

The *first branches* of the plexus to be given off arise from the nerve roots themselves. Two important branches in this category are:

1. The nerve to the rhomboids (dorsal scapular nerve). It arises from the C5 root alone.
2. The nerve to serratus anterior (long thoracic nerve). It has contributions from C5, 6 and 7. Its most proximal part arises in conjunction with the nerve to rhomboids.

C5 also contributes to the phrenic nerve, and C5, 6, 7 and 8 supply the scalenes and longus colli. Although not strictly branches of the brachial plexus, these segmental branches are of some importance; paralysis of the hemidiaphragm, when found after a brachial plexus injury, indicates a proximal lesion.

BRANCHES FROM THE TRUNKS

There are two branches only at this level:

1. The suprascapular nerve is important, supplying the supraspinatus and infraspinatus.
2. The nerve to subclavius: this is of little clinical significance.

Both these nerves arise from the upper trunk. All the branches from the nerve roots and trunks arise above the clavicle (the supraclavicular branches).

Note

1. In Erb's (upper obstetrical) palsy (E) the C5–6 roots are affected but the nerve to rhomboids and the long thoracic nerve are spared.
2. In Klumpke's (lower obstetrical) palsy (K) the C8–T1 roots are involved. The sympathetic nerve supply to the eye (arising from T1) is often also affected, leading to a Horner's syndrome. It was said that 80% of birth injuries to the plexus make a full recovery by 13 months, and persisting severe sensory or motor deficits in the hand are rare; recent work suggests that this view is somewhat optimistic. Note that a number of obstetrical injuries to the plexus are accompanied by facial nerve palsy and posterior dislocation of the shoulder.
3. In traumatic plexus lesions in adults the commonest patterns of injury are (a) C5–6 (Erb type); (b) C5, 6, 7; (c) C5–T1 inclusive.

THE BRACHIAL PLEXUS: AXILLARY PART

The cords for the most part lie in the axilla, and are closely related to the axillary artery. (The axillary artery commences at the outer border of the first rib and ends at the lower border of teres major. The second part of the axillary artery lies behind the pectoralis minor, with the first and third parts of the artery lying above and below it. The three cords enter the axilla above the first part, embrace the second part in the position indicated by their names, and give off their branches around the third part.)

BRANCHES FROM THE CORDS

The lateral cord (C5, 6, 7) This gives off the following branches:

1. The lateral pectoral (which supplies pectoralis major)
2. The musculocutaneous (which supplies coracobrachialis and biceps)
3. The lateral root of the median nerve.

The medial cord (C8, T1) This gives off:

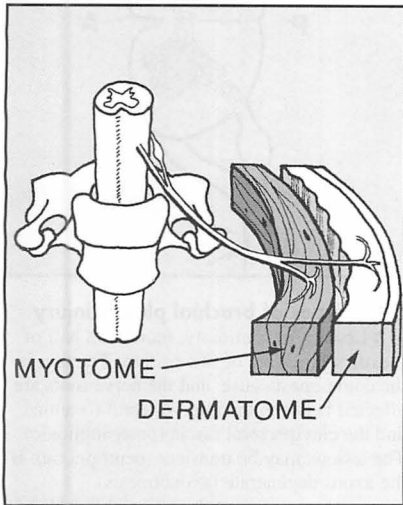
1. The medial pectoral nerve (which supplies pectoralis major)
2. The medial cutaneous nerve of the arm (which supplies the skin over the front and the medial side of the arm)
3. The medial cutaneous nerve of the forearm (which supplies the skin over the lower part of the arm and the medial side of the forearm)
4. The medial root of the median nerve
5. The ulnar nerve (in 90% of cases the ulnar nerve receives a branch (C6, 7) from the lateral cord).

The posterior cord (C5, 6, 7, 8, T1) This gives off:

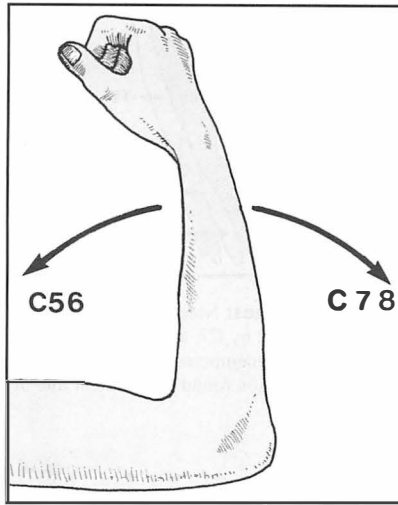
1. The upper subscapular nerve (C5, 6), which partly supplies subscapularis
2. The lower subscapular nerve (C5, 6), which supplies subscapularis and teres major

3. The thoracodorsal nerve (C6, 7, 8), which supplies latissimus dorsi
4. The radial nerve (C5, 6, 7, 8, T1)
5. The axillary nerve (C5, 6).

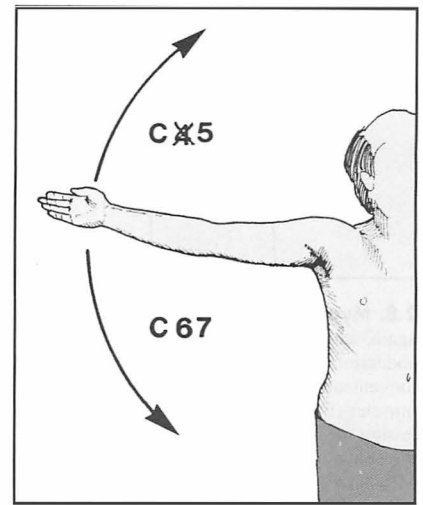
Details of the most important branches (median, ulnar, radial, axillary) are given later.



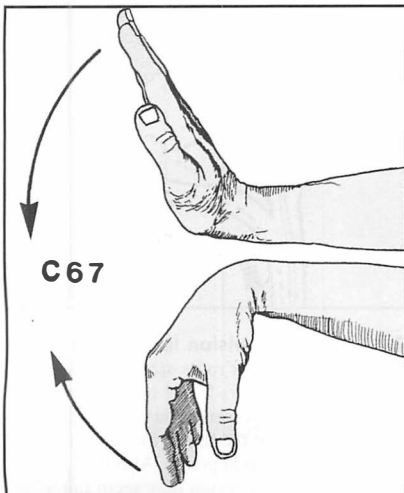
2.2. Segmental distribution: Where you suspect involvement of spinal nerves rather than peripheral nerves (e.g. injuries to the spine or brachial plexus, cervical spondylosis etc.) you must examine myotomes and dermatomes. These are the muscle masses and areas of skin supplied by single spinal nerves (no matter how the nerve fibres within these spinal nerves are finally distributed via the limb plexuses and peripheral nerves).



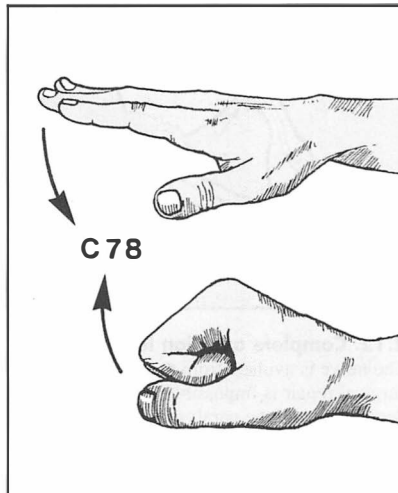
2.3. Myotomes (1): Normally two roots produce movement of a joint in one direction, and two in another. This is true at the elbow, where weakness of elbow flexion and an absent biceps tendon jerk indicate C5,6 involvement; and where weakness of extension and an absent triceps jerk suggest a C7,8 lesion. This general rule is followed throughout the lower limb, but is modified in the highly specialized upper limb.



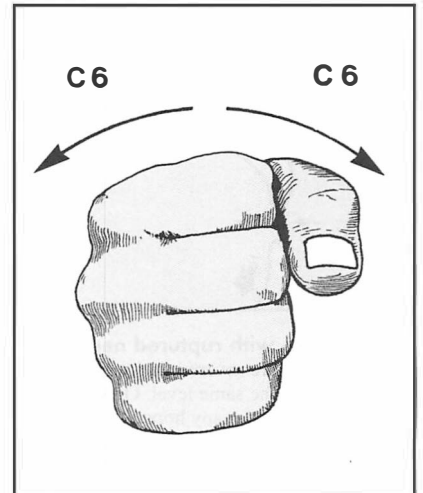
2.4. Myotomes (2): In a distal or proximal joint the four spinal segments involved differ by plus or minus one, so that theoretically the shoulder should be controlled by C4,5,6,7. However, C4 has been suppressed, with the result that abduction is mediated through C5 alone (deltoid, supraspinatus etc). Adduction (involving principally pectoralis major) is controlled by C6,7).



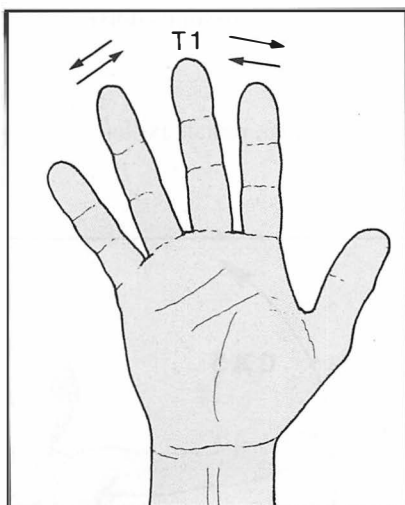
2.5. Myotomes (3): At the wrist, where C6,7 would have been expected to control palmar flexion only, it is the case that these two segments control dorsiflexion as well.



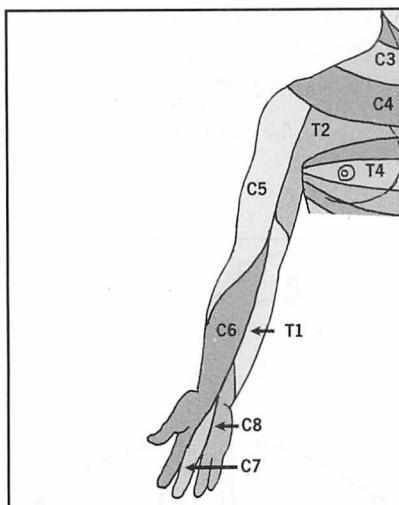
2.6. Myotomes (4): Both flexion and extension of the fingers are controlled by C7,8.



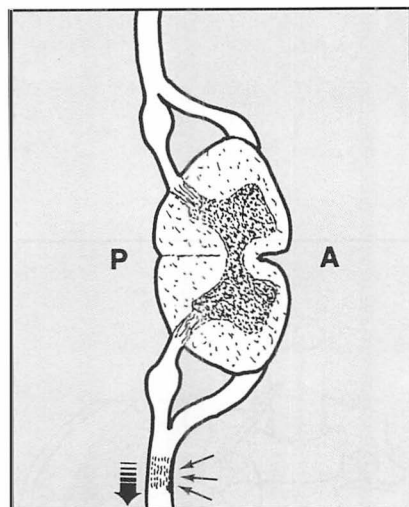
2.7. Myotomes (5): In the case of pronation and supination a single spinal segment is involved, namely C6.



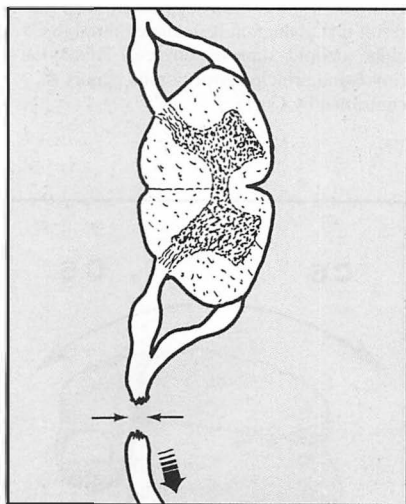
2.8. Myotomes (6): A single segment again, namely T1, is involved in producing abduction and adduction of the fingers: these movements are carried out by the small muscles (intrinsic) of the hand. Note: In testing for myotomes the ability to perform the above movements should be assessed by MRC grading, and note made of the segments affected. Often the defect can be localized to a single segment.



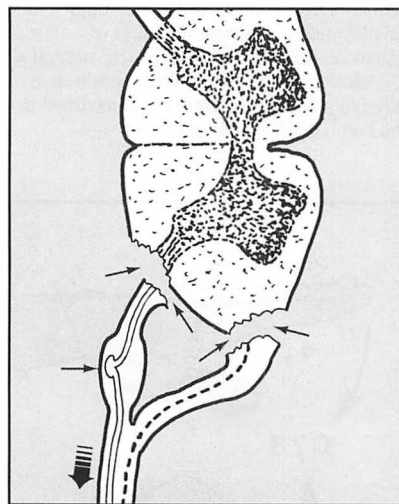
2.9. Dermatomes: Note that the middle finger is supplied by C7, and that there is a regular, easily remembered sequence of sensory distribution round the preaxial line of the limb.



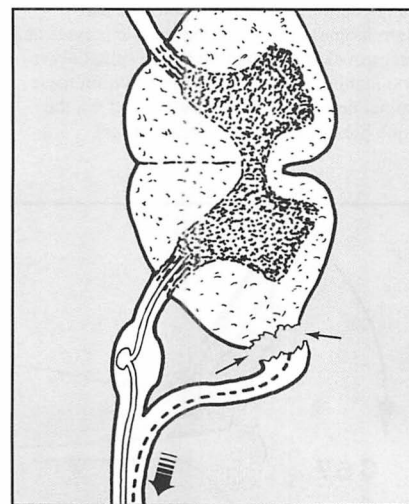
2.10. Types of brachial plexus injury (1): Lesions in continuity: more than half of plexus injuries are of this pattern. Traction is the commonest cause, and the nerve roots are affected between the intervertebral foramina and the clavipectoral fascia (postganglionic). The lesions may be transient (neuroparalysis). If the axons degenerate (axonotmesis), regeneration occurs at the rate of 1 mm/day, provided the axons can penetrate the intraneural scar.



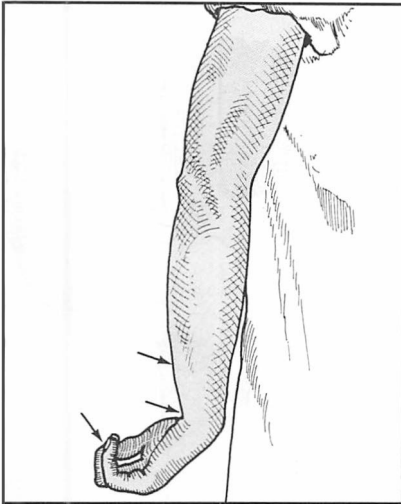
2.11. Lesions with ruptured nerve roots (2): In more severe injuries the nerves are disrupted at the same level. Only surgical intervention can offer any hope of recovery, but repair, even with nerve grafting, may be impossible because of extensive *intraneural* damage. It is important to differentiate between lesions of this type, lesions in continuity (where the treatment is expectant), and cord avulsion lesions (where the prognosis is hopeless).



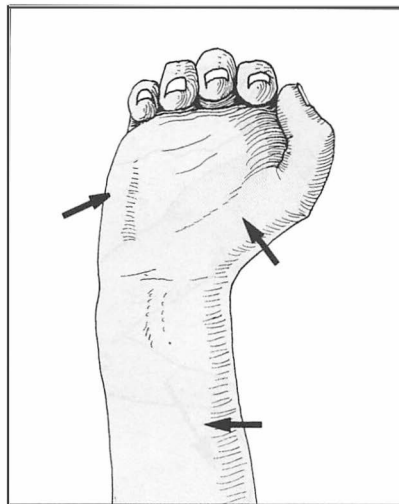
2.12. Complete avulsion lesions (3): The nerve is avulsed from the cord and surgical repair is impossible. Motor axons degenerate and the paralysed muscles show denervation fibrillation potentials on the electromyograph (EMG). The cells of the sensory nerves in the dorsal root ganglion remain intact (preganglionic lesion); although sensation is lost, conduction within the distal nerve remains and may be detected through externally applied electrodes.



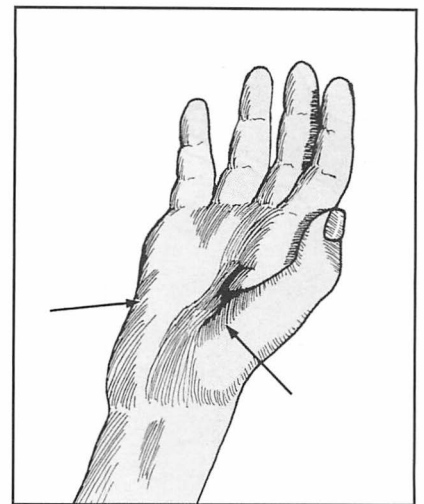
2.13. Partial avulsion lesions (4): Rarely, the posterior roots are spared, so that there may be the paradox of muscle paralysis accompanied by preservation of sensation. The prognosis for the motor loss is in these circumstances also hopeless. Although the exact nature of the lesion may seem fairly clear after clinical examination and further investigation, in many cases the picture is complex owing to the fact that one or more of these injuries may be combined.



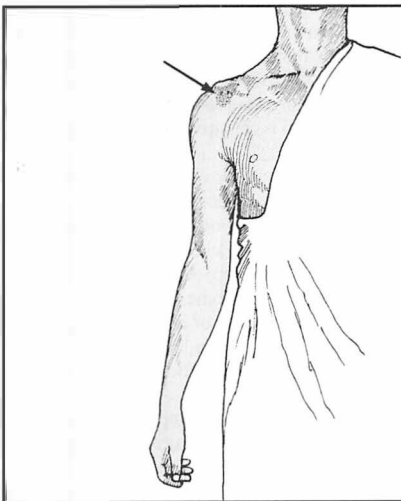
2.14. Long-standing plexus lesions (1): In Erb's palsy (upper obstetrical palsy), which affects the upper trunk of the brachial plexus (and hence C5,6), there is deformity of the limb, which is held in a characteristic position: the wrist is flexed and pronated, and the fingers flexed. The elbow is extended and the shoulder internally rotated (waiter's tip deformity). The nerve to rhomboids and the long thoracic nerve are usually spared.



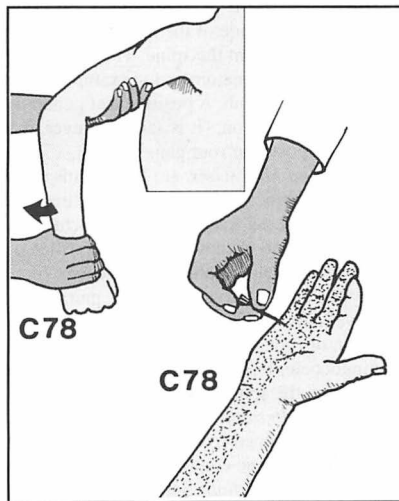
2.15. Long-standing plexus lesions (2): In *Klumpke's paralysis* the small (intrinsic) muscles, including the hypothenar and thenar groups, are wasted and there is a claw hand deformity. There is sensory loss on the medial side of the forearm and wrist. In many cases there is an associated Horner syndrome. (Note also that 38% of patients who receive radiotherapy for breast carcinoma develop a brachial neuropathy.)



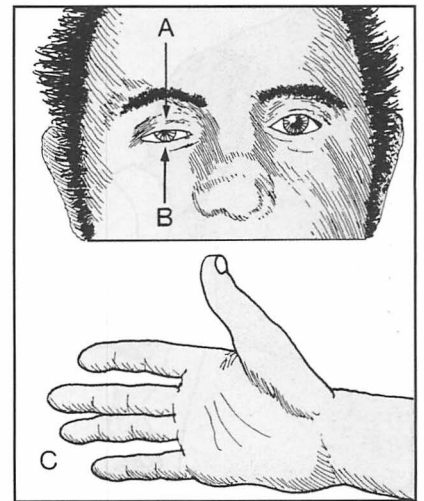
2.16. Long-standing plexus lesions (3): The T1 root alone may be involved, the sole signs being wasting of the small muscles of the hand, including the thenar group, along with sensory loss on the medial side of the hand only. Lesions of this type are seen in incomplete lower obstetrical palsy, cervical spondylosis, cervical rib syndrome, neurofibromatosis, and apical and metastatic carcinoma.



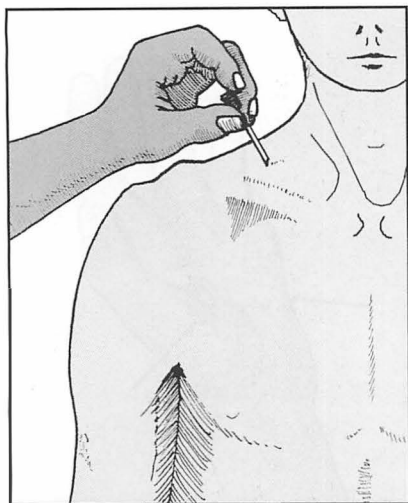
2.17. Acute traumatic lesions of the brachial plexus: The commonest mechanisms of injury involve depression of the shoulder combined with lateral flexion of the neck to the opposite side, or traction on the arm. Motorcycle accidents are the single most common cause. On inspection, look for the presence of telltale bruising over the shoulder or at the root of the neck. In the more severe cases the arm hangs flailly at the side.



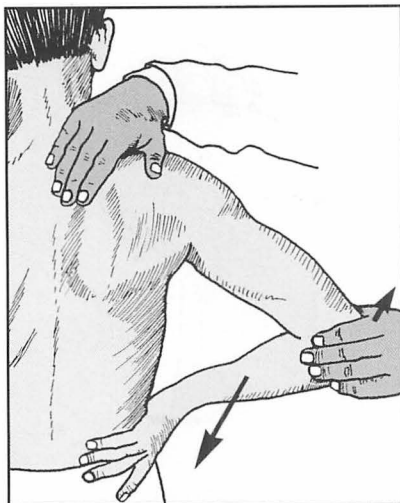
2.18. Assessment (1): Begin by determining the *extent* of the lesion, i.e. which segments are involved, and whether the involvement is partial or complete. Start by testing for active movements in the shoulder, elbow, wrist and fingers, relating your findings to the myotomes responsible for these movements. Then check for sensation to pinprick and light touch, again noting the dermatomes involved (which normally correspond with the previously determined myotomes).



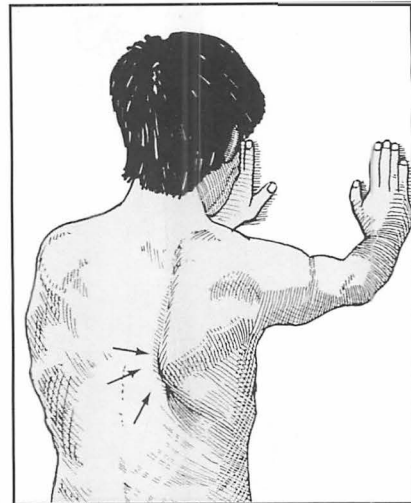2.19. Assessment (2): After determining which segments are affected, you should try to form an opinion as to the *type* of injury. This may be difficult to clarify, but the more evidence there is of proximal damage, the greater the chance of cord avulsion and a poor prognosis. Horner's syndrome, characterized by (A) pseudoptosis, (B) smallness of the pupil on the affected side, and (C) dryness of the hand from absence of sweating, occurs when the T1 root is involved close to the canal.



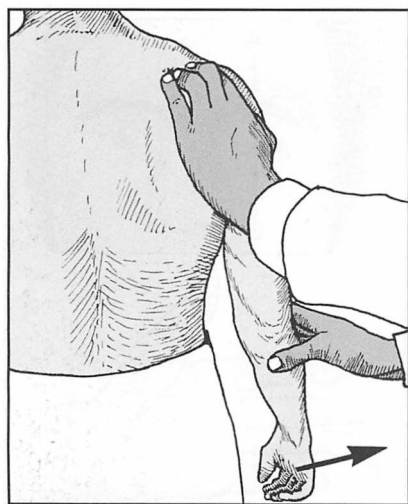
2.20. Assessment (3): Look for sensory loss above the clavicle. This area is normally supplied by C3,4, and if this is affected it generally indicates that the injury has been so severe that it has not only involved the plexus but the roots above; it is usually indicative of a proximal injury with a poor prognosis. Deep bruising in the posterior triangle is also strongly suggestive of a preganglionic lesion.



2.21. Assessment (4): Now test the first nerves that come off the plexus. *Nerve to rhomboids (C5):* Ask the patient to place the hand on the hip and to resist the elbow being pushed forwards; feel for contraction in the rhomboid muscles. Absence of activity is indicative of a lesion proximal to the formation of the upper trunk of the plexus (and suggestive of cord avulsion). Presence of activity means a lesion distal to the intervertebral foramen.



2.22. Assessment (5): *Nerve to serratus anterior (C5,6,7):* Damage to this nerve produces winging of the scapula, which is normally demonstrated by asking the patient to lean with both hands against a wall, but this test may have to be abandoned in the presence of an extensive plexus lesion. (Note that the nerve to serratus anterior may be damaged in isolation through lifting very heavy weights.)



2.23. Assessment (6): *Suprascapular nerve (C5,6):* This nerve arises from the upper trunk of the plexus and supplies the supraspinatus and infraspinatus. To test for activity in the supraspinatus, ask the patient to try to abduct the arm against resistance; feel for muscle contraction above the spine of the scapula. (The *infraspinatus* may be tested by feeling for muscle contraction below the spine of the scapula while the patient attempts to rotate the shoulder externally.)

2.24. Assessment (7): Other tests, observation and investigations. (1) *Tinel's sign:* Tap vigorously at the side of the neck, working from above downwards in the line of the nerve roots as they emerge from the spine. The test is positive if there is marked, painful paraesthesia in the corresponding dermatomes: for example, if tapping over the C6 root produces severe pain and tingling in the thumb. A positive test generally indicates a ruptured nerve root and a postganglionic lesion. (It is said, however, that the test may also be positive in the presence of an avulsed posterior root ganglion.)

(2) *X-ray and MRI scans:* (a) Plain films of the cervical spine should be obtained. Although these are of principal value in eliminating other pathology, they may occasionally reveal a transverse process fracture; such a fracture is indicative of the severity of an injury and the probability of an irrecoverable lesion. (b) A plain PA radiograph of the chest may reveal paralysis of a hemidiaphragm, indicative of a proximally sited lesion. (c) An MRI scan may clarify the site of nerve disruption, particularly in the case of preganglionic lesions. (d) Myelography may give valuable information regarding the presence or absence of signs of avulsion of roots from the cord. Signs indicative of a poor prognosis include traumatic meningocele, loss or diminution or exaggeration of root pouches, and cystic accumulation of CSF within the spinal canal.

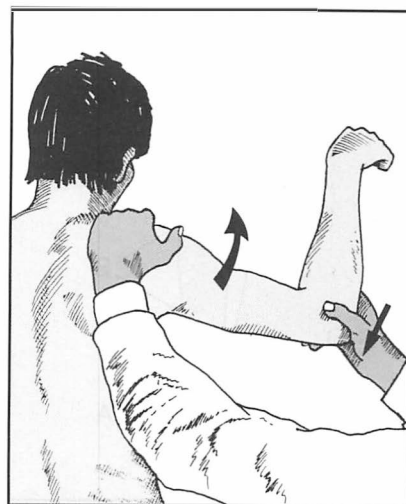
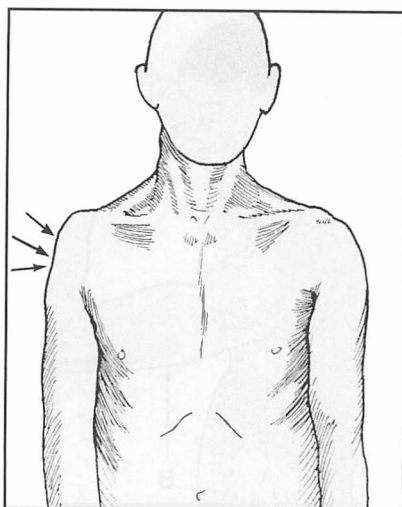
(3) *Electromyography:* It has been recommended that at least two muscles supplied by each root should be examined by the insertion of needle electrodes: the presence of any action potentials will indicate some continuity in that root.

(4) *Sensory conduction:* Sensory conduction may be assessed in two ways: (a) by electrically stimulating (say) the median nerve at the wrist, and by means of separate electrodes attempting to pick up resultant potentials over the plexus or in the neck (evoked potentials); or (b) stimulating (say) the median nerve at the wrist, and attempting to pick up potentials distally by means of ring electrodes round the index finger (sensory action (antidromic) potentials). The latter method appears preferable. One side is compared with the other. If the sides are the same, this suggests a severe or complete preganglionic lesion (avulsion of nerve roots from the cord). If no sensory action potentials are obtained on the injured side, this suggests a postganglionic lesion; and if diminished action potentials are present, a mixed lesion is likely.

(5) *Histamine test:* A drop of 1% histamine is placed over the centre of each affected dermatome and the skin pricked through it; the normal side is used as a control. On the normal side there should be the usual triple response, with the flare fully developed within 10 minutes. Absence of a flare on the injured side suggests postganglionic damage. If a normal triple response is found persisting after 3 weeks in anaesthetic skin, a preganglionic lesion is virtually certain.

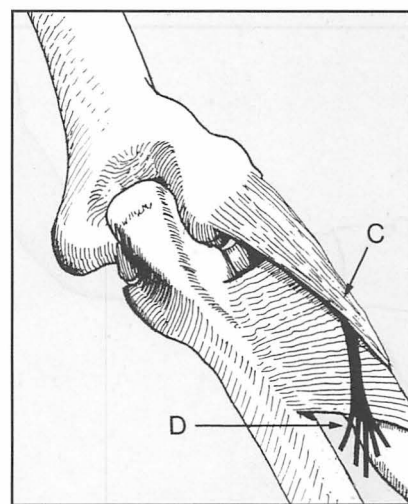
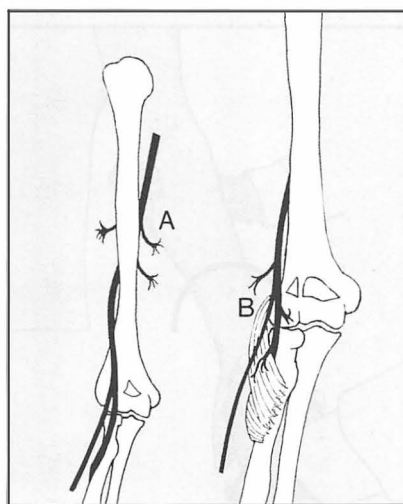
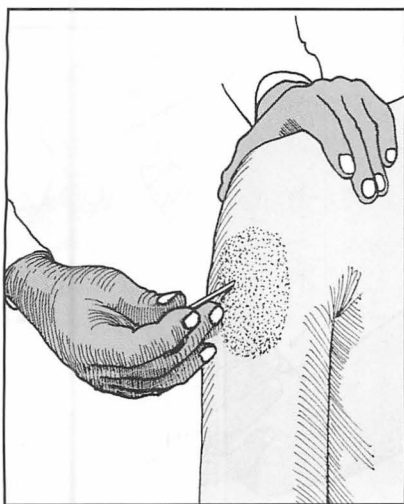
2.25. Summary of signs indicative of a poor prognosis in traumatic lesion of the plexus:

1. A complete lesion involving all five roots
2. Severe pain in an anaesthetic arm
3. Sensory loss above the clavicle and bruising in the posterior triangle
4. Fracture of a transverse process
5. Horner's syndrome
6. Paralysis of rhomboids and serratus anterior
7. Retention of sensory conduction in the presence of sensory loss.



2.26. Examination of the peripheral nerves of the upper limb: *The axillary (circumflex) nerve (posterior cord) C5,6: (1):* This nerve is most commonly damaged during shoulder dislocations and displaced fractures of the proximal humerus (humeral neck fractures). Spontaneous recovery usually occurs. Flattening over the lateral aspect of the shoulder develops when muscle wasting is at its height.

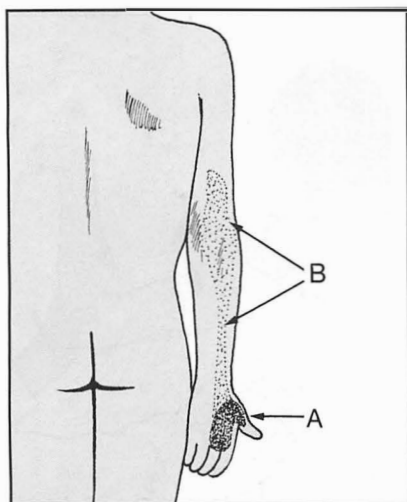
2.27. Axillary nerve (2): Ask the patient to attempt to move the arm from the side, pain permitting, while you resist any movement. Look and feel for deltoid contraction. Sometimes this is difficult to assess, and the two sides should be carefully compared if there is any doubt.



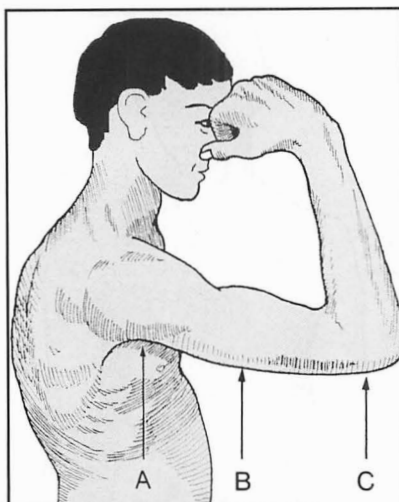
2.28. Axillary nerve (3): Look for loss of sensation over the 'regimental badge' area of the shoulder: this is the area exclusively supplied by the axillary nerve. Where the shoulder is too painful to move (e.g. if dislocated) loss of sensation is sufficient evidence of axillary nerve involvement without testing muscle power.

2.29. Radial nerve: (posterior cord) C5,6,7,8 (T1): Motor distribution: (A) In the upper arm the radial nerve supplies triceps. (B) In front of the elbow, it supplies brachioradialis, extensor carpi radialis longus and brachialis. Its posterior interosseous branch, before it enters the supinator tunnel, supplies extensor carpi radialis brevis and part of supinator.

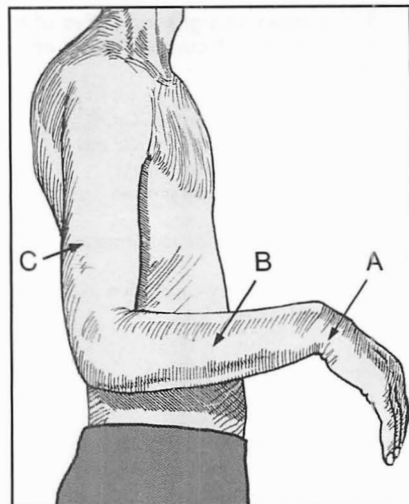
2.30. Radial nerve (motor distribution) ctd.: (C) In the supinator tunnel the posterior interosseous branch of the radial supplies the rest of supinator: lesions here may cause local tenderness. (D) On leaving supinator below the elbow it supplies extensor digitorum communis, extensors digiti minimi and indicis, extensor carpi ulnaris, abductor pollicis longus, and extensors pollicis longus and brevis.



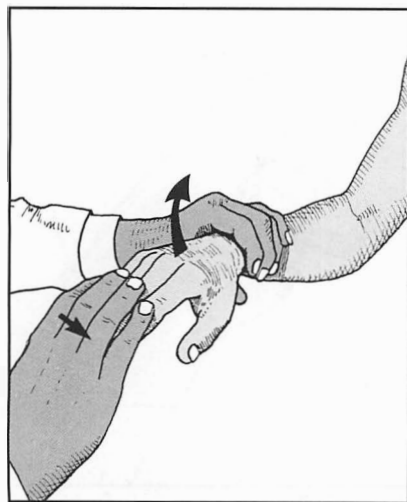2.31. Radial nerve: Sensory distribution: (A) The terminal part (the superficial radial nerve) supplies the radial side of the back of the hand. (B) The posterior cutaneous branch of the radial, given off in the upper part of the arm, supplies a variable area on the back of the arm and forearm.



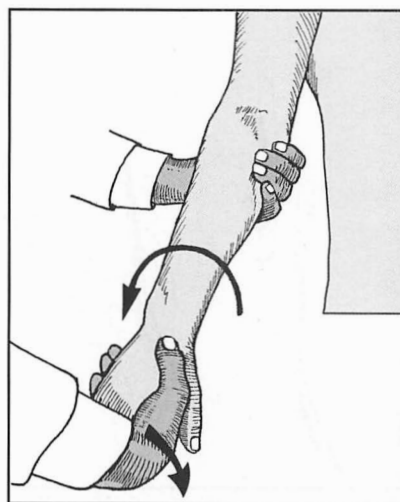
2.32. Radial nerve: Common sites affected: (A) In the axilla (e.g. from crutches, or the back of a chair in the so-called 'Saturday night' palsy); (B) Mid-humerus (from fractures and tourniquet palsies); (C) at and below the elbow (e.g. after dislocations of the elbow, Monteggia fractures, ganglions, and sometimes surgical trauma following exposures in this region).



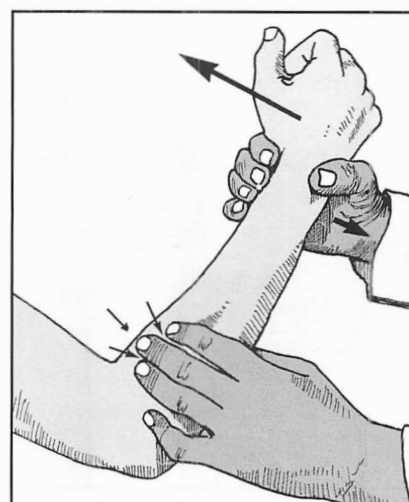
2.33. Examination of the radial nerve (1): Note in particular the following: (A) Is there an obvious wrist drop? (B) Is there wasting of the forearm muscles? (C) Is there wasting of the triceps, suggesting a high (proximal) lesion?



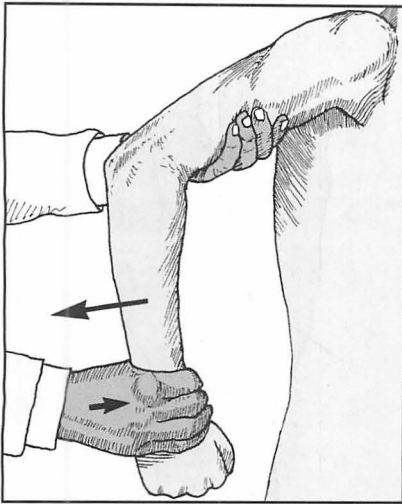
2.34. Examination of the radial nerve (2): Test the extensors of the wrist and fingers. The elbow should be flexed and the hand placed in pronation. Support the wrist, and ask the patient first to try and straighten the fingers and then to pull back the wrist: if there is any activity, judge the strength by applying counterpressure on the fingers or hand.



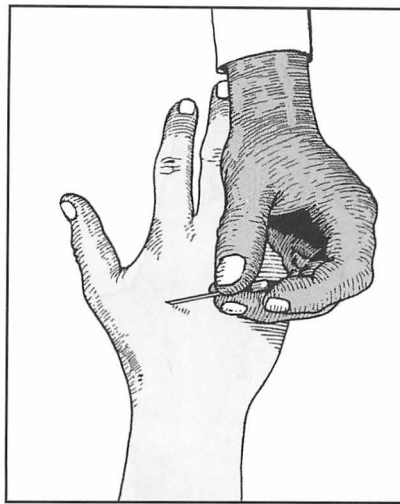
2.35. Examination of the radial nerve (3): Now test the supinator muscle. The elbow must be extended to eliminate the supinating action of biceps. Ask the patient to turn his hand while you apply counterforce. Loss of supination suggests a lesion proximal to the exit of the supinator tunnel. Look for tenderness over the tunnel.



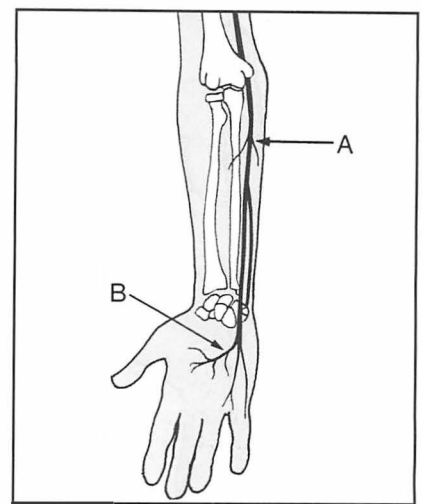
2.36. Examination of the radial nerve (4): Test the brachioradialis. Ask the patient to flex the elbow in the midprone position against resistance. Feel and look for contraction in the muscle. Loss of power suggests a lesion above (proximal to) the supinator tunnel.



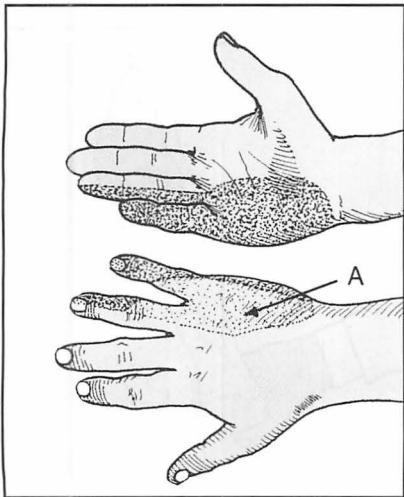
2.37. Examination of the radial nerve (5): Now test the triceps. Extend the shoulder and ask the patient to extend the elbow, first against gravity and then against resistance. Weakness of triceps suggests a lesion at mid-humeral level, or an incomplete high lesion; loss of all triceps activity suggests a high (plexus) lesion.



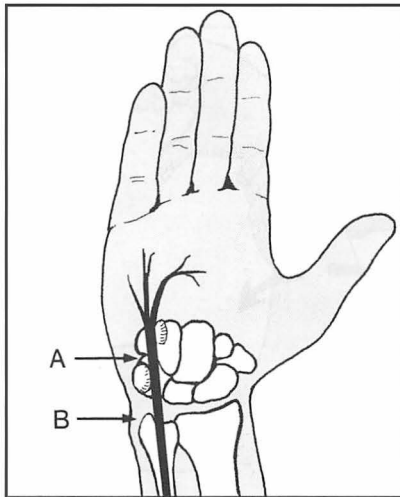
2.38. Examination of the radial nerve (6): Test for sensory loss in the areas supplied by the nerve. Loss confined to the hand indicates that the lesion is unlikely to be much proximal to the elbow. Careful analysis of both the motor and sensory deficits should allow accurate localization of the lesion.



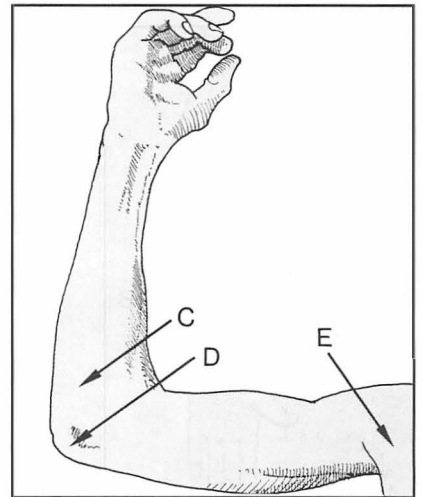
2.39. Ulnar nerve (medial cord) C8, T1:
Motor distribution: (A) In the forearm it supplies flexor carpi ulnaris and half of flexor digitorum profundus. (B) In the hand, it supplies the hypothenar muscles, the interossei, the two medial lumbricals, and adductor pollicis.



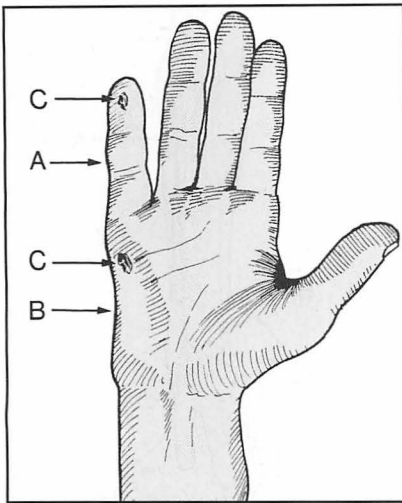
2.40. Ulnar nerve: Sensory distribution: Note that there are variations in the areas supplied by the median and ulnar nerves in the hand: the commonest pattern is illustrated. The branch supplying the dorsum (A) arises in the forearm; loss here indicates a lesion proximal to the wrist.



2.41. Ulnar nerve: common sites affected (1): (A) In the ulnar tunnel syndrome, where the nerve passes between the pisiform and the hook of the hamate (e.g. from the pressure of a ganglion, or a hook of hamate fracture). The most distal lesions affect the deep palmar nerve and are entirely motor. (B) At the wrist, especially from lacerations, occupational trauma and ganglions.

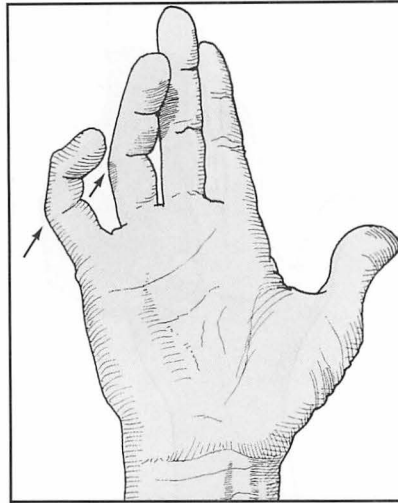


2.42. Ulnar nerve: common sites affected (2): (C) Distal to the elbow, by compression as it passes between the two heads of flexor carpi ulnaris (ulnar tunnel syndrome). (D) At the level of the medial epicondyle (e.g. in ulnar neuritis secondary to local friction, pressure or stretching, as may occur in cubitus valgus and osteoarthritis). (E) In the brachial plexus, as a result of trauma, or from other lesions in this area.



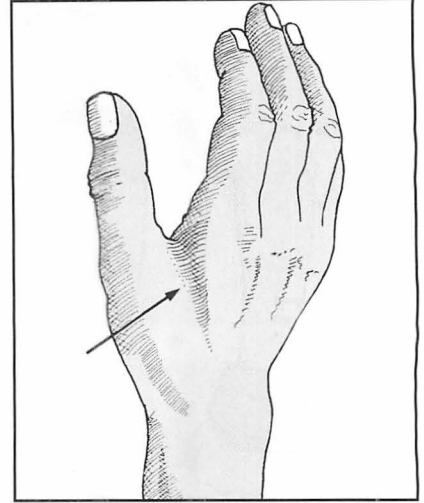
2.43. Ulnar nerve examination (1):

Note the presence of (A) involuntary abduction of the little finger; (B) hypothenar wasting; (C) ulceration of the skin, brittleness of the nails, and any other evidence of trophic change.



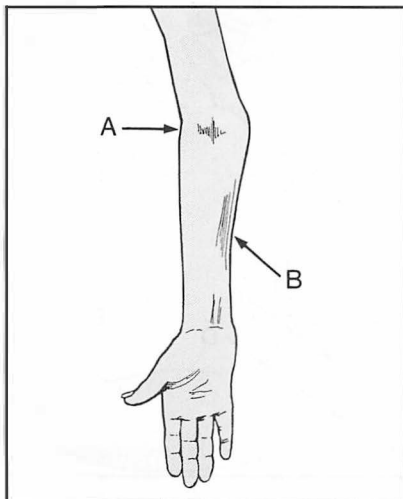
2.44. Ulnar nerve examination (2):

Note whether there is an ulnar claw hand, with flexion of the ring and little fingers at the proximal IP joints. If the distal IP joints are flexed as well, this suggests that the flexor digitorum profundus is intact and the lesion is distally placed: i.e. paradoxically, the deformity of the hand is less marked in lesions proximal to the wrist, where there is more motor involvement.



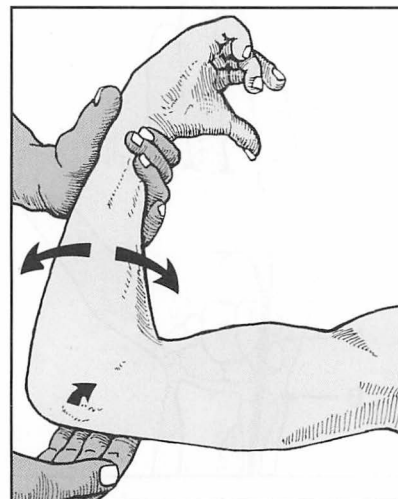
2.45. Ulnar nerve examination (3):

The ulnar nerve supplies all the interossei, so look for the presence of any interosseous muscle wasting. The first dorsal interosseous muscle is almost always the first to become noticeably affected, and the hollowing of the skin on the dorsal aspect of the first web space is often most striking.



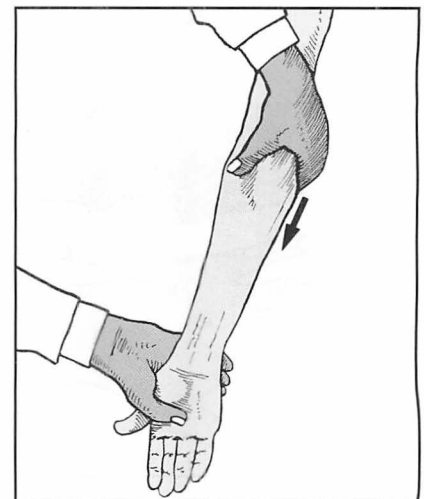
2.46. Ulnar nerve examination (4):

Note (A) if there is any cubitus valgus or varus deformity suggesting an old injury, such as a supracondylar fracture (of significance in tardy ulnar nerve palsy). (B) Muscle wasting on the medial side of the forearm, confirming a lesion proximal to the wrist. Compare one forearm with the other.



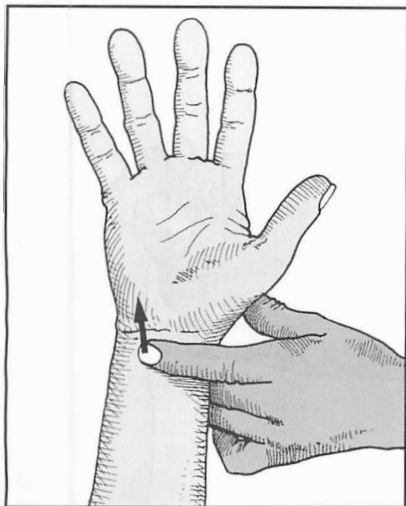
2.47. Ulnar nerve examination (5):

Flex and extend the elbow, looking for abnormal mobility in the nerve where it passes behind the medial epicondyle. If the nerve is seen to snap over the medial epicondyle, a traumatic ulnar neuritis (secondary to a deficiency in the tissues that normally anchor it in position) may be diagnosed with reasonable confidence.

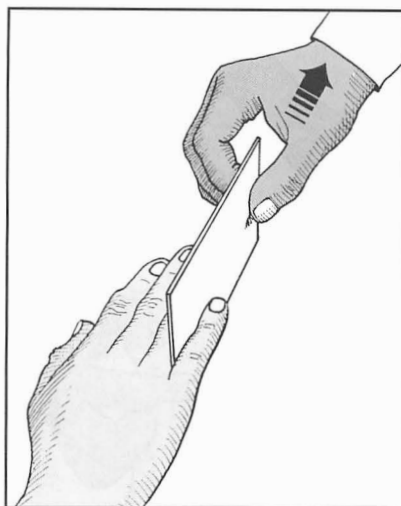


2.48. Ulnar nerve examination (6):

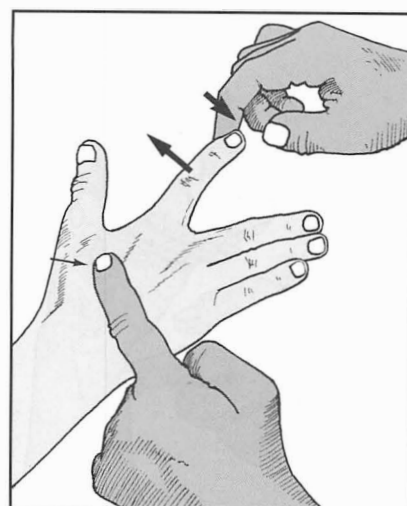Roll the nerve under the fingers above the medial epicondyle and follow it distally until it disappears under cover of flexor carpi ulnaris – about 4 cm distal to the medial epicondyle. Note the presence of any tenderness, thickening, or the production of an unusual degree of paraesthesia.

**2.49. Ulnar nerve examination (7):**

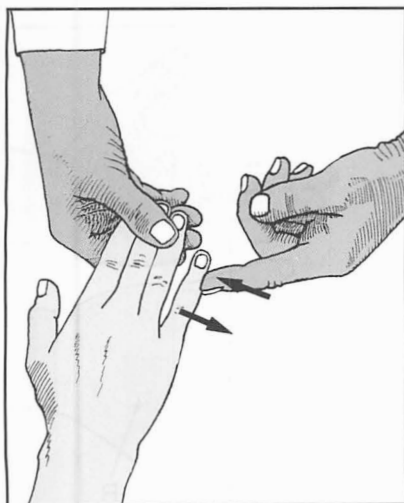Palpate the nerve as it lies just lateral to the tendon of flexor carpi ulnaris at the wrist. Follow it down to the region of the ulnar tunnel, again looking for undue tenderness and paraesthesia.

**2.50. Ulnar nerve examination (8):**

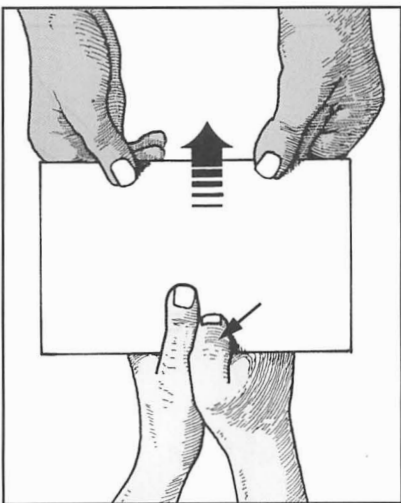
Testing the interossei. Ask the patient to hold a sheet of paper between the ring and little fingers. The fingers *must* be fully extended. Withdraw the paper and note the resistance offered. In a complete palsy the little finger is normally held in slight abduction and the patient will be unable to grip the paper at all.

**2.51. Ulnar nerve examination (9):**

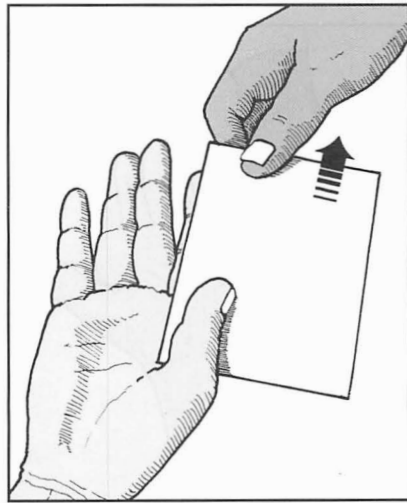
Testing the first dorsal interosseous muscle. Place the patient's hand in a palm-downwards position and ask him to resist while you attempt to adduct the index. Look and feel for contraction in the first dorsal interosseous.

**2.52. Ulnar nerve examination (10):**

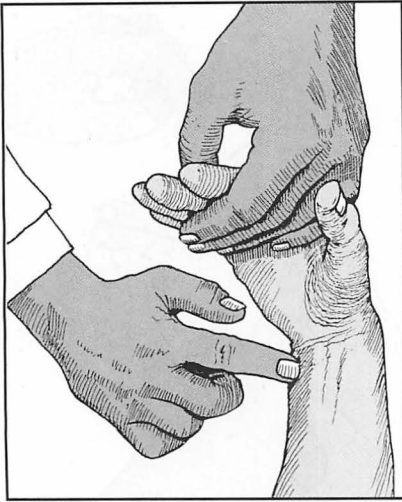
Testing abductor digiti minimi. Ask the patient to resist as you adduct the extended little finger with your index. Note the resistance offered and compare one hand with the other.

**2.53. Ulnar nerve examination (11):**

Testing adductor pollicis (1). Ask the patient to grasp a sheet of paper between the thumbs and sides of the index fingers while you attempt to withdraw it. If the adductor of the thumb is paralysed the thumb will flex at the interphalangeal joint, in contrast to the good side (Froment's test).

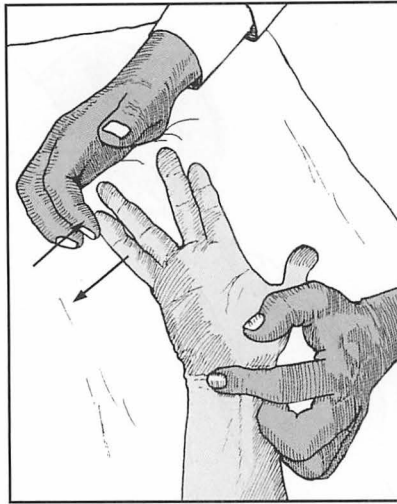
**2.54. Ulnar nerve examination (12):**

Testing adductor pollicis (2). Alternatively, test the patient's ability to grasp a sheet of paper held between the thumb and the *anterior* aspect of the index metacarpal.



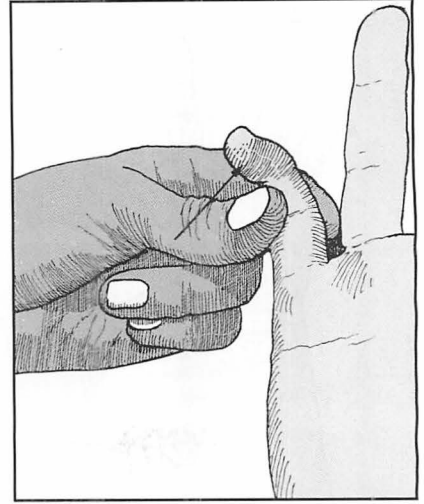
2.55. Ulnar nerve examination (13):

Testing flexor carpi ulnaris (1). Ask the patient to resist while you attempt to extend the flexed wrist. Feel for the tendon tightening at the wrist while you note the resistance offered.



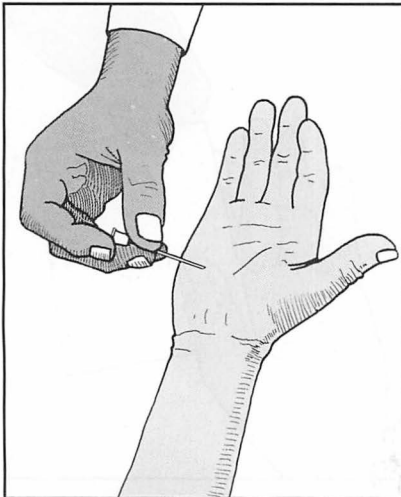
2.56. Ulnar nerve examination (14):

Testing flexor carpi ulnaris (2). Place the hand on a flat surface and ask the patient to resist while you attempt to adduct the little finger. Again feel for contraction in the tendon. Loss of activity indicates a lesion proximal to the wrist.



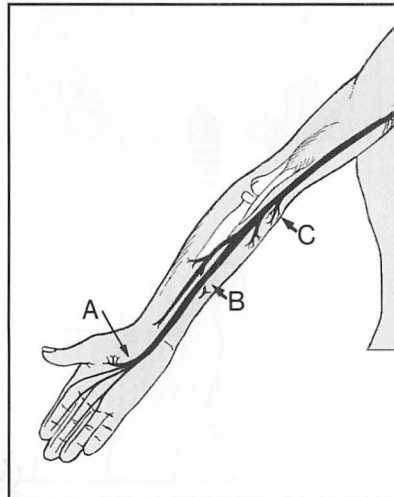
2.57. Ulnar nerve examination (15):

Testing flexor digitorum profundus. Only the ulnar half of this muscle is supplied by the ulnar nerve. Support the middle phalanx of the little finger and ask the patient to try to flex the distal joint. Apply counterpressure to the fingertip and note the resistance. Loss of power indicates a lesion near or above the elbow.



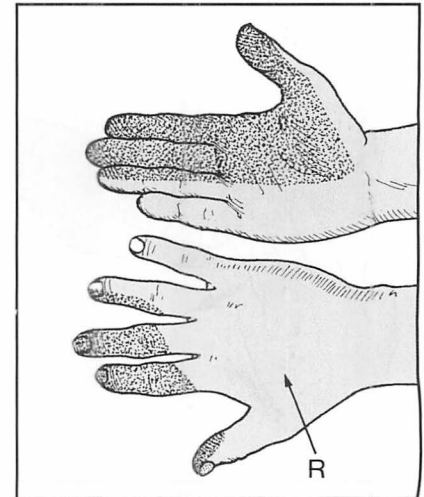
2.58. Ulnar nerve examination (16):

Testing for sensation. Test for any disturbance of pinprick sensation in the area supplied by the nerve. Note that sensory loss on the *dorsum* is indicative of a lesion proximal to the wrist.



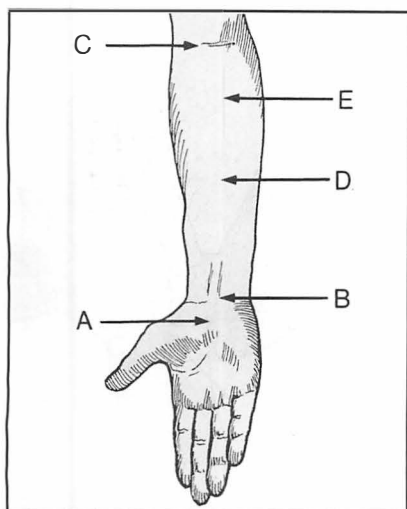
2.59. Median nerve (lateral and medial cords) C(5)6,7,8, T1:

Motor distribution (A) Hand: the thenar muscles and the lateral two lumbricals. (B) Forearm (through its anterior interosseous branch): flexor pollicis longus, half of flexor digitorum profundus, pronator quadratus. (C) Near the elbow: flexor digitorum superficialis (sublimis), flexor carpi radialis, palmaris longus and pronator teres.

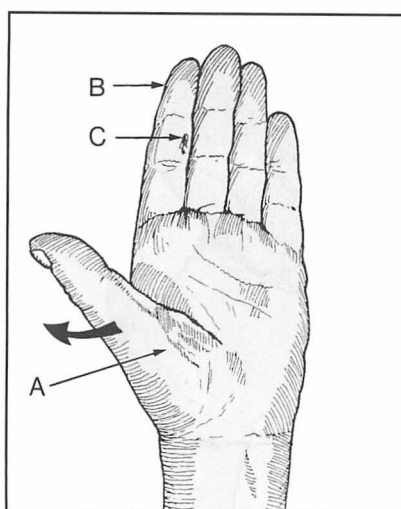


2.60. Median nerve: sensory distribution:

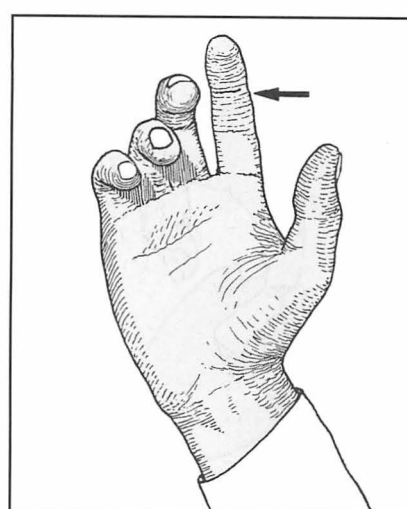
Note that there is considerable variation in the relative areas supplied by the median and ulnar nerves. Note also that the lateral side of the posterior aspect of the hand is supplied by the terminal part of the radial nerve (superficial radial nerve) (R). The commonest pattern of sensory distribution is shown.



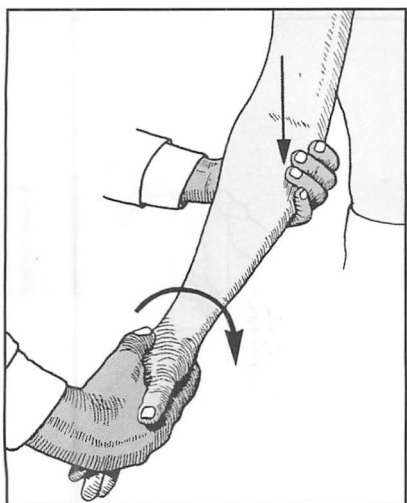
2.61. Median nerve: common sites affected: (A) In the carpal tunnel (e.g. carpal tunnel syndrome, and some fractures and dislocations about the wrist). (B) At the wrist (e.g. from lacerations). (C) At the elbow (e.g. after elbow dislocations in children). (D) In the forearm (anterior interosseous nerve) from forearm bone fractures, or by a tight tissue band at the origin of the superficialis. (E) Just distal to the elbow, in the pronator teres nerve entrapment syndrome.



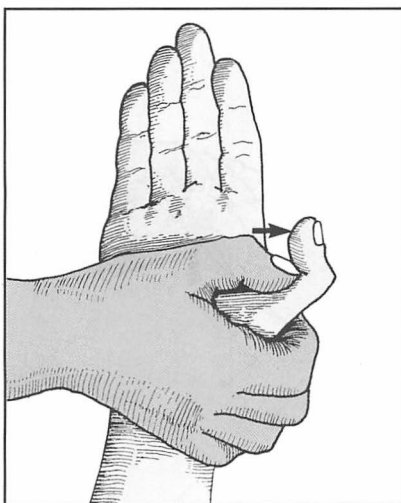
2.62. Median nerve examination (1): Note (A) thenar wasting. In long-standing cases the thumb may come to lie in the plane of the palm (Simian thumb). (B) Atrophy of the pulp of the index, cracking of the nails and other trophic changes. (C) Cigarette burns and other signs of skin trauma secondary to local sensory deprivation.



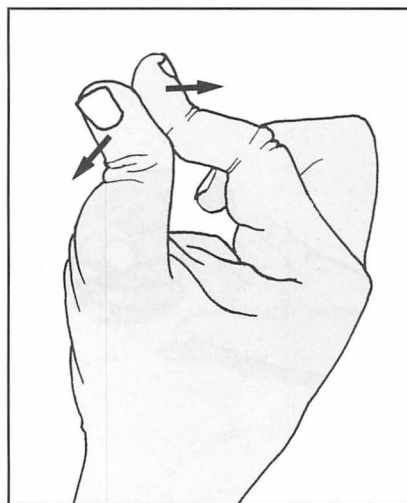
2.63. Median nerve examination (2): In lesions of the anterior interosseous branch, or of the median nerve itself at or above the elbow, there may be wasting of the lateral aspect of the forearm, and the index is held in a position of extension ('benediction attitude': but note that in some quarters an ulnar nerve palsy with an ulnar claw hand has confusingly attracted the same term).



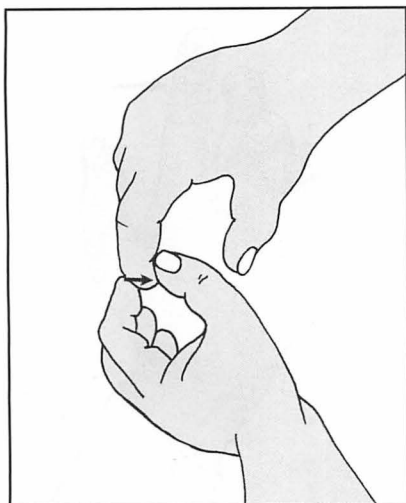
2.64. Median nerve examination (3): Testing pronator teres. Extend the patient's elbow and feel for contraction in the muscle as he attempts to pronate the arm against resistance. Loss indicates a lesion at or above the elbow. Accompanying pain and tenderness over pronator teres is found in the pronator teres entrapment syndrome.



2.65. Median nerve examination (4): *anterior interosseous branch (1):* Test the power of flexor pollicis longus in the thumb, and flexor digitorum profundus in the index by asking the patient to try to flex the appropriate distal joint while you support the phalanx proximal to it. Loss of power here may also occur in median nerve lesions proximal to the anterior interosseous branch.

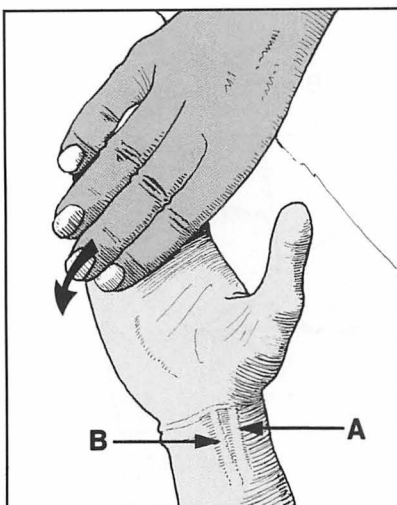


2.66. Median nerve examination (5): *anterior interosseous branch (2): Screening test:* Ask the patient to form a circle with his index and thumb and press their tips tightly together. In an anterior interosseous palsy the terminal phalanges of the thumb and index will hyperextend (owing to paralysis of flexor pollicis longus and the lateral half of flexor digitorum profundus), but the thenar muscles will remain intact.



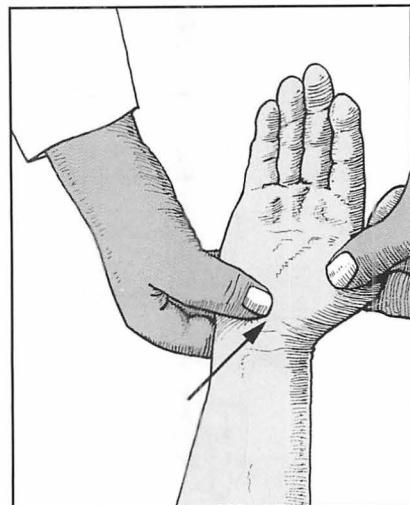
2.67. Median nerve examination (6):
anterior interosseous nerve palsy (3):

Screening test in children: It has been found that when a child with an anterior nerve palsy is asked to bend the end joint of the index finger he will use his other hand to do so. This shows that he understands the request, that movement of the finger is not painful (as it might be in a compartment syndrome), and that it is unlikely that he is able to undertake the movement actively.



2.68. Median nerve examination (7):

distal segment: First locate the position of the nerve at the wrist. Ask the patient to flex his wrist, then attempt to extend it while he resists. Look for the tendons which are prominent at the front, near the midline, palpating the area if necessary. The nerve lies between (A) flexor carpi radialis longus and (B) palmaris longus (or medial to flexor carpi radialis longus if the latter is absent).



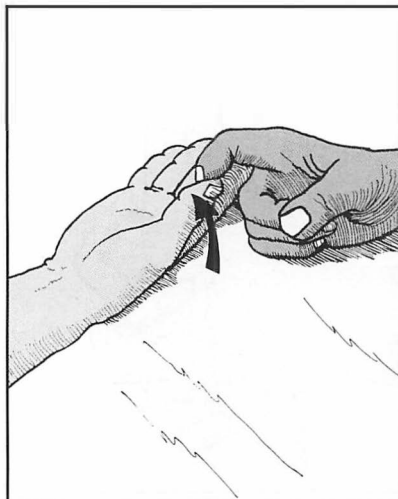2.69. Median nerve examination (8):

Apply firm pressure over the area of the nerve at the wrist and distally in the line of the carpal tunnel, looking for tenderness. (If the carpal tunnel syndrome is suspected, apply pressure with both thumbs, timing the onset of paraesthesia; and carry out the other tests detailed later in Chapter 6.)



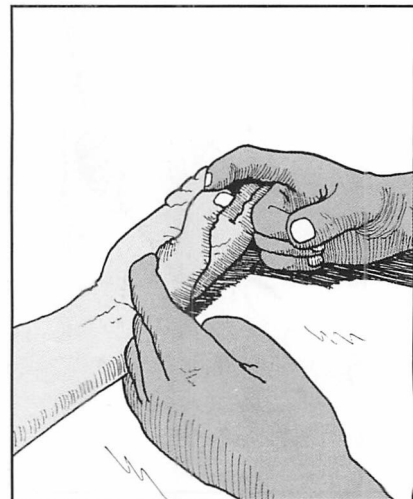2.70. Median nerve examination (9):

Testing abductor pollicis brevis (1): This muscle is invariably and exclusively supplied by the median nerve. To test it, begin by placing the patient's hand, palm upwards, on a flat surface. Hold your index finger above the palm.



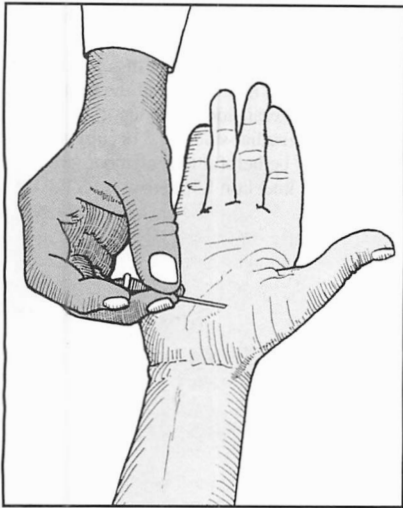
2.71. Median nerve examination (10):

Testing abductor pollicis brevis (2): Now ask the patient to raise his thumb and try to touch your finger. If he tends to move his hand while doing so, steady it with your other hand. Assess his ability to carry out the movement (he may not be able to do it), and look for contraction in the muscle.

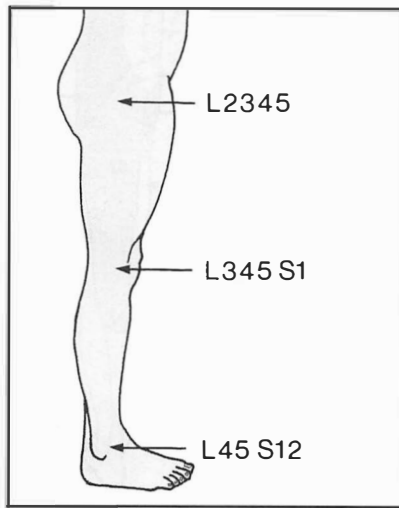


2.72. Median nerve examination (11):

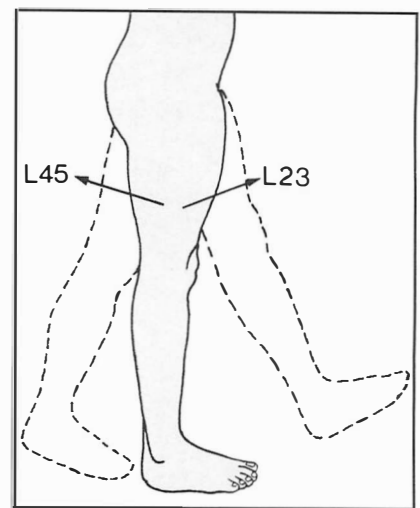
Testing abductor pollicis brevis (3): Ask the patient to resist while you attempt to force the thumb back down to the starting position. Note the resistance offered; palpate the muscle to confirm its tone and bulk, and compare the power on the affected side with that of the other.

**2.73. Median nerve examination (12):**

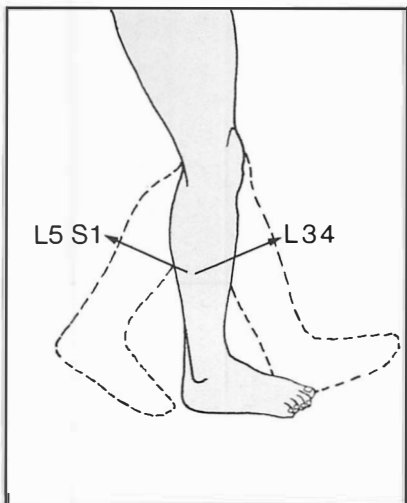
Testing for sensation: Look for impairment of sensation to pinprick in the area of distribution of the nerve.

**2.74. Segmental nerves in the lower limb:**

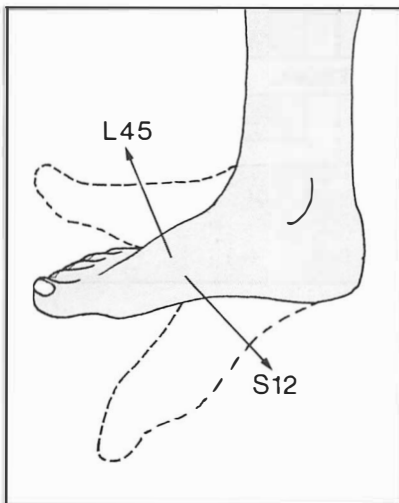
Myotomes (1): As previously described in relation to the upper limb, the general arrangement is that four consecutive spinal segments control each lower limb joint. In the case of the lower limb adherence to this plan is more rigorous. The progression of control from hip to ankle is shown in the diagram.

**2.75. Myotomes (2):** Flexion of the hip (mainly iliopsoas) is controlled by L2,3.

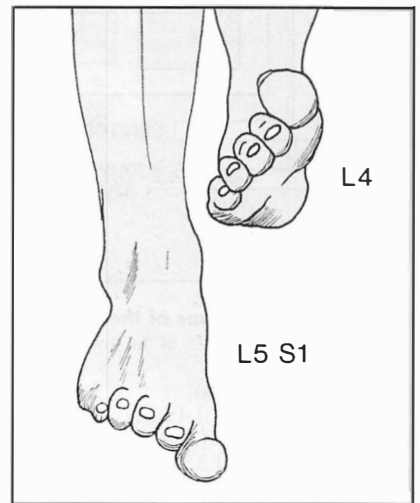
Extension of the hip (mainly gluteus maximus and the hamstrings) is controlled by L4,5 (L2,3 also control internal rotation, and L4,5 external rotation of the hip).



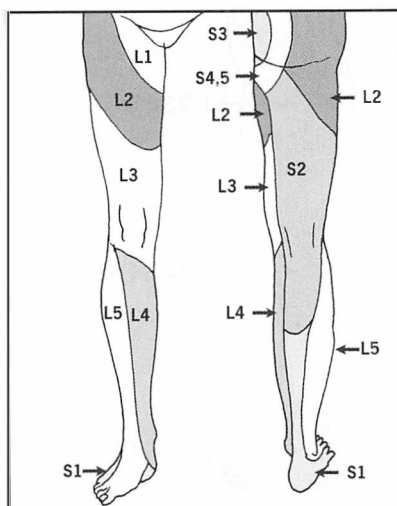
2.76. Myotomes (3): Extension of the knee and the knee jerk (quadriceps) is controlled by L3,4. Flexion of the knee (mainly hamstrings) is controlled by L5, S1.



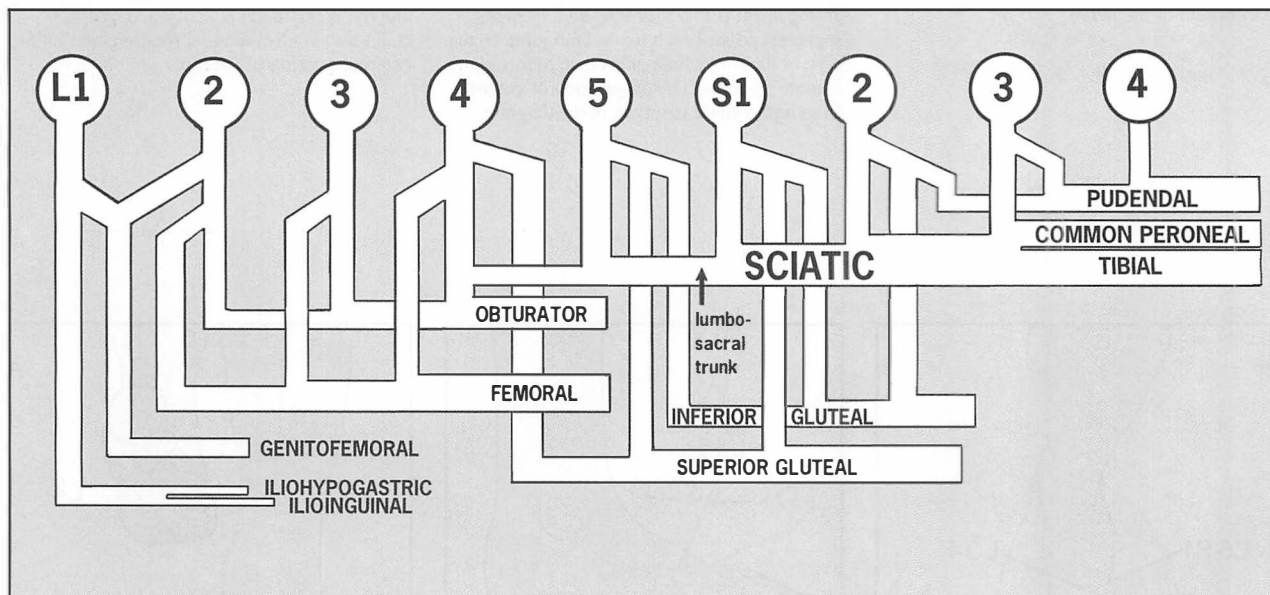
2.77. Myotomes (4): Dorsiflexion of the ankle is controlled by L4,5 (mainly tibialis anterior and the long extensors of the hallux and toes). Plantar flexion is controlled by S1,2 (mainly the muscles of the calf). The same segments control the ankle jerk.



2.78. Myotomes (5): It is also useful to know that inversion (mainly tibialis anterior) is controlled by L4. Eversion is controlled by L5, S1 (the peronei).



2.79. Dermatomes: Remember by the following: the side of the foot, S1, is commonly involved in L5–S1 disc lesions. L5 sweeps from the medial side of the foot next to S1 to the lateral side of the leg. L4 occupies the medial side, L2,3 occupy the thigh. It may be helpful to remember 'we stand on S1, kneel on L3, and sit on S3'.



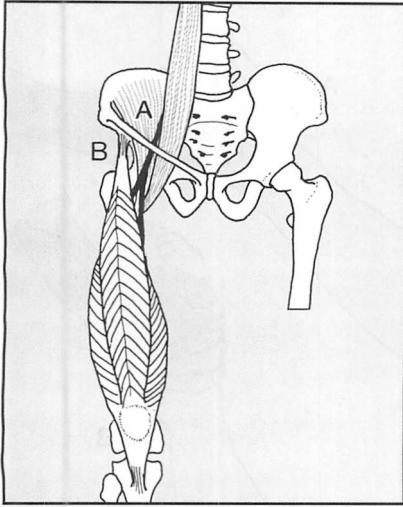
2.80. Peripheral nerves of the lower limb:

The most important nerves of the lower limb are:

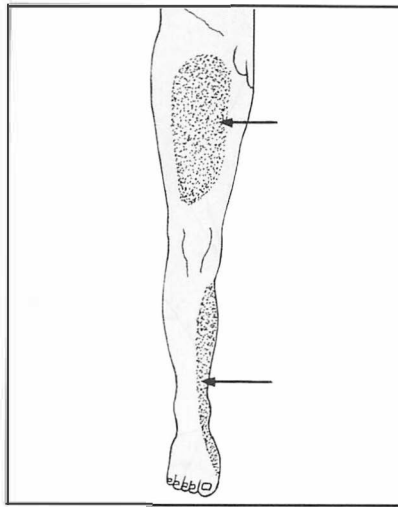
1. The femoral (L2,3,4)
2. The obturator (L2,3,4)
3. The superior gluteal (L4,5 S1)
4. The inferior gluteal (L5, S1,2)
5. The sciatic (L4,5 S1,2,3) and its two divisions, the tibial (L4,5 S1,2) and common peroneal (L4,5 S1,2,3).

Other branches shown include the pudendal (S2,3,4), the iliohypogastric and ilioinguinal (L1), and the genitofemoral (L1,2). Not illustrated are the lateral cutaneous nerve of the thigh (L2,3), the nerves to quadratus femoris and the inferior gemellus (L4,5 S1), the nerves to obturator internus and the superior gemellus (L5 S1,2), the nerve to piriformis (S1,2), the nerves to levator ani and the external sphincter (S4).

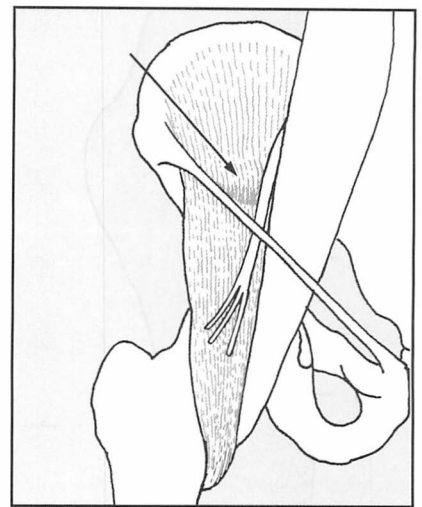
The lumbosacral trunk is formed from L4 and L5. In its progress it crosses the triangle of Marcell (bounded medially by L5, inferiorly by the proximal part of the sacrum, and laterally by the medial border of psoas), where it may be vulnerable to local pressure or traction. (Some consider that a number of cases of drop foot and other neurological problems occurring in late pregnancy may be due to involvement of the lumbosacral trunk rather than disc prolapse.)

**2.81. Femoral nerve: L2, 3, 4: (1):**

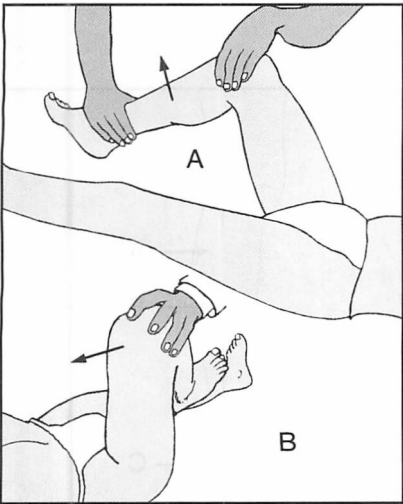
Motor distribution: (A) Above (i.e. proximal to) the inguinal ligament the femoral nerve supplies iliopsoas. (B) Below the inguinal ligament it supplies the quadriceps, sartorius and pectineus.

**2.82. Femoral nerve (2): Sensory**

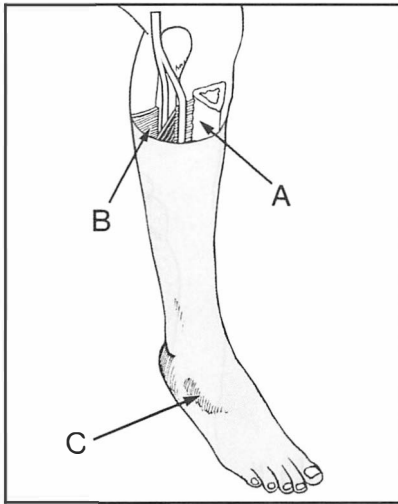
distribution: On emerging below the inguinal ligament it supplies the front of the thigh. The terminal part of the femoral nerve (renamed the saphenous nerve) supplies the medial side of the leg and the foot.

**2.83. Femoral nerve (3): Sites of**

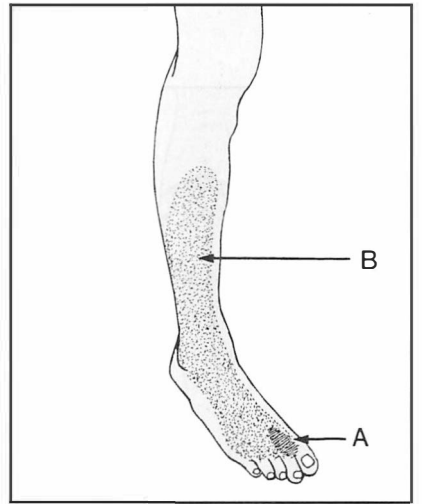
involvement: Closed lesions of the femoral nerve are rare. Damage may occur when a haematoma is formed in the iliacus muscle, causing local pressure. This is seen in haemophilia and in extension injuries of the hip.



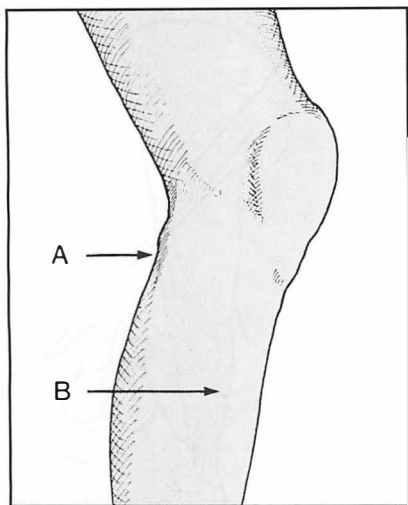
2.84. Femoral nerve (4): Tests: (A) Test the quadriceps by asking the patient to extend the knee against resistance. (B) Test the iliopsoas (hip flexion against resistance). The response to these tests should determine the level of any lesion. In doubtful cases try to elicit the knee jerk. Observe any quadriceps wasting, and test for loss of sensation to pinprick in the area supplied by the nerve.

**2.85. Common peroneal nerve (lateral popliteal): L4, 5, S1, 2 (1): Motor**

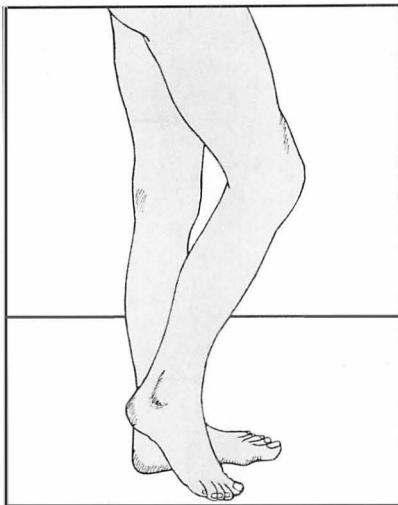distribution: (A) Muscles of the anterior compartment (tibialis anterior, extensor hallucis longus, extensor digitorum longus, peroneus tertius). (B) Muscles of peroneal compartment (peroneus brevis and longus). (C) On the foot, extensor digitorum brevis.

**2.86. Common peroneal nerve (2):**

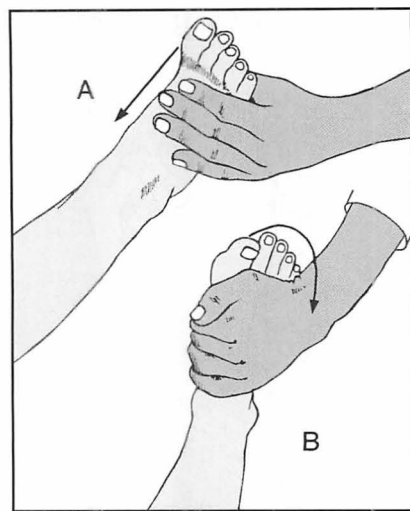
Sensory distribution: (A) The first web space (deep peroneal contribution). (B) The dorsum of foot and the front and side of the leg (superficial peroneal contribution).



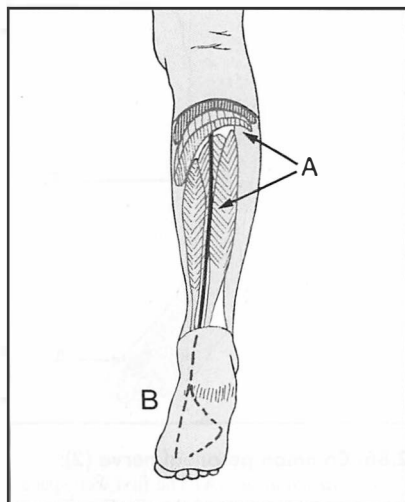
2.87. Common peroneal nerve (3): Sites of involvement: (A) At the fibular neck, e.g. from trauma (e.g. lateral ligament injuries of the knee, direct blows), and from pressure, e.g. from plaster casts or the side irons of a Thomas splint), ganglion, ischaemia (e.g. tourniquet). It is also involved in a number of neurological disorders. (B) Distal to the fibular neck, e.g. in the anterior compartment syndrome, where the deep peroneal branch may be affected.



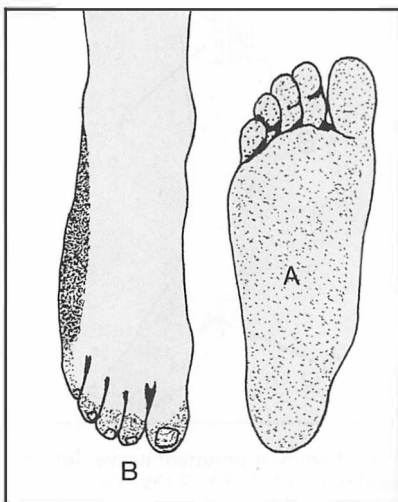
2.88. Common peroneal nerve (4): Deformity: The patient will have a drop foot and there will be disturbance of the gait: either the leg will be lifted high to allow the plantarflexed foot to clear the ground, or the foot will be slid along the ground (resulting in rapid and obvious unilateral wear of the shoe).



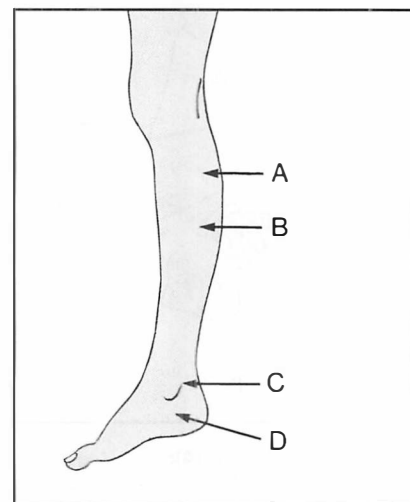
2.89. Common peroneal nerve (5): Tests: (A) Ask the patient to dorsiflex the foot (deep peroneal branch) and (B) to evert the foot (superficial peroneal branch). Test for sensation in the area of distribution of the nerve. Note any wasting of the front or side of the leg.



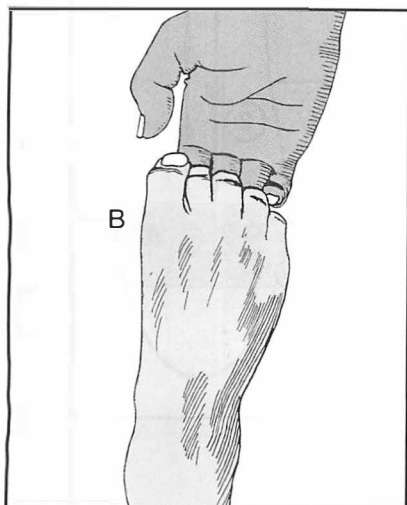
2.90. Tibial nerve (medial popliteal) (1): L4,5, S1,2,3: Motor distribution: (A) Soleus and the deep muscles of the posterior compartment (tibialis posterior, flexor hallucis longus, flexor digitorum longus). (B) All the muscles of the sole of the foot through its terminal branches of the medial and lateral plantar nerves. It also supplies gastrocnemius before passing under the soleal arch.



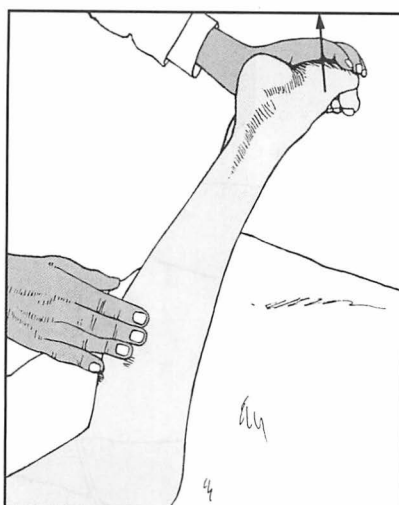
2.91. Tibial nerve (2): Sensory distribution: (A) The sole of foot through the medial and lateral plantar nerves, whose territory includes (B) the nailbeds and distal phalanges on the dorsal surfaces of the toes. Note that the side of the foot is supplied by the sural nerve, which is derived from the tibial nerve and the common peroneal nerve.



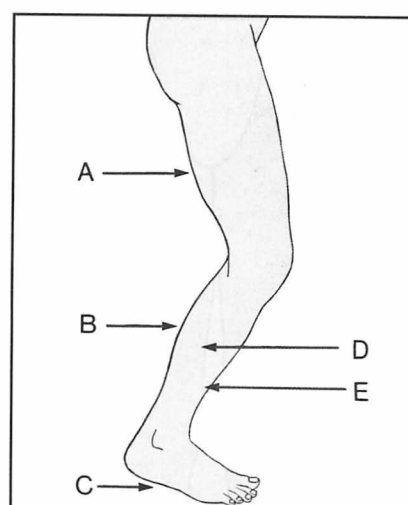
2.92. Tibial nerve (3): Common sites of involvement: (A) When passing under the soleal arch, e.g. from proximal tibial fractures. (B) From ischaemic lesions of the calf (e.g. from tight plasters and the posterior compartment syndromes), and from diabetic neuropathy. (C) When passing behind the medial malleolus (e.g. from lacerations and fractures). (D) When in the foot (e.g. in the tarsal tunnel syndrome).



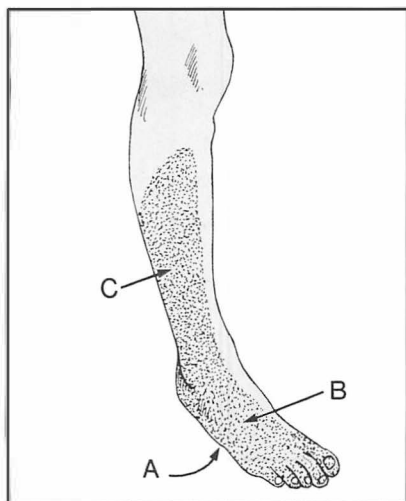
2.93. Tibial nerve (4): *Diagnosis:* Note any muscle wasting in the sole of the foot, clawing of the toes and trophic ulceration. (B) Test the power of toe flexion. (C) Look for sensory loss in the area supplied by the nerve.



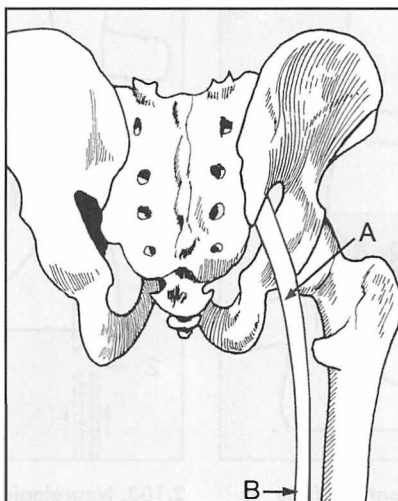
2.94. Tibial nerve (5): *Proximal lesions* of the nerve (i.e. as it lies in the popliteal fossa) are uncommon owing to the protection afforded by the surrounding soft tissues, and the space available to accommodate expanding lesions. The findings are essentially the same as in distal lesions, but with wasting and loss of power of plantar flexion owing to paralysis of gastrocnemius as well as the soleus.



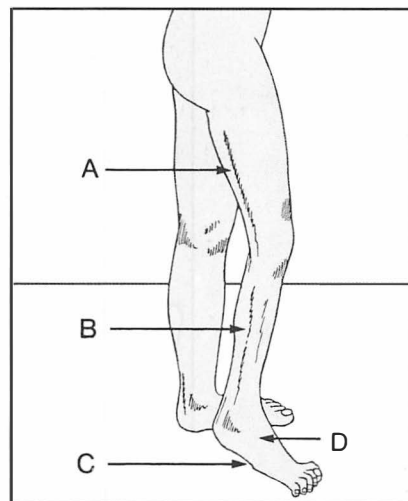
2.95. Sciatic nerve (1): **L4, 5, S1, 2, 3:** The losses include those seen in both tibial and common peroneal nerve palsies. *Motor loss:* (A) The hamstrings in the thigh. (B) The superficial and deep muscles of the calf (tibial nerve). (C) The muscles of the sole of the foot (medial and lateral plantar nerves). (D) The peronei (superficial peroneal). (E) The anterior compartment muscles (deep peroneal).



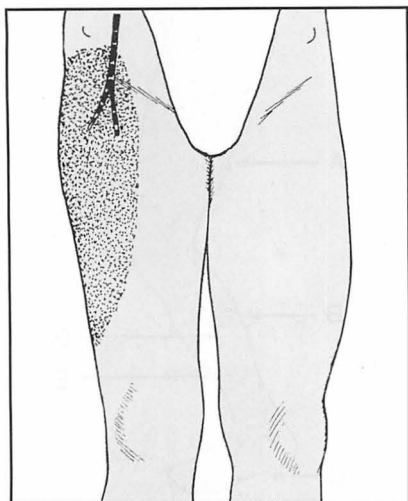
2.96. Sciatic nerve (2): *Sensory loss:* (A) The entire sole of the foot. (B) The dorsum of the foot. (C) The lateral aspect of the leg and lateral half of the calf. Note that the medial side of the calf and foot are spared. If the posterior cutaneous nerve of the thigh is involved, there is loss of sensation at the back of the thigh.



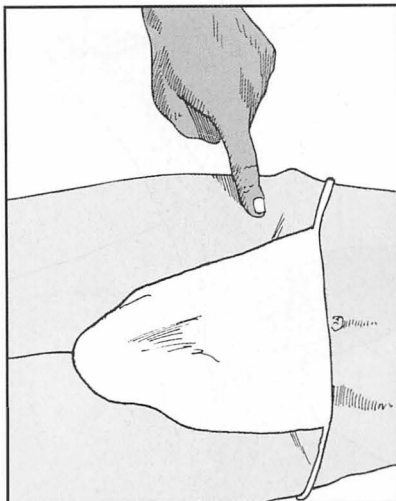
2.97. Sciatic nerve (3): *Sites involved:* (A) Behind the hip, e.g. after posterior dislocation of the hip, rarely after some pelvic fractures, and after hip surgery. (B) Following deep wounds in the back of the thigh, which are also uncommon. Do not confuse a sciatic palsy with root involvement in intervertebral disc prolapse.



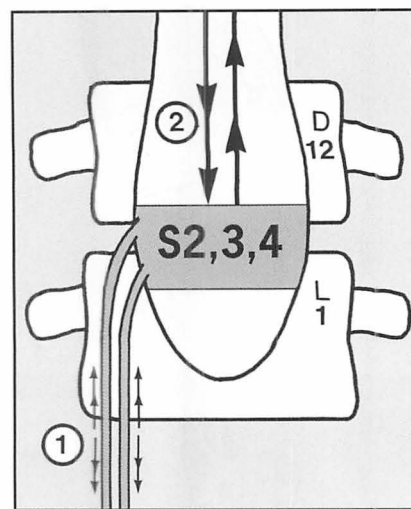
2.98. Sciatic nerve (4): *Diagnosis:* Note extensive wasting in (A) the thigh, (B) the calf, and of the peronei, and (C) the sole of the foot. Note (D), a drop foot. Observe any trophic ulceration. Note loss of power in the hamstrings and in all three compartments below the knee, an absent ankle jerk, and extensive sensory loss.



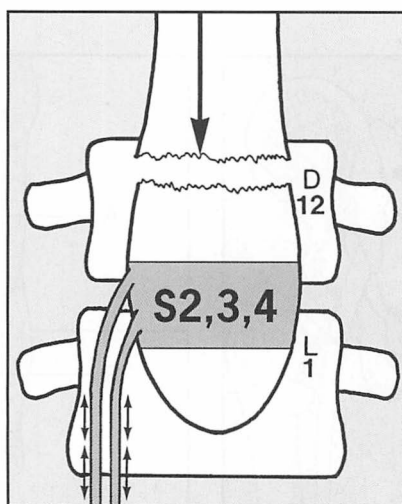
2.99. Lateral cutaneous nerve of thigh (1) (L2, 3): The nerve pierces or passes under the lateral portion of the inguinal ligament and supplies the lateral aspect of the thigh. It may be compressed by the inguinal ligament, giving rise to pain and paraesthesiae in the leg (meralgia paraesthetica). Note, however, that symptoms with the same distribution may occur secondary to spinal stenosis.



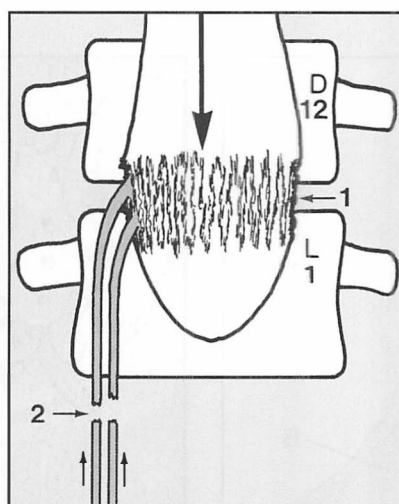
2.100. Lateral cutaneous nerve of thigh (2): *Test:* Pressure over the nerve may give rise to paraesthesia in the thigh. Test for sensory impairment in the area supplied by the nerve.



2.101. Neurological control of the bladder: *Note:* (a) Autonomic fibres controlling the detrusor muscle of the bladder and the internal sphincter travel from cord segments S2, 3 and 4 to the bladder via the cauda equina (1). (b) Under normal circumstances bladder sensation and voluntary emptying are mediated through pathways stretching between the brain and the sacral centres (2).



2.102. Neurological control of the bladder ctd: (c) If the cord is transected above S2 (e.g. by a thoracic spine fracture) voluntary control is lost, but the potential for coordinated contraction of the bladder wall, relaxation of the sphincter and complete emptying remains. (Normally 200–400 mL of urine are passed every 2–4 hours, the reflex activity being triggered by rising bladder pressure or skin stimulation.) (Automatic bladder or cord bladder.)



2.103. Neurological control of the bladder ctd: (d) Injuries that damage the sacral centres (1) or the cauda (2) prevent coordinated reflex control of bladder activity. Bladder emptying is always incomplete and irregular, and occurs only as a result of distension. Its efficiency varies with the patient's state of health, the presence of urinary infection, and muscle spasms. (Autonomous or isolated atonic bladder.) In summary, the effects on the bladder are dependent on the level of injury.

CHAPTER

3

The cervical spine

- Postural neck pain 34
- Acute neck pain in the young adult 34
- Cervical spondylosis (cervical osteoarthritis: Osteoarthritis of the cervical spine 34
- Thoracic outlet syndrome 35
- Whiplash and extension injuries of the neck 35
 - Barré-Lieou syndrome 36
- Rheumatoid arthritis in the cervical spine 37
- Klippel-Feil syndrome 37
- Neoplasms in the cervical region 37
- Osteitis of the cervical spine 37
- Inspection and palpation of cervical spine 38
- Examination of cervical spine movements 39
- Diagnosis of thoracic outlet syndrome 40-41
- Diagnosis of cord compression and cervical myelopathy 43-44
- Examination of radiographs 42-45
- Radiographs of cervical pathology 45-47

POSTURAL NECK PAIN

In this common condition, pain in the neck and shoulders occurs in association with some abnormality of neck posture. It is commonest in females under the age of 40, many of whom have sedentary jobs (such as computer operators) which entail the head being maintained for long periods in a position that may be short of ideal. In some cases there may be a history of minor trauma which exacerbates or precipitates the complaint. Clinically the head and neck may be held in a somewhat protracted position, with some loss of the normal cervical curvature, but there is usually a full range of neck movements with normal radiographs. Analgesics and physiotherapy are usually helpful in the acute case, but in the long term change of work practices and in the patient's working environment are likely to be of the greatest benefit.

ACUTE NECK PAIN IN THE YOUNG ADULT

In the 20–35-year age group, and often before there is any radiological evidence of arthritic change in the spine, a sudden movement of the neck may produce severe neck and arm pain accompanied by striking protective muscle spasm and limitation of cervical movements. In some cases these symptoms are produced by an acute disc prolapse similar to those occurring more familiarly in the lumbar region. In others, with identical symptoms, investigations including MRI scans may be quite negative; some disturbance of the facet joints or related structures is often thought responsible. Most cases respond to a period of rest in a cervical collar, or physiotherapy in the form of traction. In a few resistant cases gentle manipulation of the cervical spine may be helpful.

CERVICAL SPONDYLOSIS (CERVICAL OSTEOARTHRITIS: OSTEOARTHRITIS OF THE CERVICAL SPINE)

Cervical spondylosis is easily the most common condition affecting the neck. Degenerative changes appear early in life in the cervical spine, often during the third decade. The disc space between the fifth and sixth cervical vertebrae is most frequently involved. The earliest changes are confined to the disc, but the facet joints and the uncovertebral joints (joints of Luschka) may soon become involved. There is inevitable restriction of movements at the affected level, but this is often impossible to detect clinically as it is masked by persisting mobility in the joints above and below. The condition may in fact never attract attention, but unfortunately in many cases symptoms do occur, sometimes being triggered by minor trauma. Pain may be felt centrally in the neck and may radiate to the occiput, giving rise to severe occipital headache which may be confused with migraine; pain may also radiate distally, often and inexplicably further than might be expected on anatomical grounds, to the region of the lower scapulae. Often there is pain at the side of the neck, quite sharply localized, or in the supraclavicular region. With nerve root involvement from arthritic changes in the facet or uncovertebral joints, there may be radiation of pain into the shoulders, arms and hands, with paraesthesia and, on rare occasions, demonstrable neurological involvement; this may include absent arm reflexes, muscle weakness, and sensory impairment.

In cervical spondylosis the cervical canal may be narrowed by osteophytic lipping of the facet or uncovertebral joints, by central disc herniations, by thickening of the ligamentum flavum, or even from local cervical vertebral subluxations associated with ligamentous laxity. Developmental narrowing of the canal may be an additional factor. The reduction in the size of the canal may lead to cord compression (*cervical spondylotic myelopathy*). The disturbance of cord function that results may cause neck pain, difficulty in walking and unsteadiness on the feet, numbness, paraesthesia, weakness, and loss of upper limb dexterity. There is often coexisting compression of cervical nerve roots, leading to radicular symptoms which may complicate the clinical picture. Bladder dysfunction may occur, but is not common, and extensor plantar responses may appear late. Severe progressive myelopathy from spinal stenosis often requires operative treatment by decompression and stabilization.

Vertebral artery involvement by osteophytic outgrowths or local spinal instability may cause drop attacks precipitated by extension of the neck. Osteophytes arising from the anterior vertebral margins may sometimes, because of their size, give rise to dysphagia.

The mainstay of treatment in spondylosis is the judicious use of a cervical collar and the prescription of analgesics. If root symptoms are prominent, intermittent or continuous, cervical traction is often employed. Manipulation of the cervical spine, especially in the younger age groups with no neurological involvement, is sometimes advocated. Severe, protracted symptoms may be investigated further by MRI scans, or myelography followed by CT scanning. If a positive lesion is demonstrated, exploration may be carried out; if not, a local cervical fusion may sometimes be advised.

THORACIC OUTLET SYNDROME

The lower trunk of the brachial plexus and the subclavian artery pass between the anterior and middle scalene muscles and over the first rib. Compression of these structures may result from a cervical rib, a definite but rare occurrence. Slightly more commonly, the same structures may be kinked by fibrous bands or abnormalities in the scalene attachments at the root of the neck, or by a Pancoast tumour. Paraesthesia in the hand is usually severe, and there may be hypothenar and, less commonly, thenar wasting. There is sometimes sympathetic disturbance, with increased sweating of the hand. The radial pulse may be absent, and other signs of vascular impairment may be present. Complete vascular occlusion, sometimes accompanied by thrombosis and emboli, may lead to gangrene of the fingertips. In some cases symptoms may be precipitated by loss of tone in the shoulder girdle, with drooping of the shoulders; in such cases, physiotherapy is often successful in restoring tone to the affected muscles and relieving symptoms. When vascular involvement predominates, arteriography and exploration may be required.

WHIPLASH AND EXTENSION INJURIES OF THE NECK

Whiplash injuries are now a common cause of persistent cervical symptoms. A true whiplash injury occurs classically when, as a result of a rear impact, a stationary or slowly moving vehicle strikes another vehicle or object in front. Because of the inertial mass of the head of the car occupant, there is rapid

extension of the cervical spine followed by flexion. In the partial whiplash injury the main element is extension of the neck; this also commonly occurs as a result of a rear impact, but in this case the vehicle in which the occupant is travelling comes to rest more gradually, without striking anything ahead. Unfortunately, the attractive nature of the term has led to its misuse, and some recommend that because of its present imprecision it should be avoided altogether. If, however, it is going to be used, then it should be reserved for soft tissue injuries of the neck where extension is the main element. In the majority of cases the radiographs show normal alignment of the cervical vertebrae, but occasionally small avulsion fractures of the anterior margins of the vertebral bodies give evidence of the forcible extension of the spine. In some cases there are minor fractures involving the uncovertebral joints. Where there are spondylotic changes that interfere with the dissipation of the forces involved (because of localized areas of rigidity in the spine), there may be avulsion of anterior osteophytes. The flexion element may sometimes produce wedge compression fractures of the vertebral bodies or avulsion fractures of the spinous processes. Nevertheless, the discovery of unequivocal pathology in the spine is uncommon, and it is now apparent that there is a significant non-organic element in many cases. Although malingering does occasionally occur, this is considered to be rare. It is thought that in many cases a significant component of late disability is psychological, even if this is not at a conscious level, and that psychological elements and sometimes illness-related behaviour are often established within 3 months of injury.

Symptoms of all degrees of severity may be encountered. There is always pain and stiffness in the neck, sometimes with neurological disturbance involving the upper, and occasionally the lower, limbs. Even minor symptoms may be most protracted, often lasting 18 months or longer. In some cases disability is permanent. Analgesics for short periods and an early return to work are generally advocated, and it is thought best to avoid the use of cervical collars.

Severe extension injuries may occur in falls (often downstairs), when the neck is forcibly extended as the head strikes the ground. There is often telltale bruising of the forehead. In a car accident an unbelted occupant may also suffer severe extension of the neck in the early phases of deceleration, when the forehead strikes the roof and ricochets backwards. In both sets of circumstances the head injury may attract prior attention, but the possibility of these injuries must not be overlooked. Cervical spondylosis again has a deleterious localizing effect on the forces involved, and the neurological disturbance may be profound. In some cases thrombosis extends from the area of local cord involvement, so that there may be a deteriorating and sometimes fatal neurological outcome.

BARRÉ-LIEOU SYNDROME

This may follow a whiplash incident. There is complaint of headache, vertigo, tinnitus, ocular problems and facial pain. It is thought that it may be due to a sympathetic nerve disturbance at the C3–4 level, and in 75% of the cases there is impairment of sensation in the C4 dermatome, with weakness of shoulder and scapular movements. Myelography may show nerve root sleeve disturbances. Good results have been claimed for anterior discectomy combined with local cervical fusion.

RHEUMATOID ARTHRITIS IN THE CERVICAL SPINE

Rheumatoid arthritis frequently involves the neck, often in a patchy fashion so that additional stresses are thrown on the remaining mobile elements. With the ligamentous stretching that often accompanies rheumatoid arthritis there may be progressive subluxation of the cervical spine, particularly at the atlantoaxial and midcervical levels. As this progresses, pain and stiffness in the neck become accompanied by root and cord symptoms. In the case of atlantoaxial subluxations there may be severe occipital headache. The gait tends to become ataxic and there is progressive paralysis, often with bladder involvement. These lesions are usually treated by local cervical fusion if the patient's general condition permits.

KLIPPEL-FEIL SYNDROME

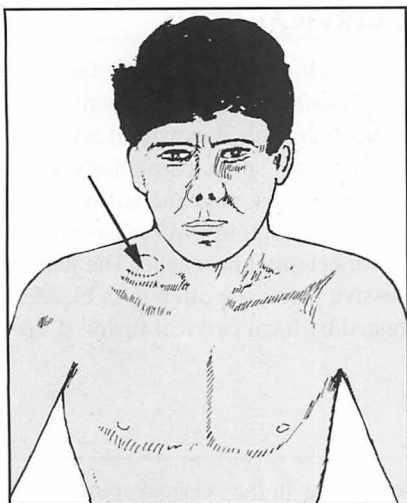
In this condition there is restriction of movements in the cervical spine owing to a congenital abnormality characterized by a failure of the cervical vertebrae to differentiate. One or more groups of vertebrae are fused together, and the condition may be associated with congenital elevation of the shoulder (Sprengel's shoulder). The condition gives rise to an increased susceptibility to injury and often neurological compromise.

NEOPLASMS IN THE CERVICAL REGION

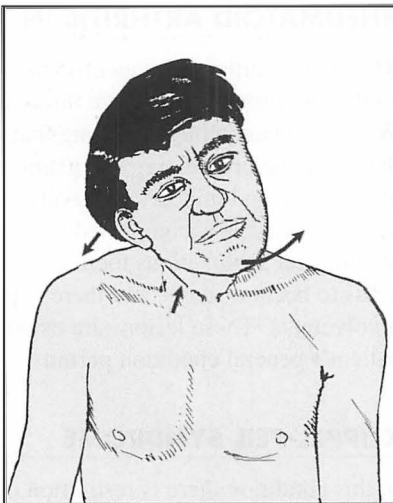
Tumours of the cervical spine are rare, secondary deposits being the most common. They may cause vertebral body erosion or collapse, affect issuing nerve roots, or give rise to cord involvement. Of the primary tumours in this region, sarcoma and multiple myeloma are the most common. Primary involvement of the cord may arise with meningiomas and intradural neurofibromata, which may also affect isolated nerve roots.

OSTEITIS OF THE CERVICAL SPINE

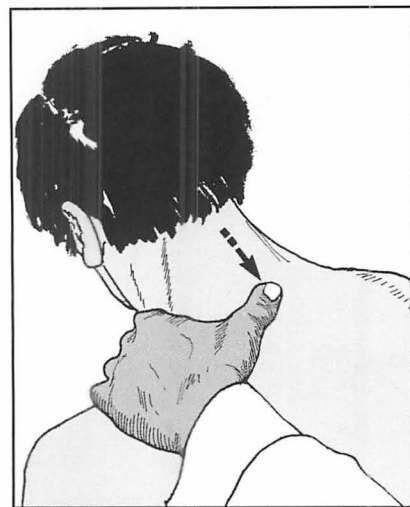
Osteitis affecting the cervical vertebrae is a rare occurrence in the UK. Tuberculosis, when it occurs, is seen most frequently in children, and may produce widespread bone destruction, vertebral collapse and cord involvement.



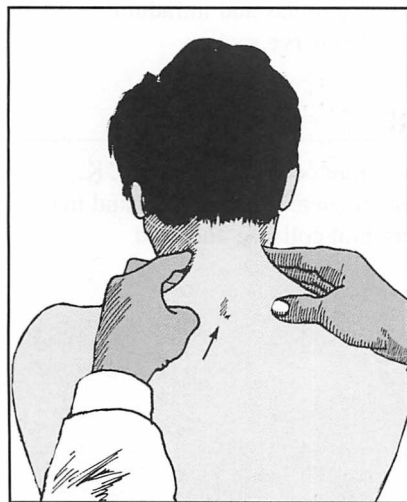
3.1. Inspection (1): Note any *asymmetry in the supraclavicular fossae*: this will require separate investigation (e.g. Pancoast tumour). (2) Note the presence of *torticollis*, where the head is pulled to the affected side and the chin often tilted to the opposite. In *congenital torticollis* there may be in the infant a small tumour in the sternomastoid muscle, and in the untreated case some facial asymmetry. **NB:** in about a third of cases the abnormal head posture is due to *ocular muscle weakness*, and a specialist ocular assessment is mandatory in *every* case.



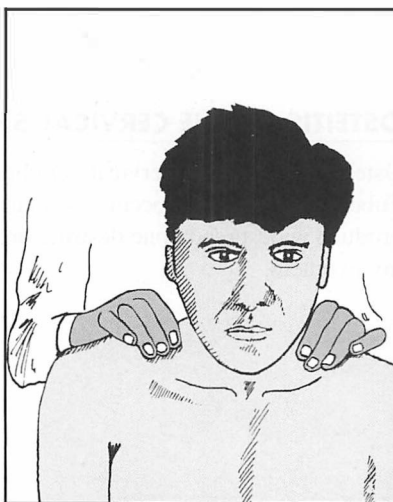
3.2. Inspection (2 ctd): Torticollis ctd: The head is tilted and rotated, the sternomastoid cord-like, and there is often facial asymmetry. In *acquired torticollis* protective muscle spasm may result from tonsillar or vertebral body infection. It is sometimes seen accompanying the Klippel-Feil syndrome. It may also be due to a vertebral malalignment (especially at the C1/C2 level), from trauma or upper respiratory infection. In advanced infections and tumours the head may be supported by the hands.



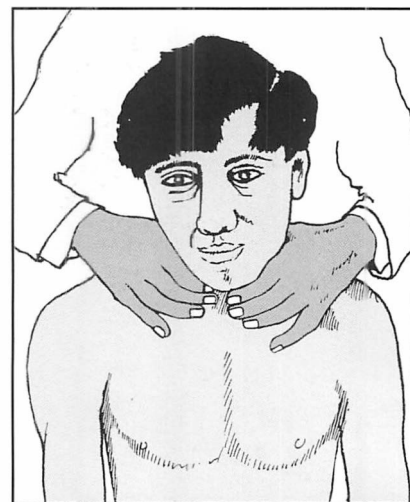
3.3. Palpation (1): Begin by looking for tenderness in the midline, working from the occiput distally. Tenderness localized to one space is common in cervical spondylosis, and much more rarely accompanies infections of the cervical spine.



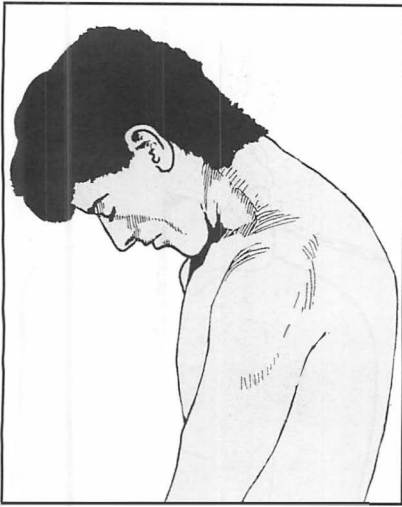
3.4. Palpation (2): Now palpate the lateral aspects of the vertebrae, looking for masses and tenderness. Note that the most prominent spinous process is that of T1, and *not* the vertebra prominens, C7.



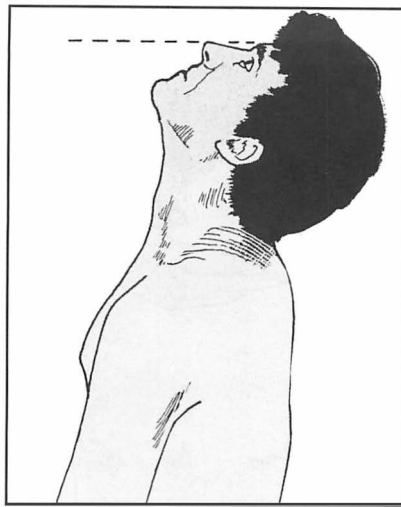
3.5. Palpation (3): Continue palpation into the supraclavicular fossae, looking particularly for the prominence of a cervical rib with local tenderness; look also for tumour masses and enlarged cervical lymph nodes.



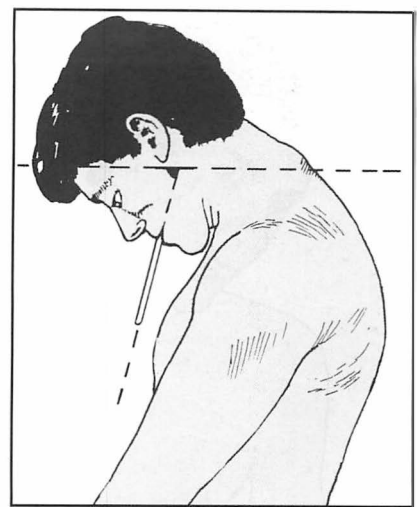
3.6. Palpation (4): Complete palpation of the neck by examining the anterior structures, including the thyroid gland.



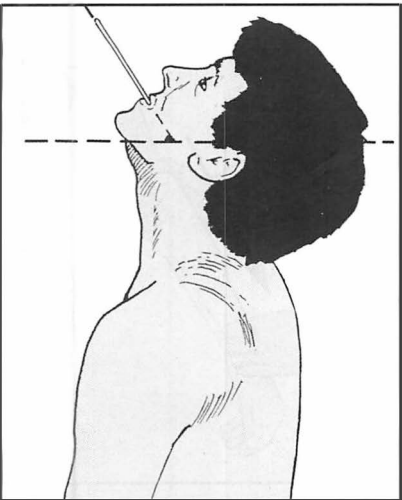
3.7. Movements (1): Flexion: Ask the patient to bend the head forward. Normally the chin can be brought down to touch the region of the sternoclavicular joints. The chin–chest distance may be measured for record purposes.



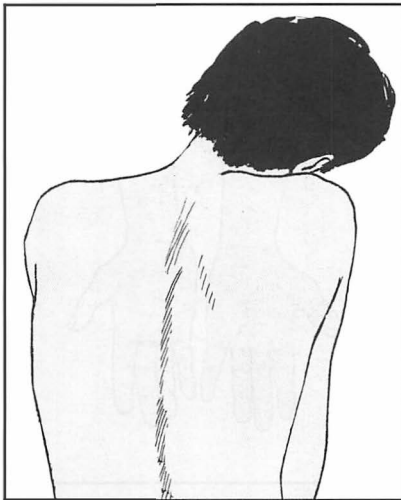
3.8. Movements (2): Extension: Ask the patient to tilt the head backward. The patient should be seated (preferably in a high-backed chair) and erect. The plane of the nose and forehead should normally be nearly horizontal, but guard against contributory thoracic and lumbar spine movements.



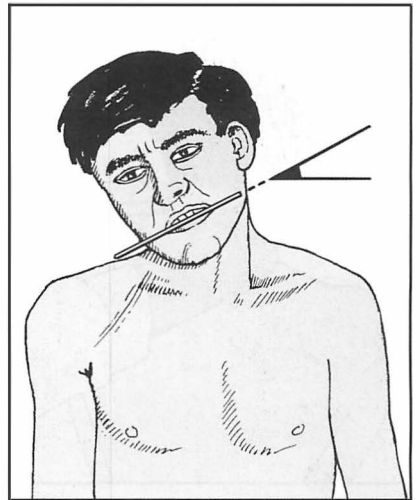
3.9. Movements (3): Recording motion in the cervical spine with any accuracy is difficult, but may be attempted using a spatula in the clenched teeth as a pointer. Stand back, and ask the patient to flex the head forward. Line up the legs of a goniometer with the spatula and the horizontal, respectively. Read off the included angle.
Normal range = 80°.



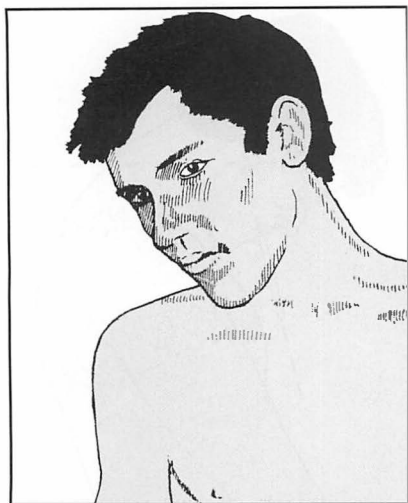
3.10. Movements (4): Now ask the patient to extend the head to measure the range of extension from the neutral position.
Normal range = 50°. The *total* range in the flexion and extension planes should be assessed, either by a single measurement or by the summation of flexion and extension.
Normal range = 130°. Of this total, about a fifth occurs in the atlantoaxial and atlanto-occipital joints.



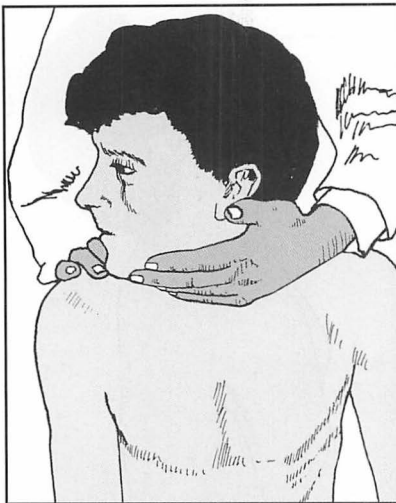
3.11. Movements (5): Lateral flexion: Ask the patient to tilt his head on to his right shoulder. In the normal case lateral flexion, with only slight shrugging of the shoulder, will allow the ear to touch the shoulder. Repeat on the other side and note any difference.



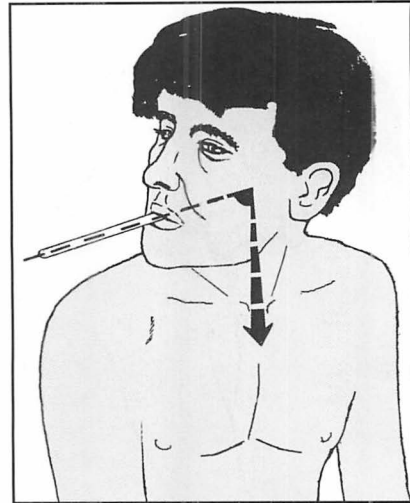
3.12. Movements (6): Lateral flexion: For greater accuracy, a spatula clenched in the teeth may again be used as a pointer. **Normal range = 45°.** About a fifth of this movement occurs at the atlantoaxial and atlanto-occipital joints. Loss is common in cervical spondylosis.



3.13. Movements (7): If lateral flexion cannot be carried out without forward flexion, this is indicative of pathology involving the atlantoaxial and atlanto-occipital joints.

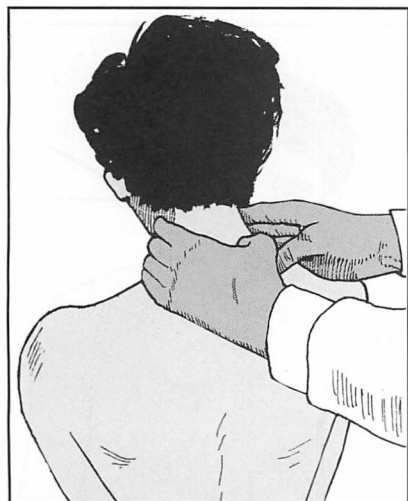


3.14. Movements (8): Rotation (1): Ask the patient to look over the shoulder. The movement may be encouraged with one hand and movement of the shoulder restrained with the other. Normally the chin falls just short of the plane of the shoulders.

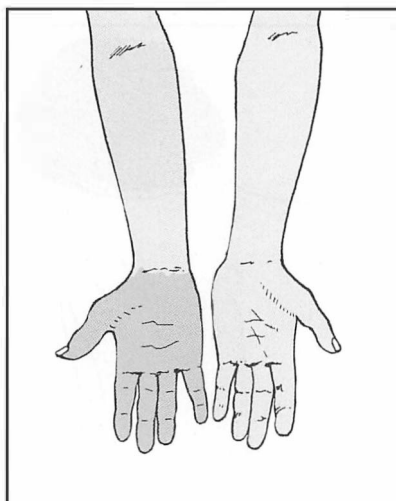


3.15. Movements (9): Rotation (2): Again a spatula may be used as a pointer for measurement.

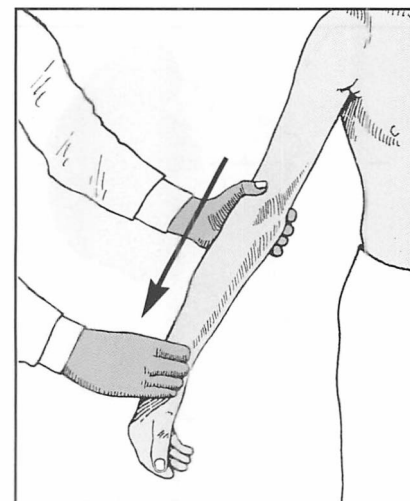
Normal range = 80° to either side. About a third of this occurs in the first two cervical joints. Rotation is usually restricted and painful in cervical spondylosis.



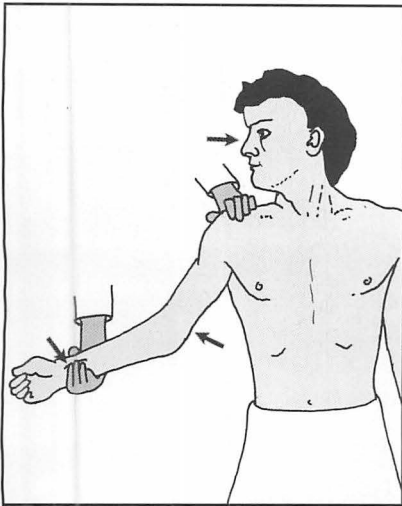
3.16. Crepitus: Spread the hands on each side of the neck and ask the patient to flex and extend the spine. Facet joint crepitus is normally detectable in this fashion, and is a common finding in cervical spondylosis; if in doubt, auscultate on either side of the spine while the patient flexes and extends.



3.17. Thoracic outlet syndrome (1): This may result from involvement of the space between scalenus anterior, scalenus medius and the first rib, so that the subclavian artery and/or the anterior primary rami of the lower cervical and first thoracic nerves may be affected. Begin by looking for evidence of ischaemia in one hand (e.g. coldness, discoloration, trophic changes). *Bilateral changes* are more in favour of Raynaud's disease.

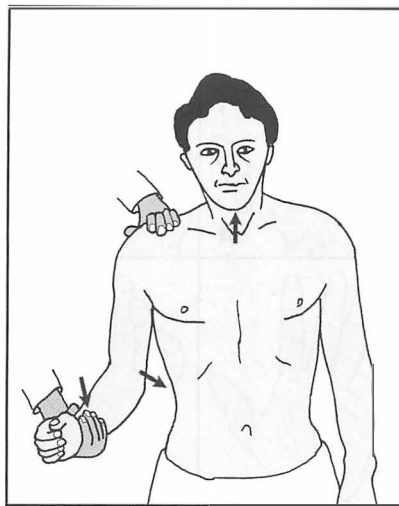


3.18. Thoracic outlet syndrome (2): Palpate the radial pulse and apply traction to the arm. Obliteration of the pulse is not diagnostic, but when the test reveals no change when repeated on the other side it is suggestive. Note that the syndrome occurs most commonly when the space is narrowed with fibrous bands or other pathology, such as a cervical rib or a Pancoast tumour.



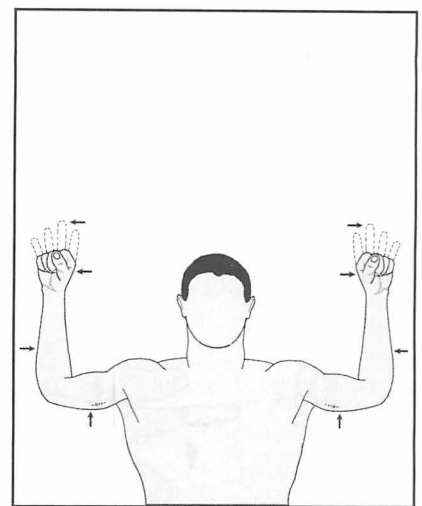
3.19. Thoracic outlet syndrome (3):

Adson's test: Abduct the shoulder to about 30° and locate the radial pulse (which is assumed to be present). Now ask the patient to turn his head fully to the affected side. He should then be asked to take and hold a deep breath.



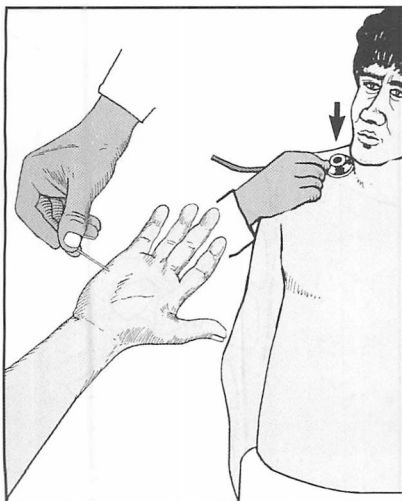
3.20. Thoracic outlet syndrome: Adson's test ctd:

The patient should then exhale, look forward, and lower the arm to the side. The pulse obtained in the first position should be compared with the second. Obliteration or reduction, especially if there is duplication of the patient's symptoms, is usually significant, but compare the sides. The test may also be tried with the head rotated to the opposite side.



3.21. Thoracic outlet syndrome (4): The Roos test:

The shoulders should be abducted and externally rotated, and the elbows flexed to a right-angle. (In this position the arms are in the aptly named 'surrender' position.) The hands should be repeatedly and slowly clenched for up to 3 minutes. Neurological and/or vascular symptoms, and early disappearance of the radial pulse on the affected side, are highly significant.

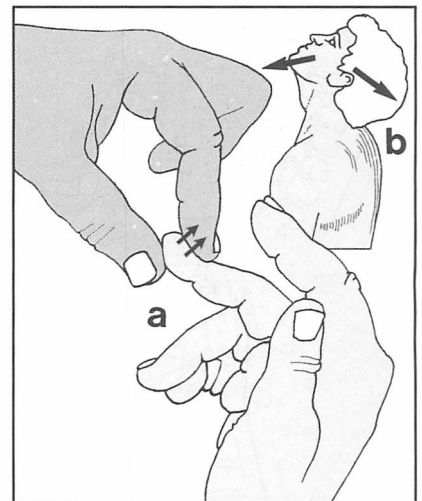


3.22. Thoracic outlet syndrome (5):

Look for neurological disturbance, paying particular attention to myotomes and dermatomes. Note any hypothenar or, much less commonly, thenar wasting. Note any disturbance of the pattern of sweating in the hand. (6): Auscultate over the subclavian artery. A murmur is suggestive of a mechanical obstruction, but repeat on the other side. (7): Examine radiographs for the presence of a cervical rib.

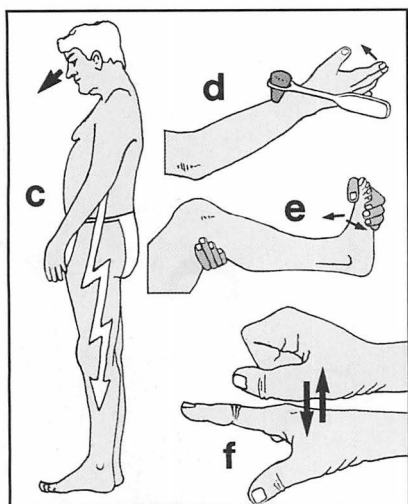
3.23. Cord compression and cervical myelopathy (1):

In this condition dysfunction in the cervical cord results from local compression. It may be seen where there is developmental narrowing of the spinal canal, or follow old ununited fractures of the dens, or spinal subluxations. It may occur in cervical spondylosis (from osteophytes protruding posteriorly from the vertebral bodies or from the uncovertebral joints) or from cervical disc prolapses. The main finding is of muscle weakness which is greater in the upper than in the lower limbs. *In the arms* lower motor signs at the level of the compression predominate (although there may be a mixed lesion). *In the legs* there is a lower motor lesion, which may include exaggerated lower limb reflexes, clonus, an extensor plantar response, loss of proprioception, and often a broad-based or ataxic gait. Extensor plantar responses are late in onset, and the sensory deficit is *not* dermatomal. The differential diagnosis includes multiple sclerosis (where there are usually abnormal cranial nerve findings), amyotrophic lateral sclerosis (where there is no alteration in sensation), syringomyelia, subacute combined degeneration (where the difference between the findings in the upper and lower limbs is less striking), spinal cord or cerebral tumour, and hydrocephalus.



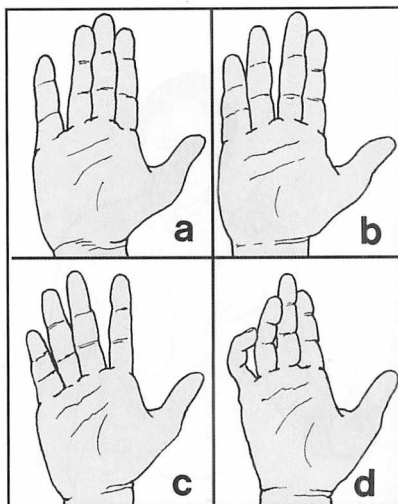
3.24. Cervical myelopathy (2):

(a) **Hoffmann's test:** Rapidly extend the distal phalanx of the middle finger by flicking its anterior surface (i.e. the pulp): the test is positive (indicating corticospinal dysfunction) if it results in flexion of the IP joints of the thumb and index. (b) **Dynamic Hoffmann test:** Repeat while the patient flexes and extends the neck, which often facilitates the response.



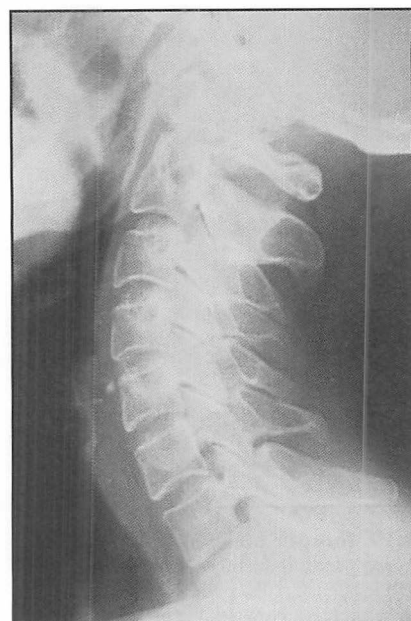
3.25. Cervical myelopathy (3): (c)

Lhermitte's test: Flexion or extension of the neck produces electric shock-like sensations, particularly in the legs. (d) *Inverted radial reflex:* This highly specific test is positive if the fingers flex when the radial reflex is elicited. (e) *Clonus.* (f) *Myelopathy hand* (indicative of pyramidal tract damage). This has two elements: (i) *Kinetic:* there is inability to rapidly flex and extend the fingers. Time the patient over 10 seconds. *The normal is in excess of 20 cycles.*

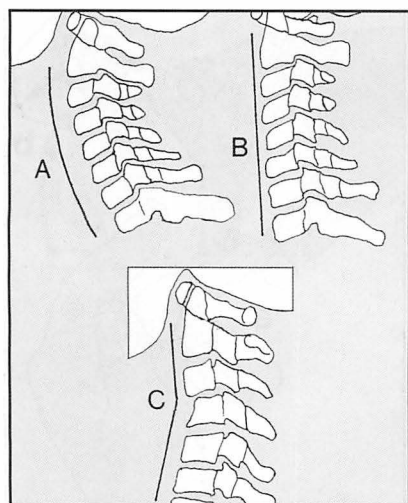


3.26. Cervical myelopathy (4):

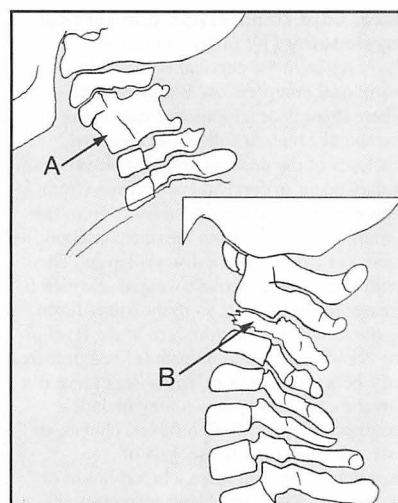
Myelopathy hand: (ii) *Postural:* There is deficient adduction, and often extension, of the ulnar fingers 1–3. In the mildest cases, when the fingers are extended the little finger lies in a slightly *abducted* position (a); if it can adduct, this position cannot be held for long. The *power of abduction* is normal, distinguishing it from ulnar nerve palsy. In more severe cases the little, ring (b), and sometimes the middle finger (c) may abduct, and/or the same fingers may *flex* (d) and lose their power of extension.



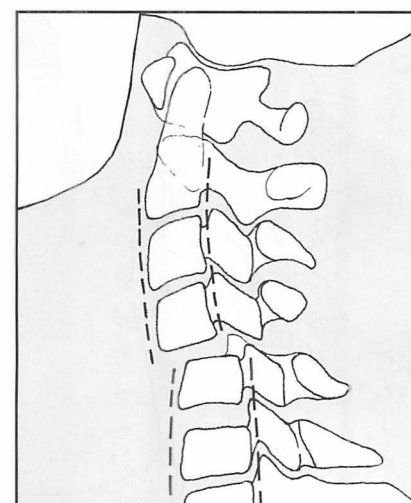
3.27. Radiographs (1): The standard projections are the lateral and anteroposterior views of the lower and upper cervical vertebrae. Illustrated: normal lateral projection, with a small non-significant opacity lying anterior to the body of C5. Note the well defined pharyngeal shadows.



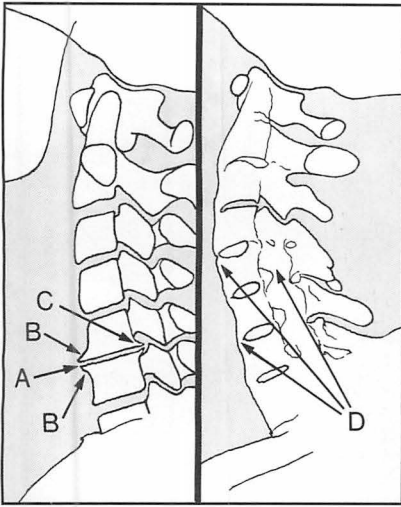
3.28. Radiographs (2): Begin your study of the lateral projection by noting the cervical curve, which is normally slightly convex anteriorly: (A) normal, regular curve; (B) loss of curvature: this can be a positional error, but in those with chronic neck pain (especially postural in origin) it may be due to protective muscle spasm. This is, however, a rather unreliable sign; (C) kinking (from a local lesion such as a subluxation, or from intense local muscle spasm).



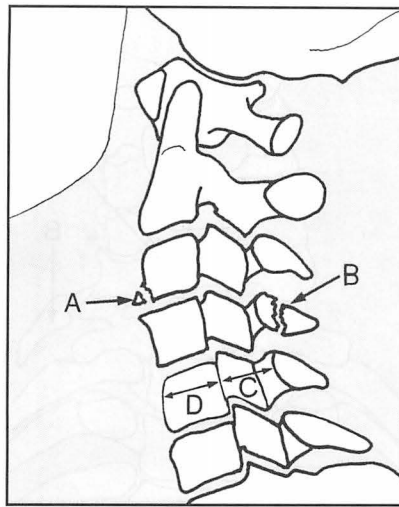
3.29. Radiographs (3): Now look at the general shape of the bodies of the vertebrae, comparing one with another. Note for example, (A) congenital vertebral fusion, such as occurs in the Klippel-Feil syndrome; (B) vertebral collapse, from tuberculosis, tumour or fracture.



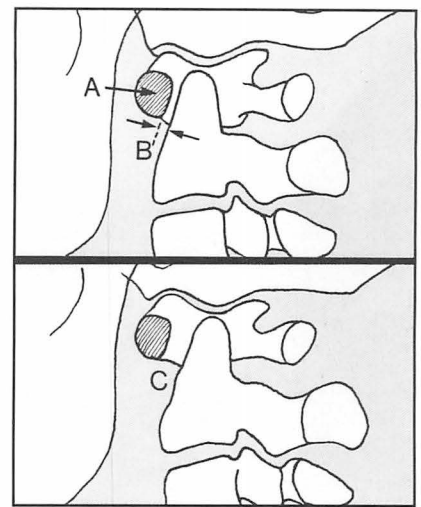
3.30. Radiographs (4): Note the relationship of each vertebra to the ones above and below. It is often helpful in doubtful cases to trace the *posterior* margins of the bodies. Displacement occurs in dislocations, and may be small when the facet joints on one side only are involved.



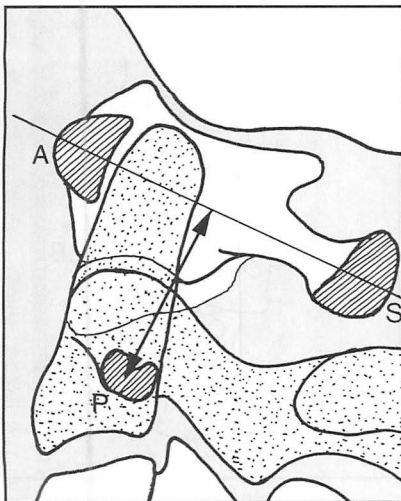
3.31. Radiographs (5): Look at the disc spaces and the related margins of the vertebrae. Note (A) disc space narrowing, (B) anterior lipping, (C) posterior lipping (all typical of cervical spondylosis). Note any evidence of vertebral fusions, (D), typical of ankylosing spondylitis.



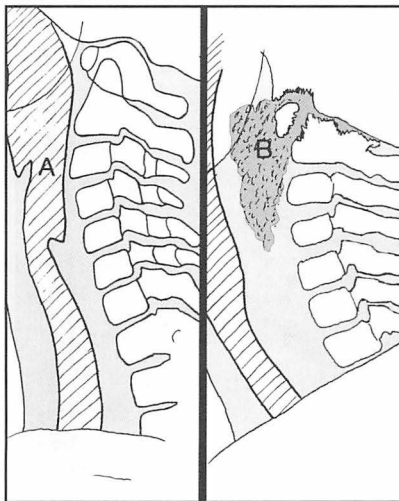
3.32. Radiographs (6): Note the presence (A) of an osteophyte or marginal fracture, suggestive of an extension injury of the neck; (B) fracture of a spinous process, suggestive of a flexion injury of the cervical spine. Syringomyelia (which can produce pain in the head, neck and limbs) may cause vertebral body erosions and dilatation of the canal. The diameter of the canal at C5 (C) should not exceed the vertebral body diameter (D) by more than 6 mm.



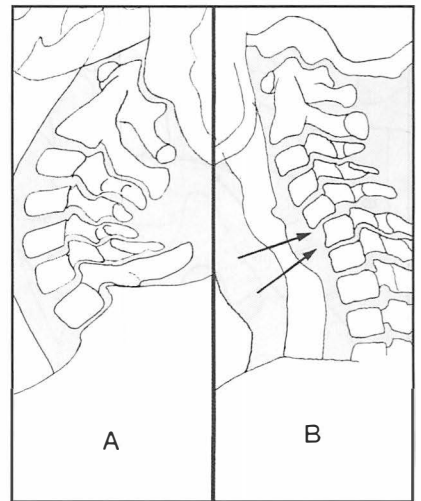
3.33. Radiographs (7): (A) Note that the anterior arch of the atlas lies in front of the lower cervical vertebrae. (B) The distance between the arch and the axis is normally 1–4 mm. A greater distance (C) suggests rupture or laxity of the transverse ligament (e.g. from trauma, rheumatoid arthritis or infection).



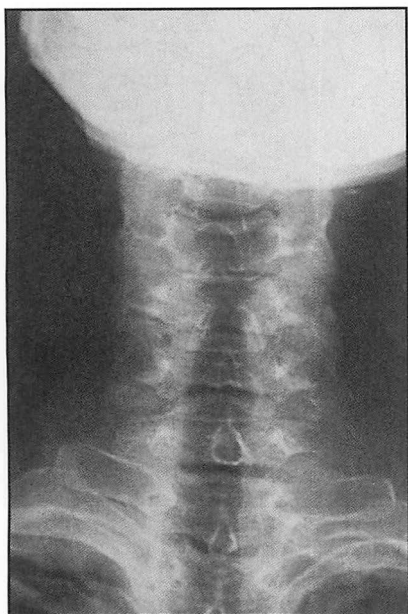
3.34. Radiographs (8): Proximal (cranial) migration of the odontoid process is also commonly seen in rheumatoid arthritis. In the adult this may be assessed by noting the distance between the pedicle (P) of C2 (shown hatched) and a line connecting the spinous process (S) with the arch (A) of C1. If this is less than 11.5 mm, proximal migration is considered to be present.



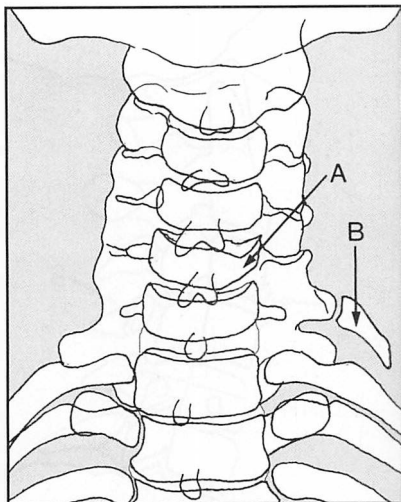
3.35. Radiographs (9): Note the pharyngeal shadow, which normally lies fairly close to the bodies of the vertebrae as at (A). Displacement suggests a retropharyngeal mass, e.g. (B) suboccipital tuberculous abscess. Other causes include haematoma and tumour.



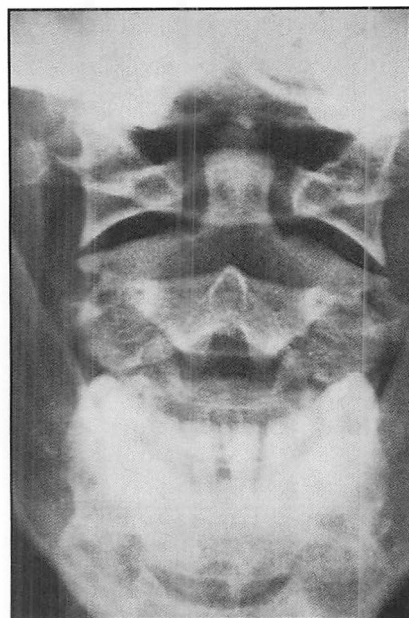
3.36. Radiographs (10): Where instability is suspected the lateral projection should be supervised with the neck (A) in extension, and (B) in flexion. Any latent instability should be discernible by comparing these views. If doubt remains, intensifier screening of movement may help.



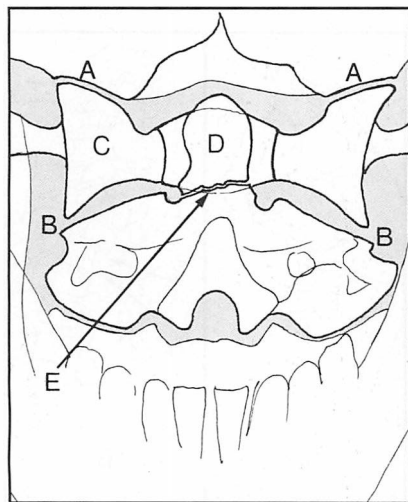
3.37. Radiographs (11): Normal anteroposterior view of the lower cervical vertebrae.



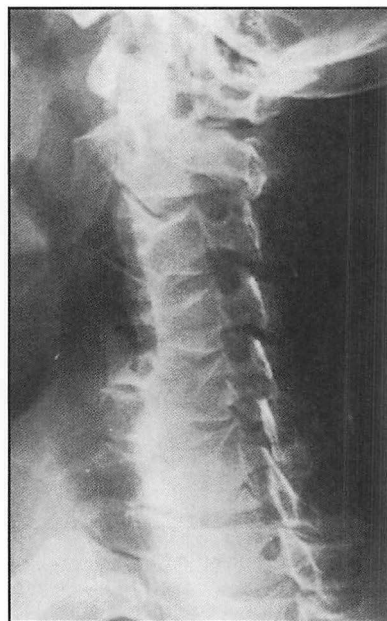3.38. Radiographs (12): In the anteroposterior view interpretation is difficult owing to the complexity of the superimposed structures. Note the shape of the vertebral bodies, observing (A) any lateral wedging, e.g. from fracture, tumour or infection. Note (B) the presence of any cervical rib.



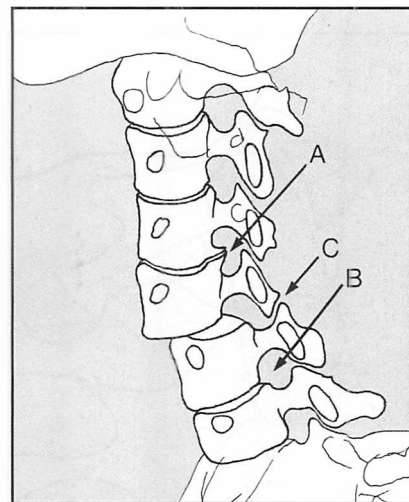
3.39. Radiographs (13): Normal anteroposterior (through-the-mouth) view of C1-3.



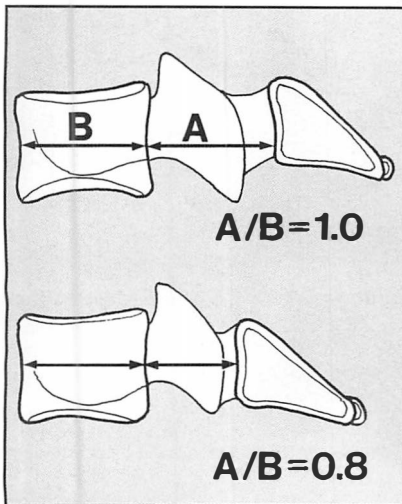
3.40. Radiographs (14): In the anteroposterior view of C1-3, note (A) the atlanto-occipital joints, (B) the atlantoaxial joints. (C) the lateral mass of the atlas. Note any lack of symmetry in the alignment of the odontoid process with the atlas, and look for any evidence of fracture (E). Occasionally congenital abnormalities of the odontoid process (such as hypoplasia, or failure of fusion between its ossification centre and the main mass of the axis) may cause difficulties in interpretation.



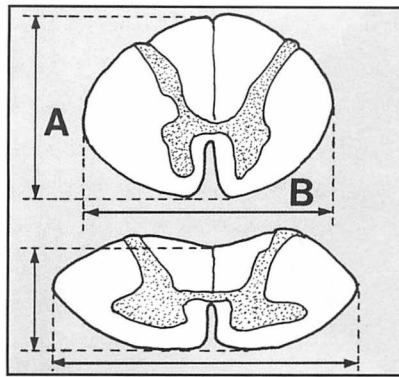
3.41. Radiographs (15): Normal oblique projection of the cervical spine (one of two).



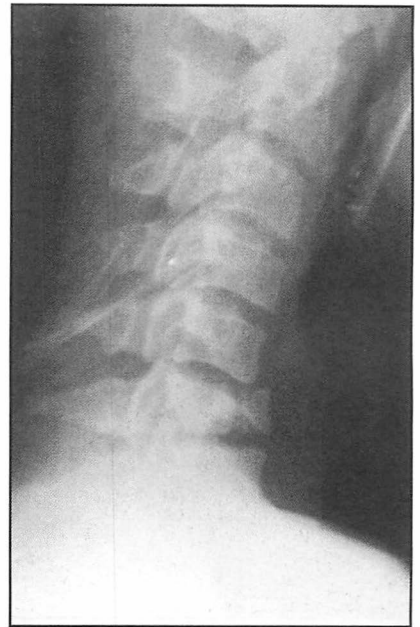3.42. Radiographs (16): Right and left oblique projections are invaluable in demonstrating (A) localized lipping in the uncovertebral joints (joints of Luschka) which may be encroaching on the neural foramina (B). They may also show overlapping (locked) facet joints (C) in cervical subluxations.



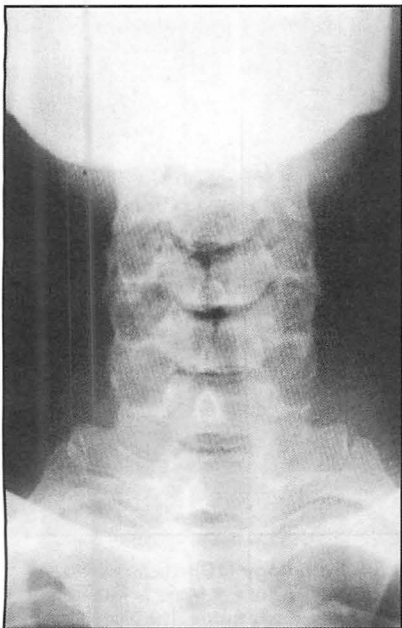
3.43. Radiographs (17): *Suspected cervical myelopathy (1):* (a) the Pavlov ratio. Normally, the depth (A) of the cervical canal, as seen in the lateral projection, is as great as that of its related vertebral body (B), giving a Pavlov ratio (A/B) of 1.0, and more than adequate room for the spinal cord. A Pavlov ratio of 0.8 or less indicates a developmentally narrow cervical canal, with risk of cord compression. If the ratio is reduced check the lumbar spine, as there may well be an associated lumbar spinal stenosis.



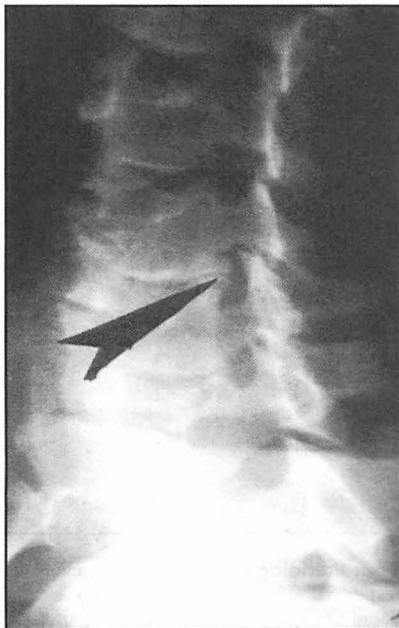3.44. Radiographs (18): *Suspected cervical myelopathy (2):* If there are axial MRI scans (or postmyelographic CT scans) which show the cord at the suspect levels, the presence and degree of cord compression may be assessed by working out the *cord compression ratio*. This is calculated by dividing the (sagittal) diameter (thickness) (A) of the cord by its width (B). (As this is a ratio, the reduction effects of the scans are immaterial.) Note also that the cord may be considerably distorted, so use its *minimal* sagittal diameter for the calculation. A value of 0.4 is indicative of a serious degree of compression, and if decompression surgery is planned it is best done before a figure as low as this is reached.



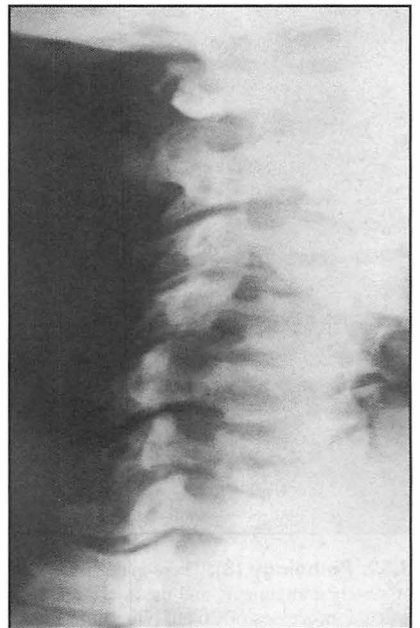
3.45. Cervical spine radiographs: examples of pathology (1): The cervical curvature is reversed: there is wedging of the body of C6.
Diagnosis: fracture of C6.



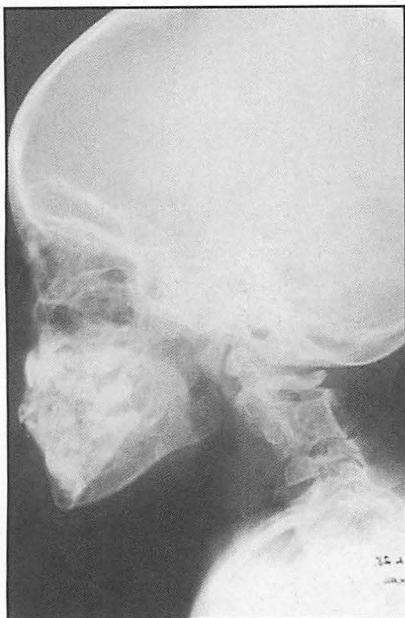
3.46. Pathology (2): There is a vertical fissure in the body of C5, and less obviously, in C6. **Diagnosis:** fractures of C5 and C6.



3.47. Pathology (3): This oblique projection shows osteophytes arising from the uncovertebral joint.
Diagnosis: cervical spondylosis, associated in this case with unilateral compression of the C6 nerve root.

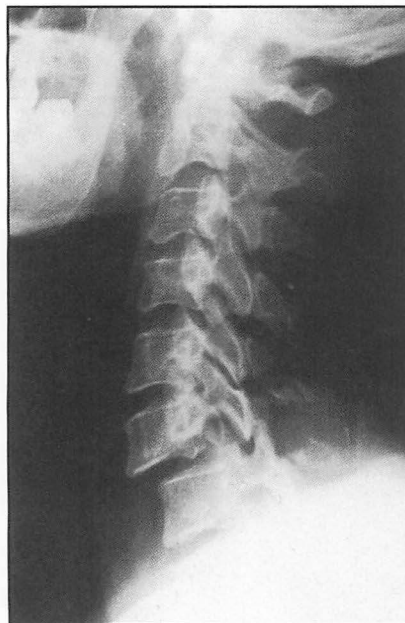

3.48. Pathology (4): The inferior articular process of C4 is displaced anteriorly over the upper articular process of C5. (The corresponding oblique projection of the other side is normal).
Diagnosis: unilateral facet joint dislocation, in this case with entrapment of C5.

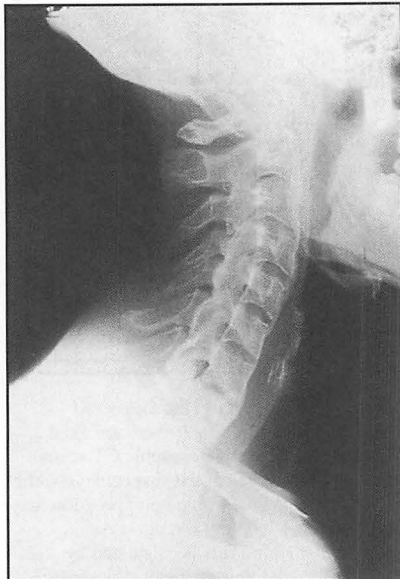

3.49. Pathology (5): C3, 4 and 5 are represented by a solid bony mass.

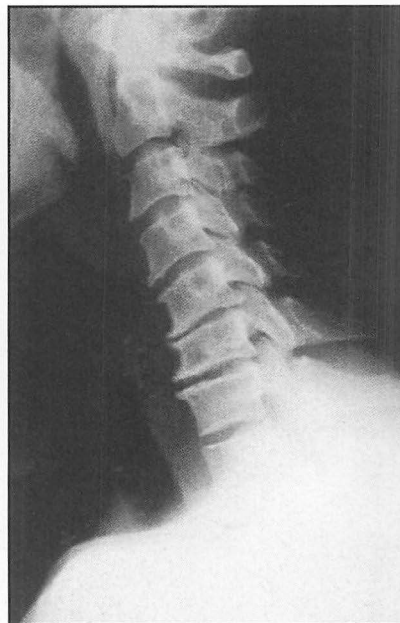Diagnosis: congenital fusion of cervical spine.



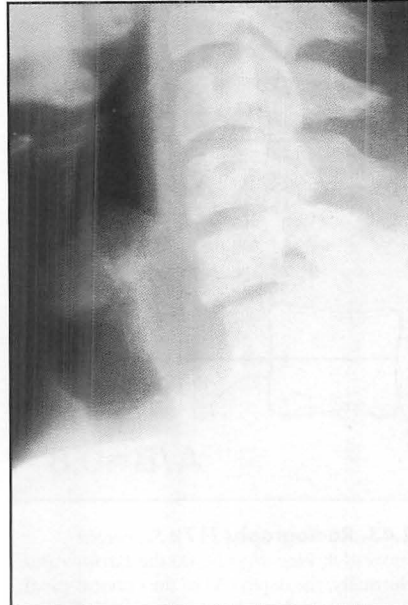3.52. Pathology (8): There is marked loss of vertebral alignment, and the inferior articular processes of C6 are lying in front of the superior articular processes of C7. The spinous processes of C5 and C6 are fractured. **Diagnosis:** dislocation of cervical spine (C6 on C7) with locked facets.



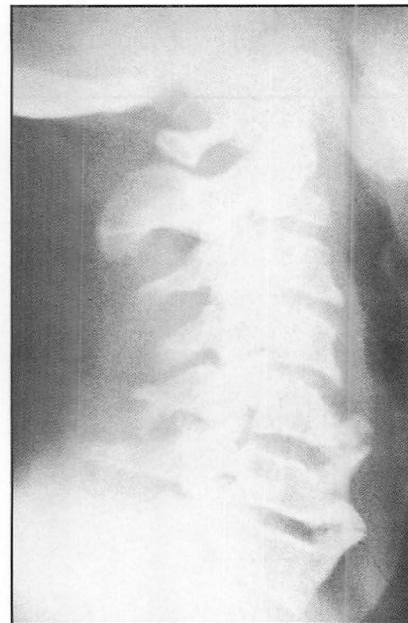3.50. Pathology (6): There is widespread fusion of the intervertebral facet joints, and the anterior longitudinal ligament is calcified. **Diagnosis:** ankylosing spondylitis.



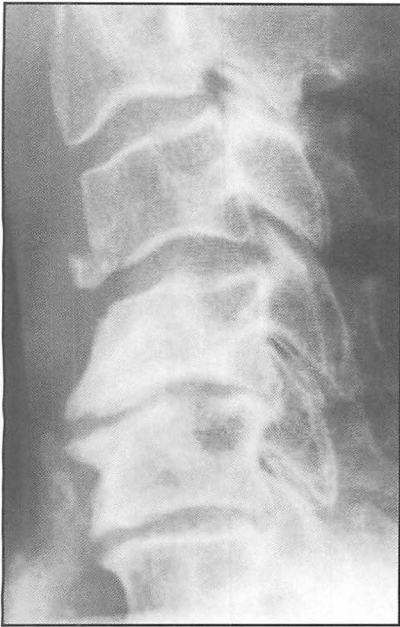
3.53. Pathology (9): There is narrowing of the C5-6 disc space and, to a lesser extent, that of C6-7. There is anterior lipping of C4, C5, C6, C7. There is posterior lipping of C5. **Diagnosis:** moderate degree of cervical spondylosis.



3.51. Pathology (7): There is slight forward shift of the body of C6 relative to that of C7. **Diagnosis:** unilateral facet dislocation of C6 on C7.

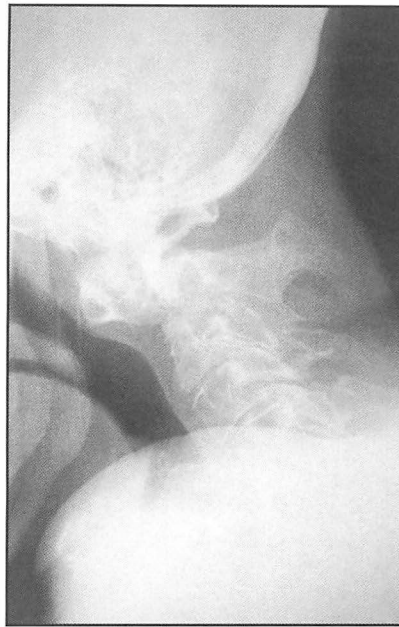

3.54. Pathology (10): There is gross anterior lipping of C5, C6 and C7, with near anterior interbody fusion. The pharyngeal shadow is distorted. **Diagnosis:** severe cervical spondylosis, associated in this case with dysphagia. Similar appearances are found in Forestier's disease, a condition in which there is excessive, widespread osteophyte formation and abnormal ligamentous calcification (especially of the anterior longitudinal ligament).



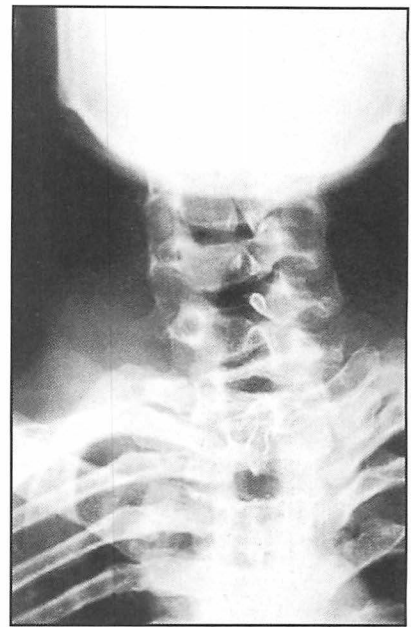3.55. Pathology (11): There is loss of the normal cervical curvature, narrowing of the C5–6 disc space and anterior lipping. There is an avulsion fracture of the anterior inferior margin of C4.

Diagnosis: extension injury of the spine with a marginal fracture and cervical muscle spasm in a patient susceptible to injury because of pre-existing cervical spondylosis.

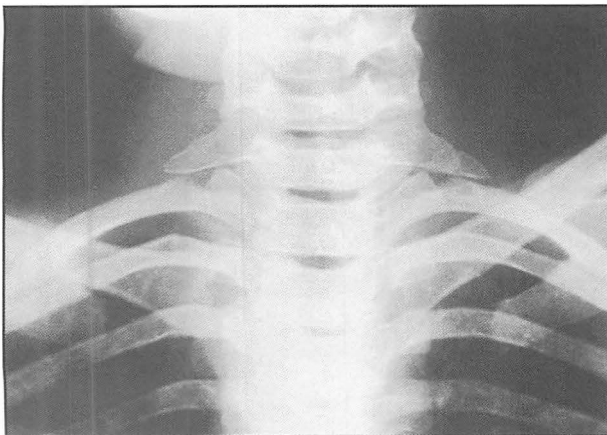


3.56. Pathology (12): The radiograph has been taken in flexion (one part of a flexion and extension pair) and shows an excessive gap between the anterior arch of the atlas and the odontoid process. There is generalized vertebral demineralization.

Diagnosis: rheumatoid arthritis with an atlantoaxial subluxation.

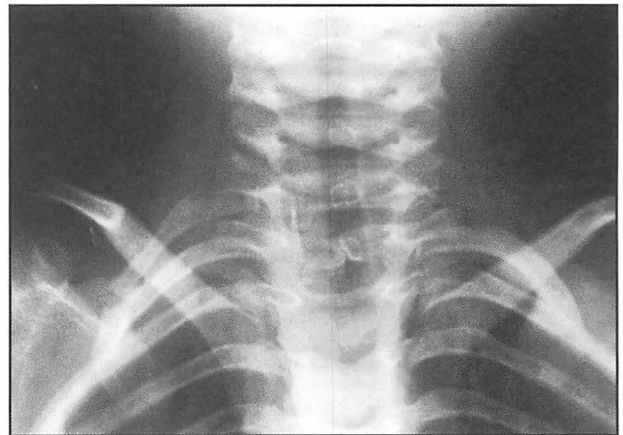


3.57. Pathology (13): There is deformity of the cervical spine, with the presence of only half of a vertebral body at the C6 level. **Diagnosis:** congenital deformity of the cervical spine (hemivertebra cervicalis).



3.58. Pathology (14): The transverse processes of the seventh cervical vertebra are enlarged on both sides.

Diagnosis: congenital deformity of the cervical spine related to cervical rib.




3.59. Pathology (12): There is an extra rib on one side. **Diagnosis:** unilateral cervical rib.

CHAPTER

4

The shoulder

- Anatomical features 50
- Common pathology around the shoulder 52
- Impingement syndrome 52
- Rotator cuff tears 52
- Rotator cuff arthropathy 53
- 'Frozen shoulder'/idiopathic adhesive capsulitis of the shoulder 53
- Calcifying supraspinatus tendinitis 53
- Osteoarthritis of the acromioclavicular joint 54
- Osteoarthritis of the glenohumeral joint 54
- Rheumatoid arthritis of the shoulder 54
- Instabilities of the shoulder joint 54
 - Recurrent dislocation of the shoulder 54
- Infections around the shoulder 55
- Miscellaneous conditions around the shoulder 55
- Assessment of combined shoulder and elbow function 57
- Inspection and palpation 58
- Examination of movements 59
- Rotator cuff examination 63
- Glenohumeral instability 63
- Biceps tendon 64
- Suprascapular and long thoracic nerves 65
- Radiographs 66–68
- Pathology 68–70
- Special investigations 70–71



ANATOMICAL FEATURES

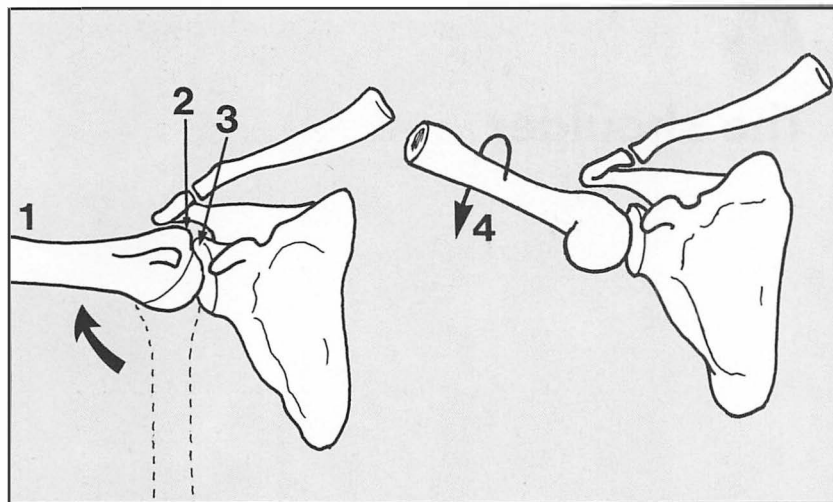


Fig. 4.A: The shoulder is complex, and it is important to note that it has two main components, namely the glenohumeral joint (between the head of the humerus and the glenoid) and the scapulothoracic joint (between the scapula and the chest wall). The latter is a physiological rather than an anatomical joint, as it has no synovial cavity.

The glenohumeral joint accounts for about half of shoulder abduction (1), and this comes to an end when the greater tuberosity (2) impinges on the glenoid rim (3); the range of glenohumeral movement (about 90°) can be increased if the arm is externally rotated (4), thereby delaying the impingement of the greater tuberosity. Note that shoulder rotation occurs mainly in the glenohumeral joint.

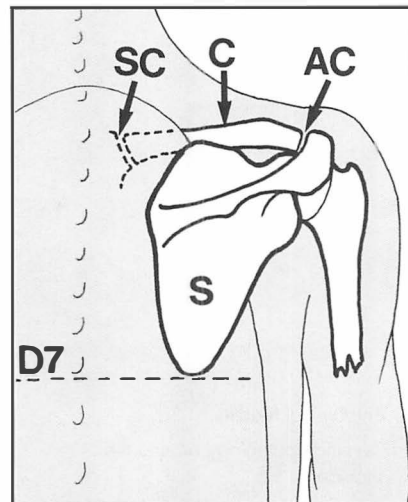


Fig. 4.B: In the scapulothoracic joint the scapula (S), moves over the rib cage and serratus anterior. It is supported by the clavicle (C) (which articulates with the scapula at the acromioclavicular joint (AC), and with the sternum at the sternoclavicular joint (SC)), and by trapezius, rhomboids, levator scapulae and serratus anterior. The inferior angle of the scapula normally lies at the level of D7.

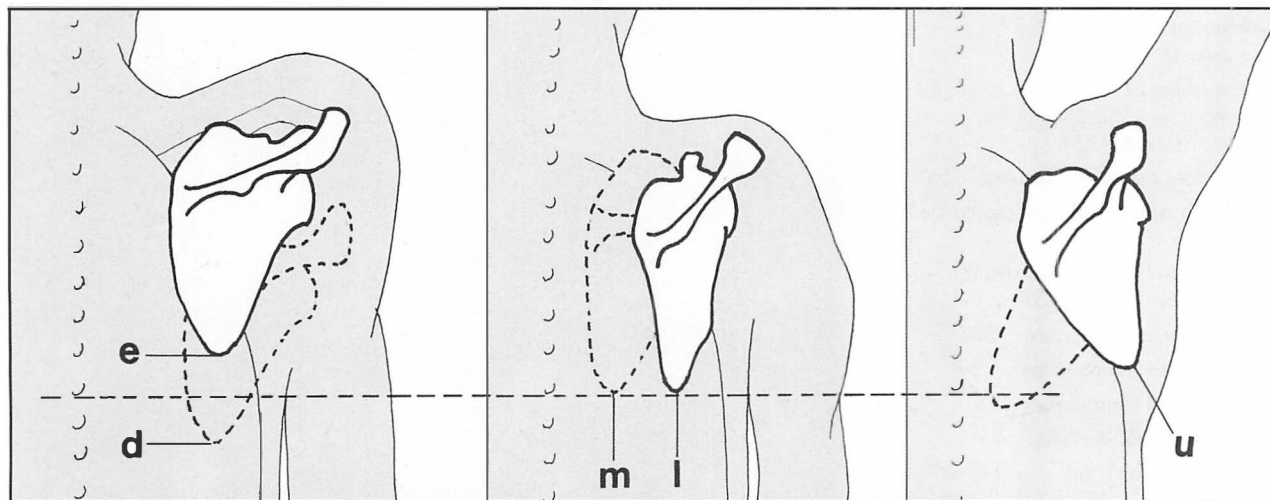


Fig. 4.C: The scapula, however, is normally a very mobile structure, varying in its position and permitting a wide range of scapulothoracic movements. The scapula may be elevated (e) or depressed (d), with a maximal total excursion in the order of 12 cm. (Note that elevation of the shoulder is a pure scapulothoracic movement, and must be distinguished from elevation of the arm. The latter term enjoys some popularity as a replacement for abduction or flexion, but because it is somewhat confusing it is probably best avoided.) The scapula may be rotated medially, or laterally and forwards (m, l) round the chest wall. It may also be tilted upwards (u) or downwards, with the glenoid angling in a corresponding fashion. When the glenoid is directed upwards, the angle between the vertebral border of the scapula and the vertical may reach 60°. Scapular movement is only possible if there is freedom at the acromioclavicular and sternoclavicular joints, and between the scapula and the chest wall.

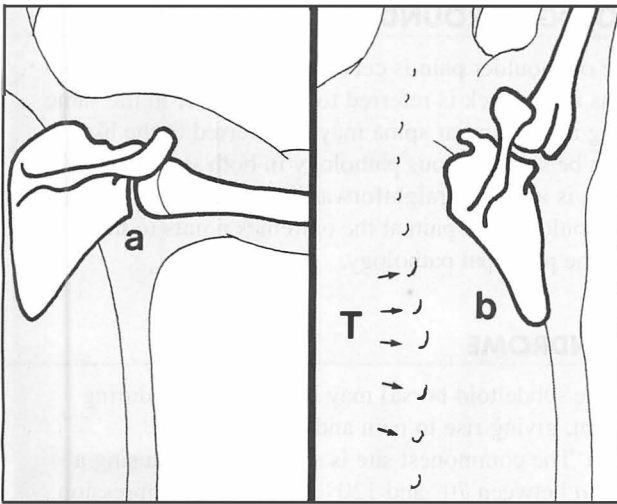


Fig. 4.D: Abduction of the shoulder (1): During the first 90° of abduction the glenohumeral joint is involved more than the scapula (a), whereas beyond 90° abduction is continued mainly by scapular movement (b). During the last 30° of abduction, when the glenohumeral joint is locked and the scapular attachments are tightening, movements of the spine may make a contribution: e.g. abduction of the shoulder may lead to some lateral flexion of the thoracic spine (T). The cervical spine may also laterally flex to the other side, to preserve the posture of the head. When both arms are abducted, neither the thoracic nor the cervical spine laterally flexes, but there may be an increase in lumbar lordosis.

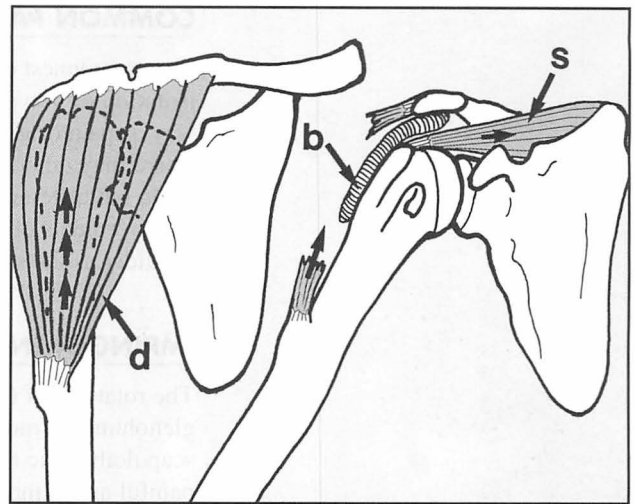


Fig. 4.E: Abduction (2): The deltoid muscle (d) arises from the lateral end of the clavicle, the acromion and the spine of the scapula; it is attached to the deltoid tubercle of the humerus. When the arm is at the side, the deltoid acting alone is incapable of initiating abduction: its contraction tends to raise the head of the humerus relative to the glenoid. On the other hand, when the arm is at the side the supraspinatus (s) is in its position of greatest mechanical advantage: with deltoid it forms a couple and initiates abduction (which is then taken over by deltoid). A tear of the supraspinatus (or relevant part of the shoulder cuff) will prevent the normal initiation of abduction, which will then only be possible by trick movements. (b=subdeltoid bursa)

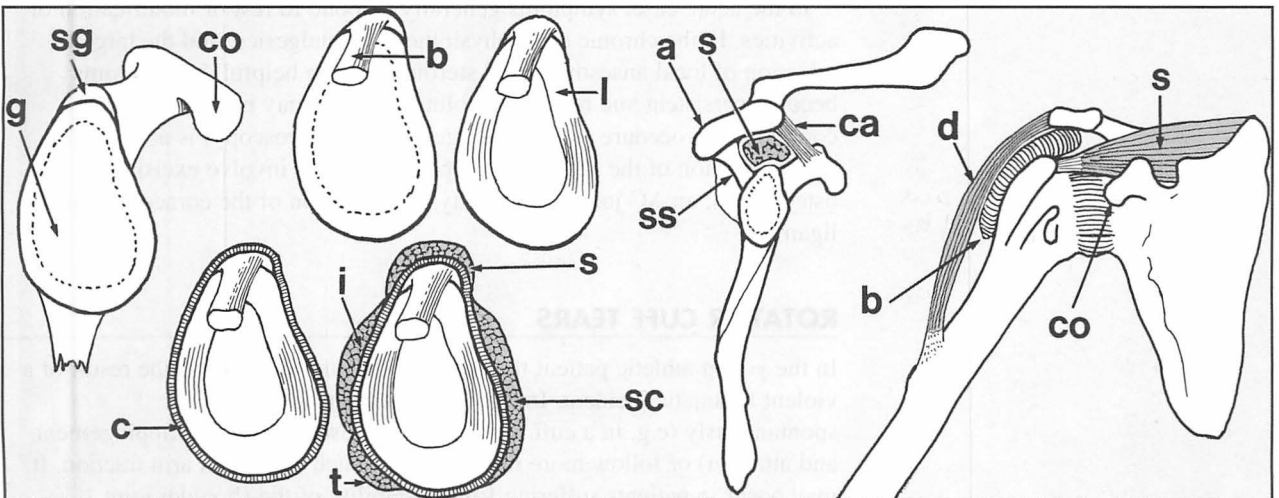


Fig. 4.F: Abduction (3): In spite of the tendency for glenohumeral and scapular movements to dominate specific portions of the abduction arc, it should be noted that there is no abrupt transition from one to the other, and indeed all the shoulder girdle joints make a contribution to nearly every movement that takes place in this region. The exceptions are shrugging movements, which do not involve the glenohumeral joint, and external rotation, which does not involve scapular movement.

The shoulder cuff: The glenoid (g) is widest inferiorly. Anteriorly lies the coracoid (co), and above is the supraglenoid tubercle (sg), from which the long head of biceps (b) arises. The fibrocartilaginous labrum (l) deepens the glenoid concavity and is attached to its peripheral margin, along with the joint capsule (c). The capsule is reinforced with the musculotendinous insertions of supraspinatus (s), subscapularis (sc), infraspinatus (i) and teres minor (t), which fuse with the capsule laterally, forming a complete tissue annulus (the shoulder cuff). The supraspinatus is its most important part. This in effect runs through a tunnel formed by the spine of the scapula (ss), the acromion (a), and the coracoacromial ligament (ca). It is partly separated from the acromion by the subdeltoid bursa (b).

COMMON PATHOLOGY AROUND THE SHOULDER

The commonest cause of shoulder pain is cervical spondylosis. Pain from irritation of nerve roots in the neck is referred to the shoulder in the same way as pain originating in the lumbar spine may be referred to the hip. There may on occasion be simultaneous pathology in both shoulder and neck, but differentiation is usually straightforward; in particular, restriction of movements of the shoulder with pain at the extremes points to the shoulder as the site of the principal pathology.

IMPINGEMENT SYNDROME

The rotator cuff (and the subdeltoid bursa) may be compressed during glenohumeral movement, giving rise to pain and disturbance of scapulothoracic rhythm. The commonest site is *subacromial*, causing a painful arc of movement between 70° and 120° abduction. Compression may also occur beneath the *acromioclavicular joint* itself, when there may be a painful arc of movement during the last 30° of abduction, or deep to the *coracoacromial ligament*. Symptoms may occur acutely (e.g. in young sportsmen, especially those engaging in activities involving throwing) or be chronic, particularly in the older patient. In this latter group there are usually degenerative changes in the acromioclavicular joint which lead to a reduction in size of the supraspinatus tunnel; this may cause attrition and rupture of the shoulder cuff.

There is a small group of cases where there is no narrowing of the tunnel, but where there is often thickening of the subdeltoid bursa or of the rotator cuff tendons. Note also that severe shoulder pain may occur in patients being dialysed, and is often due to subacromial impingement on amyloid deposits.

In the acute case, symptoms generally respond to rest or modification of activities. In the chronic case, physiotherapy, analgesics, and the targeted injection of local anaesthetic and steroids may be helpful. If symptoms become persistent and remain disabling, surgery may be required. The commonest procedure (by open surgery or by arthroscopy) is a decompression of the subacromial space; this may involve excision of *osteophytes*, an AC joint arthroplasty, and excision of the coracoacromial ligament.

*a small ant
growth of bone*

ROTATOR CUFF TEARS

In the young athletic patient the shoulder cuff may be torn as the result of a violent traumatic incident. In the older patient tears may occur spontaneously (e.g. in a cuff weakened as a result of chronic impingement and attrition) or follow more minor trauma, such as sudden arm traction. It may occur in patients suffering from instability of the shoulder joint.

Most commonly the supraspinatus region is involved, and the patient has difficulty in initiating abduction of the arm. In other cases the torn shoulder cuff impinges on the acromion during abduction, giving rise to a painful arc of movement. Although the range of passive movements is not initially disturbed, limitation of rotation may supervene, so that many of these cases, particularly in older patients, become ultimately indistinguishable from those suffering from so-called frozen shoulder. In the young patient, surgical repair of acute tears is generally advised. In the older patient the indications

for surgery are less clear, but operative repair, often combined with a decompression procedure, is becoming increasingly recommended. Arthroscopic repair may be performed, although it is technically demanding. In every case, prolonged postoperative physiotherapy is usually required.

ROTATOR CUFF ARTHROPATHY

If complete rotator cuff tears are neglected, the loss of soft tissue above the head of the humerus may lead to its proximal migration. Friction between the humeral head and the acromion may result in bony collapse and gross degenerative changes in the glenohumeral joint, which in severe cases may lead to joint replacement having to be considered.

'FROZEN SHOULDER'/IDIOPATHIC ADHESIVE CAPSULITIS OF THE SHOULDER

'Frozen shoulder' is a clinical syndrome characterized by gross restriction of shoulder movements and which is associated with contraction and thickening of the joint capsule. It is a condition that affects the middle-aged, in whose shoulder cuffs degenerative changes are occurring. Restriction of movements is often severe, with virtually no glenohumeral movements possible, but in the milder cases rotation, especially internal rotation, is primarily affected. Pain is often severe and may disturb sleep. There is frequently (but not always) a history of a minor trauma, which is usually presumed to produce some tearing of the degenerating shoulder cuff, thereby initiating the low-grade prolonged inflammatory changes and contraction of the shoulder cuff responsible for the symptoms. In a number of cases there are fibrotic changes in the coracohumeral ligament which resemble those found in Dupuytren's disease. In some cases the condition is initiated by a period of immobilization of the arm, not uncommonly as the result of the inadvised prolonged use of a sling after a Colles' fracture. It is commoner on the left side, and in an appreciable number of cases there is a preceding episode of a silent or overt cardiac infarct. It is commoner in diabetics. Radiographs of the shoulder are almost always normal. If untreated, pain subsides after many months, but there may be permanent restriction of movements. Generally those with the most severe initial symptoms have the poorest outcome in terms of final mobility and overall function.

The main aim of treatment is to improve the final range of movements in the shoulder, and graduated shoulder exercises are the mainstay of treatment. In some cases where pain is a particular problem, hydrocortisone injections into the shoulder cuff may be helpful. In a few cases, if there is no improvement with appropriate treatment for 4 months, manipulation of the shoulder under general anaesthesia or arthroscopic capsular release may be helpful in restoring movements in a stiff joint.

CALCIFYING SUPRASPINATUS TENDINITIS

Degenerative changes in the shoulder cuff may be accompanied by the local deposition of calcium salts. This process may continue without symptoms, although radiographic changes are obvious. Sometimes, however, the calcified material may give rise to inflammatory changes in the subdeltoid bursa. Sudden, severe incapacitating pain results; the shoulder becomes

acutely tender, and is often swollen and warm to the touch. It is important to differentiate the condition from an acute infection, or an acute attack of gout. Symptoms are relieved by the removal of the material by aspiration or curettage, but often local injections of hydrocortisone suffice. The joint is frequently so acutely tender that general anaesthesia is necessary for any attempted aspiration and injection of hydrocortisone. Good results have also been claimed following extracorporeal shock-wave therapy.

OSTEOARTHRITIS OF THE ACROMIOCLAVICULAR JOINT

Arthritic changes in the acromioclavicular joint may give rise to prolonged pain associated with shoulder movements (with or without shoulder cuff involvement and the production of an impingement syndrome). There is usually an obvious prominence of the joint from arthritic lipping, with well localized tenderness. Conservative treatment with local heat and exercises may be helpful, but occasionally, in severe persistent cases, acromionectomy may be considered.

OSTEOARTHRITIS OF THE GLENOHUMERAL JOINT

Osteoarthritis of the glenohumeral joint is rare, and when it occurs is most frequently secondary to avascular necrosis of the humeral head. This may be idiopathic in origin, or follow a fracture of the proximal humerus which interferes with the blood supply of its head. It may result from faulty decompression regimes in deep-sea divers, caisson workers and pilots, and it may follow radiotherapy (radionecrosis), particularly following treatment for carcinoma of the breast. If empirical treatment fails, joint replacement may have to be considered.

RHEUMATOID ARTHRITIS OF THE SHOULDER

Rheumatoid arthritis is more common than osteoarthritis in the shoulder, and the features are similar to those of the condition in other joints. It is necessary to localize the site of the main pathology so that treatment may be directed effectively, and diagnostic sequential injections (into the acromioclavicular joint, the shoulder cuff, and then the glenohumeral joint) may be helpful in this respect. Medical treatment and intra-articular injection therapy are tried first. In more advanced cases, where the symptoms are the result of impingement, decompression procedures may be highly effective. Where the glenohumeral joint is severely diseased, joint replacement will generally produce pain relief and improved function.

INSTABILITIES OF THE SHOULDER JOINT

RECURRENT DISLOCATION OF THE SHOULDER

The shoulder may be affected by anterior, posterior or inferior instability. When the shoulder is unstable in several planes, then multidirectional instability ('loose shoulder') is said to be present.

Anterior instability is the commonest, and in many cases this follows a frank dislocation of the shoulder. It occurs most frequently in the 20-40-year age group. There may be a history of repeated dislocations in which the

causal trauma has become progressively less severe (recurrent anterior dislocation of the shoulder). The shoulder is often symptom free between incidents, but there may be some pain and weakness. Surgical repair is generally advised if there have been four or more dislocations, but each case must be carefully assessed to exclude shoulder laxity in other planes: many case of failed reconstruction are due to an associated posterior instability.

Trauma to the shoulder may also result in posterior dislocation, which can proceed to recurrent posterior dislocation. Posterior dislocation of the shoulder is much less common than anterior dislocation and the diagnosis is sometimes overlooked, especially when only one radiographic projection is taken. Surgical reconstruction is sometimes required, but this may fail if concurrent anterior instability is not taken into account.

Anterior and multidirectional instabilities may occur without previous trauma, and never proceed to frank dislocations or obvious subluxations. The condition may be congenital in origin. The primary complaints are of pain and weakness in the shoulder, and the rapid onset of joint fatigue during activity. The arm may feel 'dead'. In the case of multidirectional instabilities muscle retraining is generally advocated, although surgical reconstruction is sometimes attempted.

Recurrent dislocation of the shoulder should be differentiated from habitual dislocation. In the latter the patient is often psychotic or suffering from a joint laxity syndrome. The shoulder repeatedly dislocates without much in the way of pain; the patient is often able to dislocate and reduce the shoulder voluntarily and with ease; and the radiological changes that are found in recurrent dislocation are not present in habitual dislocation. When habitual dislocation is found in children the prognosis is good, and surgery is never indicated. In the adult, surgery is usually best avoided (as the results are often poor), but good results are being claimed for biofeedback re-education of the shoulder muscles.

INFECTIONS AROUND THE SHOULDER

Staphylococcal osteitis of the proximal humerus is the commonest infection occurring near the shoulder in this country at present; nevertheless, it is comparatively uncommon.

Tuberculosis of the shoulder is now rare. In the moist form, commonest in the first two decades of life, the shoulder is swollen, there is abundant pus production, and sinuses may form; the progress is comparatively rapid and destructive. In the dry form, *caries sicca*, an older age group is affected and the progress is slow, with little destruction or pus formation. (However, it should be noted that it is now thought that many of the cases of *caries sicca* described in the past were in fact suffering from frozen shoulder.)

Gonococcal arthritis of the shoulder is uncommon, but when it occurs there is moderate swelling of the joint and great pain, which often seems out of keeping with the physical signs.

MISCELLANEOUS CONDITIONS AROUND THE SHOULDER

Acromioclavicular dislocation The acromioclavicular joint may be disturbed as a result of a fall on the outstretched hand or on the point of the shoulder. If care is taken during examination, a lesion of this joint will not be

confused with one of the glenohumeral joint. In major injuries the conoid and trapezoid ligaments are torn and the clavicle is very unstable: surgical fixation of the clavicle to the coracoid (by a screw or a sling procedure) is sometimes advised. In less severe cases the acromioclavicular capsular ligaments only are torn. Although the outer end of the clavicle becomes prominent, it follows the movement of the acromion and conservative treatment with a sling for several weeks is all that is required. These injuries are frequently missed, as they often do not show in the routine recumbent radiographs of the shoulder.

Clavicle Primary pathology in the clavicle is uncommon, but a cause of confusion is pathological fracture due to radionecrosis years after treatment for breast carcinoma. The fracture may be preceded by pain for many months, and be mistaken for metastatic spread.

Scapula

Snapping scapula A patient may complain of a grinding sensation arising from beneath the scapula. This is often due to a rib prominence, but in some cases it may be caused by an exostosis arising from the deep surface of the scapula itself. When symptoms are persistent, excision of such an exostosis may give relief.

High scapula There are several related congenital malformations affecting the neck and shoulder girdle. In the most minor cases one scapula may be a little smaller than the other and be more highly placed; in more severe cases one or both shoulders are highly situated, the scapulae are small, and there may be webs of skin running from the shoulder to the neck (Sprengel shoulder). In the Klippel–Feil syndrome the neck is short and there are multiple anomalies of the cervical vertebrae, which may include vertebral body fusions and spina bifida. Apart from highly placed scapulae, other congenital lesions may be found in association with the Klippel–Feil syndrome; these include diastatomyelia resulting in tethering of the spinal cord and neurological involvement; lumbosacral lipomata; and renal abnormalities.

Winged scapula The patient complains of prominence of the scapula, its vertebral border being raised from normal contact with the chest wall. This is due to weakness of the serratus anterior. The cause may be primarily muscular (as in progressive muscular dystrophy) or follow traumatic paralysis of the long thoracic nerve. Active treatment is seldom necessary.

Ruptured biceps tendon Rupture of the long head of biceps may occur spontaneously or as a result of a sudden muscular effort, usually in an elderly or middle-aged person in whom degenerative tendon changes are present. No treatment is usually required. In some cases the tendon may cause a detachment of its insertion into the superior part of the glenoid (SLAP lesion); in the young athletic patient surgical reattachment may be advocated.

Biceps tendon instability and tendinitis Anchorage of the biceps tendon in its groove may become faulty, so that certain movements of the shoulder may cause it to snap in and out of its normal location. This often occurs in association with a shoulder cuff tear, and isolated tendon lesions may be difficult to differentiate from pure cuff tears. The tendon may become inflamed (biceps tendinitis). No specific treatment is usually required.

Sternoclavicular joint Dislocation of the sternoclavicular joint is comparatively uncommon; there is always a history of trauma, and the joint asymmetry is obvious if looked for. In some cases, especially where the medial end of the clavicle comes to lie behind the sternum, there may be an associated thoracic outlet syndrome.

Good radiographs are often hard to obtain and their interpretation is difficult. The diagnosis should be made primarily on clinical grounds. Symptoms of pain on movement normally settle spontaneously, and only rarely is surgical repair required.

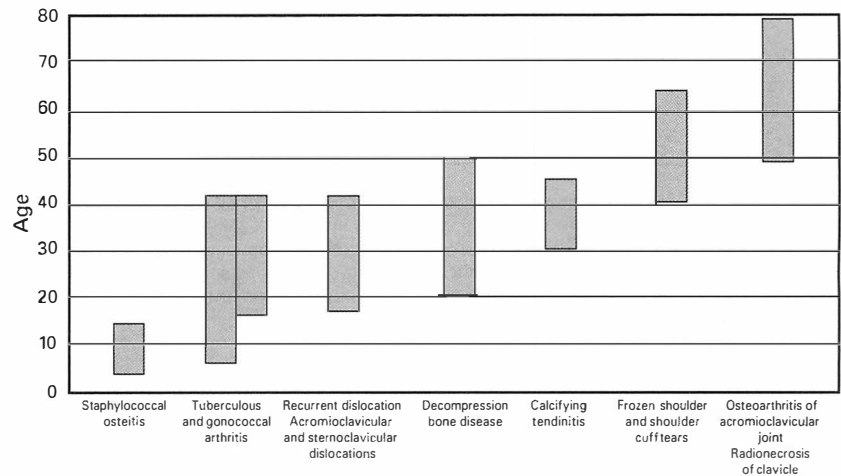


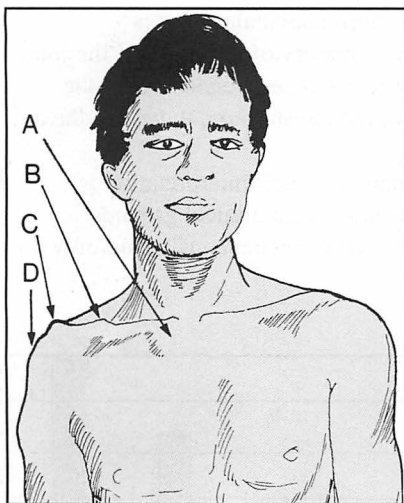
Table 4.1 Age distribution of common shoulder pathology

ASSESSMENT OF COMBINED SHOULDER AND ELBOW FUNCTION

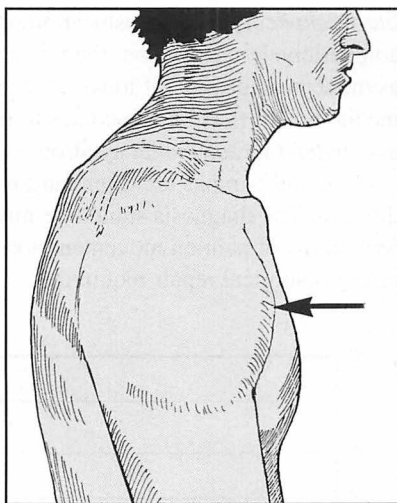
It should be noted that overall function in the arm is disproportionately affected when the elbow is also involved. The American Shoulder and Elbow Surgeons have devised a scoring system which may be used to gauge overall function in both joints. Each activity is evaluated on a scale of 0–4 and the results may be summed (0 = unable; 1 = only with assistance; 2 = with difficulty; 3 = mild compromise; 4 = normal).

The tests include:

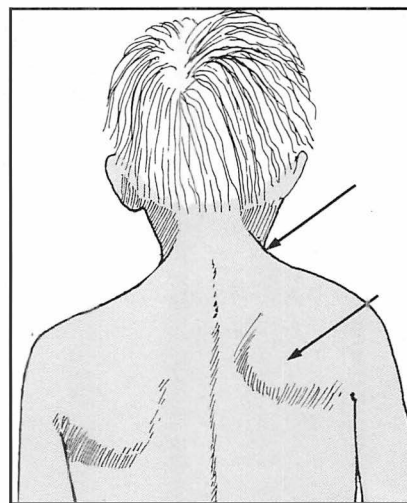
1. Putting the hand in a back pocket
2. Washing the opposite axilla
3. Combing the hair
4. Carrying a 10 lb weight (4.5 kg) at the side
5. Sleeping on the affected side
6. Using the hand overhead
7. Lifting
8. Perineal care
9. Eating with a utensil
9. Using the arm at shoulder level
10. Dressing
11. Pulling
12. Throwing.



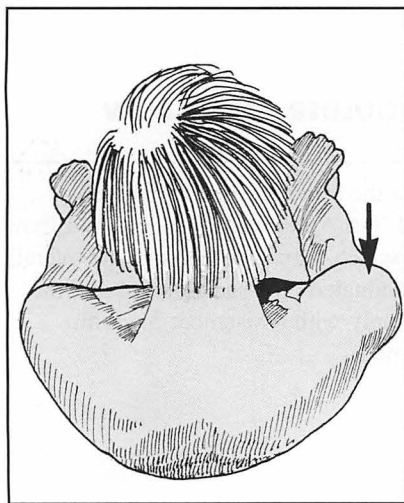
4.1. Inspection (1): the front: Note whether any of the following are present:
(A) Prominent sternoclavicular joint (subluxation). (B) Deformity of clavicle (old fracture). (C) Prominent acromioclavicular joint (subluxation or osteoarthritis). (D) Deltoid wasting (disuse or axillary nerve palsy).



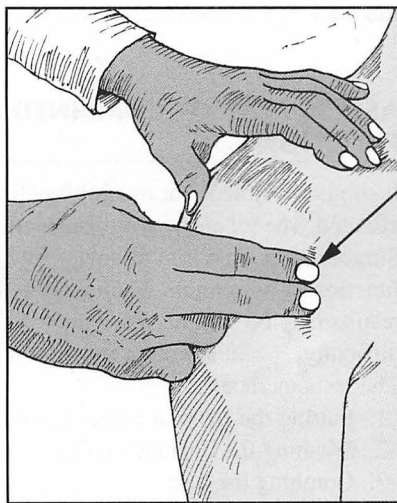
4.2. Inspection (2): the side: Note if there is any swelling of the joint, suggesting infection or inflammatory reaction from, for example, calcifying supraspinatus tendinitis, pyogenic infection of the glenohumeral joint, or trauma.



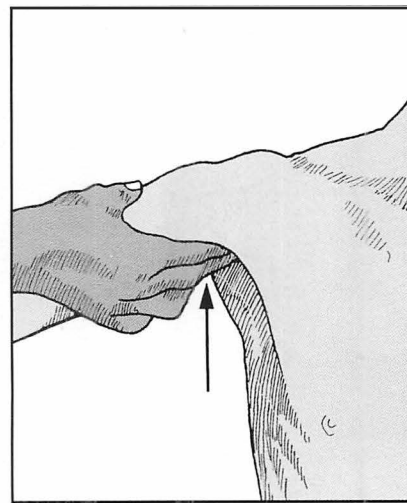
4.3. Inspection (3): from behind: Are the scapulae normally shaped and situated, or small and high, as in Sprengel's shoulder and the Klippel-Feil syndrome? Is there webbing of the skin at the root of the neck, also typical of the latter? Is there winging of the scapula owing to paralysis of serratus anterior?



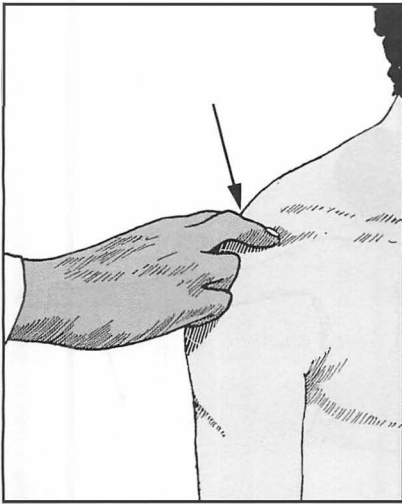
4.4. Inspection (4): from above: Again look for swelling of the shoulder, deformity of the clavicle, asymmetry of the supraclavicular fossae.



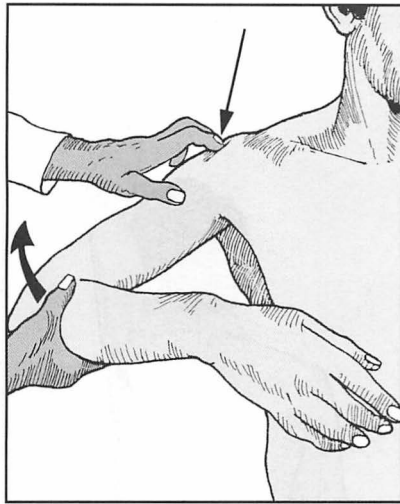
4.5. Palpation (1): Palpate the anterior and lateral aspects of the glenohumeral joint. Diffuse tenderness is suggestive of infection or calcifying supraspinatus tendinitis. Very marked tenderness is particularly associated with calcifying supraspinatus tendinitis and gonococcal infections.



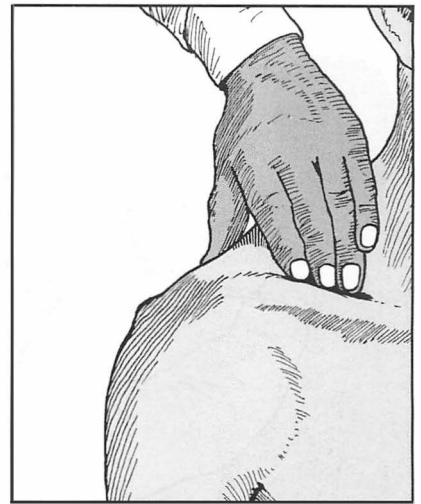
4.6. Palpation (2): Continue the examination by palpating the upper humeral shaft and head via the axilla. Exostoses of the proximal humeral shaft are often readily palpable by this route.



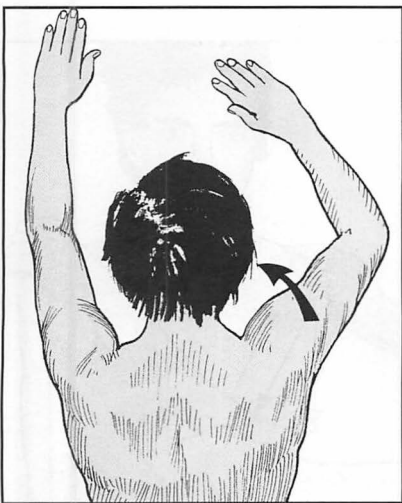
4.7. Palpation (3): Tenderness over the acromioclavicular joint is found after recent dislocations, and in osteoarthritis of the joint. In the latter liping is usually palpable, and crepitus may be detectable when the arm is abducted.



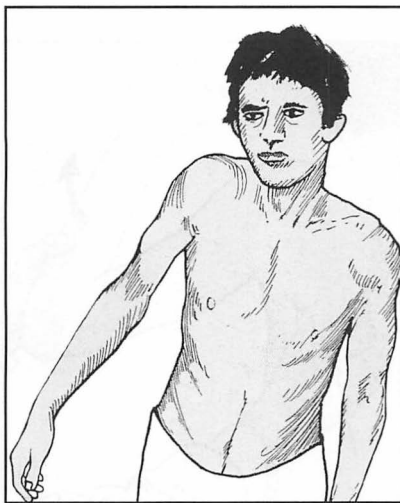
4.8. Palpation (4): Press below the acromion and abduct the arm. Sudden tenderness occurring during a portion of the arc of movement is found in tears and inflammatory lesions involving the shoulder cuff and/or the subdeltoid bursa.



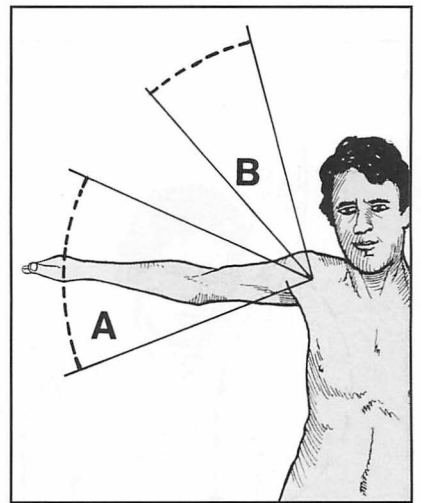
4.9. Palpation (5): Palpate the length of the clavicle. Tenderness is found in sternoclavicular dislocations and infections (particularly tuberculosis), tumours (rare), and radionecrosis (usually after treatment for breast cancer). Radiological examination of the clavicle is essential if local tenderness is found.



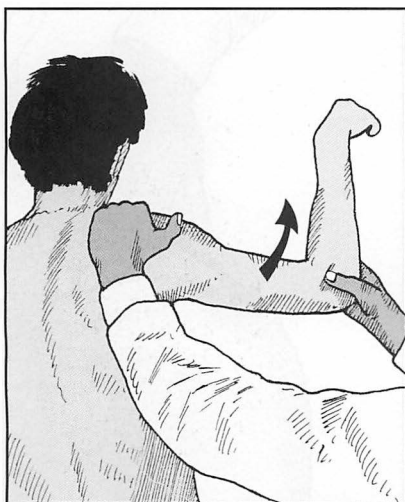
4.10. Movements: abduction (1): Ask the patient to abduct both arms; observe the smoothness of the movement and the range achieved. A full, free and painless range is rare in the presence of any significant pathology in the shoulder region.




4.11. Movements: abduction (2): Note whether the patient has any problem with initiating abduction. Difficulty in doing so is suggestive of a major shoulder cuff tear. A history of violent injury may be obtained in the young adult. In the middle-aged or elderly patient a tear may follow comparatively minor trauma, or occur spontaneously in a shoulder cuff weakened by attrition from chronic impingement.



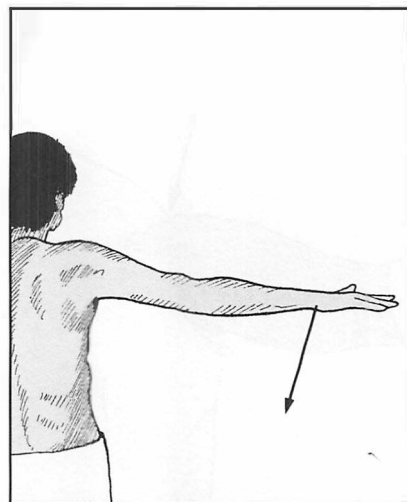
4.12. Movements: abduction (3): Note *pain* during abduction (which may have to be assisted): (A) During the arc 70° – 120° , suggestive of shoulder cuff impingement in the region of the acromion; (B) During the latter phase of abduction, suggestive of shoulder cuff impingement in the region of the acromioclavicular joint or coracoacromial ligament, or from osteoarthritis of the acromioclavicular joint.




4.13. Movements: abduction (4): If the patient cannot abduct the arm actively, attempt to do this passively, remembering to rotate the arm externally while doing so. A full range indicates an intact glenohumeral joint.



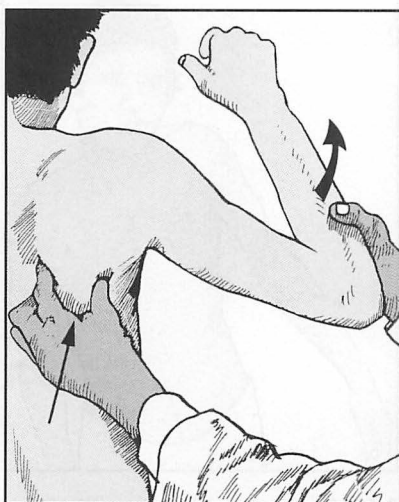
4.14. Movements: abduction (5): Ask the patient to hold the arm in the vertical position himself. If he can do so, deltoid and the axillary nerve are likely to be intact.



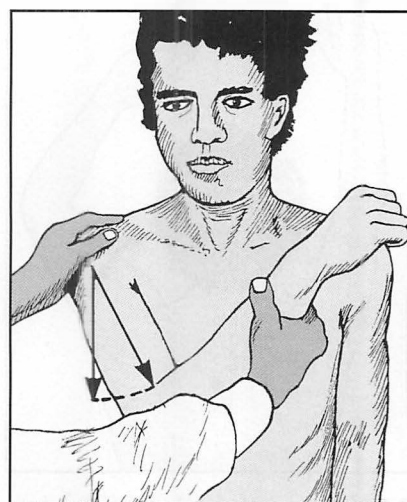
4.15. Movements: abduction (6): If the patient has passed the last test, ask him to lower the arm to the side. Again note the presence of any painful arc of movement. Sudden dropping of the arm in the process is a common finding in major shoulder cuff tears (drop arm test).



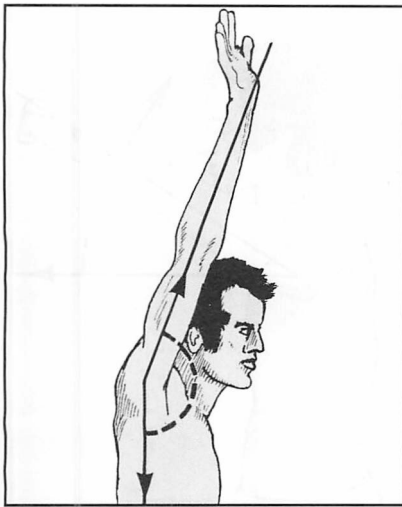
4.16. Movements: abduction (7): Measure the range of abduction. In the normal shoulder the arm can touch the ear with only slight tilting of the head. The shoulders have already been compared (see Frame 4.10).
Normal range: 0–170°.



4.17. Movements: abduction (8): If both active and passive movements are restricted, fix the angle of the scapula with one hand and try to abduct the arm with the other. Absence of movement indicates a fixed glenohumeral joint, the previously noted movements having been entirely scapular.

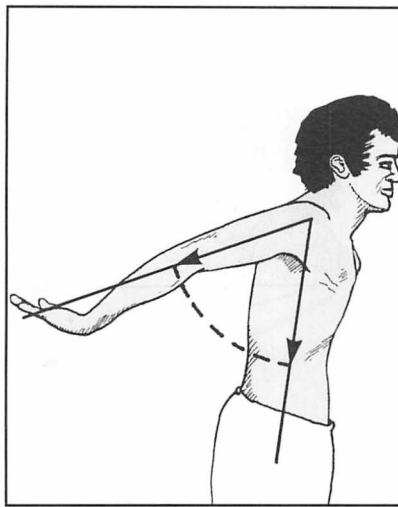


4.18. Movements: adduction in extension: Place one hand on the shoulder and swing the arm, flexed at the elbow, across the chest.
Normal range: 0–50°.




4.19. Movements: forward flexion: Ask the patient to swing the arm forwards and lift it above his head. View the patient from the side.

Normal range: 0–165°. (Note that instead of measuring abduction and flexion, some prefer to measure the maximum height to which the arm can be raised, irrespective of the planes of movement – and record this as ‘total active elevation’; but see note in Figure 4.C)



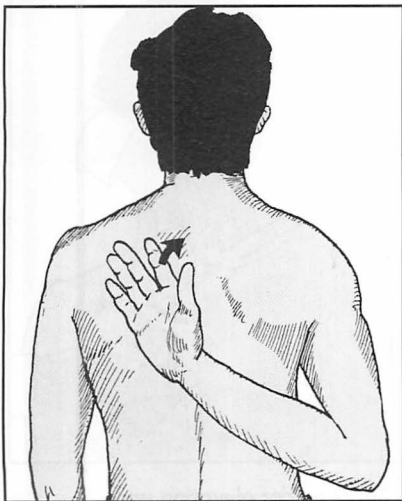
4.20. Movements: backwards extension: Ask the patient to swing the arm directly backwards, again viewing and measuring from the side.

Normal range: 0–60°.

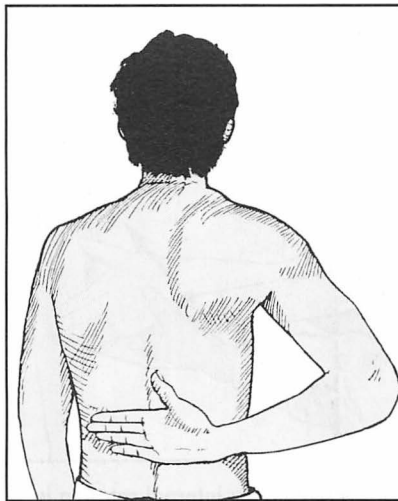


4.21. Movements: horizontal flexion and adduction: Occasionally measurement of this angle may be helpful, but it need not be routine. View the patient from above. The arm is moved forwards from a position of 90° abduction.

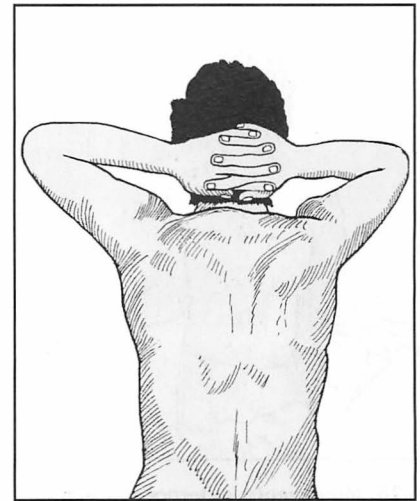
Normal range: 0–140°. Note that pain during this manoeuvre is common in osteoarthritis or trauma to the acromioclavicular joint.



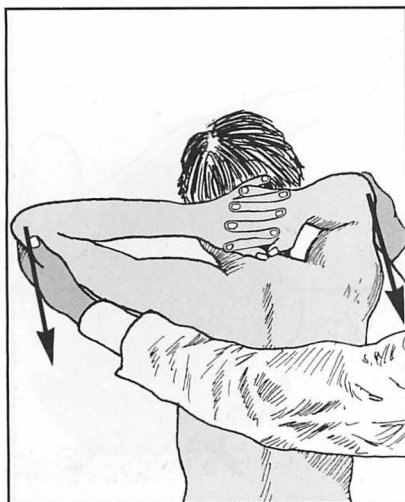4.22. Movements: rotation screening tests (1): Ask the patient to place the hand behind the opposite shoulder blade. This is a useful test of internal rotation in extension.



4.23. Movements: rotation screening (2): With slight restriction he will not be able to get the hand far up the back, and with severe restriction he will not be able to get it behind the back at all. This movement is commonly affected in frozen shoulder. *To test subscapularis* (which may be torn by violent external rotation, hyperextension, or anterior dislocation of the shoulder), ask the patient if he can draw the hand away from contact with the back when in the position shown.

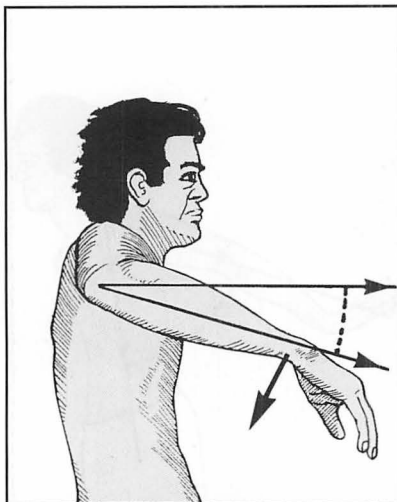


4.24. Movements: rotation screening (3): Ask the patient to place both hands behind the head to screen external rotation at 90° abduction. Compare the two sides. Lack of success or restriction is common in frozen shoulder.



4.25. Movements: rotation screening

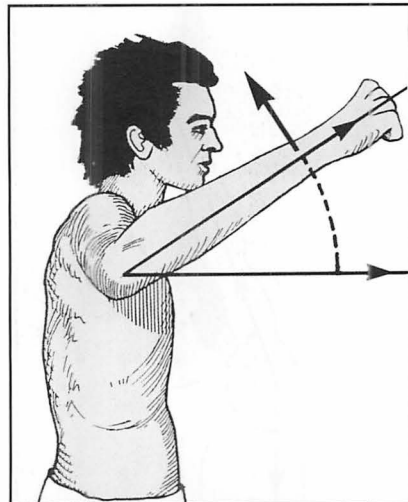
(4): Sometimes in the last test the patient manages to get the hand on the affected side behind the head, but in a position of horizontal flexion. If so, gently pull both elbows backwards, noting any difference. (Pain and restriction are common in frozen shoulder.)



4.26. Movements: internal rotation in abduction

Abduct the shoulder to 90°, and flex the elbow to a right-angle. Ask the patient to lower the forearm from the horizontal plane.

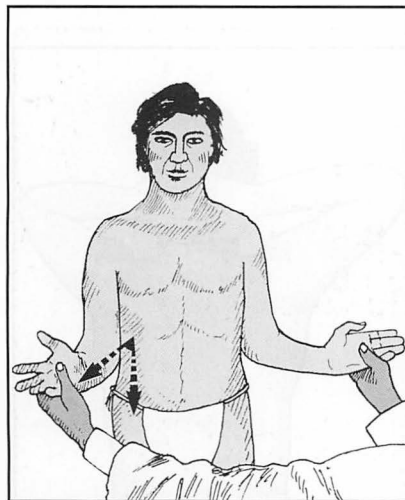
Normal range: 70°.



4.27. Movements: external rotation in abduction

From the same starting position with the forearm parallel to the ground, ask the patient to raise the hand, keeping the shoulder in 90° abduction.

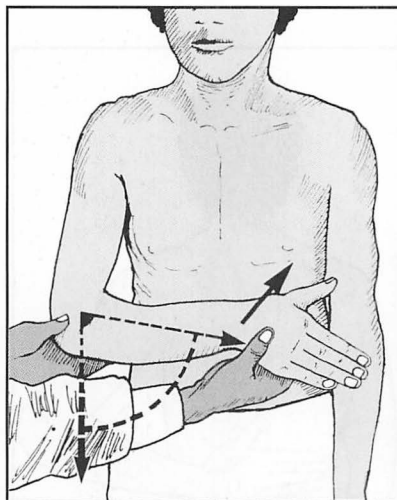
Normal range: 100°.



4.28. Movements: external rotation in extension

Place the elbows into the sides and flex them to 90° with the hands facing forwards. Move the hands laterally, comparing one side with the other.

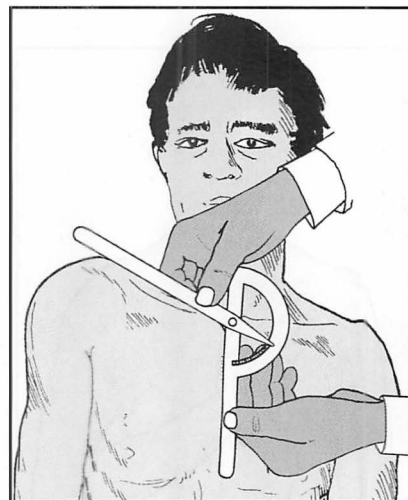
Normal range: 70°. Note that an increase in external rotation in extension is a feature of tears of the subscapularis muscle (see also Frame 23).



4.29. Movements: internal rotation in extension

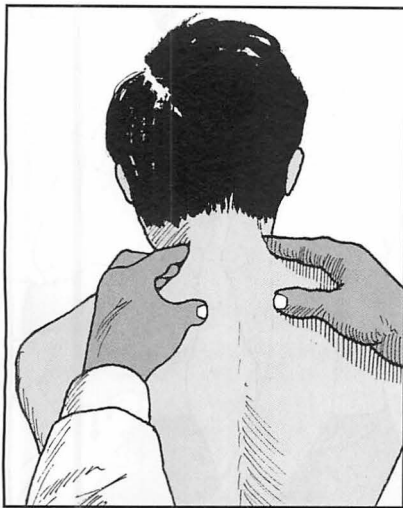Move the hand to the chest from the facing forward position.

Normal range: 70°. For most clinical work, assessment of abduction and screening rotation in the shoulder should suffice (but record angular ranges of movements in all planes for monitoring progress and for medicolegal reports).

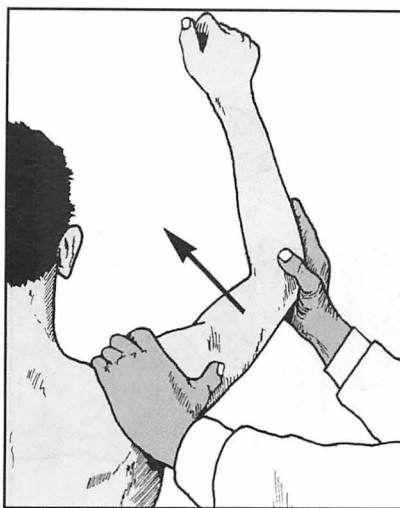

4.30. Shoulder elevation and depression

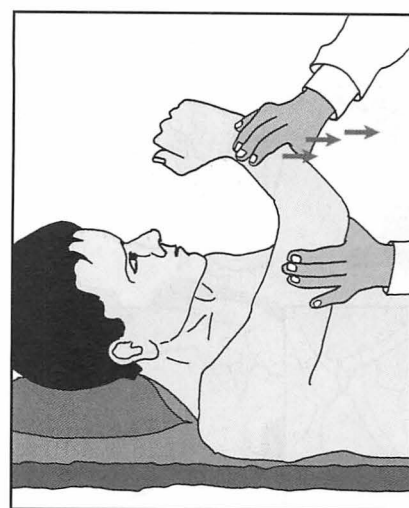This may be assessed by direct measurement (see 4C), but Hallaçeli and Güinal advocate the use of a goniometer, centred on the jugular notch, with one arm vertical and the other on the acromion. Normal range: elevation and depression in the order of 37° and 8°. Elevation (shrugging) gives a measure of trapezius function, and may also be used to assess hand recovery after stroke. These movements are also impaired in any condition involving scapulothoracic movement.



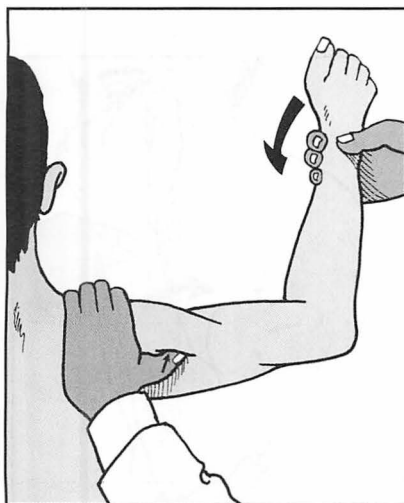
4.31. Cervical spine: Always screen the cervical spine in examining a case of shoulder pain; this is doubly important if shoulder movements are found to be normal.



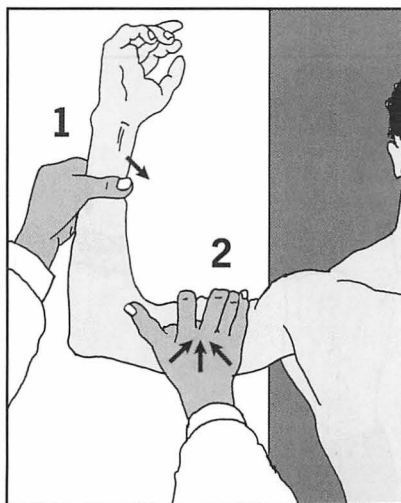
4.32. Crepitus: Place one hand over the shoulder, with the middle finger lying along the acromioclavicular joint. Abduct the arm with the other hand. Detect any crepitus coming from the shoulder and locate its source (glenohumeral or acromioclavicular). Repeat while the arm is actively abducted, and if in doubt, auscultate. Clicking may arise from a number of sources, including scapular exostoses and coracoid impingement. (The latter may cause shoulder pain and coracoid tenderness.)



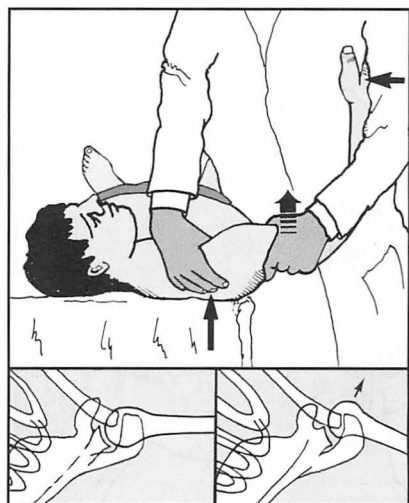
4.33. Rotator cuff examination: Pathology in the rotator cuff may be suspected by the performance of abduction and the drop arm test (see 11 and 15). *Neer impingement sign:* pain occurs when the shoulder is flexed to 90° and forcibly internally rotated. *Neer impingement test:* the test is repeated after injection of 10–15 mL of 1% xylocaine into the subacromial space, when less pain should be encountered if the pain is due to impingement of the rotator cuff against the acromion.



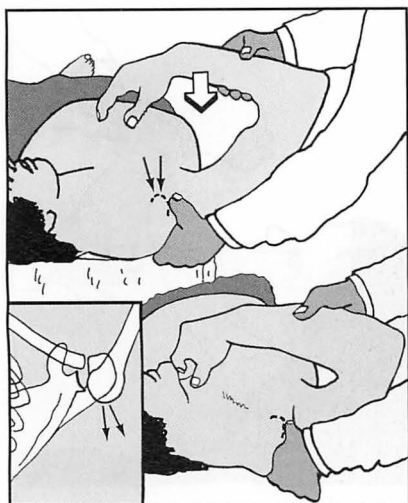
4.34. Anterior glenohumeral instability (1): *The apprehension test:* Stand behind the patient (preferably seated) and abduct the shoulder to 90°. Slowly externally rotate the shoulder with one hand while pushing the head of the humerus forwards with the thumb of your other hand. Apprehension, fear or refusal to continue is evidence of chronic anterior instability of the shoulder. Repeat at 45° and 135° abduction. Pain only may be felt in minor subluxations.



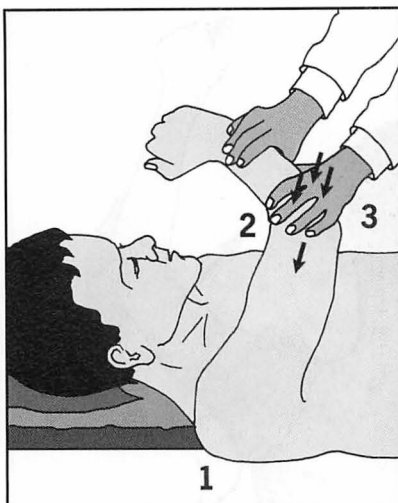4.35. Anterior glenohumeral instability (2): *Relocation test:* Repeat the apprehension test with the patient in the recumbent position: abduct and externally rotate the shoulder (1). When pain or apprehension first appear, press down on the upper arm (2). This will stabilize the head of the humerus in the glenoid at the time when subluxation is imminent, and should relieve any pain or apprehension. This, and the return of pain and apprehension on release of the downward pressure, is confirmatory of anterior instability.



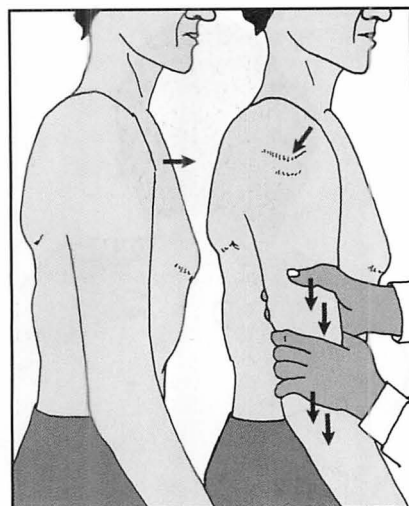
4.36. Anterior glenohumeral instability (3): *Drawer test of Gerber and Ganz:* Support the (supine) patient's relaxed arm against your side, with his shoulder in 90° abduction, slight flexion and external rotation. Steadying the scapula with the thumb on the coracoid and the fingers behind, try to move the humeral head anteriorly with your other hand. Observe any movement, clicks and patient apprehension, and compare the sides: axial radiographs may be taken in confirmation during the procedure, which is sometimes performed under anaesthesia.



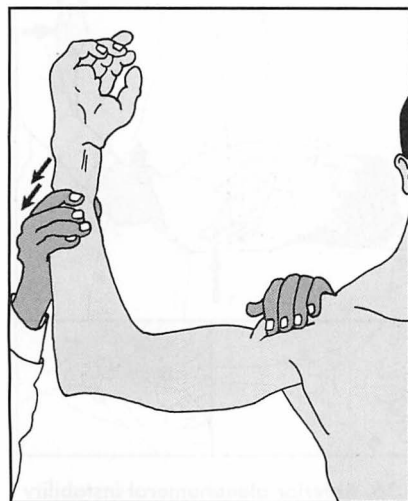
4.37. Posterior glenohumeral instability (1): Drawer test: Where recurrent posterior dislocation is suspected, hold the relaxed, supine patient's forearm with the elbow flexed and the shoulder in 20° flexion and 90° abduction. Place the thumb just lateral to the coracoid. Now internally rotate the shoulder and flex it to about 80°, pressing the humeral head backwards with the thumb; any backward displacement of the humeral head should be detected with the thumb, but X-ray confirmation may also be made.



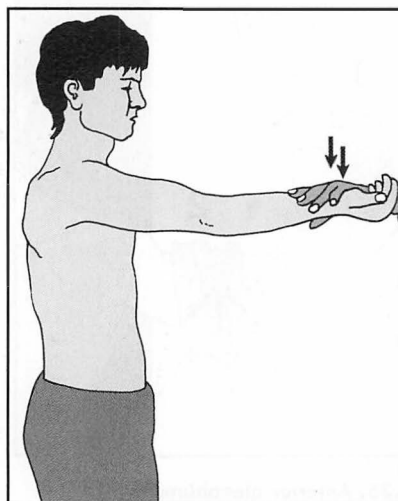
4.38. Posterior glenohumeral instability (2): The jerk test: With the patient's shoulder over the edge of the examination couch (1), flex both the shoulder and elbow to 90° (2). With one hand on the elbow, push downwards (3) and attempt to sublux the humeral head posteriorly. If this occurs, indicating instability, a jerk or jump will be felt. If negative, repeat with the shoulder adducted and internally rotated.



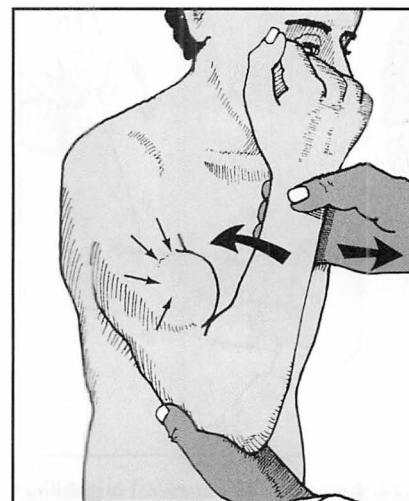4.39. Inferior glenohumeral instability: The sulcus sign: With the patient standing, grasp the arm and pull it downwards. If there is inferior laxity then a depression will become obvious between the humeral head and the acromion. This is of greatest significance if absent or less on the good side, or if accompanied by pain and apprehension on the affected side. A positive test is usually indicative of multidirectional instability.



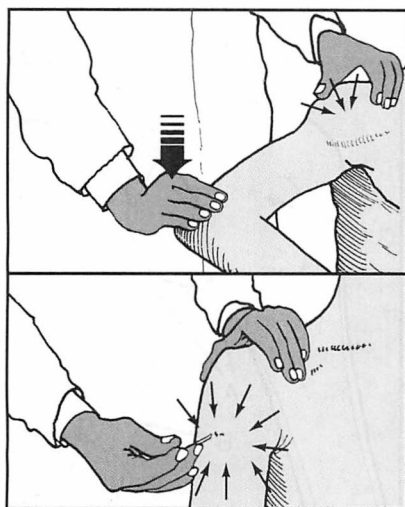
4.40. Biceps tendon instability test: The shoulder is abducted to 90° and the elbow flexed to a right-angle. The tendon is then located as it lies in the bicipital groove and, keeping the examining fingers in position, the patient's shoulder is internally rotated. If the tendon is unstable it may be felt to move out of position; this may be accompanied by an audible click.



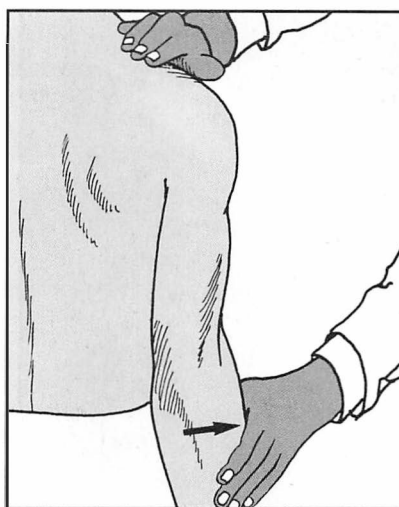4.41. Biceps tendinitis: The Speed test: With the elbow fully extended and supinated, the shoulder is flexed to 90°. The patient is asked to resist as the examiner tries to extend the shoulder. There is complaint of pain during this manoeuvre if there is inflammation in the tendon.



4.42. Integrity of the long head of biceps: Support the patient's elbow with one hand. Grasp his wrist and ask him to pull toward his shoulder while you resist this movement. If the long tendon of biceps is ruptured, the belly of biceps will appear globular in shape. Compare the two sides.

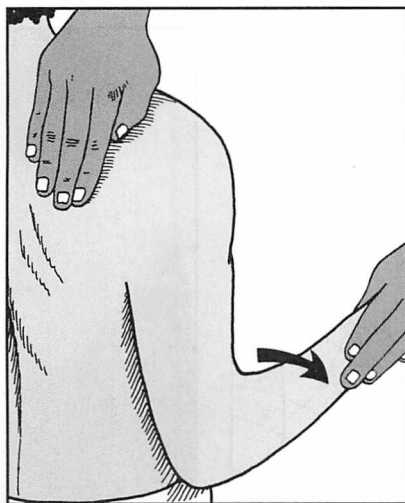


4.43. Deltoid power: Ask the patient to try to keep the arm elevated in abduction while you press down on his elbow; look and feel for deltoid contraction. Traction injuries of the axillary nerve resulting in deltoid involvement are seen most frequently after dislocations of the shoulder. If axillary nerve palsy is suspected, test for sensory loss in the 'regimental badge' area on the lateral aspect of the arm.



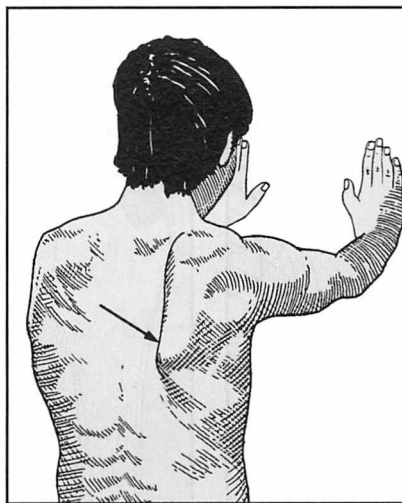4.44. The suprascapular nerve (1):

Supraspinatus: Palpate the scapula and identify its spine. Place the fingers of one hand above the spine, over the supraspinatus muscle. Steady the forearm with the other hand and ask the patient to attempt to abduct the arm against this resistance. If the suprascapular nerve is intact, the contraction of the supraspinatus should be easily felt.

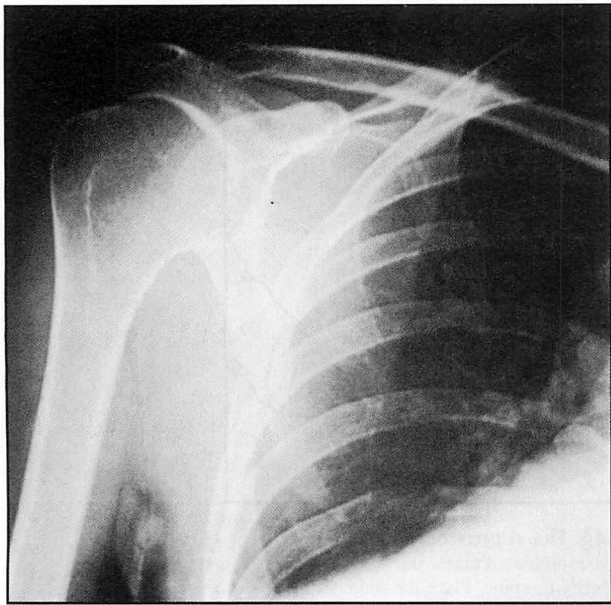


4.45. The suprascapular nerve (2):

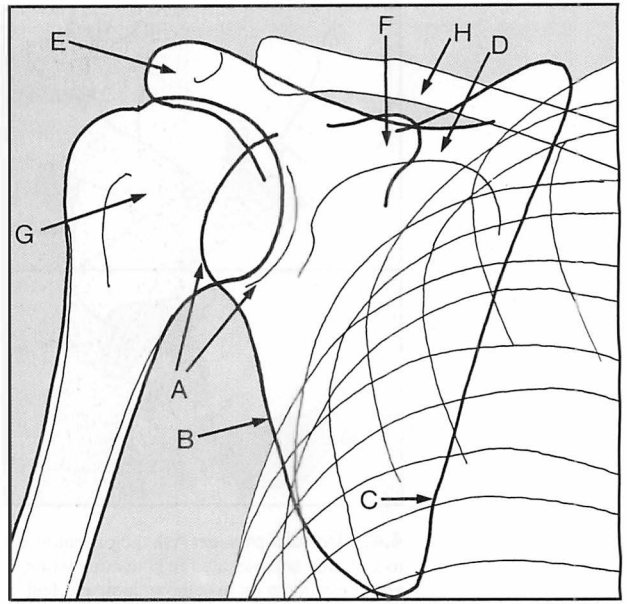
Infraspinatus: In a similar manner palpate the infraspinatus, caudal to the spine of the scapula, while asking the patient to externally rotate the shoulder against resistance. Paralysis of the muscle, with pain and weakness of the shoulder, may result from a ganglion in the spinoglenoid (greater scapular) notch. This diagnosis may be confirmed by MRI scan.



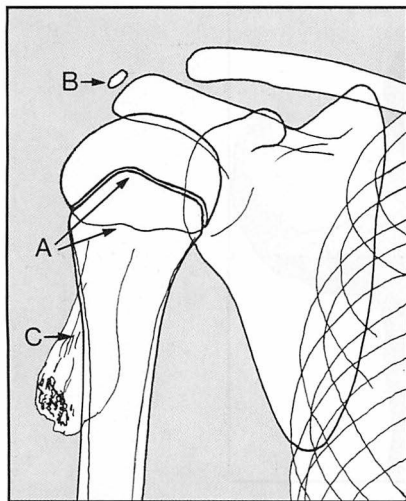
4.46. Long thoracic nerve: Where paralysis of serratus anterior is suspected, ask the patient to lean with both hands against a wall. Any tendency to winging of the scapula immediately becomes apparent.



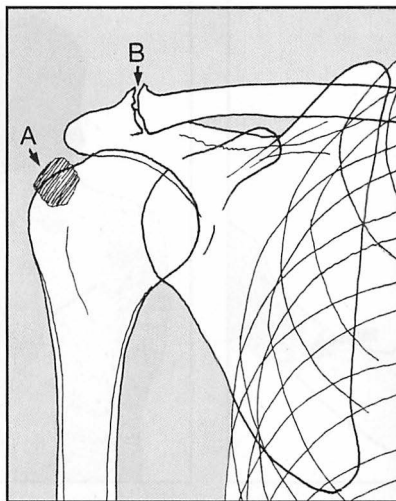
4.47. Radiographs (1): In screening the shoulder an anteroposterior projection is usually carried out, although additional views are highly desirable. This shows a typical normal film.



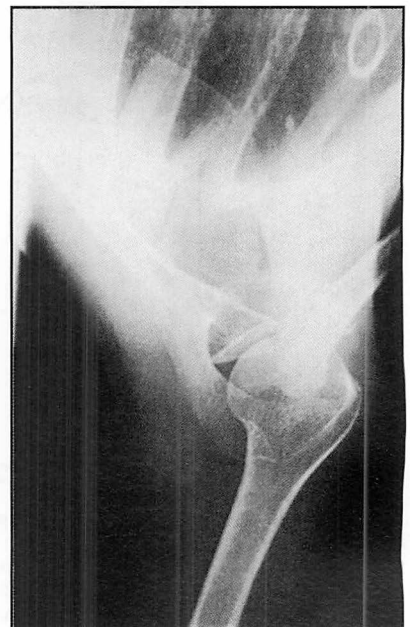
4.48. Radiographs (2): The standard shoulder projection is taken in recumbency. Examine the radiograph methodically by identifying (A) the glenoid, (B) the lateral border of the scapula, (C) the medial border of the scapula, (D) the spine of the scapula, (E) the acromion, (F) the coracoid. Note the relations of (G) the humeral head and (H) the clavicle to the glenoid and the acromion.



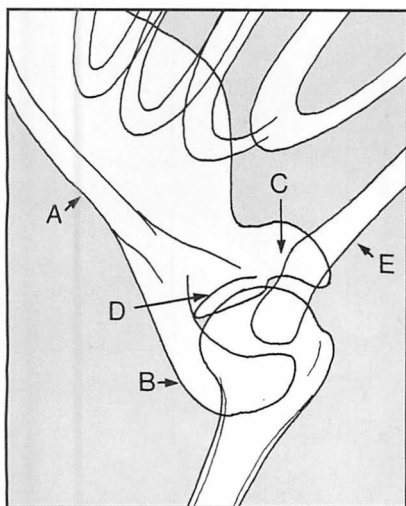
4.49. Radiographs (3): In the child or adolescent, do not mistake (A) the anterior and/or posterior margins of the epiphyseal plate for fracture or (B) the acromial ossification centre for a loose body. Note (C) the typical appearance of a simple exostosis (ossifying chondroma) of epiphyseal plate origin.



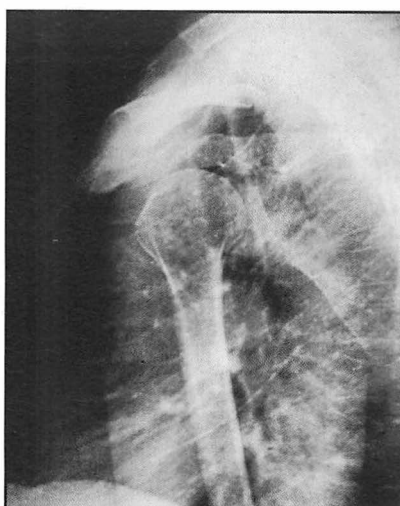
4.50. Radiographs (4): Calcification in the supraspinatus tendon in the upper part of the shoulder cuff has an amorphous appearance (A) and is characteristically situated. It may be symptom free. Note (B) arthritic changes in the acromioclavicular joint. Inferiorly projecting osteophytes are commonly associated with shoulder cuff pathology.



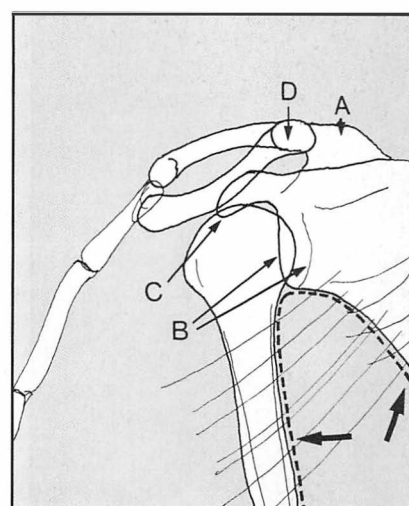
4.51. Radiographs (5): Additional projections (1): Normal axial (per-axillary or axillary lateral).



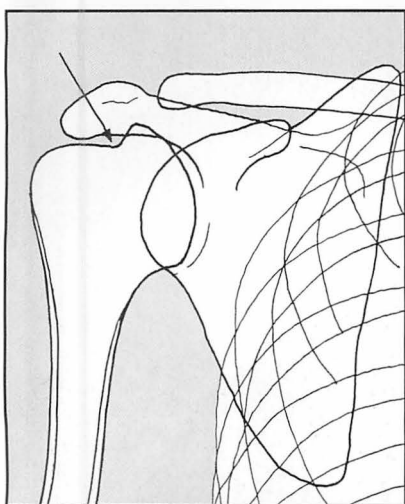
4.52. Radiographs (6): The axial lateral gives the most useful additional information, but is dependent on the patient being able to abduct the shoulder. It is very helpful in clarifying the relationships of the glenoid and humeral head; the lateral border of the scapula (A); the acromion and spine (B); the coracoid (C); the glenoid (D); and the clavicle (E).



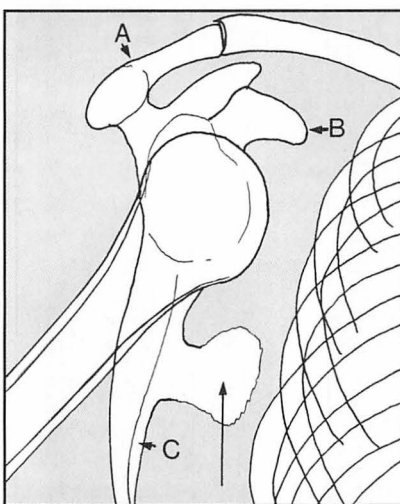
4.53. Radiographs (7): Additional projections (2): *Normal translateral (1):* If the patient is not able to have the arm abducted, a translateral is another view that may be used to give additional information. Unfortunately detail is often poor, especially in the stout patient. (Some prefer an apical oblique projection, taken with the plate at 45° and the beam angled appropriately; this duplicates and foreshortens the features seen in Frame 4.48, but helps clarify the glenohumeral relationship.)



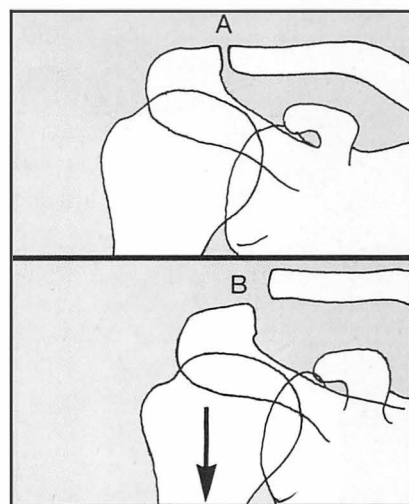
4.54. Radiographs (8): *Normal translateral (2):* Note (A) scapular spine; (B) glenoid; (C) coracoid; (D) acromioclavicular joints and superimposed clavicular shadows. Note the parabolic curve formed by the humeral shaft and the lateral border of the scapula. This is disturbed in most shoulder dislocations and subluxations.



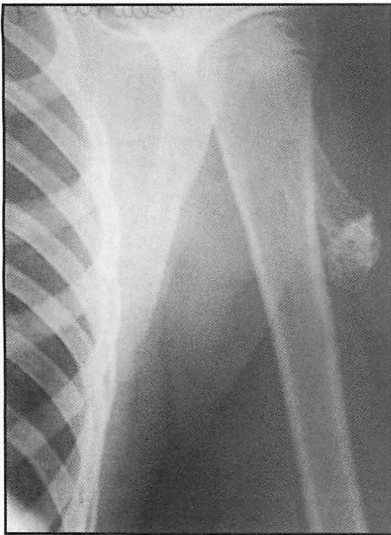4.55. Radiographs (9): Additional projections (3): In suspected recurrent dislocation of the shoulder an additional anteroposterior view should always be taken with the arm internally rotated. This may show a confirmatory defect in the posterolateral part of the humeral head (Hill–Sachs, or ‘hatchet head’ lesion). An axial lateral view will help to confirm this.



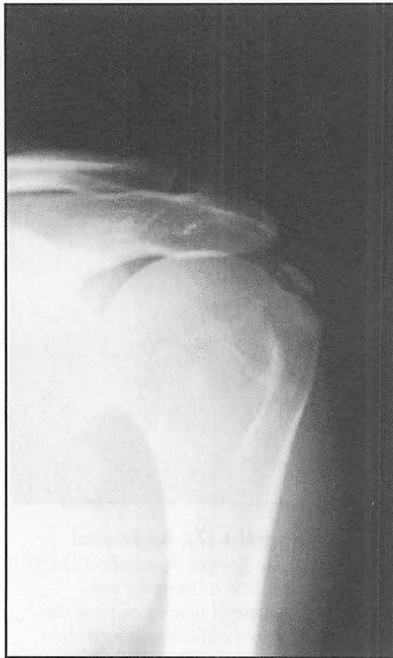
4.56. Radiographs (10): Additional projections (4): In cases of clicking or snapping shoulder, tangential views of the blade of the scapula will reveal any causal exostosis, particularly on the costal surface. (A) Acromion; (B) glenoid; (C) blade of scapula.



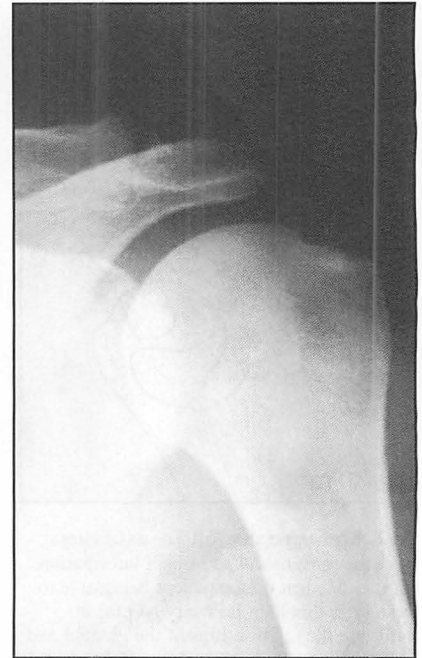
4.57. Radiographs (11): Additional projections (5): Where subluxation of the acromioclavicular joint is suspected, it is essential that the anteroposterior view of the shoulder is taken with the patient erect and holding a weight on the affected side. (A) Normal joint; (B) acromioclavicular dislocation.



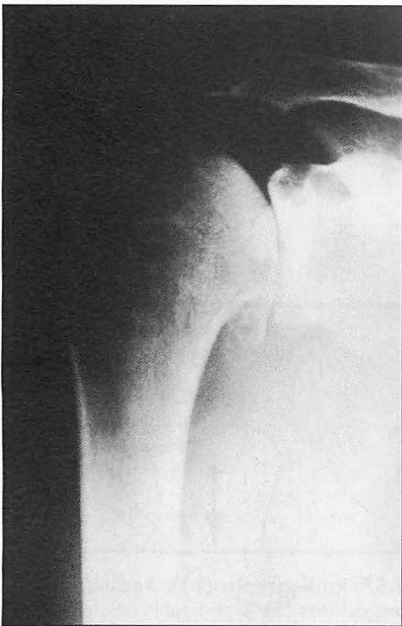4.58. Shoulder radiographs – examples of pathology (1): There is a calcified mass over the humeral shaft: its pedicle is attached to the metaphysis.
Diagnosis: the appearances are of a simple exostosis (ossifying chondroma, enchondroma).



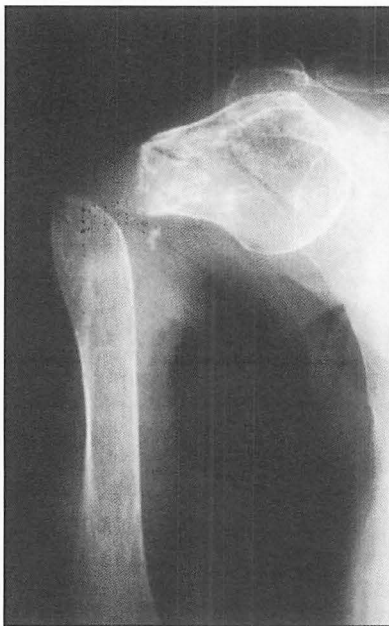4.59. Pathology (2): There is an amorphous mass of calcified material situated over the humeral head.
Diagnosis: calcifying supraspinatus tendinitis.



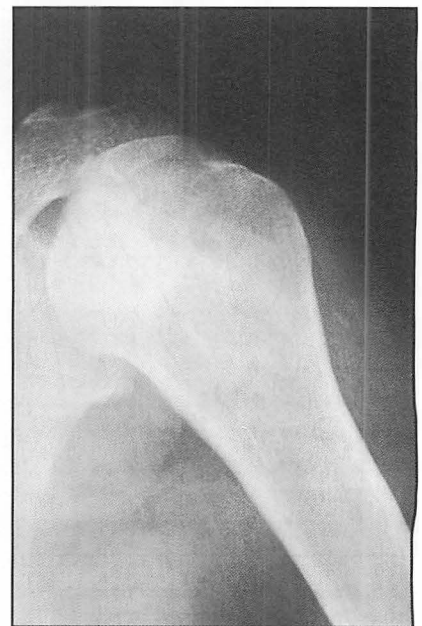
4.60. Pathology (3): There is narrowing of the joint space, some irregularity of the joint surfaces and a little lipping. There is a minimal degree of calcifying supraspinatus tendinitis also present.
Diagnosis: Osteoarthritis of the acromioclavicular joint.



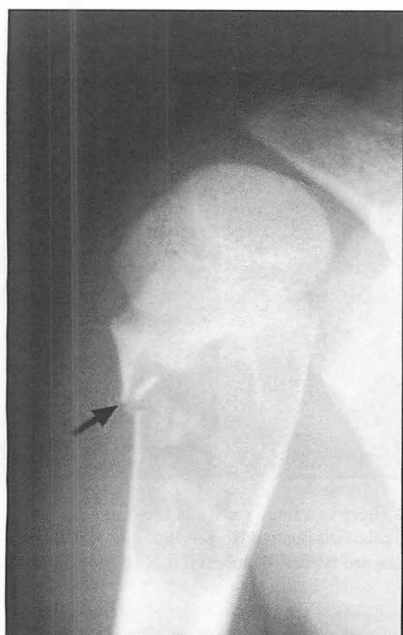4.61. Pathology (4): There is marked narrowing of the glenohumeral joint space, with a large exostosis arising from the humeral head.
Diagnosis: osteoarthritis of the glenohumeral joint.



4.62. Pathology (5): There is non-union in a fracture of the proximal humerus. The bone ends are rounded off and rather osteoporotic.
Diagnosis: history reveals that this has been a pathological fracture resulting from radionecrosis, following therapy for breast carcinoma.

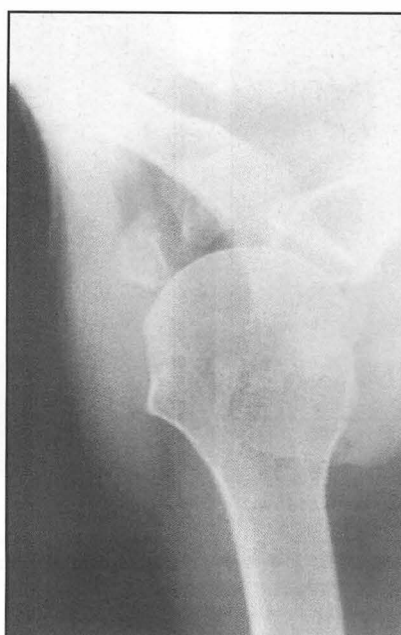

4.63. Pathology (6): There is irregularity of the humeral head, with patches of increased density.
Diagnosis: avascular necrosis of the head of the humerus. In this case the condition was due to caisson disease.

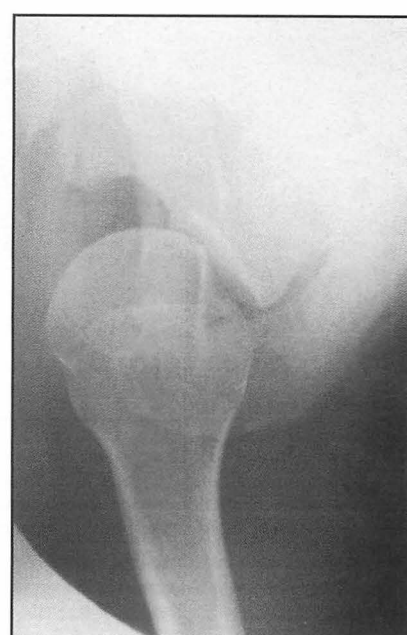

4.64. Pathology (7): The arrow points to a fracture through the proximal humerus of a child. The bone is expanded and there is thinning of the cortex.

Diagnosis: this is a pathological fracture, in this case through a simple (unicameral) bone cyst.

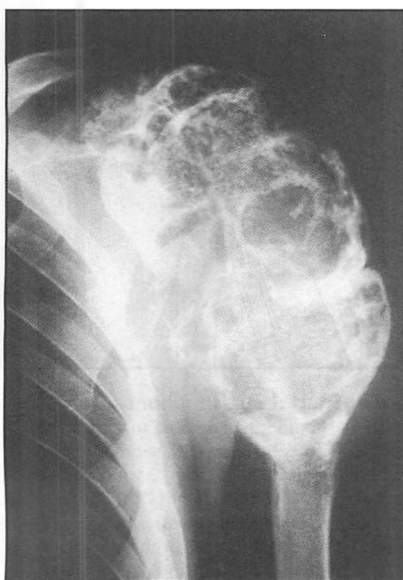


4.65. Pathology (8): Diagnosis: this axial projection shows non-union in a fracture of the coracoid.



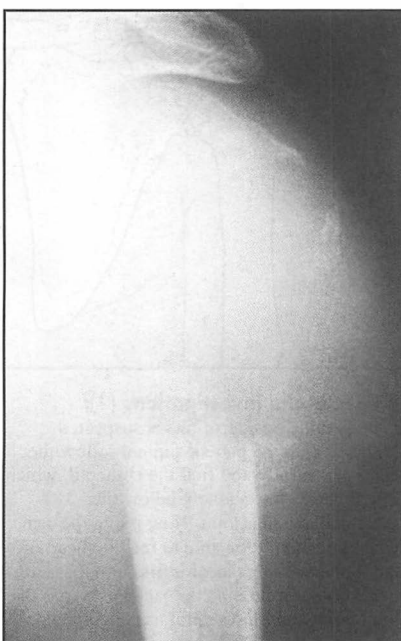
4.66. Pathology (9): This axial radiograph shows an anterior subluxation of the shoulder associated with a defect in the humeral head.

Diagnosis: the findings confirm a clinical diagnosis of recurrent dislocation of the shoulder.



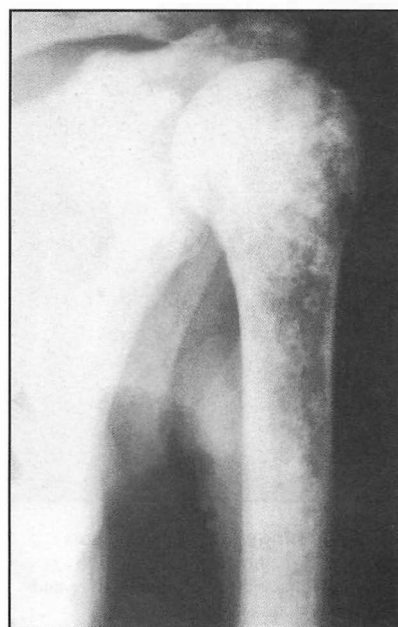
4.67 Pathology (10): The humeral head has been replaced by a huge mass of poorly differentiated bone.

Diagnosis: the appearances are typical of osteoclastoma (giant cell tumour of bone), a locally malignant condition which may, however, on occasion become invasive and metastasize.



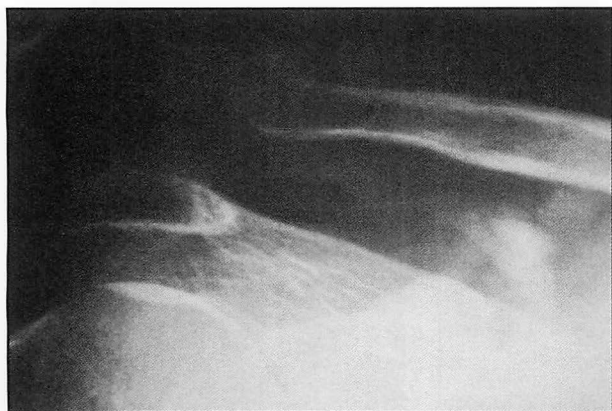
4.68. Pathology (11): The head of the humerus has been destroyed.

Diagnosis: in this case the appearances are the result of a (malignant) chondrosarcoma.

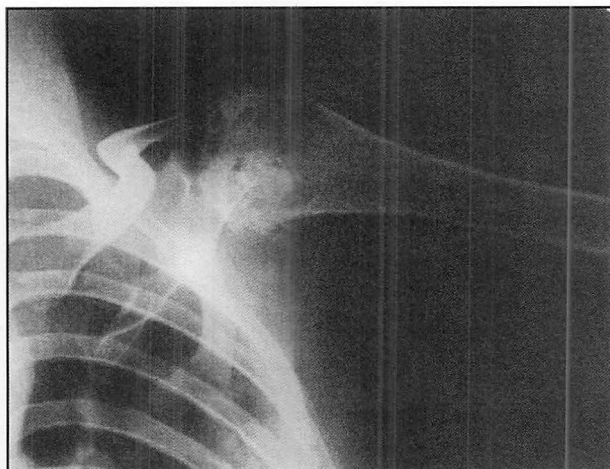


4.69. Pathology (12): The humerus and scapula show widespread patchy sclerotic changes.

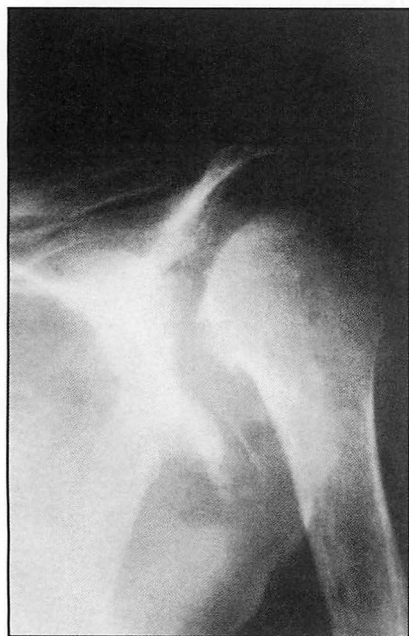
Diagnosis: the appearances are typical of metastatic spread from a carcinoma of the prostate.



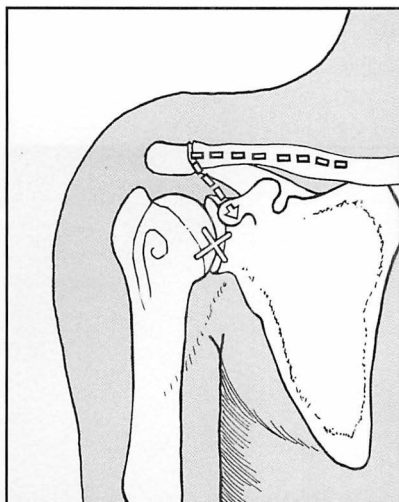
4.70. Pathology (13): **Diagnosis:** the radiograph shows a dislocation of the acromioclavicular joint. In addition, there is evidence of calcification in the haematoma which has resulted from the tearing of the conoid and trapezoid ligaments.



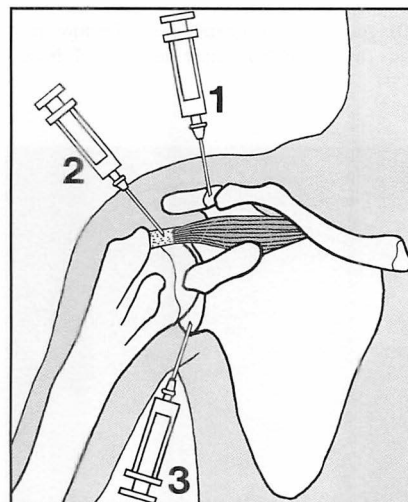
4.71. Pathology (14): There is a large cavity in the humeral head containing a sequestrum; calcified pus is also present.
Diagnosis: the appearances are typical of tuberculosis of the shoulder joint.



4.72. Pathology (15): There is gross distortion of the humeral head and the glenoid, with alteration of bone texture and destructive changes.
Diagnosis: the appearances are typical of Charcot's disease.



4.73. Special investigations (1):
Aspiration. Consider if pus is suspected.
Method: with the patient supine, follow the clavicle laterally and find the coracoid, which lies about 5 cm obliquely below the acromioclavicular joint. Now rotate the arm, when you should be able to feel the head of the humerus. After local infiltration, pass a large-bore needle directly backwards into the joint below and just lateral to the coracoid.



4.74. Special investigations (2): Where there is shoulder pain related to movement and the source is uncertain, serial injections with local anaesthetic may be tried. Start with the acromioclavicular joint (1): if pain on movement is not relieved after 5–10 minutes, proceed to the upper part of the shoulder cuff (2); if this also fails, infiltrate the glenohumeral joint (3). This may be approached as detailed in the previous frame.

4.75. Special investigations (3): Other investigations can include the following:*Suspected infections*

1. White cell count and differential blood count
2. Blood culture
3. ESR
4. Chest X-ray
5. Aspiration of the joint, with the appropriate examinations to exclude pyogenic, gonococcal and tubercular infections.

Undiagnosed mechanical problems or painful arc syndromes

1. Examination of the joint by CT or MRI scans
2. Arthrography, with the use of radio-opaque dye in (a) the glenohumeral joint, or (b) the subdeltoid bursa
3. Examination of the joint under general anaesthesia
4. Arthroscopy.

CHAPTER

5

The elbow

- Anatomical features 74
 - General points 74
 - Important relations 74
 - Elbow function 75
- Tennis elbow 75
- Cubitus varus and cubitus valgus/elbow instability 75
- Tardy ulnar nerve palsy 75
- Ulnar neuritis and the ulnar tunnel syndrome 76
- Olecranon bursitis 76
- Pulled elbow 76
- Osteoarthritis and osteochondritis dissecans 76
- Rheumatoid arthritis 77
- Tuberculosis of the elbow 77
- Myositis ossificans 77
- Inspection 78
- Movements 79
- Palpation 80–81
- Tennis elbow tests 81–82
- Radiographs 82–84
- Pathology 84–87
- Aspiration of the elbow joint 87

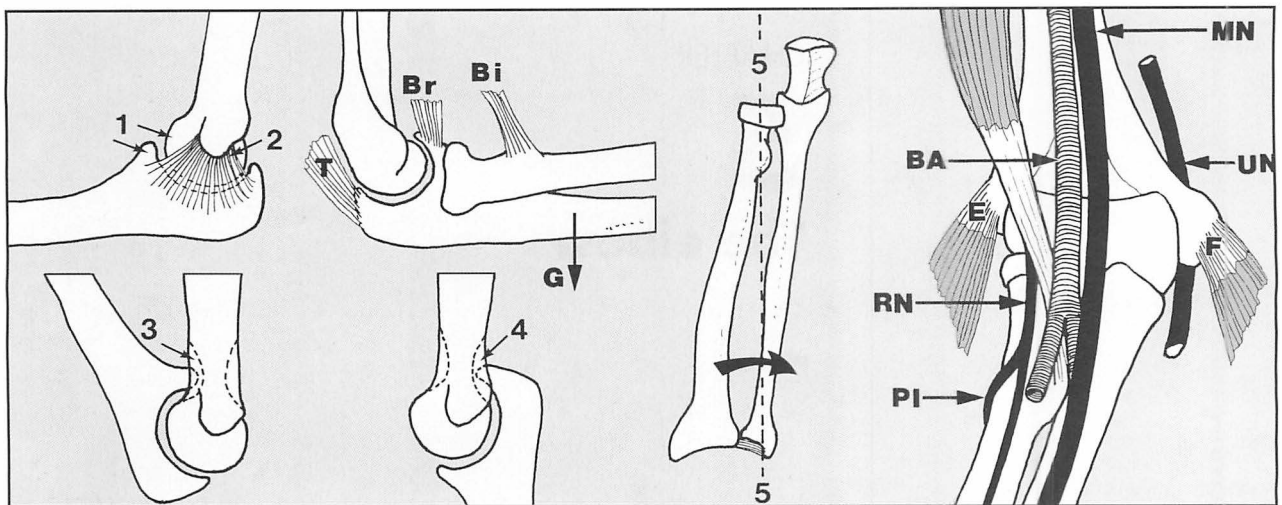


Fig. 5.A

ANATOMICAL FEATURES

GENERAL POINTS

The calliper-like close fit between the ulna and the trochlea (1) contributes to the impressive stability of the normal elbow; this is aided by the strong collateral ligaments (2). Instability may be seen following certain fractures of the coracoid or olecranon, owing to impairment of the stabilizing bony features of the joint. It may follow ligamentous laxity from repeated stretching and tears in athletes; or it may occur when the ligaments become lax in the course of rheumatoid arthritis or an elbow joint infection.

At the end of flexion the coronoid process tucks into the coronoid fossa (3), and at full extension, the olecranon process fits into the olecranon fossa (4). The clearances are small, and only a little local disturbance, such as a small loose body in one of the fossae, may produce a significant restriction of movement.

The elbow joint is normally extended by gravity (G); forced extension is powered by triceps (T); and triceps acting with the elbow flexors (biceps (Bi) and brachialis (Br)) holds the elbow straight and rigid.

The axis (5) of pronation and supination passes through the radial head and the attachment of the triangular fibrocartilage.

Mechanically, pronation and supination may be restricted by problems involving the elbow, wrist or forearm bones. Pronation is controlled by pronator teres and pronator quadratus; supination is carried out by biceps and supinator.

IMPORTANT RELATIONS

- The median nerve (MN) and brachial artery (BA) lie medial to the biceps tendon and superficial to the brachialis muscle.
- The radial nerve (RN) and its important posterior interosseous nerve branch (PI) lie lateral to the biceps tendon.
- The ulnar nerve (UN) at the elbow lies behind the medial epicondyle.
- The main extensor muscle origin (E) is from the lateral epicondyle.
- The main flexor origin (F) is from the medial epicondyle.

ELBOW FUNCTION

Note that disturbance of arm function secondary to elbow pathology is disproportionately greater when the shoulder is also impaired. (See also p. 57.)

TENNIS ELBOW

This is by far the commonest cause of elbow pain in patients attending orthopaedic clinics. It is generally believed to be due to a strain of the common extensor origin, but fibrosis in extensor carpi radialis brevis or a nerve entrapment syndrome have been suggested as alternative causes. The patient, usually in the 35–50-year age group, complains of pain on the lateral side of the elbow and difficulty in holding any heavy object at arm's length. There may be a history of recent excessive activity involving the elbow, e.g. dusting, sweeping, painting, or even playing tennis.

In sportsmen, a period of rest or modification of a flawed game-playing technique may allow the condition to settle. In manual workers relief may follow avoidance of the suspected causal activity, although this may not always be possible. When these basic measures fail, an elbow clamp (employed to redirect the pull of the forearm extensors) can be effective. Symptoms are also usually relieved by one to three injections of local anaesthetic and hydrocortisone into the painful area, and local ultrasound may be tried. Excellent results have been claimed from extracorporeal shock-wave therapy. In resistant cases, when all conservative measures have failed, exploration of extensor carpi radialis brevis may be considered (with excision of any fibrous mass or lengthening of the tendon).

In golfer's elbow there is a similar history, but here pain and tenderness involve the common flexor origin on the medial side of the elbow. This condition is much less common than tennis elbow.

CUBITUS VARUS AND CUBITUS VALGUS/ELBOW INSTABILITY

A decrease or increase in the carrying angle of the elbow generally follows a supracondylar or other elbow fracture in childhood. Although the normal child has great powers of spontaneous recovery following injury, there may nevertheless be some epiphyseal damage that fails to correct; where there is evidence of interference with the carrying angle the child should be observed for a number of years. If there is failure of spontaneous correction, or even deterioration, and the deformity is very unsightly, correction by osteotomy may be undertaken. In later life either of these deformities may be followed by a tardy ulnar nerve palsy.

Medial instability may occur in athletes who subject their elbows to severe valgus stresses by throwing, e.g. javelin throwers and baseball pitchers. There may be attenuation of the medial collateral ligaments, or even rupture. Mild cases may subside with rest, but in some a reconstruction may become necessary if there is the desire to continue with the activity. Instability is also seen in rheumatoid arthritis, the Ehlers–Danlos syndrome, and in Charcot's disease.

TARDY ULNAR NERVE PALSY

This ulnar nerve palsy is slow in onset and progression. It appears usually between the ages of 30 and 50, and the preceding injury to the elbow,

considered responsible for the ischaemic and fibrotic changes in the nerve, has usually been in childhood. It is seen most frequently where there is a cubitus valgus deformity. The progress of the palsy may be arrested by transposition of the nerve from its normal position behind the medial epicondyle to the front of the joint.

ULNAR NEURITIS AND THE ULNAR TUNNEL SYNDROME

Ulnar neuritis, with its frequent accompaniment of small muscle wasting and sensory impairment in the hand, may occur as a complication of local trauma at the elbow or at the wrist. At the elbow, it is also seen where the nerve is abnormally mobile. In these circumstances it is exposed to frictional damage as it slips repeatedly in front of and behind the medial epicondyle. In such cases reanchorage or transposition may prevent further deterioration. Some advocate epicondylectomy.

The nerve is also subject to pressure as it passes between the two heads of flexor carpi ulnaris below the elbow (the cubital tunnel), or as it lies in the ulnar tunnel in the hand. Where the local findings are not clear enough to localize the site of involvement, nerve conduction rate studies are often most helpful.

In a number of cases no obvious cause for an ulnar neuritis may be found.

OLECRANON BURSITIS

Swelling of the olecranon bursa is common in carpet-layers and others who repeatedly traumatize the posterior aspect of the elbow joint. Swelling of the bursa is also common in rheumatoid arthritis, and there may be associated nodular masses in the proximal part of the forearm. The condition is usually painless unless there is an associated bacterial infection within the bursa. Excision is sometimes advised for cosmetic reasons.

PULLED ELBOW

This condition occurs in young children under the age of 5, and is produced by traction on the arm, as for example when a mother snatches the hand of a child wandering towards the edge of a pavement. The radial head slides out from under cover of the orbicular ligament, and the child complains of pain and limitation of supination. The orbicular ligament and radial head may be reduced by forced supination while pushing the radius in a proximal direction (by forced radial deviation of the hand). On the other hand, spontaneous reduction, without manipulation, usually occurs within 48 hours of the incident if the arm is rested in a sling.

OSTEOARTHRITIS AND OSTEOCHONDRITIS DISSECANS

Primary osteoarthritis of the elbow joint is not uncommon in heavy manual workers. Osteoarthritis is also seen secondary to old fractures involving the articular surfaces of the elbow. It may also follow osteochondritis dissecans. Both osteoarthritis and osteochondritis dissecans may give rise to the formation of loose bodies, which restrict movements or cause locking of the joint. The joint may lock in any position, and the patient often develops the trick of unlocking the joint himself. If loose bodies are found, they should be

removed to prevent further incidents of locking and to reduce the risk of their causing more damage to the articular surfaces. Joint replacement surgery in those suffering from osteoarthritis of the elbow is seldom indicated, as the physical demands are likely to exceed the capabilities of any current replacement.

RHEUMATOID ARTHRITIS

Rheumatoid arthritis may affect either one or both elbows. If both elbows are involved the functional disability may be particularly great.

Clinically there may be marked synovitis, painful restriction of movements, and a fixed flexion deformity. Pronation and supination may be restricted and painful, although in some cases the distal radioulnar joint may be responsible. When there is gross destruction of the elbow, the ulnar nerve may be affected and the joint may become flail.

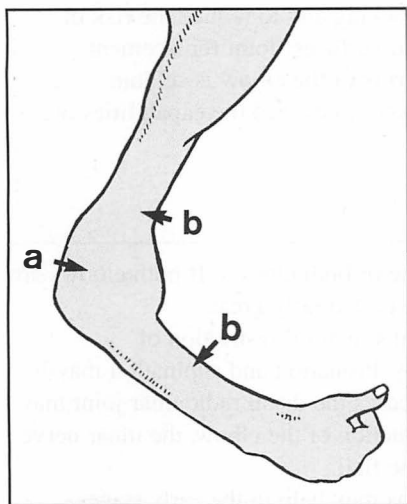
Medical treatment and steroid injections may help in the early stages. Later, synovectomy with excision of the radial head may delay progress; and in advanced cases, with gross instability, joint replacement may be considered.

TUBERCULOSIS OF THE ELBOW

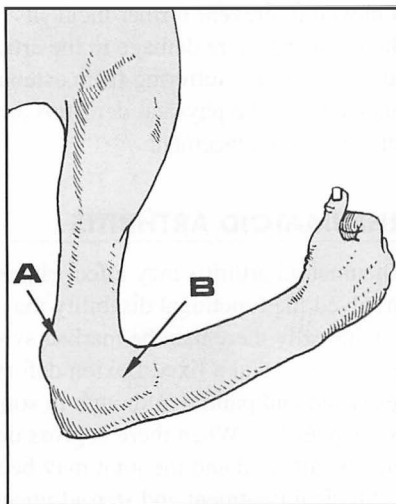
Tuberculosis of the elbow is now very uncommon; marked swelling of the elbow with profound local muscle wasting is usually so striking that there is unlikely to be a delay in further investigation by aspiration and synovial biopsy.

MYOSITIS OSSIFICANS

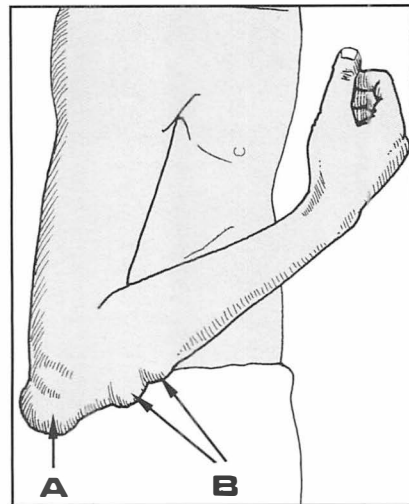
This condition occurs most commonly after supracondylar fractures and dislocations of the elbow. Calcification occurs in the haematoma that forms in the brachialis muscle covering the anterior aspect of the elbow joint. It is particularly common in association with head injuries, and may also follow over-vigorous physiotherapy. It leads to a mechanical block to flexion. If discovered at an early stage, complete rest of the joint is necessary to minimize the mass of material formed. In later cases it may be excised after the lesion has appeared quiescent for many months, and postoperatively a single dose of radiation therapy may help prevent recurrence.



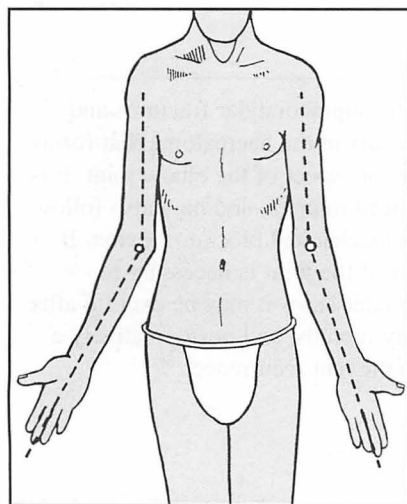
5.1. Inspection (1): Look for (A) generalized swelling of the joint and (B), muscle wasting, both suggestive of infective arthritis (e.g. tuberculosis) or rheumatoid arthritis. The swollen elbow is always held in the semiflexed position, as in this position intra-articular pressure, and hence pain, is least marked.



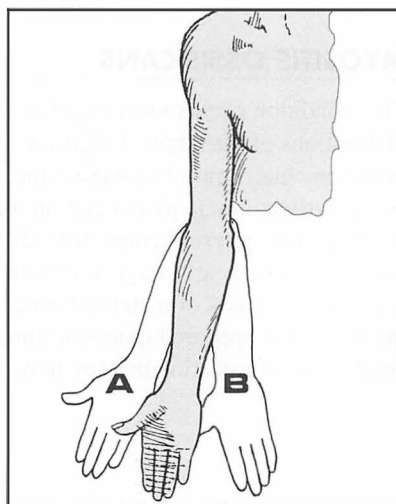
5.2. Inspection (2): Note that the earliest clinical sign of effusion is the filling out of the hollows seen in the flexed elbow above the olecranon (A). The next sign is swelling of the radiohumeral joint (B). Fluid may be squeezed between these two areas.



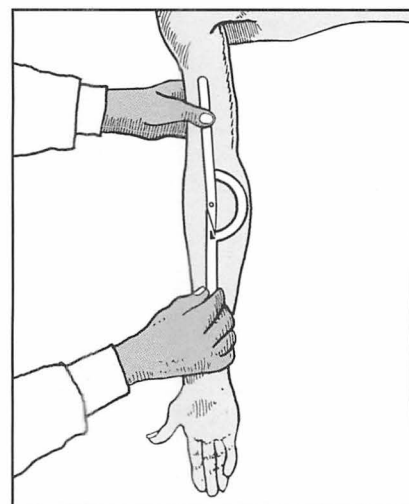
5.3. Inspection (3): Note whether there are any localized swellings round the joint, e.g. (A) olecranon bursitis, (B) rheumatoid nodules.



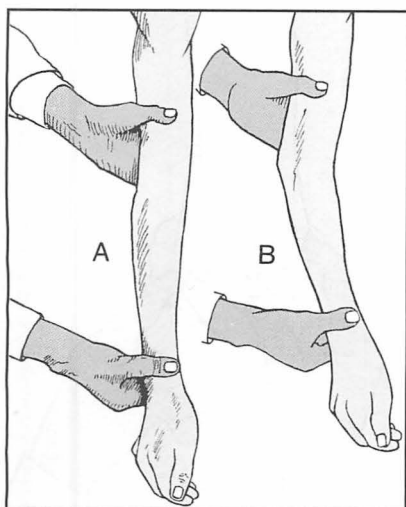
5.4. Inspection (4): Ask the patient to extend both elbows and note the carrying angle on both sides. Any small difference between the sides will then be obvious.



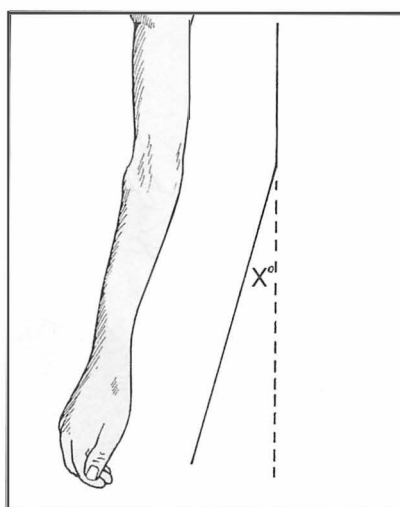
5.5. Inspection (5): (A) In cubitus valgus there is an increase in the carrying angle. (B) In cubitus varus there is a decrease in the carrying angle ('gunstock deformity'). The commonest cause of unilateral alteration in the carrying angle is an old supracondylar fracture. Valgus and/or varus laxity and instability (confirm by stressing) may also follow certain elbow fractures.



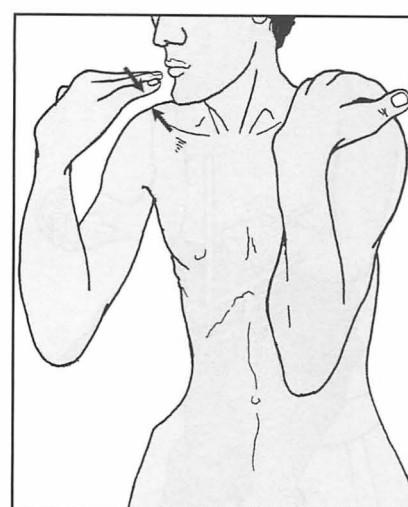
5.6. Inspection (6): The carrying angle may be measured with a goniometer.
Average values of carrying angle:
Males: 11° (range 2° – 26°)
Females: 13° (range 2° – 22°).



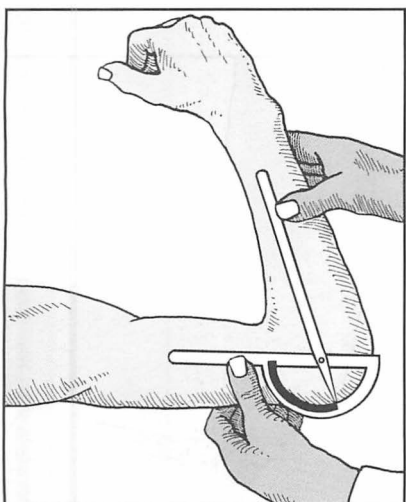
5.7. Movements (1): Extension: (A) Full extension, 0°, is present if the arm and forearm can be made to lie in a straight line. (B) Loss of full extension is especially common in osteoarthritis, rheumatoid arthritis, and old fractures (particularly of the radial head) involving the elbow joint.



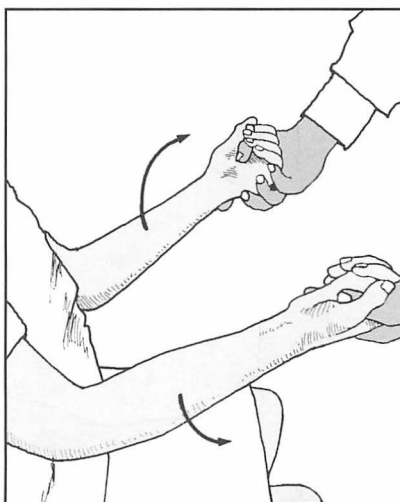
5.8. Movements (2): Hyperextension: If the elbow can be extended beyond the neutral position, record this as 'X° hyperextension'. Up to 15° is accepted as normal, especially in women. Beyond this, look for hypermobility in other joints (for example as may occur in the Ehlers-Danlos syndrome).



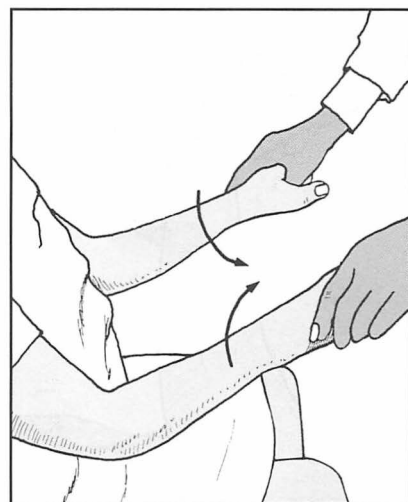5.9. Movements (3): Flexion (1): (Screening test) Ask the patient to attempt to touch both shoulders. A slight difference in flexion between the sides is then usually obvious.



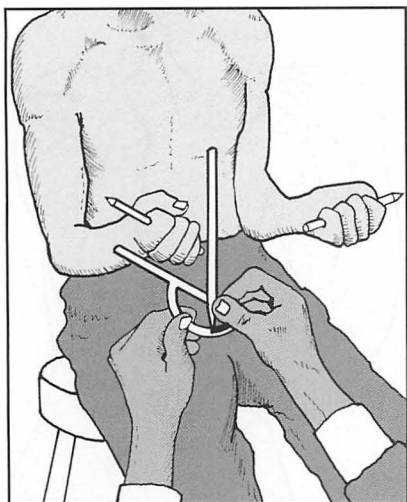
5.10. Movements (4): Flexion (2): The range of flexion may be measured. **Normal range = 145°.** Restriction of flexion is common after all fractures round the elbow, and in all forms of arthritis.



5.11. Movements (5): Pronation/supination screening (1): Ask the patient to hold the elbows closely to the sides. Turn the palms upwards into supination and compare the sides.



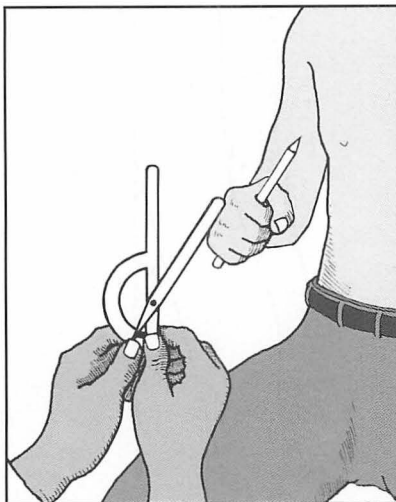
5.12. Movements (6): Pronation/supination screening (2): Now turn the palms downwards in pronation, again comparing the sides.



5.13. Movements (7): *Supination:*

Supination may be recorded. Give the patient a pencil to hold, and note the angle from the vertical that can be achieved.

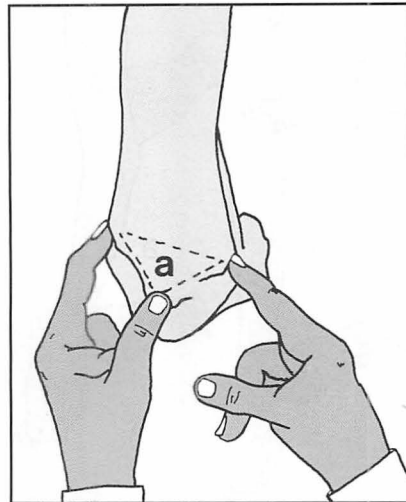
Normal range = 80°.



5.14. Movement (8): *Pronation:* This may be measured in the same way.

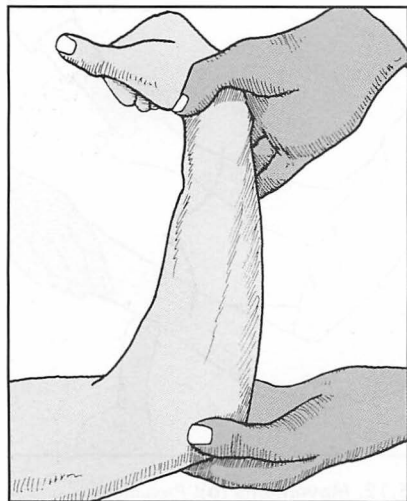Normal range = 75°.

Pronation/supination movements may be reduced after fractures at the elbow, in the forearm and at the wrist (e.g. most commonly after Colles' fracture). Loss may also occur after dislocation of the elbow, and rheumatoid and osteoarthritis. Pure supination loss may occur in children with pulled elbow.



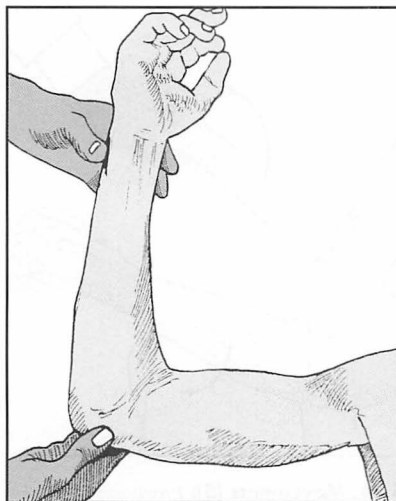
5.15. Palpation (1):

Begin by locating the epicondyles and the olecranon. If in doubt, flex the elbow and note the equilateral triangle normally formed by these structures. This relationship is disturbed in elbow subluxations.



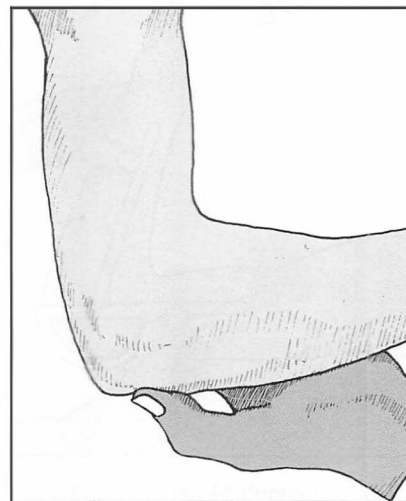
5.16. Palpation (2):

Palpate the lateral epicondyle with the thumb. Sharply localized tenderness here or just distal is almost diagnostic of tennis elbow. Carry out confirmatory tests (22 et seq.). Note that after the injection of hydrocortisone locally (e.g. for tennis elbow) tenderness becomes more diffuse.



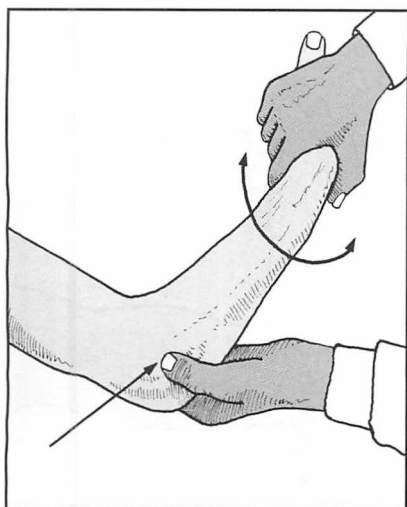
5.17. Palpation (3):

Palpate the medial epicondyle. Tenderness occurs here in golfer's elbow, tears of the ulnar collateral ligament, and in injuries of the medial epicondyle.

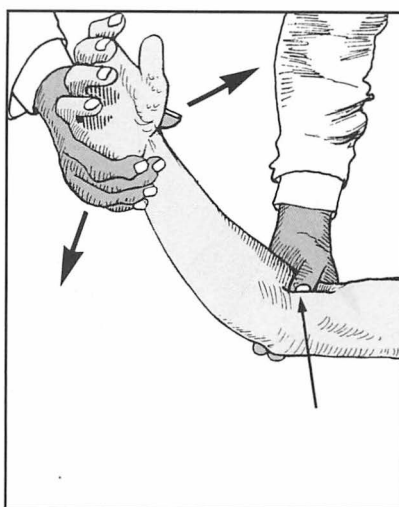


5.18. Palpation (4):

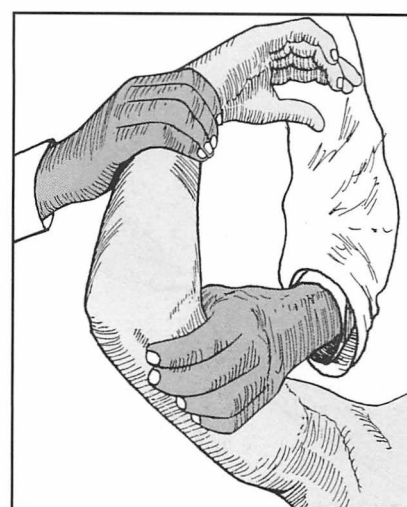Tenderness over the olecranon is uncommon, apart from after fracture and infected olecranon bursitis, both of which are usually obvious.



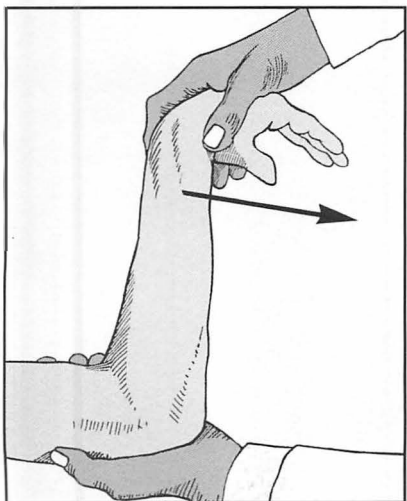5.19. Palpation (5): Press the thumb firmly into the space on the lateral side of the elbow between the radial head and humerus. Now pronate and supinate the arm. Tenderness here is common after injuries of the radial head, osteoarthritis and osteochondritis dissecans.



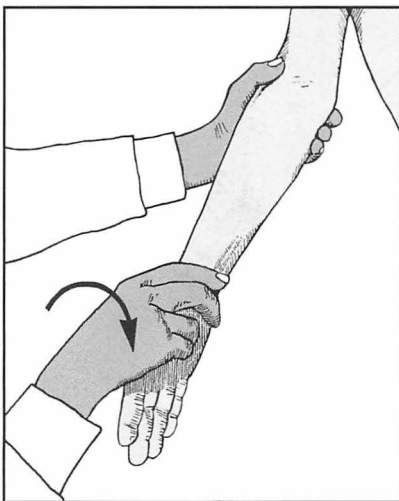5.20. Palpation (6): Palpate the front of the elbow on both sides of the biceps tendon while flexing and extending the elbow through 20°. Note the presence of any abnormal masses (e.g. myositis ossificans, loose bodies).



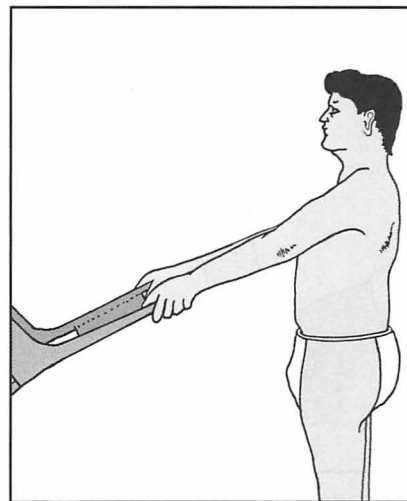
5.21. Palpation (7): Roll the ulnar nerve under the fingers behind the medial epicondyle. Note whether there is any difference between the sides. If indicated, carry out a fuller examination of the nerve.



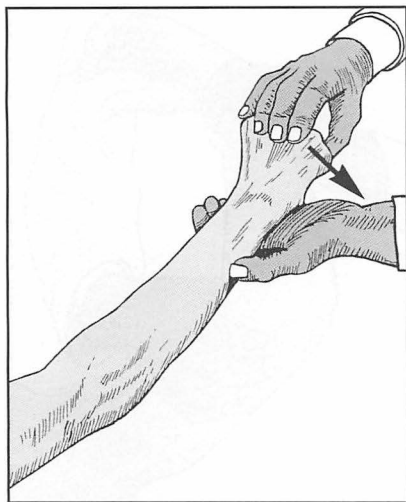5.22. Additional tests: Tennis elbow (1): Flex the elbow and fully pronate the hand. Now extend the elbow. Pain over the lateral epicondyle is almost diagnostic of tennis elbow.



5.23. Tennis elbow (2): As an alternative, pain may be sought by pronating the arm with the elbow fully extended.

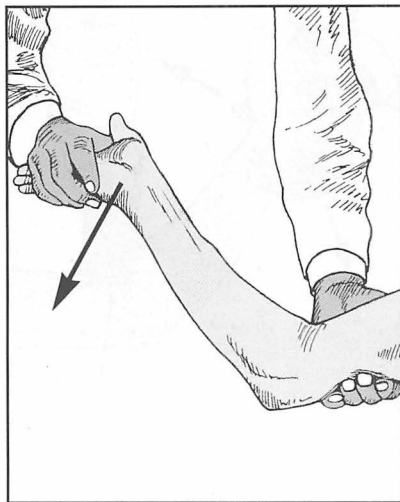


5.24. Tennis elbow (3): The chair test. Ask the patient to attempt to lift a chair (of about 3.5 kg in weight) with the elbows extended and the shoulders flexed to 60°. Difficulty in performing this manoeuvre, with complaint of pain on the lateral aspect of the affected elbow, is suggestive of tennis elbow.

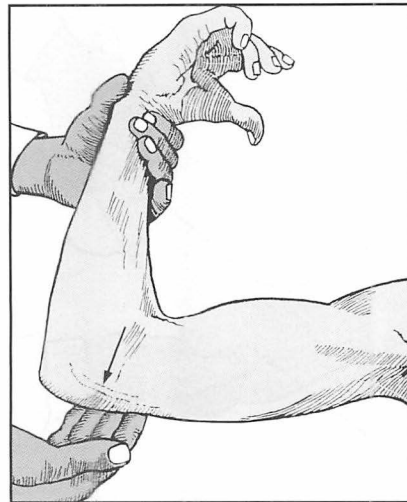


5.25. Tennis elbow (4): Thomsen's test: Ask the patient to clench the fist, dorsiflex the wrist and extend the elbow. Try to force the hand into palmar flexion while the patient resists. Severe pain over the external epicondyle is again most suggestive of tennis elbow.

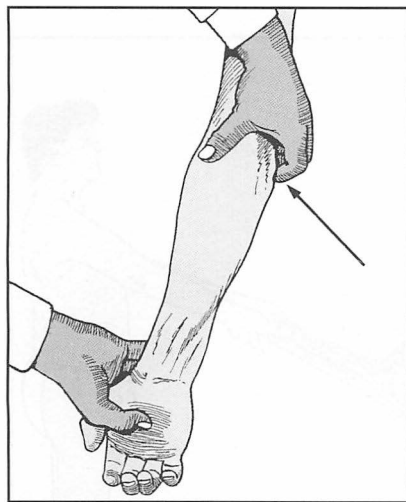
(5): Repeat, this time attempting to flex the extended middle finger rather than the wrist.



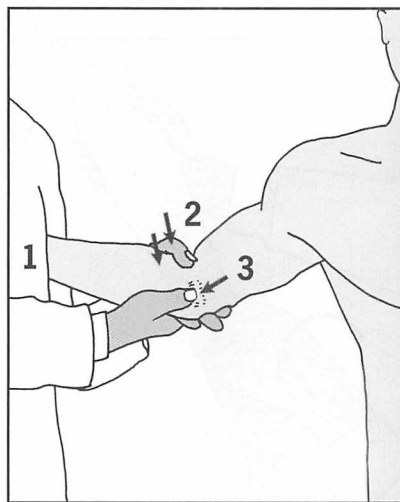
5.26. Additional tests: golfer's elbow: Flex the elbow, supinate the hand, and then extend the elbow. Pain over the medial epicondyle is very suggestive of golfer's elbow.



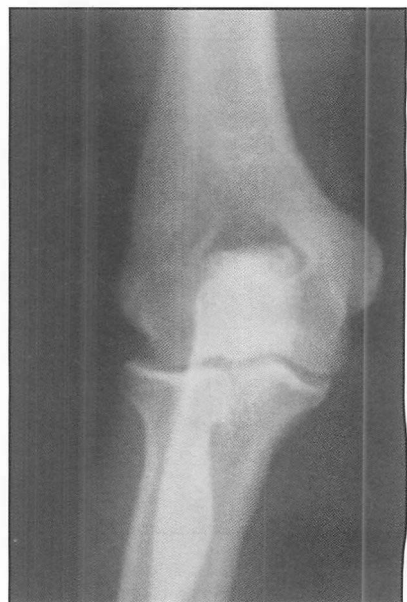5.27. Additional tests: ulnar nerve (1): Inspect the medial side of the elbow carefully while the patient flexes and extends the joint. The nerve is visible in the thin patient, and displacement on movement may be obvious.



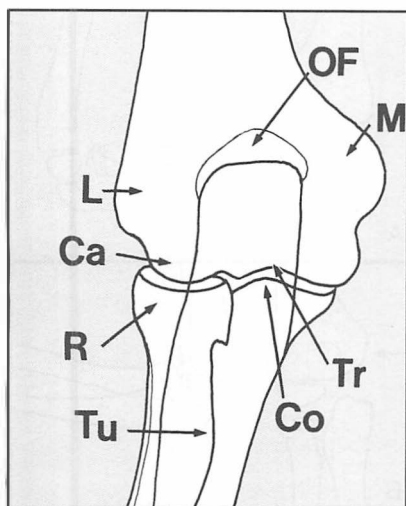
5.28. Ulnar nerve (2): Palpate again and note the extent of any tenderness, and whether the nerve is thickened. Look again for cubitus valgus. Look for evidence of ulnar nerve palsy.



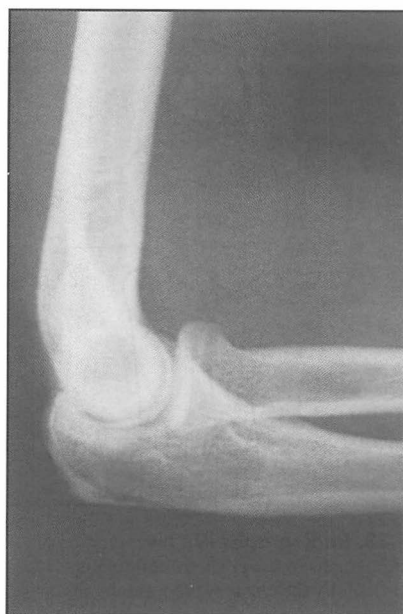5.29. Additional tests: elbow instability: Both valgus and varus instability may be tested by stressing the joint in extension and 30° flexion (as performed for the collateral ligaments in the knee). Alternatively, for valgus instability (which is the commonest), anchor the patient's arm in 30° elbow flexion against your side (1), apply a valgus stress (2), and feel for any gap opening up on the medial side (3).



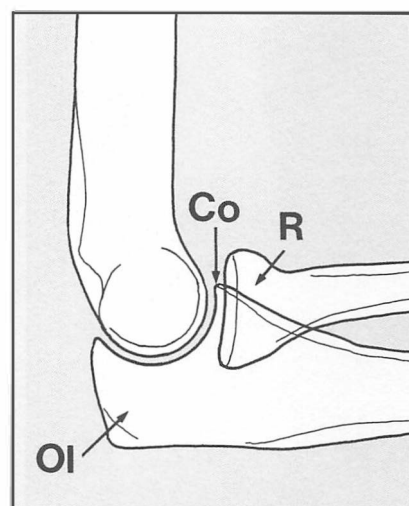
5.30. Radiographs (1): Normal anteroposterior radiograph of the elbow.



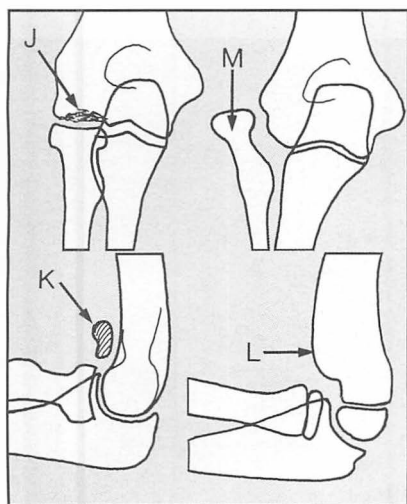
5.31. Radiographs (2): In examining the standard AP view trace out the outline of (M), the medial epicondyle; (OF) the olecranon and coronoid fossae; (L) the lateral epicondyle; (Ca) the capitulum; (R) the radial head; (Tu) the tuberosity of the radius; (Co) the coronoid process of ulna; (Tr) the trochlea.



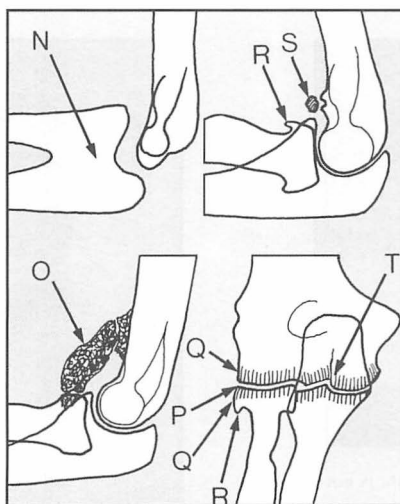
5.32. Radiographs (3): Normal lateral radiograph of the elbow.



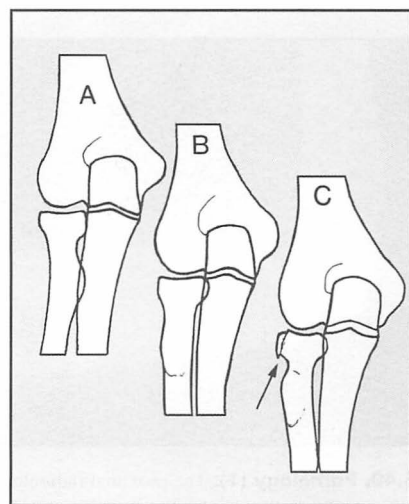
5.33. Radiographs (4): In examining the standard lateral projection, note (R) the radial head; (Co) the coronoid process of the ulna; (Ol) the olecranon.



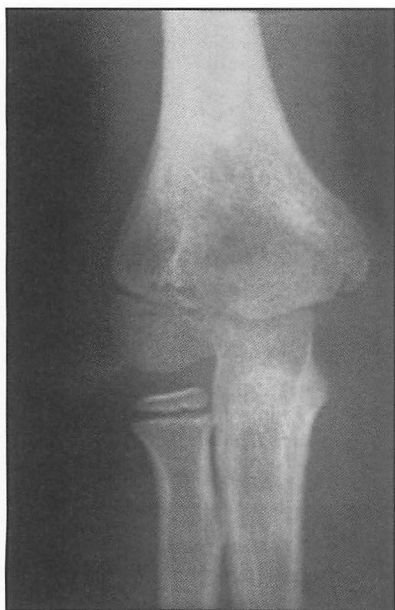5.34. Radiographs (5): Look for (J) any defects in the capitulum suggesting osteochondritis dissecans; (K) loose bodies (usually secondary to osteoarthritis or osteochondritis); (L) incompletely remodelled supracondylar fracture (usually associated with loss of flexion); (M) old Monteggia fracture (fracture of ulna and dislocation head of radius), usually associated with reduction of pronation and supination.



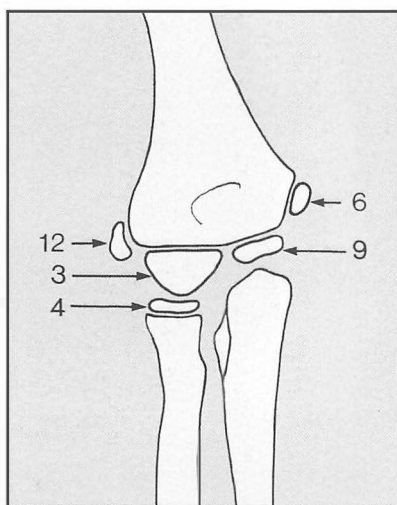
5.35. Radiographs (6): Note the presence of (N) a congenital synostosis (with inevitable loss of pronation and supination); (O) myositis ossificans (with clinically restriction of flexion). Note any osteoarthritic changes with, for example, (P) joint space narrowing, (Q) bony sclerosis of the joint margins, (R) osteophytes, (S) loose body formation, or (T) evidence of previous fracture.



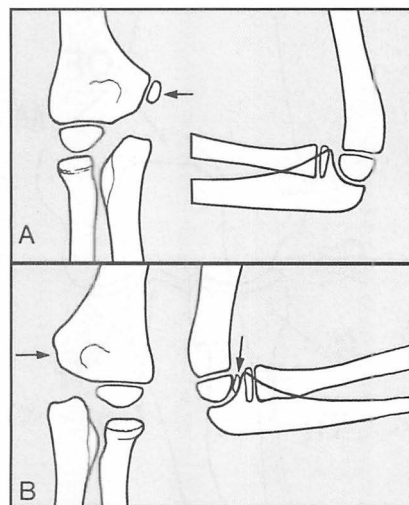
5.36. Radiographs (7): Where the radial head is suspect, radiographs should be taken in the anteroposterior plane (A) in midposition, (B) in supination, (C) in pronation. These may bring an area of osteochondritis of the radial head or an old fracture into profile.



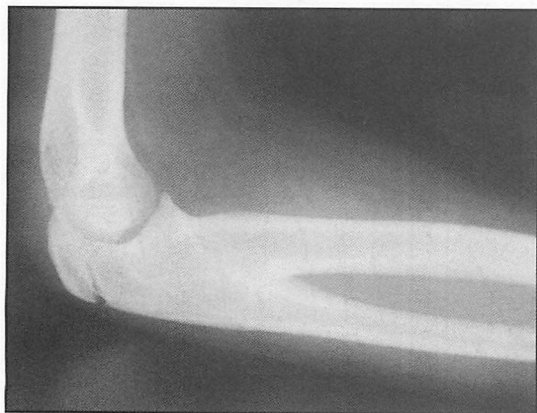5.37. Radiographs (8): Normal anteroposterior radiograph of the elbow of a child of 8.



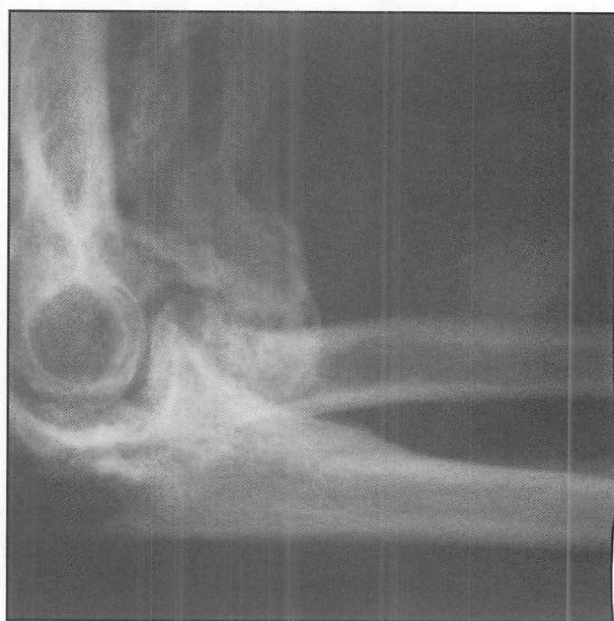
5.38. Radiographs (9): Interpretation of radiographs of the elbow in children is made difficult by the changes produced by the successive appearance of ossification in the epiphyses (and there are both gender and race variations). The old mnemonic 'cite' (capitulum, internal epicondyle, trochlea, external epicondyle) for the appearance of the epiphyseal centres at 3, 6, 9 and 12 years, is sufficiently accurate for normal purposes.



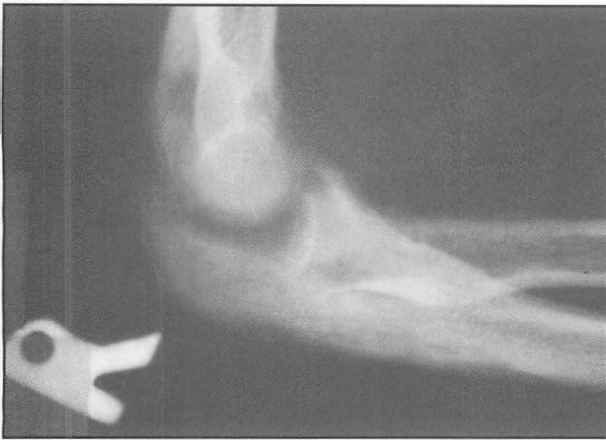5.39. Radiographs (10): If there is any doubt, radiographs of both sides should be taken. Note that if a child over the age of 6 has injured the elbow there is every likelihood that the medial epicondyle has become displaced into the joint if it *cannot* be seen in the anteroposterior view, or if it *can* be seen in the lateral. (A) Normal, (B) displaced.



5.40. Pathology (1): The proximal radioulnar joint is not present, and no pronation/supination movements are possible. The epiphysis of the olecranon has not yet united.
Diagnosis: congenital radioulnar synostosis.

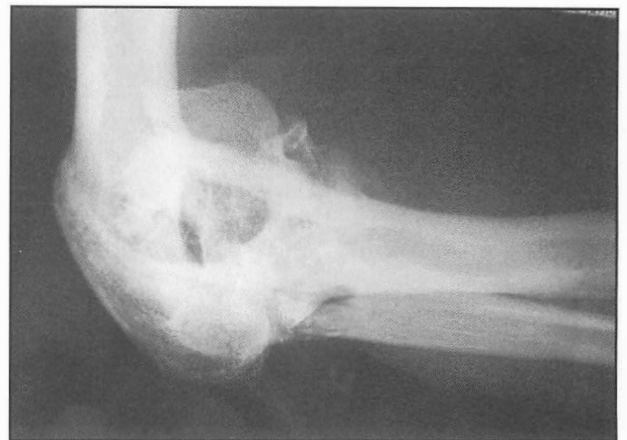

5.41. Pathology (2): After an elbow injury a large mass of bone has formed in the front of the joint, and has virtually obliterated all movements.
Diagnosis: myositis ossificans.



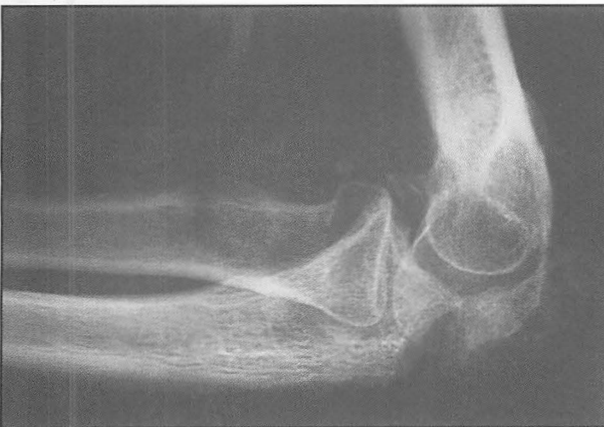5.42. Pathology (3): All the joint surfaces are irregular, and the bone texture has a moth-eaten appearance.

Diagnosis: septic (infective) arthritis of the elbow.



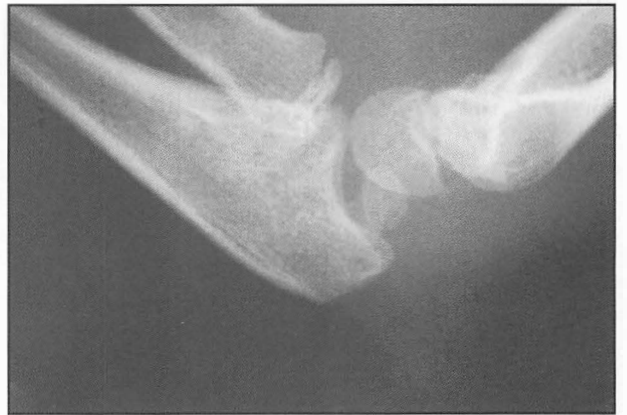5.43. Pathology (4): There is gross disturbance of the architecture of the elbow joint, and bony ankylosis has occurred.

Diagnosis: in this case the cause was a gunshot wound to the elbow, with extensive bone damage.



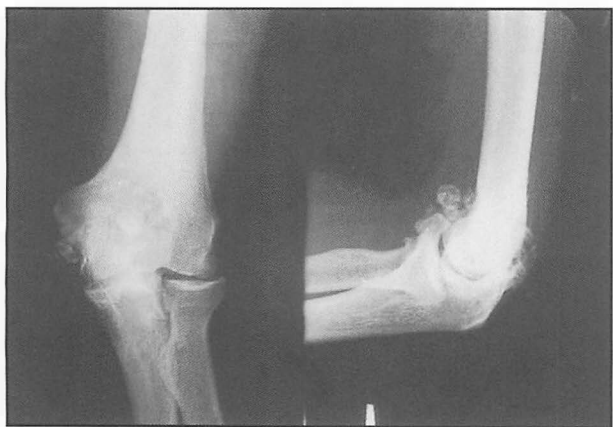5.44. Pathology (5): There is an obvious defect in the olecranon, with separation of the fragments. The complaints was of weakness of elbow movements.

Diagnosis: ununited fracture of the olecranon. Injuries of this type may have surprisingly few symptoms, but there is often weakness (as was the case here) and restriction of extension.



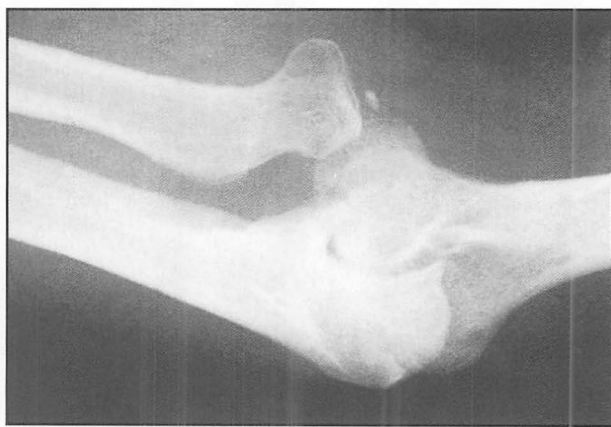5.45. Pathology (6): The radiograph is of an acute case where, following a dislocation of the elbow, there was marked restriction of movements.

Diagnosis: the medial epicondyle has displaced and become trapped in the joint.



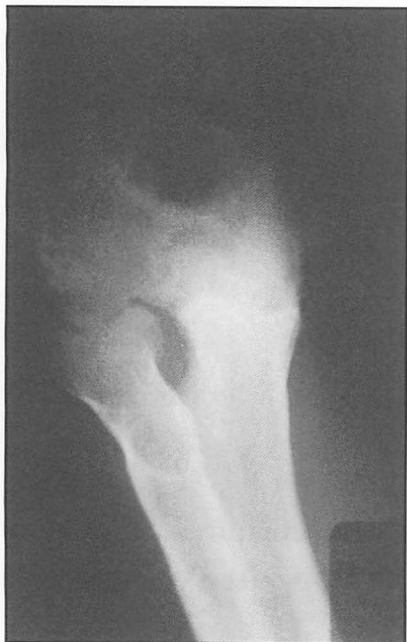5.46. Pathology (7): Both projections show narrowing of the joint space between the ulna and the humerus, with a degree of marginal bone sclerosis. In the lateral view there is lipping of the olecranon, and multiple loose bodies are present.

Diagnosis: osteoarthritis of the elbow with loose body formation. Synovial chondromatosis may have a similar appearance.



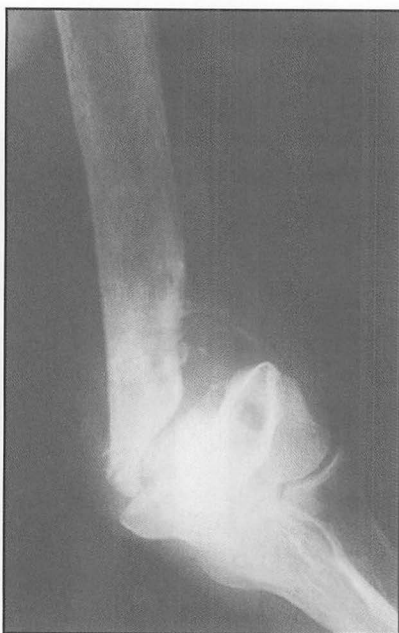5.47. Pathology (8): The radial head has lost its normal site of articulation with the capitulum, and there is a cubitus valgus deformity. The appearances are of a long-standing lesion.

Diagnosis: this is an old Monteggia fracture dislocation of the elbow. The ulnar fracture has healed and is no longer visible, but the dislocation of the radial head persists. In this case there was an associated tardy ulnar nerve palsy.



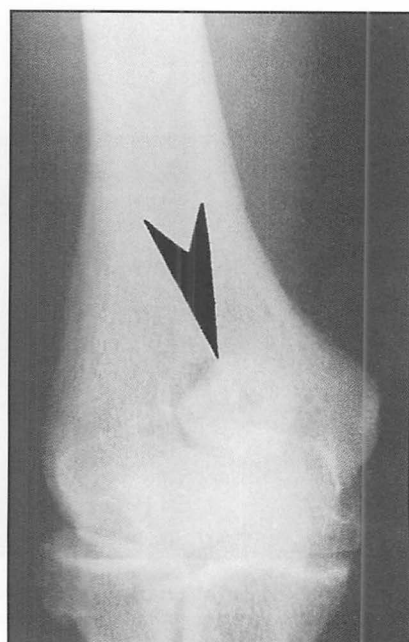
5.48. Pathology (9): The articular surfaces between the humerus and ulna have been virtually obliterated following a long period of pain, swelling and loss of function in the elbow.

Diagnosis: in this case this was due to tuberculous infection of the joint, and ankylosis has resulted.



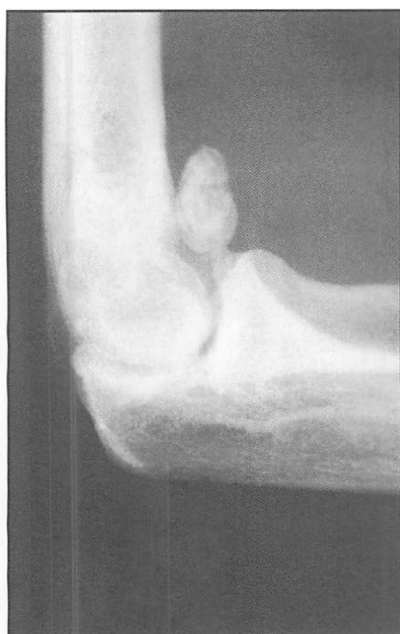5.49. Pathology (10): There is a gap between the distal articular complex of the humerus and the distal humeral shaft. There was little movement left in the elbow joint itself, but there was a limited range of rather unstable movements proximal to it.

Diagnosis: this is an example of long-standing non-union following a supracondylar fracture of the humerus.



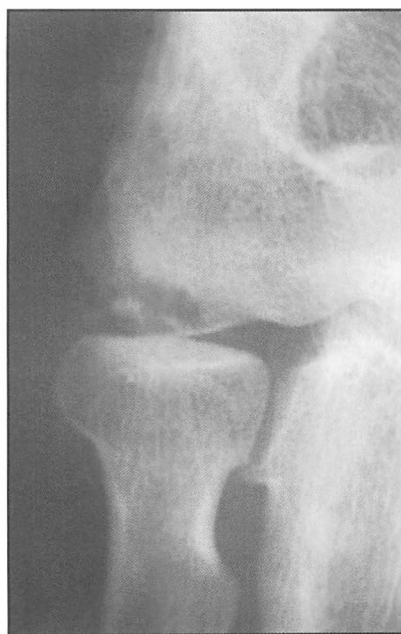5.50. Pathology (11): The arrow points to an abnormality in the region of the coronoid fossa. This was associated with severe restriction of elbow flexion.

Diagnosis: this is a large loose body. In the single view the source is not obvious, but the most likely causes are osteochondritis dissecans or osteoarthritis. The loss of flexion is due to a purely mechanical block to movement.



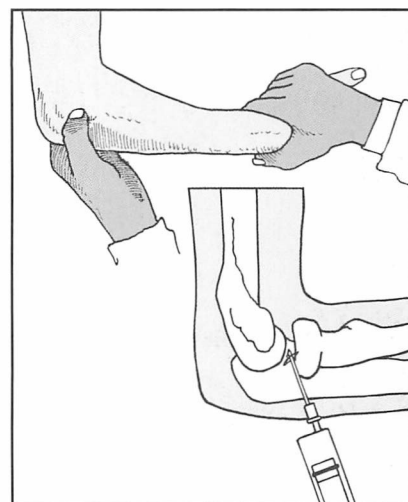
5.51. Pathology (12): This lateral radiograph shows a large loose bony mass lying in the front of the elbow joint.

Diagnosis: loose body, probably secondary to osteochondritis dissecans or osteoarthritis. In some cases loose bodies of this type may be extruded and come to lie in the brachialis muscle, where their mechanical effects on elbow flexion are less obtrusive.



5.52. Elbow radiographs: Examples of pathology (13): This radiograph shows an irregularity of the capitulum involving its articular surface. This was associated with aching pain in the joint of several months' duration.

Diagnosis: osteochondritis of the capitulum.



5.53. Aspiration of the elbow joint: The most direct and safest approach is from the lateral side. Flex the elbow to 90° to locate the radial head, pronate and supinate the arm, and feel with the thumb for its rotation. After infiltration of the area with local anaesthetic, introduce the aspirating needle in the area of the palpable depression between the proximal part of the radial head and the capitulum.

CHAPTER

6

The wrist

Complications occurring after Colles' fracture 90

Ganglions 90

de Quervain's disease 91

Extensor tenosynovitis 91

Osteoarthritis of the wrist 91

Rheumatoid arthritis 91

Carpal tunnel syndrome 92

Ulnar tunnel syndrome 92

Ehlers-Danlos syndrome 93

Tuberculosis of the wrist 93

Carpal instabilities 93

Inspection 94-95

Palpation 95-96

Movements 96-98

Joint hypermobility 97

Crepitus 99

de Quervain's tenosynovitis 99

Carpal tunnel syndrome 99-101

Radioulnar laxity 101

Carpal instability 102

Radiographs 102-107

Pathology 102-107

Aspiration of the wrist 107

Study of the wrist cannot be separated from that of the hand, and in many cases careful examination of both may be required.

COMPLICATIONS OCCURRING AFTER COLLES' FRACTURE

Considering the incidence of Colles' fracture, the commonest of all fractures, it is surprising that complications from this injury are not seen more frequently; nevertheless, they do occur and are of importance. Excluding initial weakness of the wrist, the commonest complaints are of residual deformity, restriction of movements, and pain.

The common deformities are radial deviation of the hand and prominence of the ulna. Owing to resorption of bone at the fracture site during healing, there is shortening of the radius with radial deviation of the hand. This may be aggravated by a poor reduction. At the back of the wrist, the head of the ulna becomes prominent. (Gross subluxations of the ulna of this pattern are sometimes referred to as Madelung's deformity; this term was used initially to describe a condition occurring in adolescents where, following some disturbance of growth in the distal radial epiphysis, often idiopathic in origin, the ulna becomes relatively prominent.)

In all Colles' fractures there is disturbance of the inferior radioulnar joint. In some cases this is responsible for persisting pain and tenderness just lateral to the ulnar styloid.

Again, disruption of the inferior radioulnar joint is partly responsible for loss of movements in the wrist. This certainly accounts for the loss of supination that causes patients the greatest concern. Although restriction of dorsiflexion occurs after most Colles' fractures, this seldom gives rise to any functional problems.

Two other important complications are seen after Colles' fracture: (a) delayed rupture of extensor pollicis longus tendon may occur some months after injury and is due to ischaemia or attrition of the tendon, and (b) Sudeck's atrophy (complex regional pain syndrome), which is usually diagnosed some weeks after cast fixation has been discontinued, and which is characterized by marked swelling of the wrist, hand and fingers, gross stiffness of the fingers, and decalcification of the carpal bones which is obvious on radiographs of the region.

Regarding treatment of these complications, the patient is generally advised to accept minor degrees of residual deformity and stiffness. When there is gross prominence of the ulna causing symptoms, excision of the distal end of the bone may be advised. Ruptures of extensor pollicis longus are treated by tendon transfer (extensor indicis proprius is generally employed). Sudeck's atrophy generally requires intensive physiotherapy, and often other measures (which may include sympathetic blockade with guanethidine sulphate) if much permanent stiffness is to be avoided.

GANGLIONS

Ganglions are extremely common about the wrist and hand. In many cases they may have a tenuous communication with a carpal joint or tendon sheath. Some are spherical in shape, firm, and have no obvious connection to other structures. Tiny ganglions of this type are common in the fingers. Fluctuations in the size of ganglions and their rupture from trauma is well known, and diagnosis is not usually difficult unless the swelling is small.

This applies in particular to small ganglions on the back of the wrist, arising from the radiocarpal joint; local swelling and tenderness may only be obvious when the wrist is palmarflexed. This type of ganglion is often the cause of persisting wrist pain in young women: their symptoms are often labelled as functional when this difficulty in examination has not been appreciated. Excision of most ganglions is advised, and this is essential if the ganglion is producing nerve complications (e.g. if a ganglion in the ulnar tunnel in the hand is producing ulnar motor and sensory loss).

DE QUERVAIN'S DISEASE

Tenosynovitis involving abductor pollicis longus and extensor pollicis brevis is known as de Quervain's disease. It occurs in the middle-aged. The walls of the fibrous tendon sheaths on the lateral aspect of the radius are greatly thickened, and there is often marked underlying swelling. The patient complains of pain on certain movements of the wrist, and weakness of grip. Treatment is by splitting the lateral wall of the sheath.

EXTENSOR TENOSYNOVITIS

Acute frictional tenosynovitis occurs most frequently in the 20–40-year age group, generally following a period of excess activity. Any or all of the extensor tendons may be involved. The condition has a benign course and usually settles if the wrist is immobilized in a cast for 3 weeks.

OSTEOARTHRITIS OF THE WRIST

Osteoarthritis of the wrist is surprisingly uncommon considering the frequency with which the joint is involved in fractures. It is seen most often after avascular necrosis of the scaphoid following fracture of that bone, non-union of a scaphoid fracture, comminuted fractures involving the articular surface of the radius, and Kienbock's disease (spontaneous avascular necrosis of the lunate).

Where symptoms are severe, fusion of the wrist (radiocarpal joint) may be undertaken.

RHEUMATOID ARTHRITIS

Rheumatoid arthritis of the wrist is common, and extensive synovial thickening of the joint and related tendon sheaths leads to gross swelling, increased local heat, pain and stiffness. Fluctuation can sometimes be transmitted from just above the wrist to the palm, the synovial fluid being displaced from one level to the other underneath the flexor retinaculum (compound palmar ganglion). With progressive joint involvement the carpus tilts into ulnar deviation and subluxes in a palmar direction. The head of the ulna displaces dorsally, disrupting the inferior radioulnar joint and causing painful and reduced pronation and supination. Rarely tuberculosis of the wrist may produce a similar clinical picture, but the multifocal nature of rheumatoid arthritis usually makes differentiation easy.

As far as treatment is concerned, local measures can include the use of night splints; later, synovectomy of the wrist and of the inferior radioulnar joints may be effective in slowing the progress of the condition. Where

pronation and supination are particularly affected, excision of the distal end of the ulna may give worthwhile functional improvement. Where there is gross destruction of the joint and marked local symptoms, fusion may have to be considered.

CARPAL TUNNEL SYNDROME

This condition occurs most commonly in women in the 30–60-year age group. Basically there is compression of the median nerve, which leads to symptoms and signs related to its distribution. In some cases premenstrual fluid retention, early rheumatoid arthritis with synovial tendon sheath thickening, and old Colles' or carpal fractures may be responsible by restricting the space left for the nerve in the carpal tunnel. The condition is sometimes seen in association with myxoedema, acromegaly and pregnancy; often, however, no obvious cause can be found, and it is very frequently bilateral. The patient complains of paraesthesia in the hand: often all the fingers are claimed to be involved, although theoretically at least the little finger should always be spared. Paraesthesia may also radiate proximally to the elbow. There may be pain in the same areas, and weakness in the hand. The symptoms may become most marked in the early hours of the morning, often waking the patient from sleep and causing her to shake the hand or hang it over the side of the bed. In many cases the history and results of the clinical examination are unequivocal. In others it may be difficult to differentiate the patient's symptoms from those produced by cervical spondylosis, and indeed both conditions may be present at the same time: a trial period of immobilization of the wrist in a cast or the use of a cervical collar may be helpful. Nerve conduction-time tests, showing a delay at the wrist, may be used to confirm the diagnosis. These studies are being employed with increasing frequency in the practice of defensive medicine.

Most cases are treated quite simply by division of the flexor retinaculum, which forms the roof of the carpal tunnel, thereby relieving pressure on the nerve; the procedure may be performed arthroscopically through a minimal incision. Conservative measures may be tried, especially in cases occurring in pregnancy, when diuretics may be prescribed with success. Other measures include the use of night splints and injections of hydrocortisone.

Note that on rare occasions the median nerve may be compressed *proximal to the carpal tunnel*. Above the elbow this may be due to a supracondylar bony spur (obvious on radiographs); just distal to the elbow, by the origin of pronator teres; and in the proximal part of the forearm by the sublimis. Proximal lesions of the median nerve give rise to the *anterior interosseous nerve syndrome*.

ULNAR TUNNEL SYNDROME

The ulnar nerve may be compressed as it passes through the ulnar carpal canal between the pisiform and the hook of the hamate. Both the sensory and the motor divisions of the nerve may be affected, but often one only is involved. The symptoms therefore may include small muscle wasting and weakness in the hand, with sensory disturbance on the volar aspect of the little finger. The sensory supply to the dorsum of the hand is given off in the distal forearm, so that sensory disturbance on the dorsum of the hand and little finger excludes a lesion at this level. In all cases every effort should be

made to exclude a more proximal cause for the patient's symptoms (e.g. ulnar neuritis at the elbow, and cervical spondylosis). Nerve conduction studies are often of particular value in this situation. The commonest causes of nerve involvement at the wrist are ganglionic compression, occupational trauma, ulnar artery disease, and old carpal or metacarpal fractures.

On the establishment of a firm diagnosis of a localized lesion in the ulnar tunnel, exploration and decompression of the nerve are carried out.

EHLERS-DANLOS SYNDROME

This is the name given to a number of closely related connective tissue disorders which are due to a collagen abnormality. The condition is comparatively rare (50 000 cases are said to be affected in the UK), with a strong (autosomal dominant) hereditary tendency. It is found in association with Marfan's syndrome and osteogenesis imperfecta. *The skin* has a velvety feel and is fragile and hyperelastic; when grasped it can be raised and stretched by a remarkable amount. *Wound healing* is poor, leading to abnormal and somewhat keloid scarring, evidence of which may be widespread. Cases vary in severity, but in some healing may be so poor that surgery is contraindicated. *The walls of blood vessels* are affected, and bruising is a common problem. *Ligaments* lose their resistance to stretching, so that there is usually a striking increase in the range of movements in the affected joints; this is often well in excess of the normal range (sometimes to a grotesque degree), and there may be instability, leading to sprains and dislocations. There is no effective treatment.

TUBERCULOSIS OF THE WRIST

Tuberculosis of the wrist is now rare in Britain. Marked swelling of the joint is followed by muscle wasting in the forearm, erosion, destruction and anterior subluxation of the carpus. The diagnosis is confirmed by synovial biopsy. Monoarticular rheumatism is the only other condition in this area that is likely to cause difficulty in diagnosis.

CARPAL INSTABILITIES

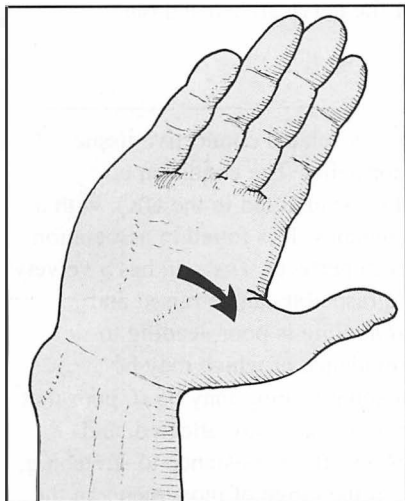
A carpal instability is a condition in which there is a loss of normal carpal alignment which develops at an early or a late stage after an injury. Untreated cases may lead to the development of osteoarthritis in the wrist.

In *static carpal instabilities* there is an abnormal carpal alignment, which can be seen by careful study of standard AP and lateral radiographs of the wrist.

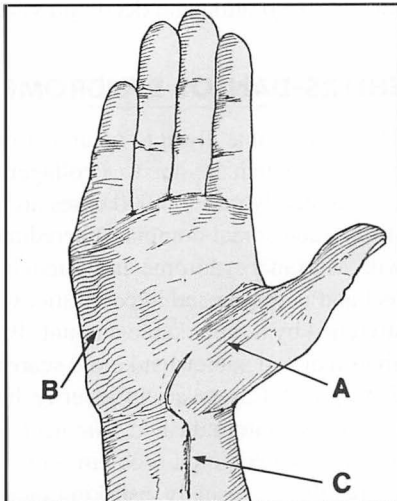
In *dynamic carpal instabilities* routine radiographs are normal. The patient is usually able to toggle his carpal alignment from normal to abnormal and back. To establish the diagnosis in this situation, lead markers may be placed on the skin over points of local tenderness, and radiographs taken in both stable and unstable positions.

In the case of scapholunate instability (scapholunate dissociation), the commonest of these problems, AP views of the supinated wrist in both radial and ulnar deviation are usually diagnostic. Other investigations include examination of the wrist in motion using an image intensifier and radioisotope bone scans.

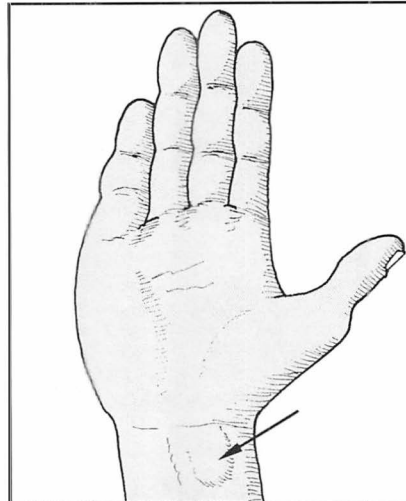
Acute cases may be stabilized by manipulative reduction and the insertion of K-wires, or by ligamentous repair. In chronic cases reattachment of the avulsed ligaments may be carried out, but where there are arthritic changes and subluxation a salvage procedure may have to be considered.



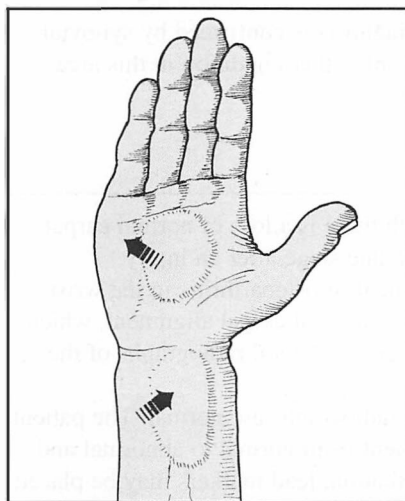
6.1. Inspection: front (1): Note any deformity of the wrist, e.g. radial deviation of the hand, common after Colles' fracture, and striking in congenital absence of the radius. Note any ulnar deviation, common in rheumatoid arthritis.



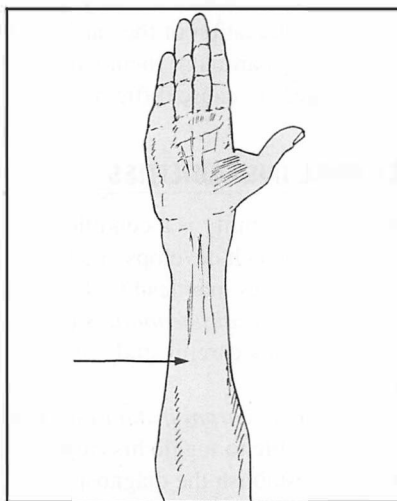
6.2. Front (2): Note (A) thenar wasting in hand, (B) hypothenar wasting, (C) scars suggestive of previous surgery or injury.



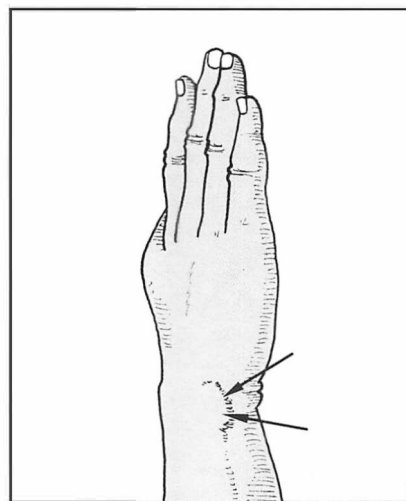
6.3. Front (3): Note any localized swellings suggestive of ganglion, rheumatoid nodule or tumour.



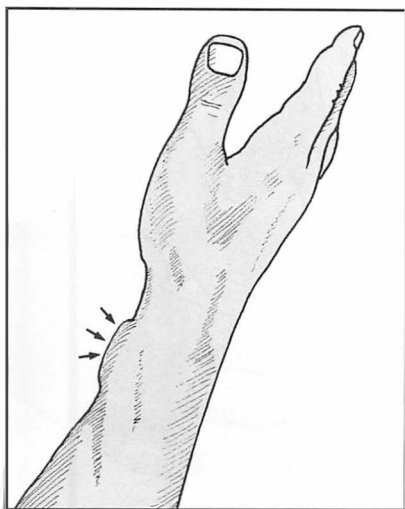
6.4. Front (4): If there is swelling at the wrist and also in the palm, try to demonstrate cross-fluctuation. This occurs in compound palmar ganglion, seen most often in rheumatoid arthritis and tuberculosis.



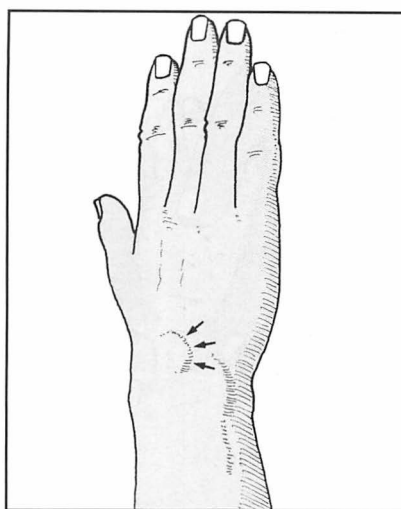
6.5. Front (5): Note the presence of muscle wasting in the forearm, also suggestive of rheumatoid arthritis and tuberculosis. Widespread bilateral wasting is common in many neurological conditions (e.g. after cervical spine injuries, multiple sclerosis etc.) and in the muscular dystrophies.



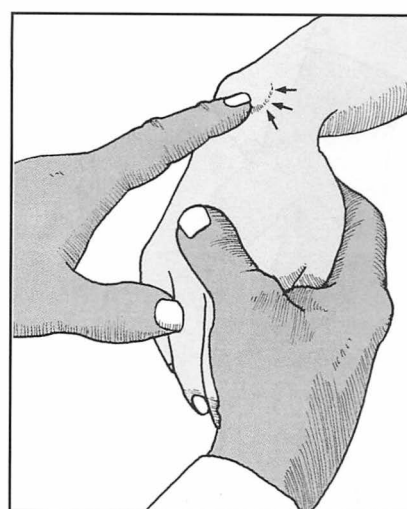
6.6. Inspection: side (1): Note any undue prominence of the ulna (common after Colles' fracture or Madelung deformity), any anterior tilting of the plane of the wrist (e.g. after Smith's fracture), backward tilting (post Colles' fracture) or anterior subluxation (rheumatoid arthritis, old carpal injury or infective arthritis).



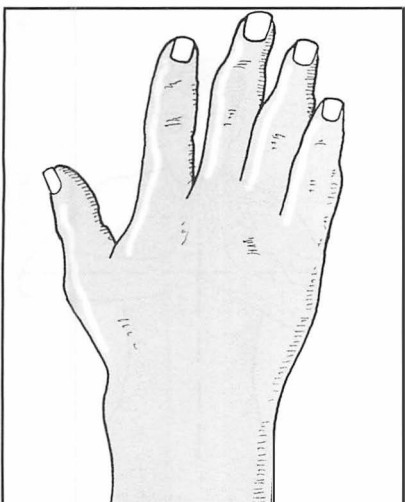
6.7. Side (2): Swelling over the lateral aspect of the distal radius occurs in de Quervain's tenosynovitis. If this is present, carry out additional tests (see Frame 6.34).



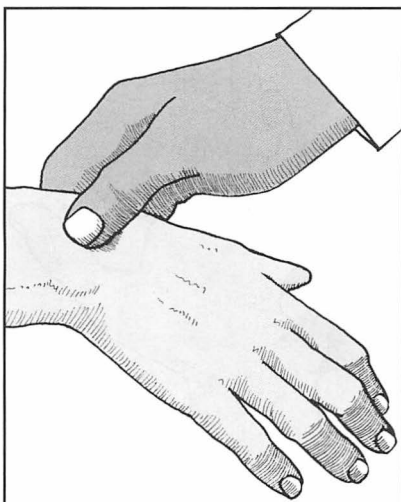
6.8. Inspection: dorsum (1): Ganglions in relation to the wrist, carpus and extensor tendons may be quite obvious on inspection.



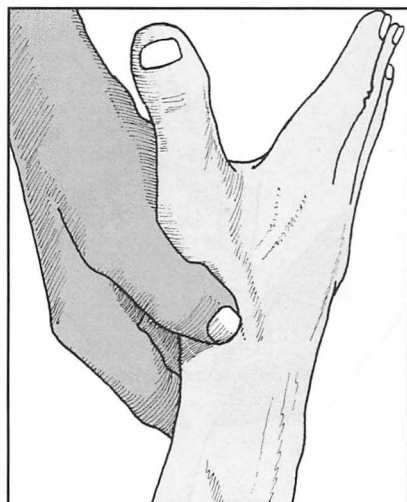
6.9. Dorsum (2): Palmarflex the wrist and compare one side with the other. Small ganglions between the radius and carpus are a common source of obscure wrist pain. Palmarflexion makes such ganglions obvious, and the presence of local tenderness should confirm the diagnosis.



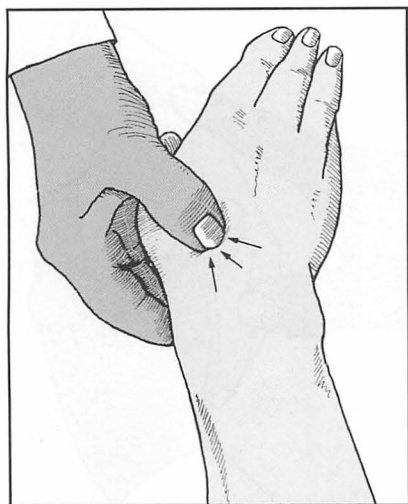
6.10. Dorsum (3): Swelling of the wrist, hand and fingers, with a glazed appearance of the skin, diffuse tenderness, pain and stiffness is typical of Sudeck's atrophy (complex regional pain syndrome), which may occur as a sequel to Colles' fracture or carpal injury.



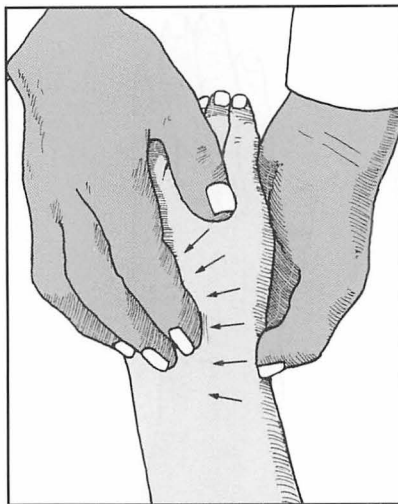
6.11. Palpation (1): Pain in the wrist persisting after a Colles' fracture, and due to disruption of the inferior radioulnar joint, is always associated with well localized tenderness at that site.



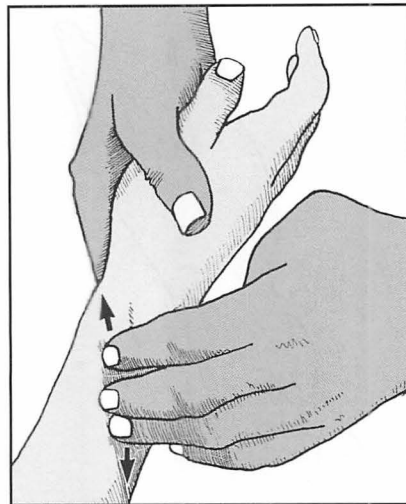6.12. Palpation (2): Tenderness in the anatomical snuffbox occurs classically after scaphoid fractures, but in fact is present after many wrist sprains and other minor injuries.



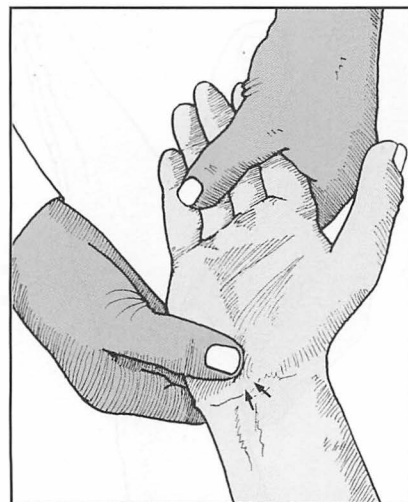6.13. Palpation (3): To help distinguish a sprain from fracture, also palpate the *dorsal* surface of the scaphoid. Tenderness here is usually present after fractures but not sprains. Scaphoid radiographs and plaster fixation are necessary in all cases of suspected fracture.



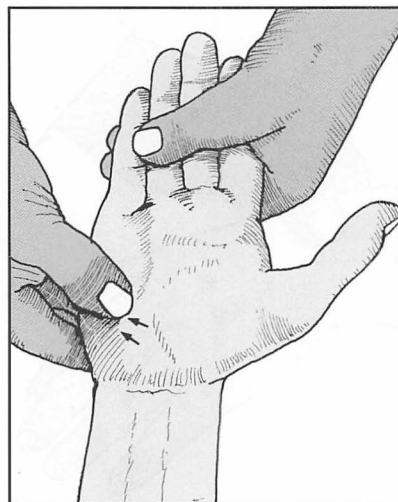6.14. Palpation (4): Diffuse tenderness is common in all inflammatory lesions (e.g. rheumatoid arthritis and tuberculosis of the wrist) and in Sudeck's atrophy (complex regional pain syndrome).



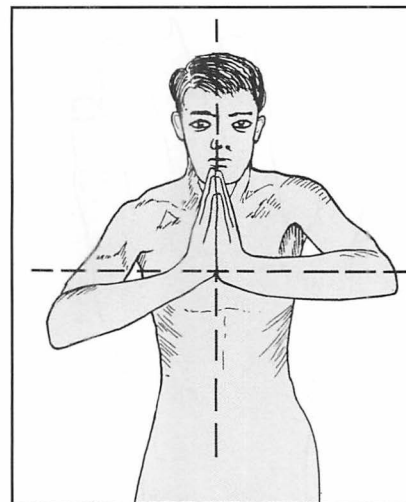
6.15. Palpation (5): Tenderness localized to the sheaths of abductor pollicis longus and extensor pollicis brevis is found in de Quervain's tenosynovitis. There is often striking local thickening of the tendon sheaths over the dorsolateral aspect of the radius.



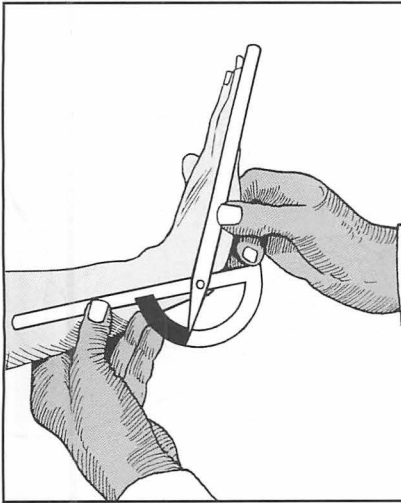
6.16. Palpation (6): Tenderness over the median nerve, with the production of paraesthesia in the fingers and lateral side of the hand, is suggestive of the carpal tunnel syndrome. (See also Frame 6.36 et seq.)



6.17. Palpation (7): In the same way, tenderness with paraesthesia on pressure over the ulnar nerve is suggestive of the ulnar tunnel syndrome.



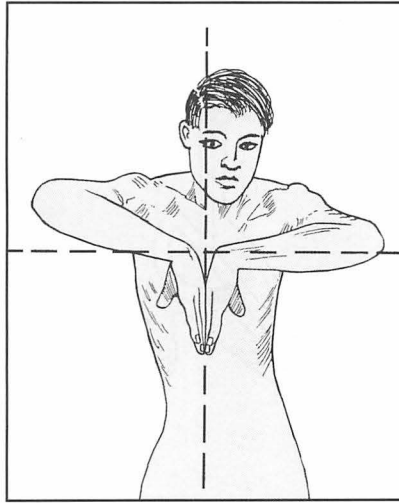
6.18. Movements: dorsiflexion (1):
Screening test: Ask the patient to press the hands together in the vertical plane and to raise the elbows to the horizontal. Loss of any dorsiflexion should be obvious. The commonest cause is stiffness after a Colles' fracture.



6.19. Dorsiflexion (2): Dorsiflexion may be measured with a goniometer.

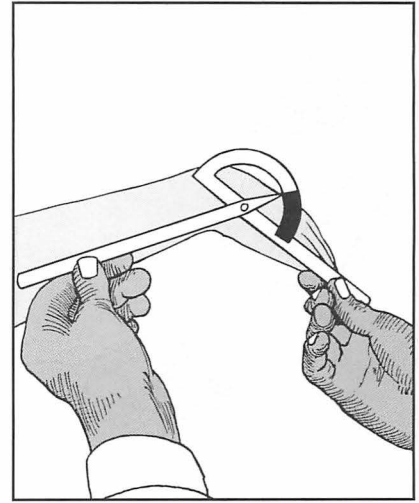
Normal range = 75°.

Hypermobility is not uncommon in women. If hypermobility is gross, however, other joints should be examined to exclude a joint laxity syndrome.



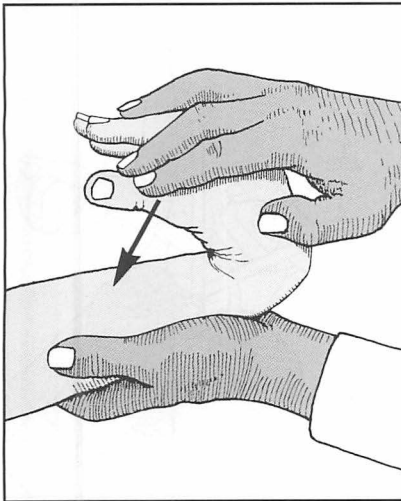
6.20. Palmarflexion (1): Screening test:

Ask the patient to put the backs of the hands in contact, and then to bring the forearms into the horizontal plane. Loss of palmarflexion should be obvious.

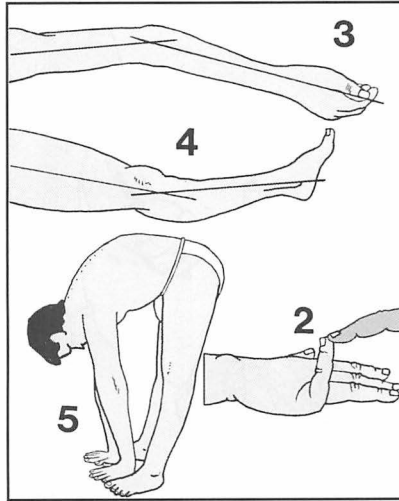


6.21. Palmarflexion (2): Palmarflexion may be measured with a goniometer.

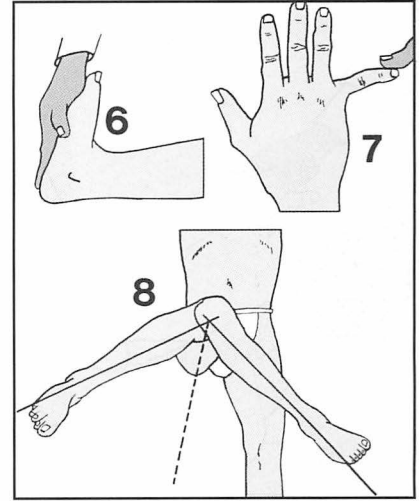
Normal range = 75°. If the range exceeds this, look for other signs of wrist (and other joint) hypermobility, as described in the following frames.



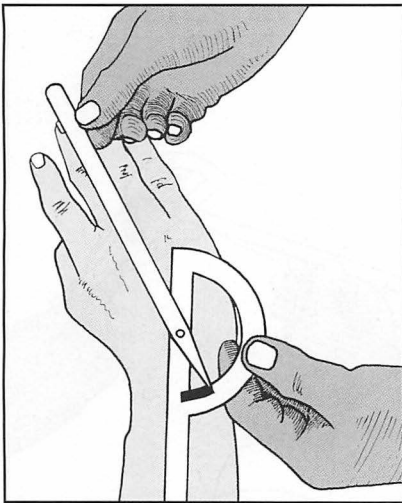
6.22. Joint hypermobility (1): (1) Try to bring the thumb into contact with the forearm and measure any gap. The *average* separation is 4.5 cm at age 17½ and it increases with age (as the ligaments lose some of their elasticity). Although the thumb contacting the forearm suggests hypermobility, this is nevertheless said to occur in 56% of normal subjects.



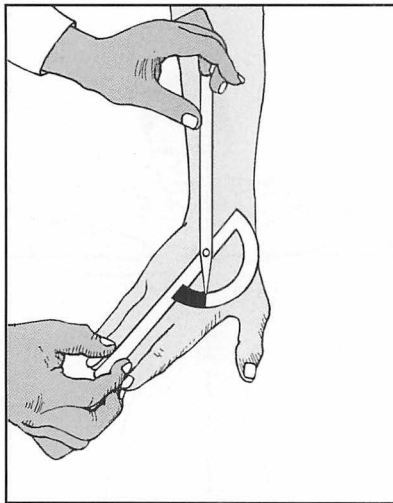
6.23. Joint hypermobility (2): (2) Test whether the little finger can be passively dorsiflexed to 90° or more. (3) Check the elbow and (4) the knee to see if they can hyperextend by 10° or more. (5) Check if the spine can be flexed so that the palms of the hands can be placed on the floor. Joint laxity is diagnosed if any three of these tests (1–5) are positive.



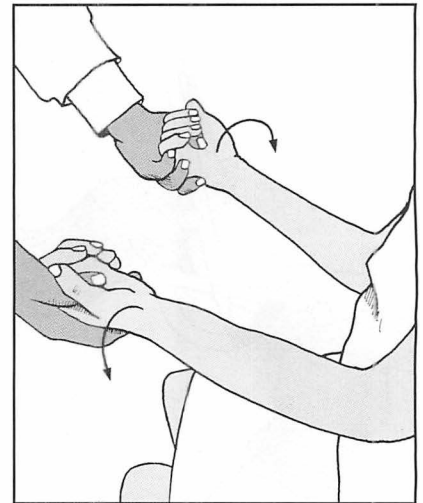
6.24. Joint hypermobility (3): Other evidence of hypermobility includes (6) hyperextension of the ankle beyond 45°; (7) an abnormal range of abduction of the little finger; (8) an increase in hip rotation in children (from 90–93° to about 110°), with the centre of the range displaced lateral to the midline. Joint hypermobility is a feature of the Ehlers–Danlos syndrome, Marfan's disease, osteogenesis imperfecta and Morquio–Brailsford's disease.



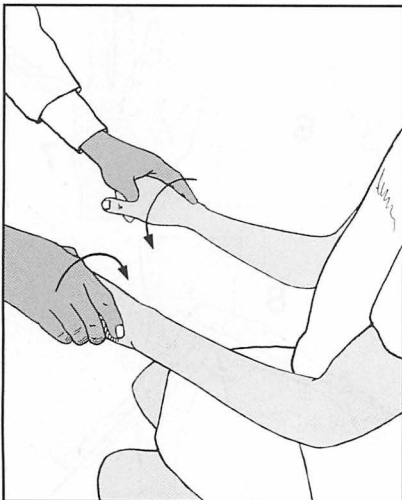6.25. Radial deviation: Radial deviation is measured as the angle formed between the forearm and the middle metacarpal. This test is best carried out in the mid position of the pronation/supination range.
Normal range = 20°.



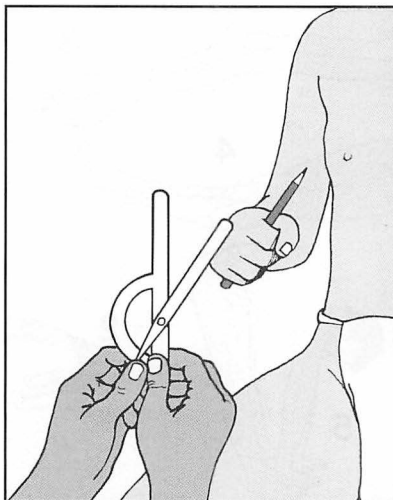
6.26. Ulnar deviation: Ulnar deviation may be measured in the same way.
Normal range = 35°.



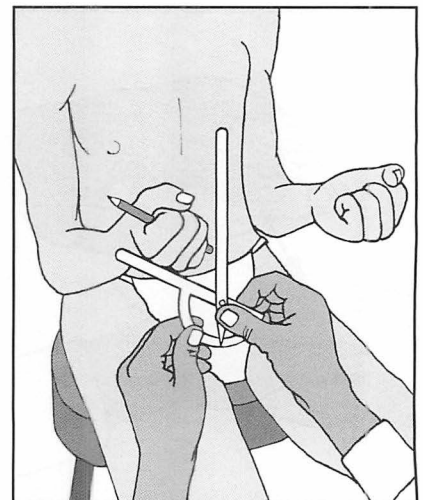
6.27. Pronation/supination: *Screening test:* Ask the patient to hold the elbows firmly at the sides. Grasp the hands and turn them so that the palms are uppermost. Compare the amount of supination in both sides.



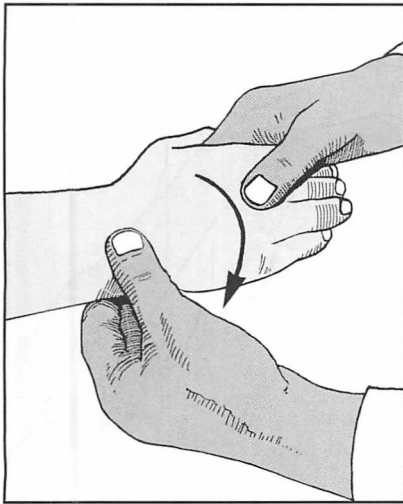
6.28. Pronation/supination: *Screening test (2):* Repeat, turning the palms downward to assess pronation. If no obvious cause for loss of pronation or supination is found at the wrist then the forearm and elbow must be carefully examined.



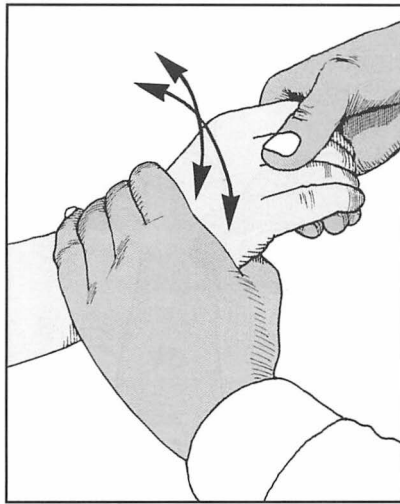
6.29. Pronation: For accurate measurement, give the patient a pen to hold. Ask the patient to keep the elbows firmly at the sides and to pronate the wrist. Measure the angle between the vertical and the held pen.
Normal range = 75°.



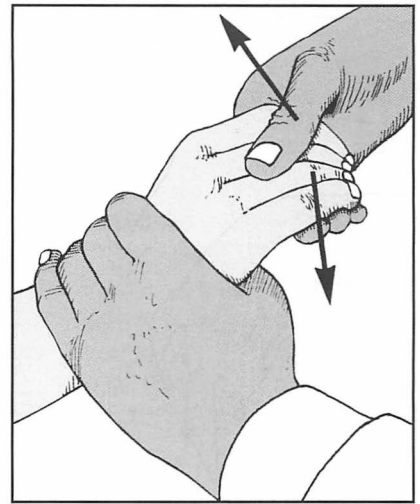
6.30. Supination: Supination may be measured in the same way.
Normal range = 80°.



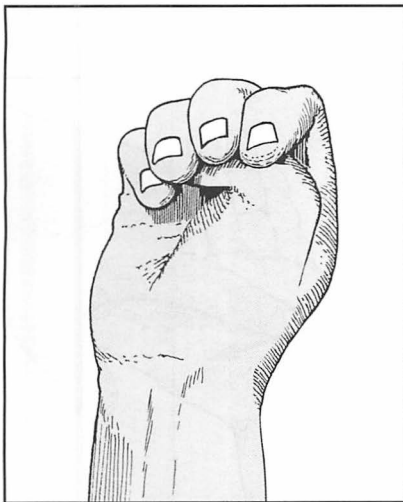
6.31. Crepitus (1): radioulnar joint: Place the index and thumb over the joint and pronate and supinate the wrist. Crepitus is common when the joint is disorganized, especially after a Colles' fracture.



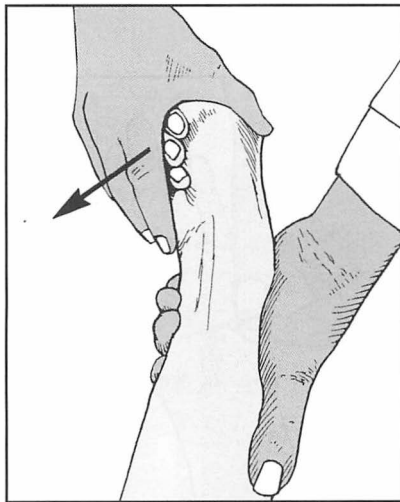
6.32. Crepitus (2): radiocarpal joint: Encircle the wrist with the hand and ask the patient to dorsiflex, palmarflex, radial deviate and ulnar deviate the wrist. Osteoarthritis of the wrist is uncommon, but occurs after scaphoid and distal radius fractures. Kienbock's disease etc.



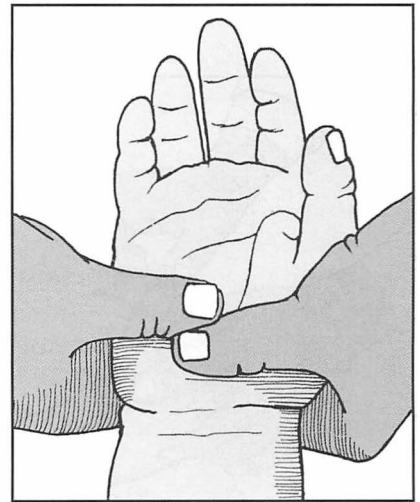
6.33. Crepitus (3): While grasping the wrist, flex and extend the fingers. Ask the patient to repeat these movements on his own. Crepitus, fine in character, occurs in tenosynovitis of the extensor tendons. Auscultation over the tendons may reveal characteristic grating sounds.



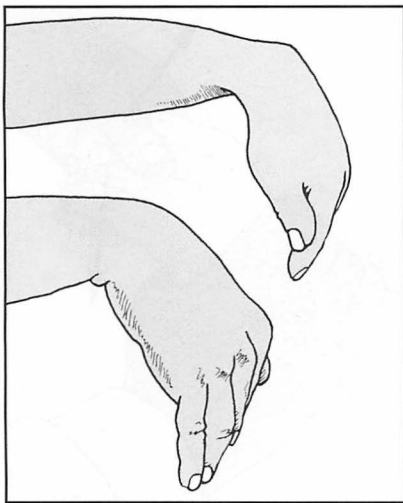
6.34. de Quervain's tenosynovitis (of abductor pollicis longus and extensor pollicis brevis). Where this is suspected from the history, local swelling and tenderness, confirm the diagnosis with the following test. Ask the patient to flex the thumb and close the fingers over it.



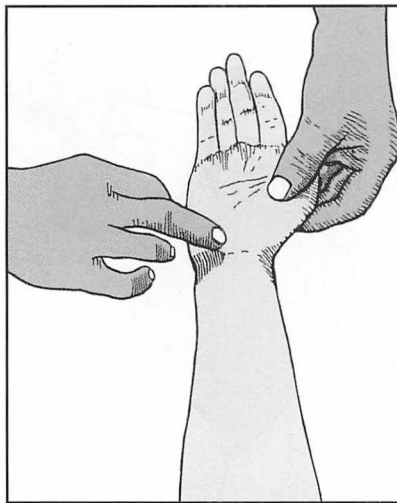6.35. de Quervain's tenosynovitis: Now move the hand into ulnar deviation. In de Quervain's tenosynovitis excruciating pain accompanies this manoeuvre.



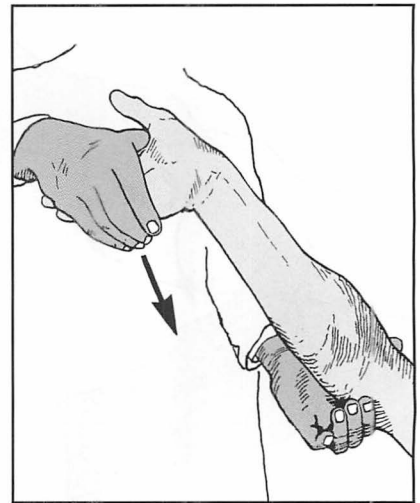
6.36. Carpal tunnel syndrome (1): Where this is suspected, apply very firm, steady pressure with both thumbs for 30 seconds over the median nerve as it runs within the carpal tunnel. Note the interval between the application of pressure and the onset of numbness, pain or paraesthesia in the median distribution (average 16 seconds in carpal tunnel syndrome). *This is the most reliable test for carpal tunnel syndrome.*

**6.37. Carpal tunnel syndrome (2):**

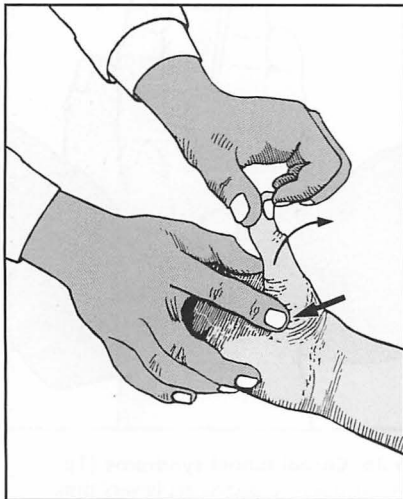Phalen test: Ask the patient to hold both wrists in a fully flexed position for 1–2 minutes. The appearance or exacerbation of paraesthesia in the median distribution is suggestive of the carpal tunnel syndrome, and is positive in 70% of those suffering from this condition.

**6.38. Carpal tunnel syndrome (3):**

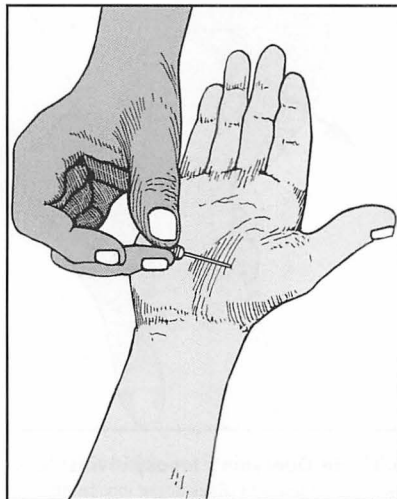
Tinel's sign: the test is positive if gentle finger percussion over the median nerve produces paraesthesia in its distribution. This test is said to be positive in 56% of cases of carpal tunnel syndrome.

**6.39. Carpal tunnel syndrome (4):**

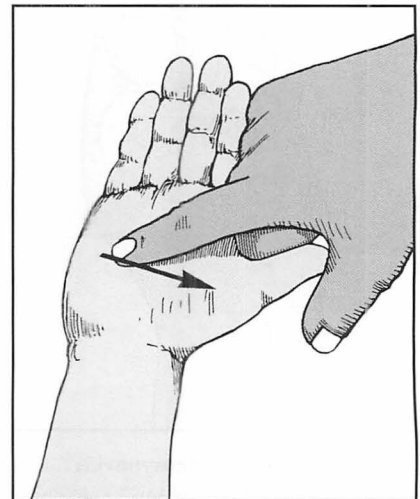Note any pain and paraesthesia on stretching the nerve by the manoeuvre of extending the elbow and dorsiflexing the wrist.



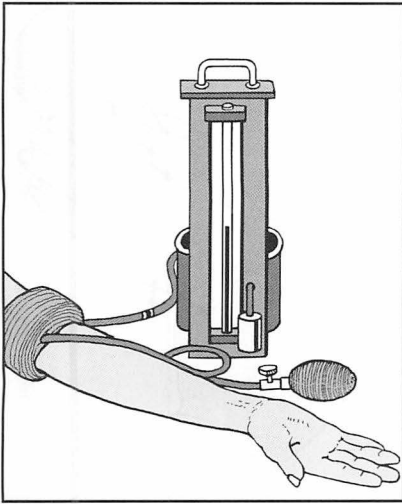
6.40. Carpal tunnel syndrome (5): Test the motor division of the median nerve. Note the resistance offered by the patient as you try to push the vertically held thumb into the plane of the palm. Feel the tone in the thenar muscles.



6.41. Carpal tunnel syndrome (6): Look for sensory impairment in the median distribution.

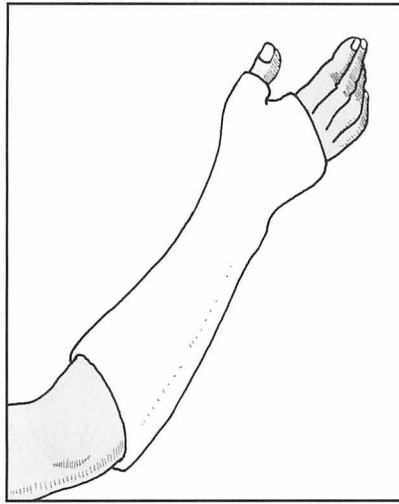


6.42. Carpal tunnel syndrome (7): Slide the tip of the index finger across the palm, noting frictional resistance and temperature. Increased thenar resistance (from lack of sweating) and temperature rise (vasodilatation) may occur with median nerve involvement.

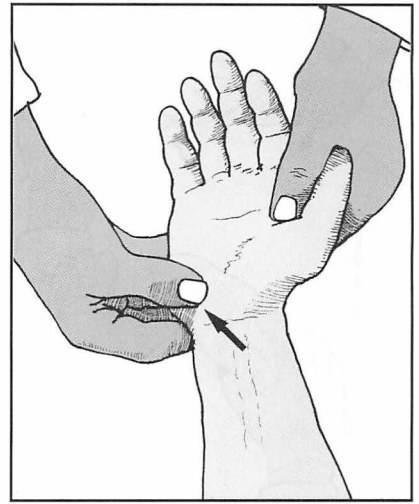


6.43. Carpal tunnel syndrome (8):

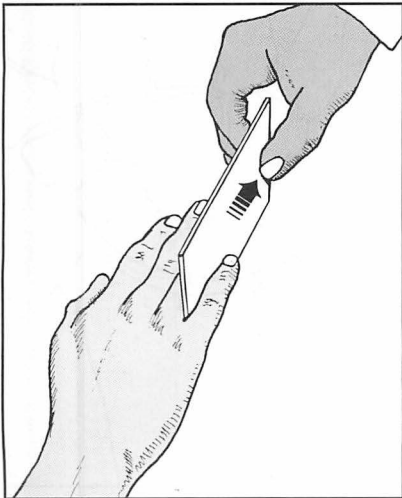
Apply a tourniquet and inflate it to just above the systolic blood pressure; maintain this for 1–2 minutes. The appearance or exacerbation of symptoms again suggests the carpal tunnel syndrome. This test, however, should be interpreted with caution.



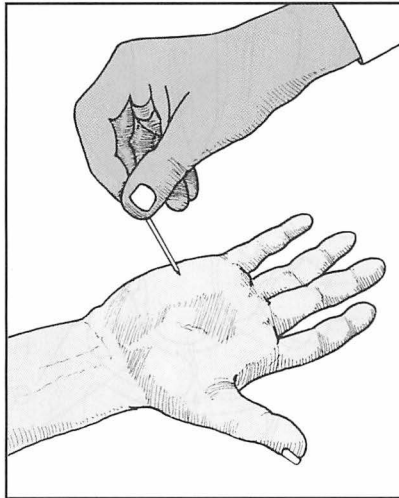
6.44. Carpal tunnel syndrome (9): If there is still doubt, apply a scaphoid plaster for 7–10 days. Improvement of symptoms while in plaster, and deterioration on removal, is suggestive of the carpal tunnel syndrome. Nerve conduction studies that show impairment of conduction at the level of the tunnel are virtually diagnostic, and are used by many to counter the chances of future litigation.



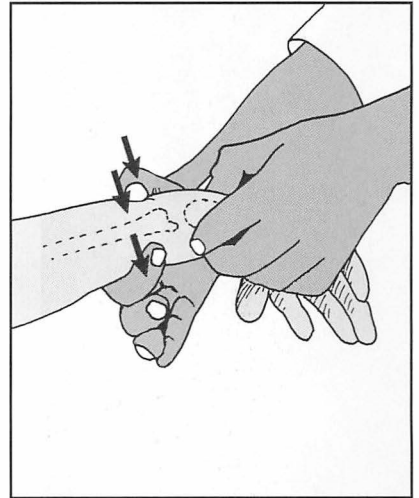
6.45. Ulnar tunnel syndrome (1): Look for tenderness over the tunnel, and for signs of ulnar nerve involvement (hypothenerar wasting, abduction of the little finger, early clawing of the ring and middle fingers).



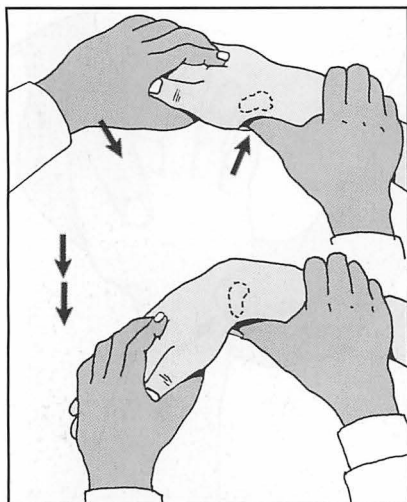
6.46. Ulnar tunnel syndrome (2): Test for involvement of the motor distribution of the nerve. The power of adduction of the little finger is a useful screening test. Note that weakness of *adduction*, but with normal power of *abduction*, is one early sign of cervical spinal myelopathy.



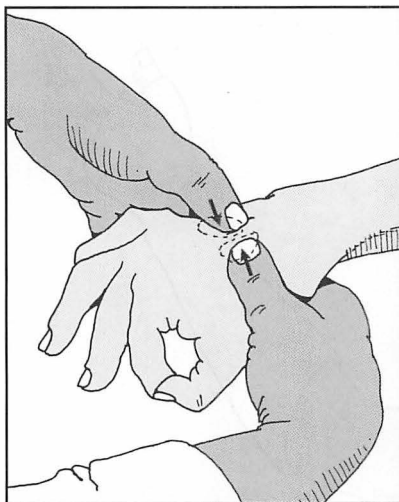
6.47. Ulnar tunnel syndrome (3): Test for sensory impairment in the common area of sensory distribution of the nerve.



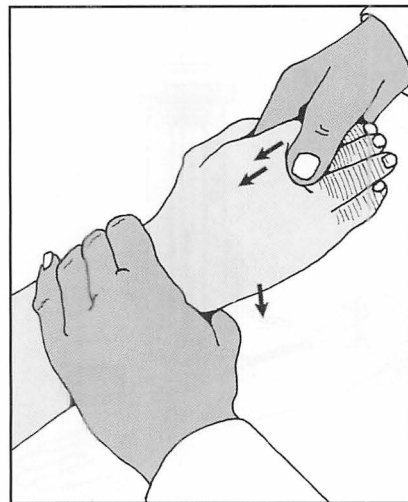
6.48. Distal radioulnar joint laxity: Test for laxity in the joint; its presence may be associated with weakness of the wrist, clicking sensations and ulnar nerve involvement. Steady the carpus with one hand and use the other to hold the distal ulna and attempt to move it in a dorsal and then a volar direction, noting any clicking sensations or complaint of pain. Compare the sides.



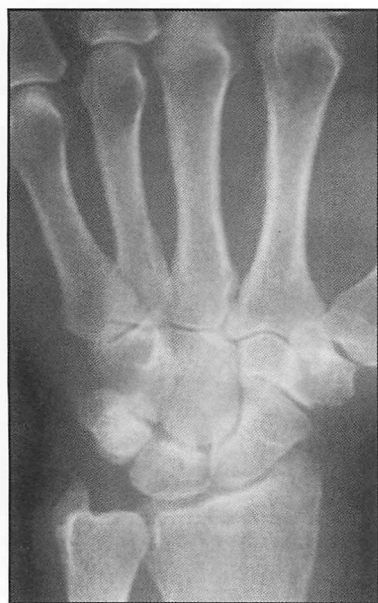6.49. Carpal instabilities (1): *scapholunate instability:* Watson's test: press the thumb against the tubercle of the scaphoid, and with the other hand palmarflex and radially deviate the patient's wrist. A click should be felt if the scaphoid subluxes over the distal radius, and reduction should occur if the pressure of the thumb is slackened. Accompanying pain is confirmatory.



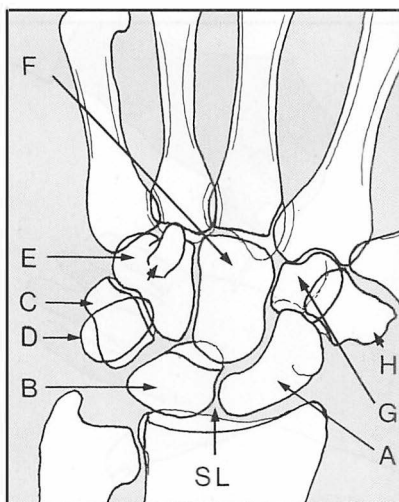
6.50. Carpal instabilities (2): *lunotriquetral instability:* Ballottement test: the triquetrum and lunate respectively are grasped between the thumb and index of each of the examiner's hands, and an attempt made to displace them relative to one another, first in a dorsal and then in a volar direction. Note any associated and confirmatory pain or crepitus.



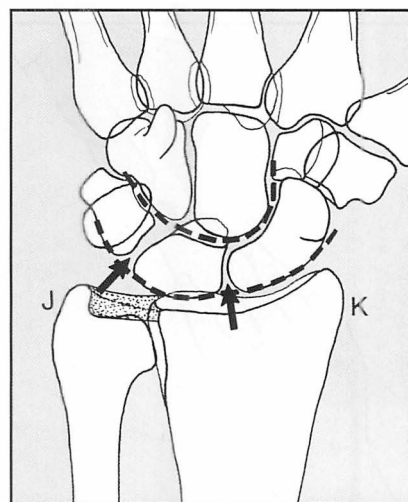
6.51. Carpal instabilities (3): *midcarpal instability:* with one hand steadying the distal forearm and the other grasping the patient's hand, push the carpus against the radius and gently swing the wrist from a position of full ulnar deviation to full radial deviation. The test is positive if this normal smooth movement is irregular, with for example an accompanying clunking sensation.



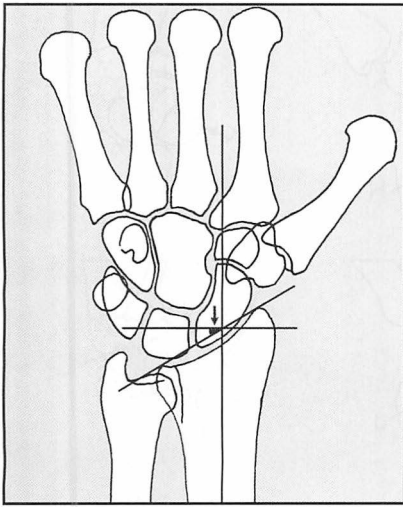
6.52. Radiographs (1): Normal anteroposterior radiograph of the wrist.



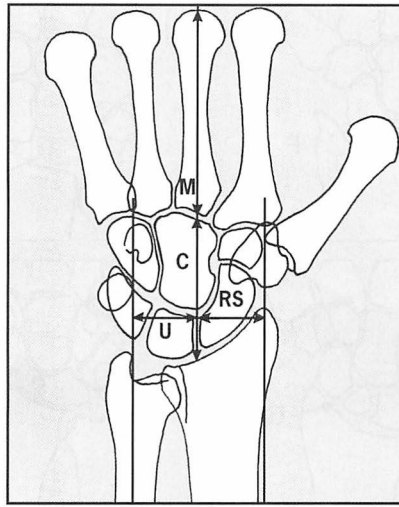
6.53. Radiographs (2): *Landmarks:* In the anteroposterior, identify the carpal bones and note their shape, density and position: (A) scaphoid, (B) lunate, (C) triquetrum, (D) pisiform, (E) hamate with hook, (F) capitate, (G) trapezoid, (H) trapezium. Note the gaps between the various carpal bones, particularly between the scaphoid and lunate (SL), and whether these are diminished or excessive.



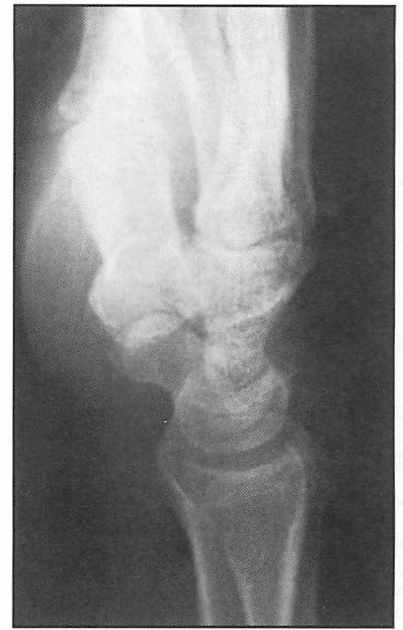6.54. Radiographs (3): Note the smooth curves formed by the proximal and distal rows of the carpus, and that the distal end of the ulna stops short of the radius to make room for the triangular fibrocartilage. If there is any widening of the gaps between the scaphoid and lunate, or the lunate and triquetrum, or any suggestion of carpal instability, obtain additional views in full radial and ulnar deviation. (J) Ulnar styloid, (K) radial styloid.



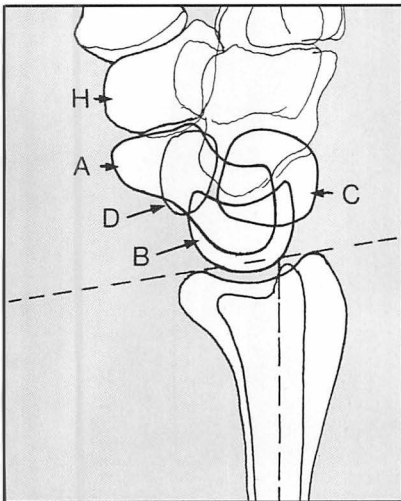
6.55. Radiographs (4): Note the *radial inclination*: this is the angle between the distal articular surface of the radius and the radial shaft. It is often decreased after a Colles' fracture. For critical assessment it may be measured on the radiographs. Normal range = 19–25°.



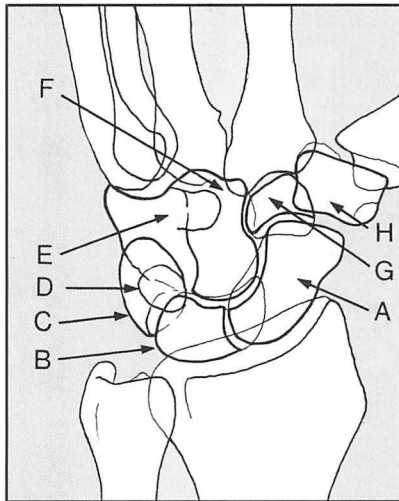
6.56. Radiographs (5): A line drawn through the middle metacarpal (M) and carpus (C), and its distance from the radial styloid (RS) and ulnar axis (U), may be very occasionally used to assess carpal height and drift, expressing these as ratios. Carpal height ratio = C/M (normal = 0.51–0.57); Chamay measurement = U/M (normal = 0.25–0.31); McMurtry's index = U/M (normal = 0.27–0.33).



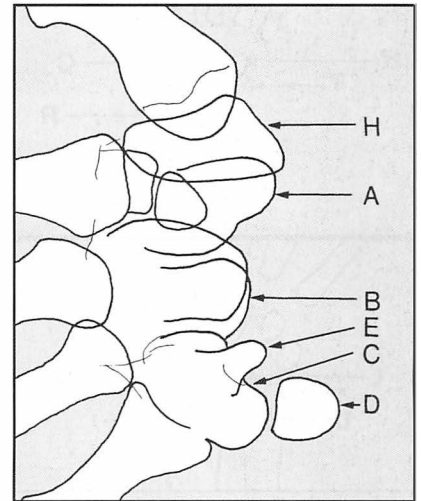
6.57. Radiographs (6): Normal lateral radiograph of the wrist.



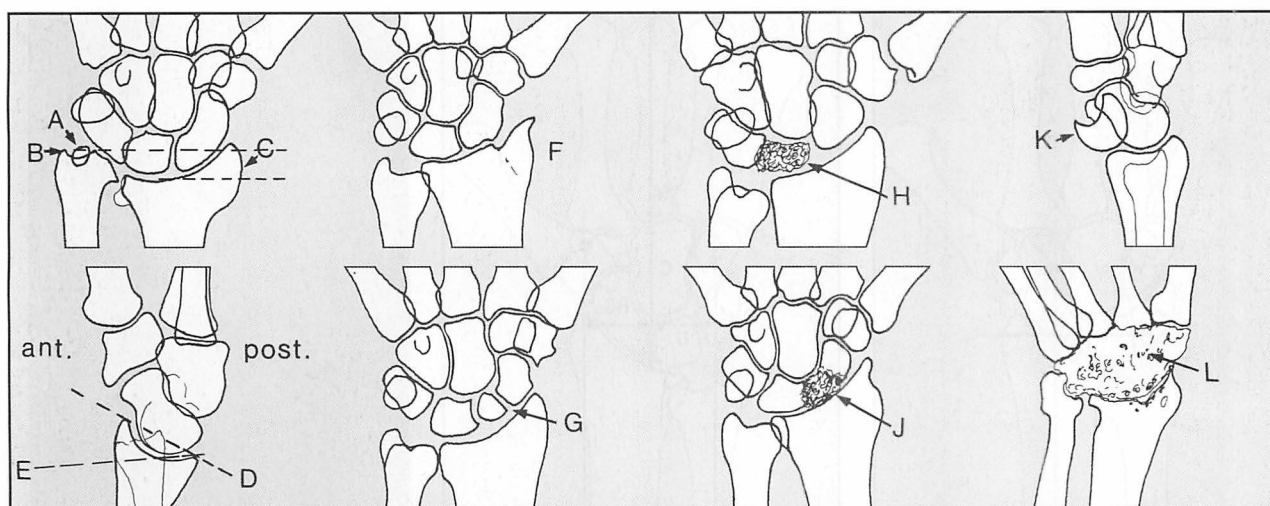
6.58. Radiographs (7): It is usually possible to make out in the lateral the following, in spite of the superimposition of the bony structures: (H) trapezium; (A) tubercle and body of the scaphoid; (D) pisiform; (B) crescent of lunate; (C) triquetrum. Note that the plane of the wrist joint has normally a 5° anterior tilt.



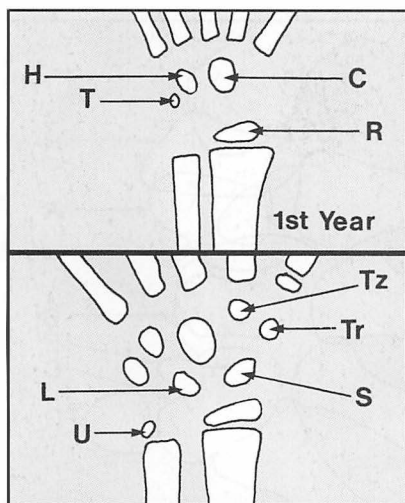
6.59. Radiographs (8): When the carpus is suspect, at least one (but preferably two) oblique views should be taken in addition to the routine anteroposterior and lateral. These are of particular value in detecting hairline crack fractures of the carpal bones. (The labelling is the same as in previous diagrams.)



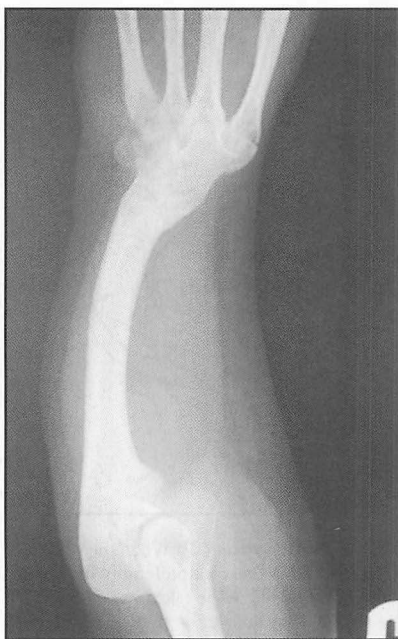6.60. Radiographs (9): In suspected carpal tunnel syndrome a tangential projection of the tunnel should be obtained. This view occasionally shows osteoarthritic lipping or other causal pathology. (A) Scaphoid, (B) lunate, (C) triquetrum, (D) pisiform, (E) hook of hamate, (H) trapezium.



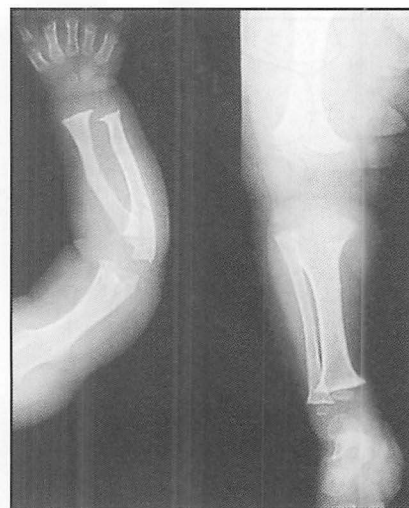6.61. Radiographs (10): Look for evidence of previous injury. In the malunited Colles' fracture there may be (A) non-union of the ulnar styloid; (B) prominence of the distal ulna secondary to (C) distortion and resorption at the radial fracture, with disturbance of the radial inclination. In the lateral the joint line (D) may also be tilted away from (E) the normal. Osteoarthritic changes are uncommon after Colles' fracture, but are seen after (F) radial styloid fractures. Osteoarthritis may not always follow (G) non-union of a scaphoid fracture, but is nevertheless common. Note increased bone density and deformity in (H) Kienbock's disease of the lunate or in (J) avascular necrosis of the scaphoid, both of which are almost invariably accompanied by osteoarthritis. Note any carpal malalignment, such as dislocation of the lunate (K), which is the most common. Gross porotic changes are seen most frequently in rheumatoid arthritis and in Sudeck's atrophy (complex regional pain syndrome), whereas gross destructive changes are a feature of (L) tuberculosis and other infections.



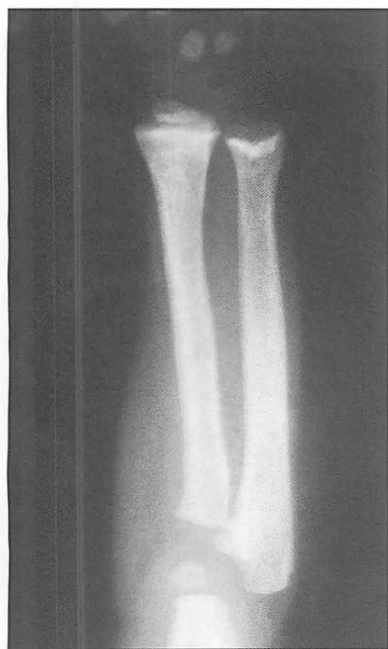6.62. Ossification: In the first year of life the ossification centres for the capitate (C) and hamate (H) appear at 2 months, the radius (R) at 6 months, and the triquetrum (T) at 10 months. After the first year, the lunate (L) appears at about 2, the trapezium (Tr) at 2½, the trapezoid (Tz) and scaphoid (S) at 3, and the distal ulna (U) at 4½ years.



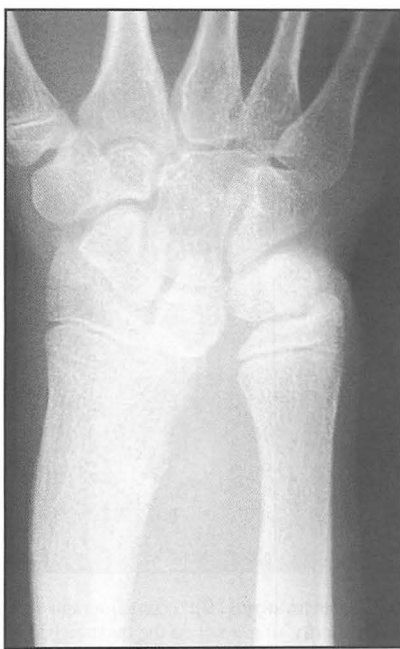6.63. Wrist radiographs: examples of pathology (1): the radiograph shows a deformity of the upper limb in which there is absence of the radius and thumb, along with failure of carpal differentiation.
Diagnosis: congenital deformity.



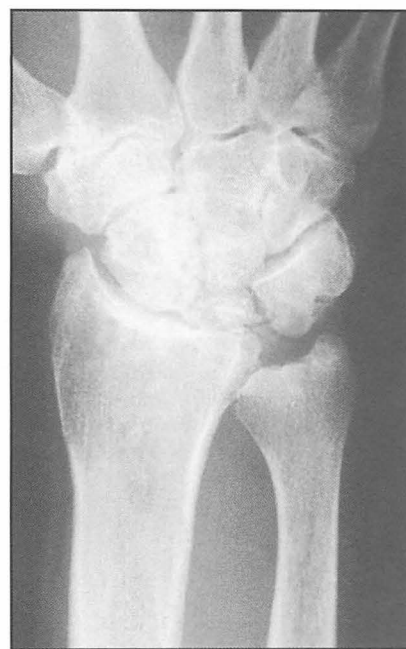6.64. Pathology (2): The radiographs show an upper and lower limb where the width of the bones is normal but they are proportionately short, contributing to the dwarfism associated with this hereditary abnormality. The metaphyses are wide, and there is defective modelling of the shafts.
Diagnosis: achondroplasia.



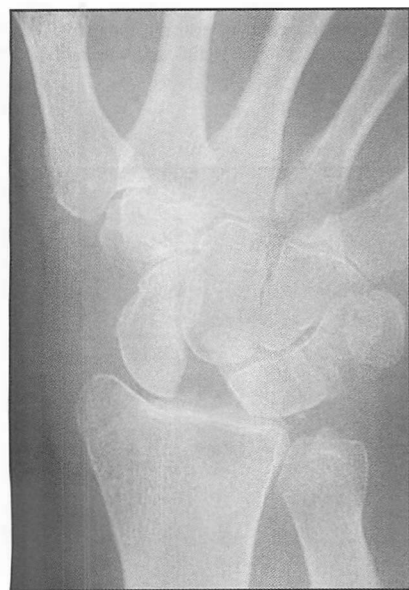6.65. Pathology (3): In this radiograph of a child's forearm there is a little metaphyseal widening and irregularity, with ulnar metaphyseal cupping (said to be due to pressure transmitted in crawling).
Diagnosis: rickets.



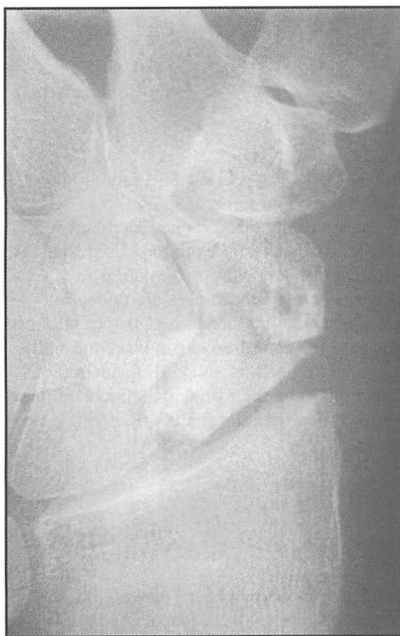6.66. Pathology (4): There are deformities of the distal radius and ulna, which are splayed. There is relative lengthening of the ulna, which is unduly prominent at the side and back of the wrist.
Diagnosis: Madelung deformity of the wrist.



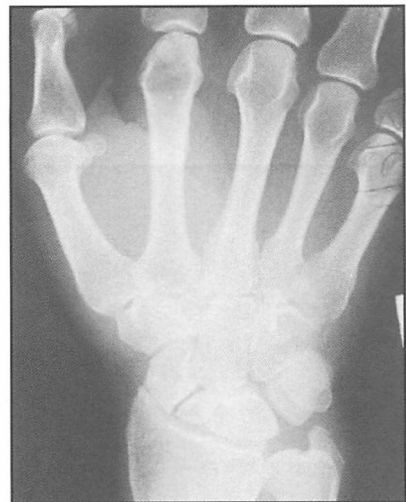6.67. Pathology (5): There is gross distortion and collapse of the lunate.
Diagnosis: Kienbock's disease.



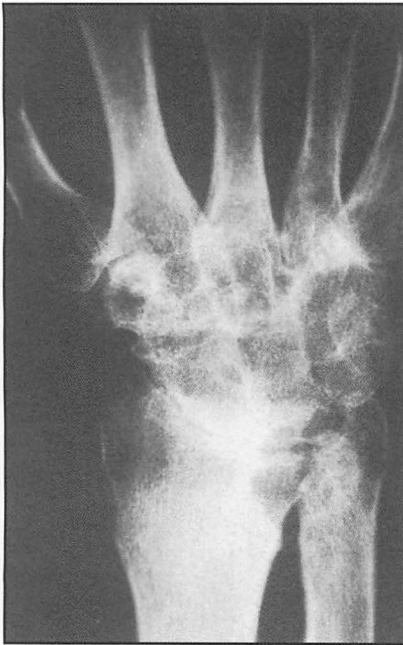6.68. Pathology (6): The history is of weakness and instability of the wrist, with clicking sensations and pain occurring with certain movements.
Diagnosis: carpal instability secondary to scapholunate dissociation.



6.69. Pathology (7): The radiograph shows a defect in the continuity of the scaphoid, with increased density of its proximal pole.
Diagnosis: there has been a fracture of the scaphoid, followed by non-union and avascular necrosis.

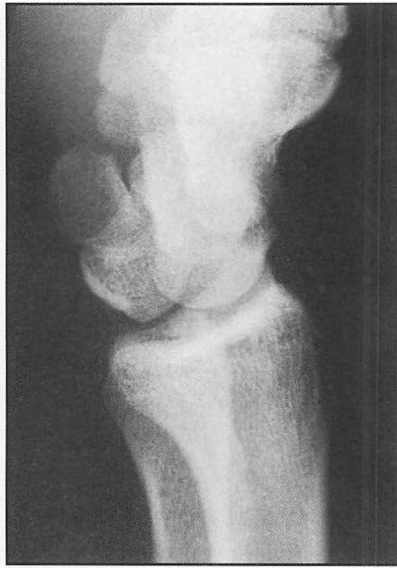


6.70. Pathology (8): The radiograph shows a long-established defect situated in the waist of the scaphoid. There is some narrowing of the joint space between the scaphoid and the radius.
Diagnosis: established non-union of the scaphoid following fracture, with early secondary radiocarpal osteoarthritis.



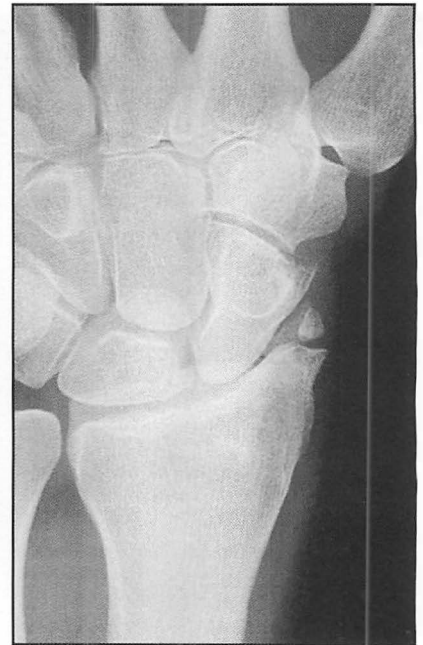
6.71. Pathology (9): There is gross destruction of the carpal and wrist joints, with fibrous ankylosis.

Diagnosis: the findings are typical of the late appearances of an infective arthritis (in this case clue to tuberculosis).



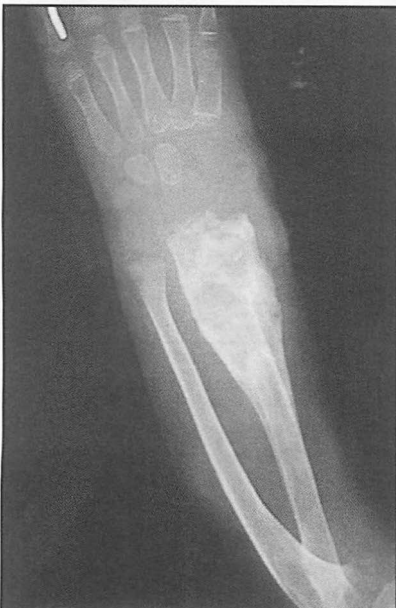6.72. Pathology (10): The radiograph was taken shortly after a fall on the outstretched hand, when there was complaint of pain in the wrist and paraesthesia over the ball of the thumb.

Diagnosis: the lateral projection shows two bones lying proud of the rest of the carpus at the front of the wrist: one is the normally situated pisiform; the other, semilunar in shape and lying more proximal, is a dislocated lunate. The symptoms suggest involvement of the median nerve.



6.73. Pathology (11): The radiograph shows an abnormality of the distal radius. There is rounding of the proximal part of the small bone fragment in the region of the styloid process.

Diagnosis: fracture of the styloid process of the radius, which has failed to unite. The appearances are of a long-standing lesion. Such a condition may be symptom free, or give pain if secondary arthritic changes develop between the radius and scaphoid.

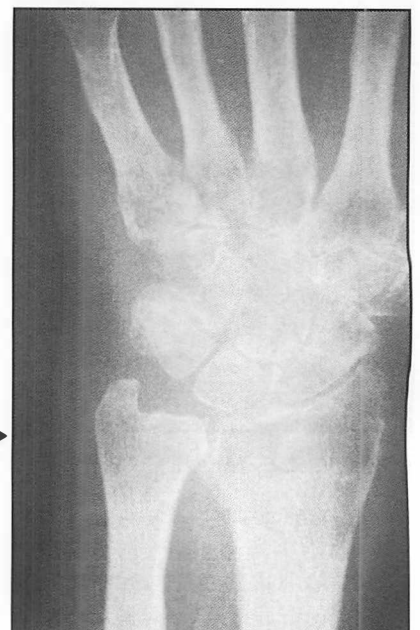

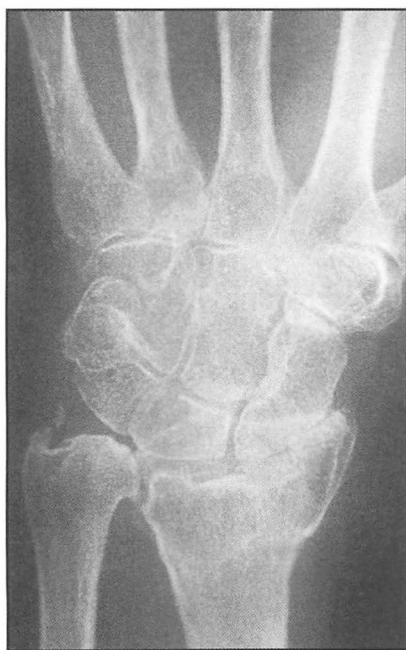6.74. Pathology (12): This radiograph of a child's wrist and forearm shows gross distortion of the distal radius. There are apparently cystic spaces in the radial shaft, with extensive new bone formation.

Diagnosis: the appearances are typical of gross osteitis, with bone abscess formation. In this case the causal organism was, unusually, the tubercle bacillus. (NB: Most tuberculous infections have their principal effects on the joints, rather than the shafts of the long bones.)

6.75. Pathology (13): There is widespread decalcification of the carpus and adjacent long bones, with loss of radiological carpal detail. There was complaint of pain and stiffness following a minor injury.

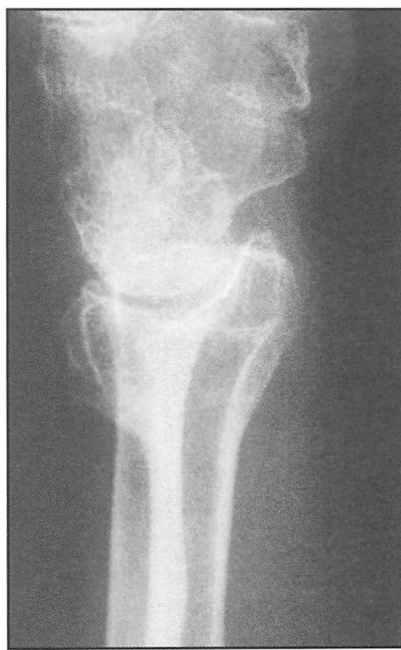Diagnosis: Sudeck's atrophy (complex regional pain syndrome). The radiological appearances are similar to those found in rheumatoid arthritis.



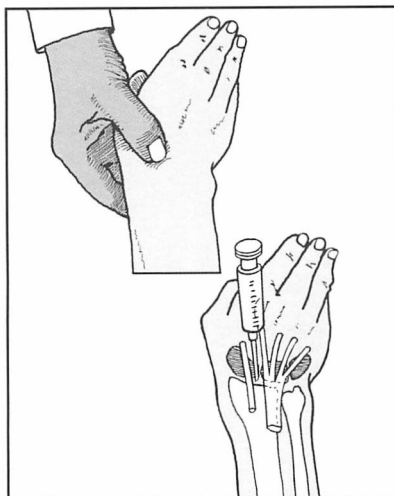


6.76. Pathology (14): This anteroposterior radiograph shows distortion of the inferior radioulnar joint, relative lengthening and prominence of the ulna, and widening of the radius. The patient complained of pain in the wrist (in the radioulnar joint) and restriction of pronation/supination movements.

Diagnosis: malunion of a Colles' fracture.



6.77. Pathology (15): The lateral radiograph of the same case shows marked alteration in the plane of the radiocarpal joint, again due to malunion: this, apart from the deformed appearance, has the effect of seriously restricting palmar flexion.



6.78. Aspiration of the wrist joint:

Using your thumb, feel for the depression at the back of the wrist which lies between the distal end of the radius and scaphoid, and which is bordered by extensor digitorum communis and extensor carpi radialis brevis. Infiltrate this area with local anaesthetic before introducing the aspirating needle. The tip of the needle should be directed cranially at an angle of 30° from the vertical.

CHAPTER

7

The hand

- Dupuytren's contracture 110
- Vibration syndromes 110
- Tendon and tendon sheath lesions 111
- Rheumatoid arthritis 112
- Osteoarthritis of the interphalangeal joints 113
- Carpometacarpal joint of the thumb 113
- Tumours in the hand 113
- Infections in the hand 114
- Inspection 115–123
- Movements 119–123
- Vibration syndromes 123
- Assessing hand circulation 123
- Tendon injuries 123–124
- Infections 124–125
- Assessing hand function 125–126
- Pathology 126–127

Note that the separation of conditions into those affecting the wrist and those affecting the hand has been done for convenience, and that in many cases examination of both regions is necessary.

DUPUYTREN'S CONTRACTURE

In this condition there is nodular thickening and a contracture of the palmar fascia. The palm of the hand is affected first, followed at a later stage by the fingers. The ring finger is most frequently involved, followed by the little and middle fingers. The index and even the thumb may be affected. In some cases there is corresponding thickening of the *plantar* fascia. The progressive flexion of the affected fingers interferes with the function of the hand and may be so severe that the fingernails dig into the palm. The condition mainly affects men over the age of 40. There is a definite genetic predisposition in 60–70% of cases, and in some cases there may be an association with epilepsy, diabetes or alcoholic cirrhosis. There is a distinct geographical distribution: it is rare in Africa, India and China. Below the age of 40, and in either sex, its onset may be precipitated by trauma. Under these circumstances it may pursue a particularly rapid course.

As far as treatment is concerned, a waiting policy may be pursued if the condition is confined to the palms. When the fingers are affected surgical treatment is usually advised, but this is complicated by a number of factors. If the fingers have been held in a flexed position for a long time, secondary changes in the interphalangeal joints may prevent finger extension even after the involved tissue has been removed. In the case of the little finger, amputation in these circumstances may be the best line of treatment. The digital nerve sheaths may blend with the fascia so that dissection is tedious and difficult; involvement of the skin may necessitate Z-plasties or other plastic procedures; and the patient's age and general health may be adverse factors. In most cases wide excision of the affected fascia is advised. When this is not possible, improvement in function, often lasting for some years, may follow simple division of the contracted fascia in the palm.

VIBRATION SYNDROMES

Prolonged exposure to high-frequency vibration (such as may be experienced from the use of jack hammers or handheld buffing, riveting and caulking machines) may affect bone, nerves and blood vessels. *Bone* is rarely affected to a significant degree, but new bone formation and hairline fractures (which are slow to heal) are sometimes seen. Involvement of the peripheral *nerves* may lead to pain and paraesthesia, numbness, tremor, loss of fine touch sensation, proprioception and discrimination. There may be muscle denervation and weakness involving especially the small muscles of the hand. In the case of the *peripheral blood vessels* there is disturbance of their autonomic control, and the arterioles of the hand become hypersensitive to cold and vibration. In the typical case there are attacks in which one or more fingers turn white on exposure to cold ('episodic blanching'), with reactive hyperaemia on warming; and there is usually associated discomfort and clumsiness of the hand during attacks. As the condition progresses more fingers become involved, incidents occur both in summer and in winter, and hand function becomes permanently disturbed. The hand becomes weak and clumsy, and with impaired sensation and proprioception the patient has

difficulty in dressing (e.g. doing up buttons and shoelaces), handling small objects (e.g. coins, nuts and screws), and carrying out many other tasks (e.g. tying fishing hooks). The differential diagnosis includes Raynaud's disease, cervical rib and the costoclavicular syndrome, cervical spondylosis, and sensitivity to β -blockers.

There are a number of classifications of the stages of the condition, and the long-established Taylor–Pelmear scale is still widely used (Table 7.1). Well established cases are recognized as one of the prescribed diseases under the Social Security Act, and the qualifying criteria are clearly stated. (The condition must occur throughout the year, involve at least three fingers of one hand (with the middle and/or proximal phalanges being affected), and be due to exposure to vibrating tools.) No treatment is effective, but deterioration may be slowed or prevented by avoiding further exposure to vibration.

Table 7.1 The Taylor–Pelmear Scale

Stage	Condition of digits	Work and social interference
0	No blanching of digits	No complaints
0T	Intermittent tingling	No interference with activities
0N	Intermittent numbness	No interference with activities
1	Blanching of one or more fingertips, with or without tingling or numbness	No interference with activities
2	Blanching of one or more fingers, with numbness; usually confined to winter	Slight interference with home and social activities; no interference at work
3	Extensive blanching. Frequent episodes, summer and winter	Definite interference at work, at home, and with social activities. Restriction of hobbies
4	Extensive blanching. Most or all fingers affected. Frequent episodes, summer and winter	Occupation changed to avoid further exposure to vibration because of severity of signs and symptoms

TENDON AND TENDON SHEATH LESIONS

See also under Rheumatoid arthritis.

Mallet finger In a mallet finger the distal interphalangeal joint is held in a permanent position of flexion; the deformity may be moderate or complete. The patient is unable to extend the distal joint of the finger, either not at all or only incompletely. The problem is that the extensor tendon, usually as a result of trauma, either ruptures close to its insertion in the distal phalanx, or it avulses its bony attachment. Healing may occur spontaneously over a 6–12-month period, but it is usual practice to treat these injuries for 6 weeks with a light splint that holds the distal interphalangeal joint in extension.

Mallet thumb Delayed rupture of the extensor pollicis longus tendon may follow Colles' fracture (see Wrist) or rheumatoid arthritis, and repair by tendon transfer (using extensor indicis proprius) is usually advised. If the tendon is damaged by an incised wound, repair by direct suture is undertaken.

Boutonnière deformity Flexion of the interphalangeal joint of a finger with extension of the distal interphalangeal joint characterizes this deformity, which is due to detachment of the central slip of the extensor tendon which is attached to the base of the middle phalanx. This may follow incised wounds on the dorsum of the finger and avulsion injuries, but is more commonly seen in rheumatoid arthritis. Surgical repair of the extensor band is often undertaken for isolated lesions of this type.

Extensor tendon division in the back of the hand Extensor tendons divided by wounds on the back of the hand carry an excellent prognosis and are treated by primary suture and splintage for approximately 4 weeks.

Profundus tendon injuries

- (i) Isolated avulsion injuries, which are uncommon, may be treated by surgical reattachment of the tendon.
- (ii) Profundus tendon division in open wounds: in the palm, repair by direct suture is usually feasible. In the flexor tendon sheaths there is considerable risk of adhesions spoiling function. In uncontaminated wounds where good facilities are available, primary flexor tendon repair may be undertaken; otherwise, free flexor tendon grafting is usually advised. Accompanying digital nerve divisions may also be dealt with by primary repair.

Trigger finger and thumb This condition results from thickening of a fibrous tendon sheath or nodular thickening in a flexor tendon.

In young children the thumb is held flexed at the MP joint, and a nodular thickening in front of the MP joint is palpable; not infrequently the deformity is wrongly considered to be congenital in origin and untreatable.

In adults, the middle or ring finger is most frequently involved. When the fingers are extended the affected finger lags behind and then quite suddenly straightens. Nodular thickening, always at the level of the MP joint, may also be palpable. Division of the sheath at the level of the MP joint gives an immediate and gratifying cure.

RHEUMATOID ARTHRITIS

Rheumatoid arthritis, as is well known, very frequently affects the hand, and as it progresses may involve joints, tendons, muscles, nerves and arteries, producing most severe deformities and crippling effects on hand function.

In the earliest phases the hands are strikingly warm and moist; later the joints become obviously swollen and tender. Synovial tendon sheath and joint thickening, with effusion, muscle wasting and deformity, then becomes apparent. Tendon ruptures and joint subluxations are the main factors leading to the more severe deformities.

Surgery of the rheumatoid hand is highly specialized, requiring *particular* skills and experience in judgement, timing and technique, and is difficult to summarize with any accuracy.

In the earliest stages of the disease, medications which have analgesic, anti-inflammatory and antiautoimmune effects may be prescribed, with the judicious use of physiotherapy and splintage to alleviate pain, preserve movement and minimize deformity. When there is much synovial thickening at a stage before joint destruction has advanced, synovectomy is often helpful in alleviating pain and delaying local progress of the condition. In a

few well selected cases, where there is severe joint destruction and progressive deformity, joint replacement may be helpful; some cases of major tendon involvement may benefit from repair and other procedures.

OSTEOARTHRITIS OF THE INTERPHALANGEAL JOINTS

Nodular swellings situated dorsally over the bases of the distal phalanges (Heberden's nodes), or less commonly over the bases of the middle phalanges (Bouchard's nodes), are a sign of osteoarthritis of the finger joints. They occur most frequently in women after the menopause, and are often familial. They are not related to osteoarthritis elsewhere. In many cases they are symptom free, but they may be associated with progressive joint damage which does cause pain.

CARPOMETACARPAL JOINT OF THE THUMB

Osteoarthritic changes are common between the thumb metacarpal and the trapezium, and they may give rise to disabling pain and impaired function in the hand. There may on occasion be a history of a previous Bennett's fracture, or of occupational overuse. Several surgical procedures (e.g. excision of the trapezium) are available which give relief of pain, sometimes at the expense of some functional loss.

TUMOURS IN THE HAND

Tumours in the hand are not uncommon. Most involve the soft tissues and are simple, but it need hardly be stressed that where the diagnosis is uncertain a full investigation is essential. Among the commonest tumours are the following:

1. *Ganglions* occur in the fingers, most commonly along the volar aspects. They are small, spherical, and tender to the touch. They are generally treated by excision.
2. *Implantation dermoid cysts* occur along the volar surfaces of the fingers and palms. They are treated by excision.
3. *Glomus tumours* are less common. These small, vascular, exquisitely tender tumours are seen most often in the region of the nailbeds. They are also treated by excision.
4. *Mucous cysts*. These always occur on the dorsal surface of a distal interphalangeal joint. Excision is best avoided unless their rupture has led to a synovial fistula.
5. *Osteoid osteoma*. This tumour may involve a distal phalanx (or a carpal bone) and has a typical X-ray appearance. If there is doubt about the diagnosis, an isotope bone scan will show it up as a 'hot spot'. Spontaneous resolution may occur, but if symptoms are marked the tumour should be excised.
6. *Chondroma*. This is a very common benign tumour which occurs in the metacarpals and phalanges. It is generally confined to bone (enchondroma) and may give rise to a pathological fracture, or to gross swelling and deformity. It is often solitary, but multiple tumours of a similar nature are found in Ollier's disease, which has a hereditary diathesis. Tumours of this type may be treated by excision and bone grafting of the defect.

7. *Metastatic tumours*. These are uncommon, but have a tendency to involve the distal phalanges. Lung and breast are the commonest primary sites. The treatment is dependent on the nature of the primary and the spread elsewhere.

INFECTIONS IN THE HAND

1. *Paronychia*. This is the commonest of all infections in the hand, and occurs between the base of the nail and the cuticle.
2. *Apical infections* occur between the tip of the nail and the underlying nailbed.
3. *Pulp infections* occur in the fibrofatty tissue of the fingertips and are extremely painful. If unchecked, infection frequently leads to involvement of the terminal phalanx.

These three common infections are treated along well established lines, using antibiotics and surgical drainage if pus has formed.

4. *Tendon sheath infections*. Infection within a tendon sheath (Fig. 7.A) leads to rapid swelling of the finger and build-up of pressure within the tendon sheath; there is always a serious risk of tendon sloughing or disabling adhesion formation. In the case of the little finger there may be retrograde spread of infection to involve the ulnar bursa in the hand. In the case of the thumb, infection may also spread proximally to involve the radial bursa. In either case, swelling appears in the palm and in the wrist proximal to the flexor retinaculum. It should also be noted that in 70% of cases there is a connection between these two bursae, allowing spread from one to the other.

5. *Web space infections*. Web space infections are usually accompanied by great pain and systemic upset. There is redness and swelling in the affected space. Infection may spread along the volar aspects of the related fingers or to adjacent web spaces across the anterior aspect of the palm. If seen early, most web space infections respond to antibiotics, splintage and elevation, but drainage is sometimes necessary.

6. *Midpalmar and thenar space infections*. These two compartments of the hand lie between the flexor tendons and the metacarpals. Infection may spread to them from web space or tendon sheath infections: dissemination through the hand is then rapid and potentially crippling. In either case there is usually gross swelling of the hand and a severe systemic upset. Unless there is a rapid response to antibiotics, elevation and splintage, early drainage is essential for the preservation of function in the hand.

It should be noted that where splintage of the hand is advocated, and if functional recovery is to be hoped for, the fingers should be held in a position of right-angled flexion at the MP joints and extension in the interphalangeal joints.

7. *Tuberculosis and syphilis*. On rare occasions either of these two infections may produce spindle-shaped deformity of a finger. Spindling of a finger is much more common, however, in rheumatoid arthritis, gout, or collateral ligament trauma.

8. *Occupational infections*. Superficial infections are common in certain trades and the following may be noted:

- Pilonidal sinus in barbers
- Erysipeloid in fishmongers and butchers
- 'Butcher's wart' (tuberculous skin lesions) in butchers and pathologists
- Malignant pustule (anthrax) in hide sorters and tanners.

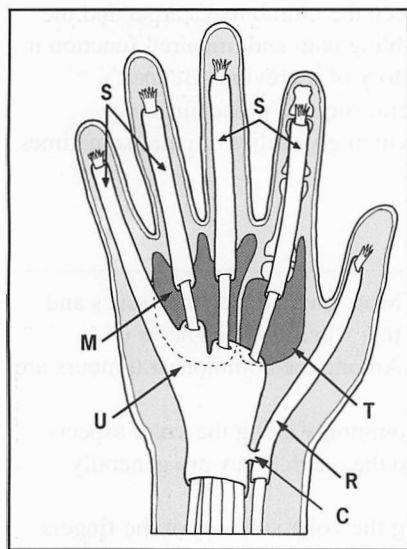
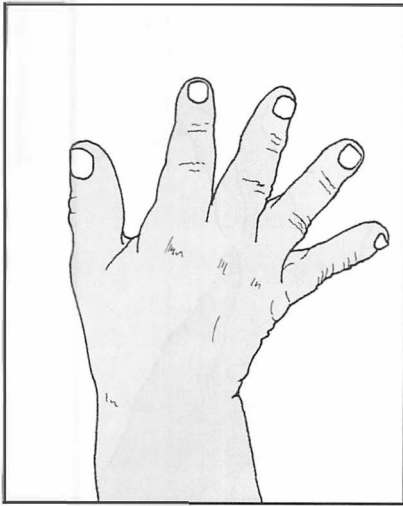
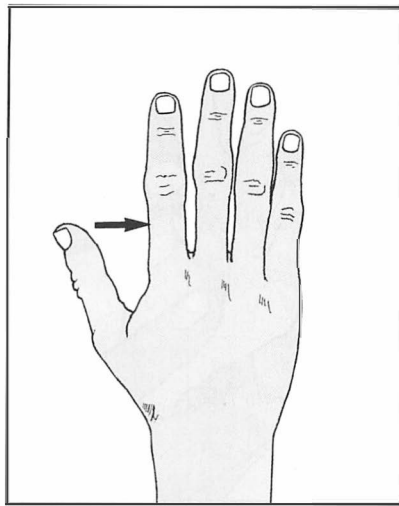


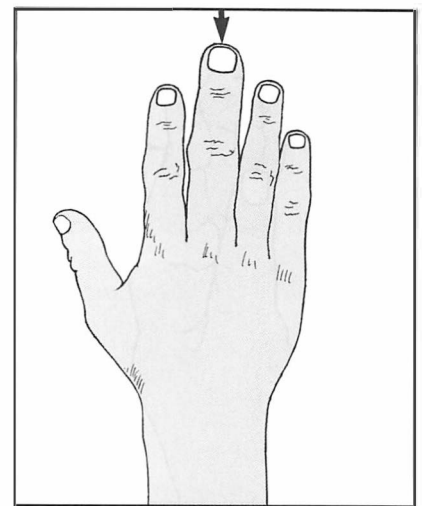
Fig. 7.A. Some potential sites of infection in the hand and fingers. S = synovial tendon sheaths; U = ulnar bursa; R = radial bursa; M = midpalmar space; T = thenar space. Note: C = communication between the radial and ulnar bursae.



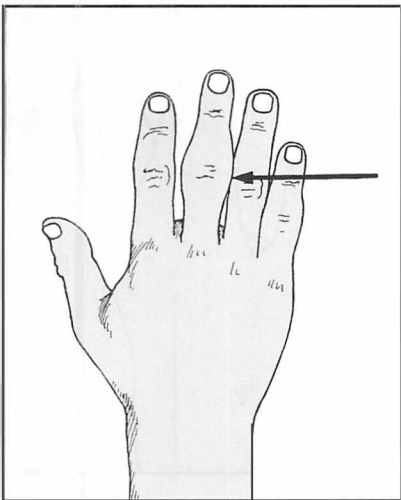
7.1. Inspection (1): Look first at the general shape of the hand and its size in proportion to the rest of the patient: e.g. in achondroplasia the fingers are short and stumpy; in acromegaly the hand is large and coarse; and in myxoedema the hand is often podgy and the skin dry.



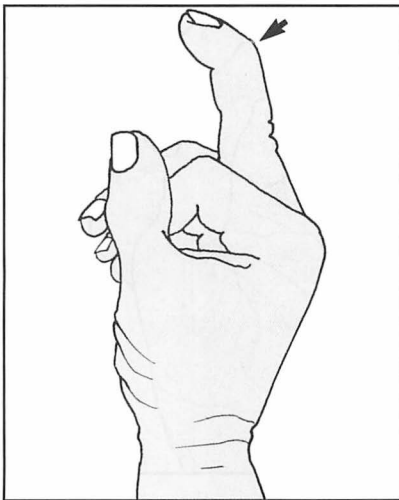
7.2. Inspection (2): In Marfan's syndrome the proximal phalanges in particular are long and thin. In Turner's syndrome the ring metacarpal is often very short. In hyperparathyroidism the fingertips may be short and bulbous, and in Down's and Hurler's syndromes the little fingers are incurved.



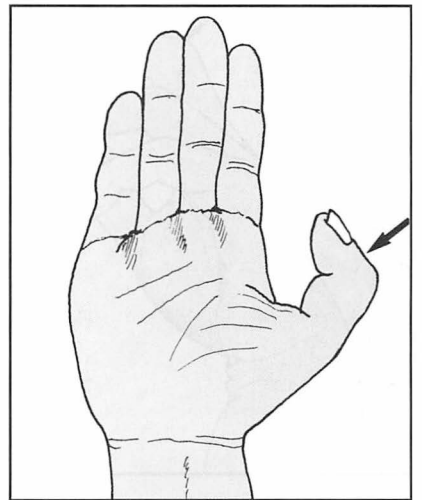
7.3. Inspection (3): Note the presence of any hypertrophy of a finger. This may occur in Paget's disease, neurofibromatosis and local arteriovenous fistula.



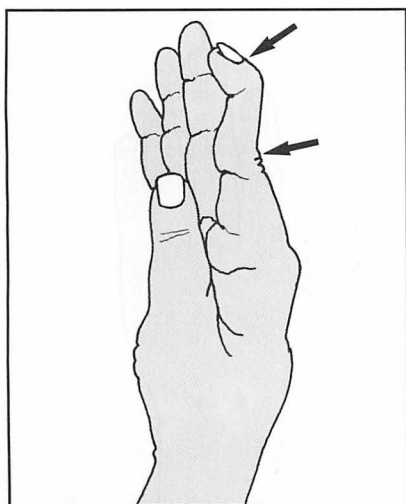
7.4. Inspection (4): Note the presence of any fusiform swelling. The commonest causes are collateral ligament tears and rheumatoid arthritis. Less commonly this is seen in syphilis, TB, sarcoidosis and gout. In psoriatic arthritis the distal joint is usually involved.



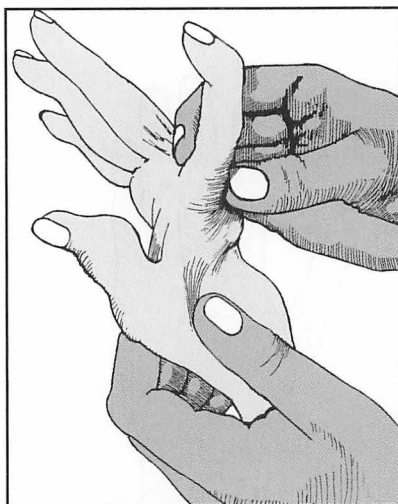
7.5. Inspection (5): Mallet finger: The distal interphalangeal joint is flexed. The patient cannot extend the terminal phalanx, although the joint can usually be extended passively. It is caused by rupture or avulsion of the extensor tendon, usually from trauma or rheumatoid arthritis.



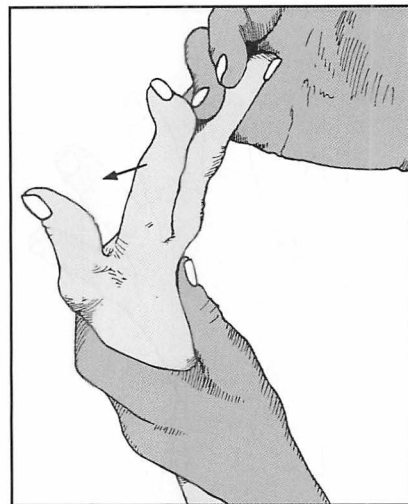
7.6. Inspection (6): Mallet thumb: Loss of active extension in the interphalangeal joint of the thumb is due to rupture of extensor pollicis longus. This is seen as a late complication of Colles' fracture, from rheumatoid arthritis, or wounds of the wrist or the thumb with tendon division.



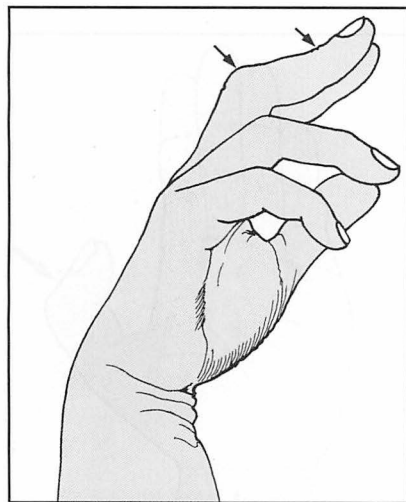7.7. Inspection (7): *Swan-neck deformity (1):* The distal interphalangeal joint is flexed and the proximal interphalangeal joint hyperextended. It is seen most often in rheumatoid arthritis, and may be produced by a number of different factors.



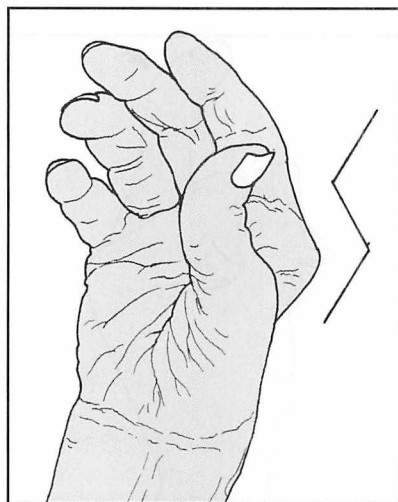
7.8. Inspection (8): *Swan-neck deformity (2):* Extend the metacarpophalangeal joint of the affected finger. Improvement in the deformity indicates that shortening of extensor digitorum communis is a factor. If the deformity is made worse, tight interossei are likely to be responsible.



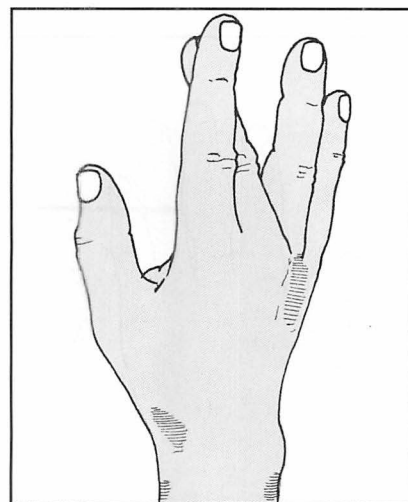
7.9. Inspection (9): *Swan-neck deformity (3):* Hold all the fingers in an extended position but leave the affected finger free. Ask the patient to flex it. If he cannot, this indicates a rupture of flexor digitorum sublimis as the cause of the deformity.



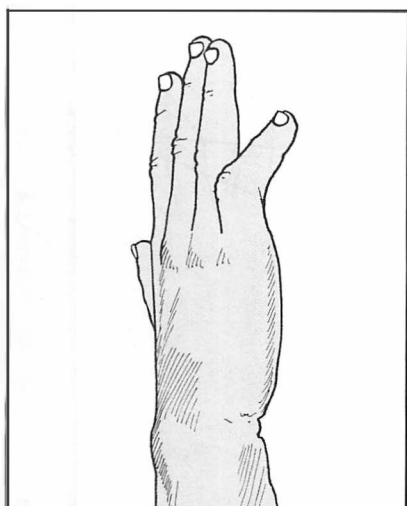
7.10. Inspection (10): *Boutonnière deformity:* The proximal interphalangeal joint is flexed and the distal joint extended. It occurs when the central extensor tendon slip to the middle phalanx is affected, by a wound on the dorsum of the finger, by traumatic avulsion, or by spontaneous rupture as in rheumatoid arthritis.



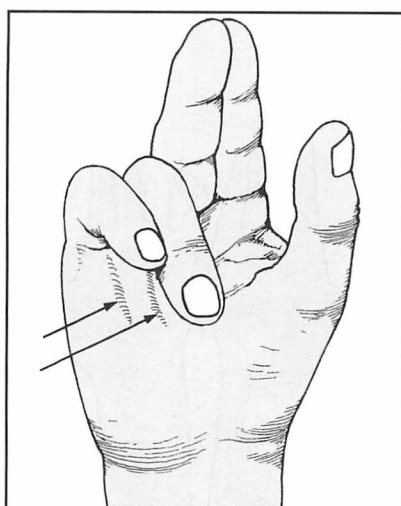
7.11. Inspection (11): *Z deformity of the thumb:* The thumb is flexed at the metacarpophalangeal joint and hyperextended at the interphalangeal joint. The deformity is seen in rheumatoid arthritis secondary to displacement of the extensor tendons or rupture of flexor pollicis longus.



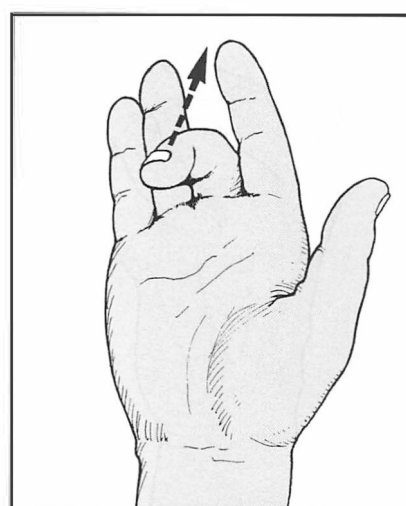
7.12. Inspection (12): Flexion of a finger at the metacarpophalangeal joint, with inability to extend, follows rupture or division of the extensor tendon in the back of the hand or at the wrist.



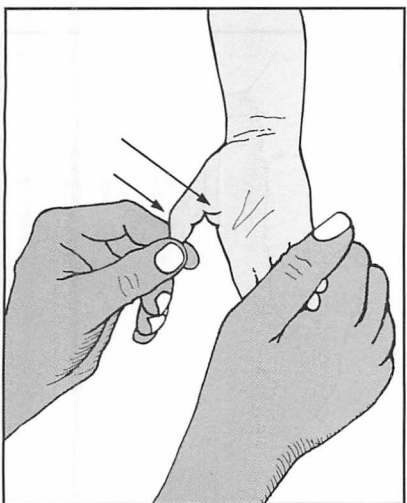
7.13. Inspection (13): Flexion of the little finger, mainly at the proximal interphalangeal joint, is seen in congenital contracture of the little finger.



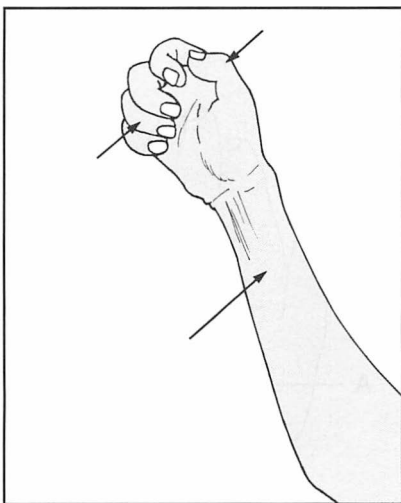
7.14. Inspection (14): Flexion of the fingers at the metacarpophalangeal and interphalangeal joints, associated with nodular thickening in the palm and fingers, is characteristic of Dupuytren's contracture. The thumb is occasionally involved.



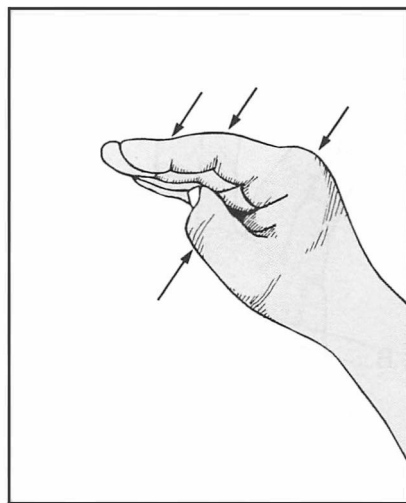
7.15. Inspection (15): Flexion of the middle or ring fingers at the proximal interphalangeal joint, with sudden extension on effort or with assistance, is seen in trigger finger. There is usually a palpable nodular thickening over the corresponding metacarpophalangeal joint.



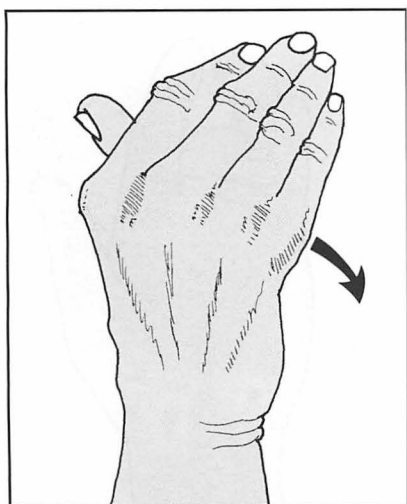
7.16. Inspection (16): Flexion of the interphalangeal joint of the thumb in infants and young children is usually due to stenosing tenovaginitis involving flexor pollicis longus. A nodular thickening is usually palpable over the metacarpophalangeal joint. The condition is said to be acquired (i.e. it is not congenital) and triggering is not a feature.



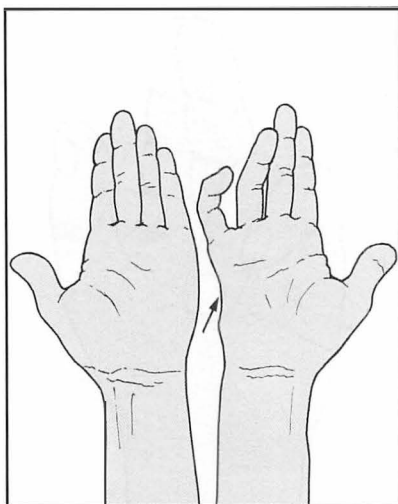
7.17. Inspection (17): In Volkmann's ischaemic contracture (which usually occurs as a sequel to brachial artery damage accompanying a supracondylar fracture) there is clawing of the thumb and fingers, and forearm wasting. The fingers can be extended if the wrist is flexed. Slight flexion of all the fingers at the MP and IP joints is sometimes seen in association with diabetes: then, when the hands are put in a praying position, there is an unclosable gap between them.



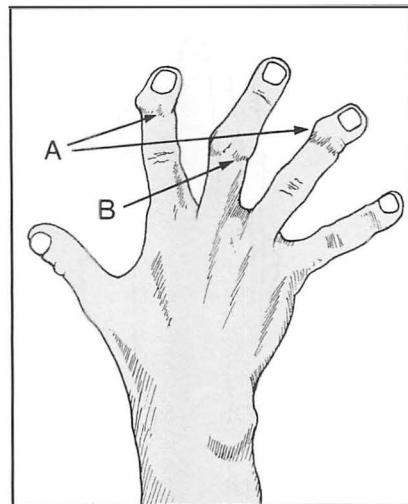
7.18. Inspection (18): Ischaemic contracture of the small muscles of the hand (usually as a result of swelling within a tight forearm plaster) leads to fingers which are flexed at the metacarpophalangeal joints and extended at the interphalangeal joints. The thumb is adducted into the palm.



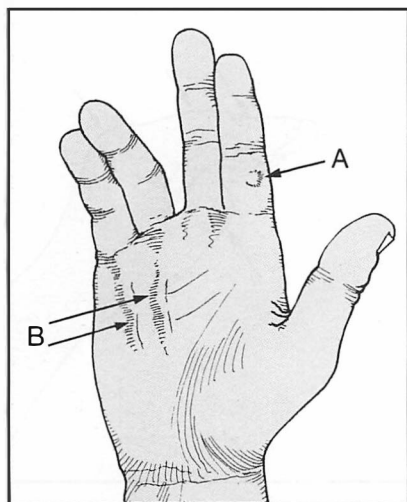
7.19. Inspection (19): Ulnar deviation of the fingers at the metacarpophalangeal joints occurs in rheumatoid arthritis. In the later stages the metacarpophalangeal joints may dislocate.



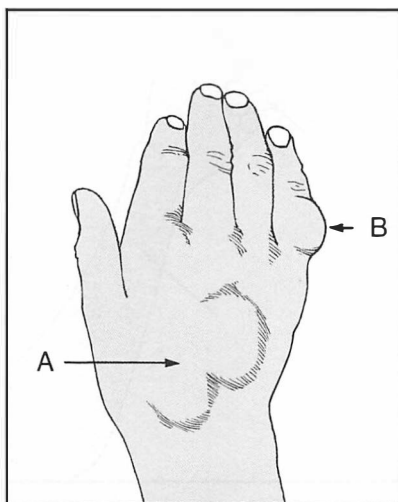
7.20. Inspection (20): Unilateral hypothenar wasting suggests a root, plexus or nerve lesion. Widespread involvement necessitates a full examination in order to exclude disorders such as generalized peripheral neuropathy, syringomyelia, multiple sclerosis and the muscular dystrophies.



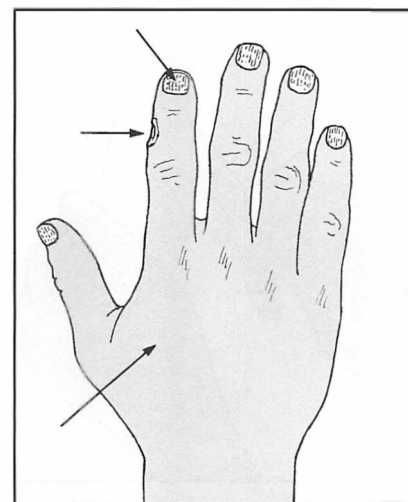
7.21. Inspection (21): Swellings (1): Note (A) Heberden's nodes on the dorsal surface of the distal interphalangeal joint. (They are often associated with deviation of the distal phalanx and are a sign of osteoarthritis of the fingers.) (B) The proximal interphalangeal joints may be similarly affected (Bouchard's nodes).



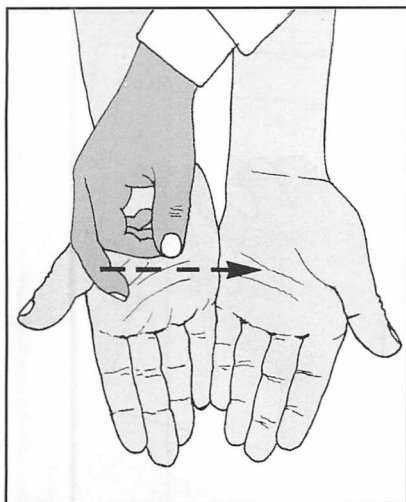
7.22. Inspection (22): Swellings (2): Note (A) firm, pea-like ganglions are common along the line of the tendon sheaths. (B) Nodular swellings of the palm and fingers accompany Dupuytren's contracture.



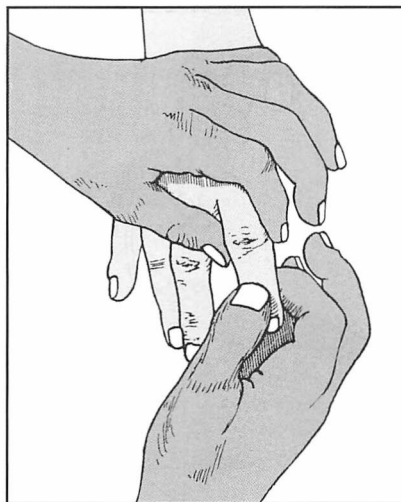
7.23. Inspection (23): Swellings (3): Note (A) isolated rheumatoid nodules or synovial swellings. (B) Enchondroma is one of the commonest bone tumours to occur in the hand. Tumours of this type are sometimes multiple, and there may be a hereditary diathesis. If small, an enchondroma may not be noticed until it declares itself with a pathological fracture.



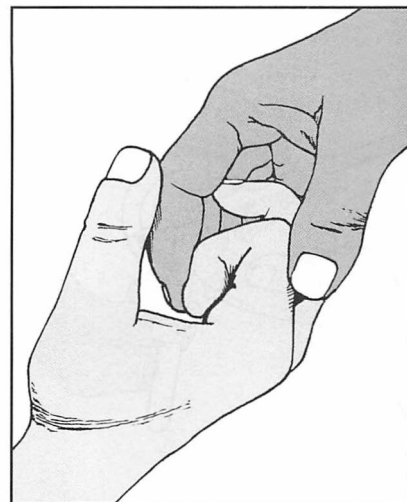
7.24. Inspection (24): Note the nutrition of the skin and nails. In the case of the nails, note any disturbance of growth, deformity, evidence of fungal infection or psoriasis. In the skin, note the presence of finger bumps or trophic ulceration, suggestive of a neurological disturbance. Note any alteration of skin colour, suggesting circulatory involvement from local arterial or sympathetic supply disturbance.



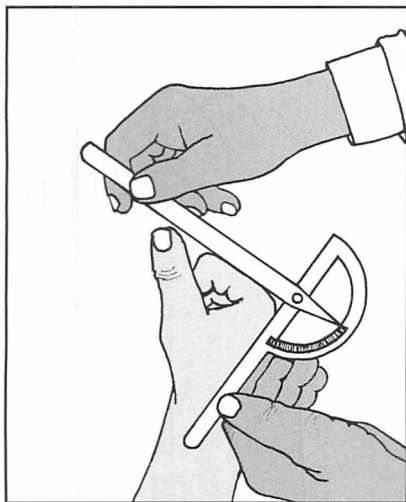
7.25. Palpation (1): Note any generalized or local disturbance of temperature or sweating in the palm or volar surfaces of the fingers. The other hand may be used for comparison.



7.26. Palpation (2): Palpate the individual finger joints between the finger and thumb, looking for thickening, tenderness, oedema and increased local heat. Note that in gouty arthritis a single joint only may be affected, especially in the early stages.



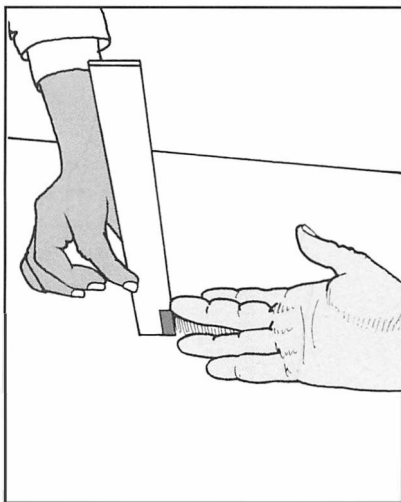
7.27. Palpation (3): Try to tuck each finger into the palm, and ask the patient to repeat this unaided. Loss of active movements only is usually due to nerve or tendon discontinuity, whereas passive loss may be due to joint or tendon adhesions or arthritis.



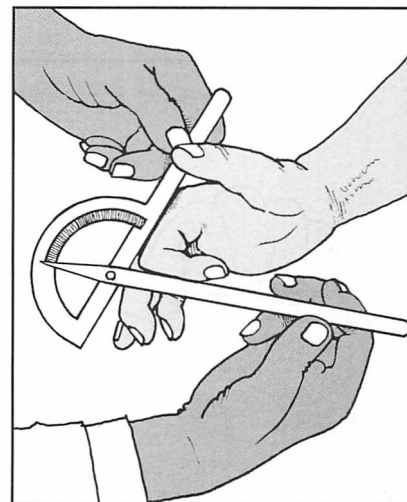
7.28. Movements (1): Where indicated for continued assessment or medicolegal purposes, both the active and the passive range in an affected finger should be recorded.

Metacarpophalangeal joint: Normal range = 0–90°.

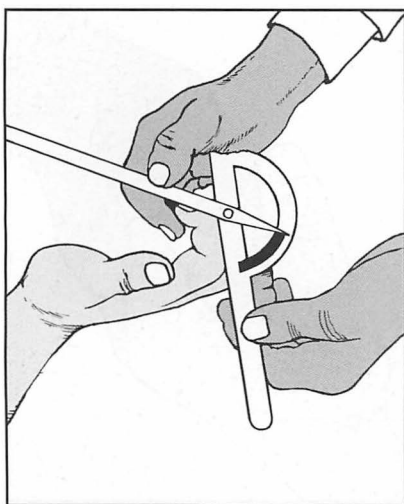
Note that the metacarpophalangeal joints can usually be passively hyperextended by up to 45°.



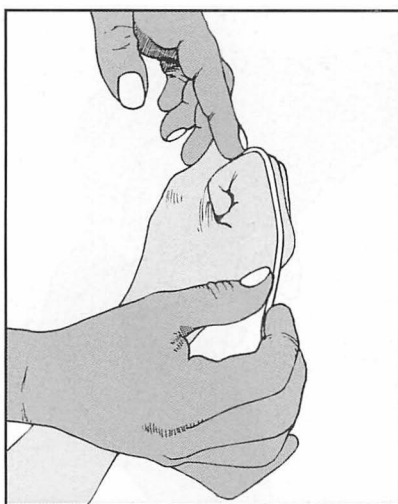
7.29. Movements (2): Alternatively, ask the patient to put his hand, palm upwards, on a table, and note the linear discrepancy between it and the tip of the affected finger as he attempts to extend it. When passive extension is possible, loss of active extension suggests division, rupture or displacement of the extensor tendons, or a posterior interosseous palsy if all are affected.



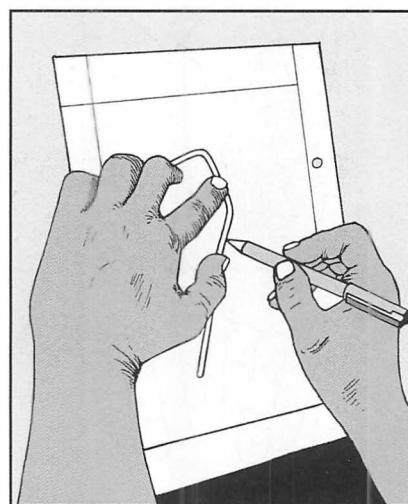
7.30. Movements (3): Proximal interphalangeal joint: Normal range = 0–100°.



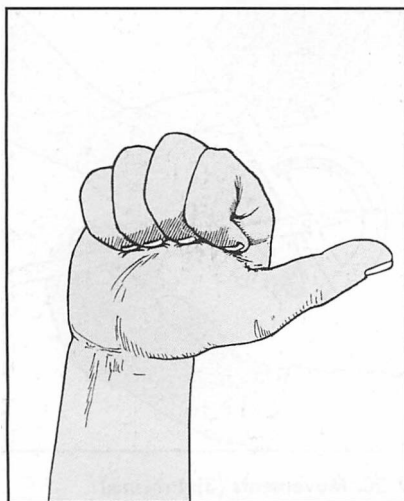
7.31. Movements (4): Distal interphalangeal joints:
Normal range = 0–80°.



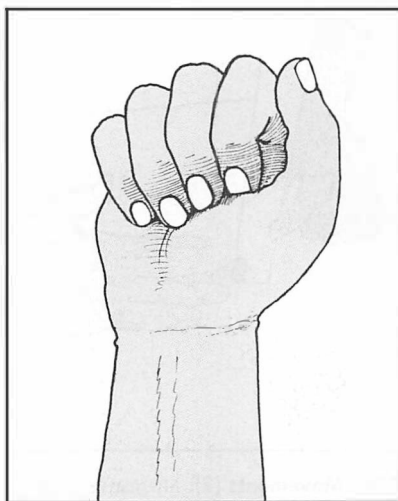
7.32. Movements (5): An alternative method of measuring the range of movements in the finger joints involves moulding a length of malleable wire over the finger (14 G, electrician's or other solder wire, approximately 2 mm in diameter is suitable).



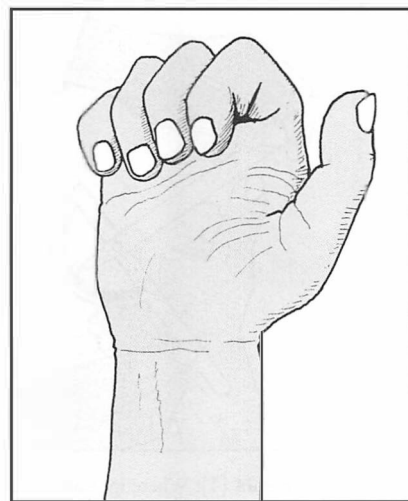
7.33. Movements (6): The wire is then transferred to the case record, and an outline drawn round it. The finger which has been examined and date should be noted. An additional record of extension may be superimposed. Subsequent assessment of progress is easily made by repeating the process.



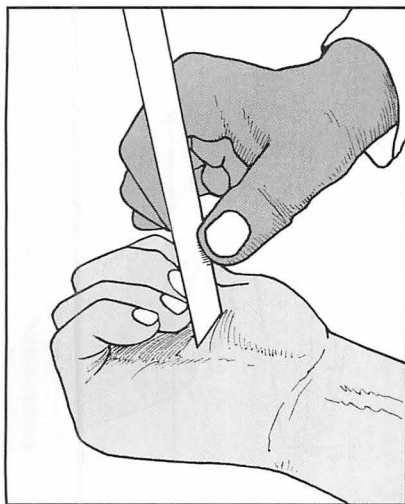7.34. Movements (7): *Total finger movements:* As all the joints of all the fingers are involved in grasping and holding, ask the patient to make a fist. Normally the distal phalanges should 'tuck in', touching the palm at right-angles.



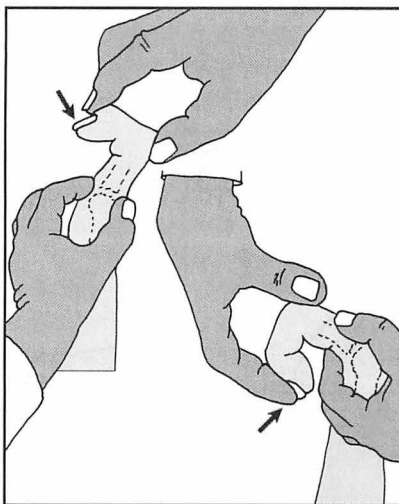
7.35. Movements (8): Only a slight loss at any level is sufficient to prevent 'tuck in'. All the fingers may be involved, as shown. If a single finger is affected its prominence will be obvious. This screening test may be carried out earlier in the examination if desired.



7.36. Movements (9): Greater reduction in movements will prevent the fingers from reaching the palm. Such a stand-off indicates more serious impairment of the patient's ability to grasp and hold.



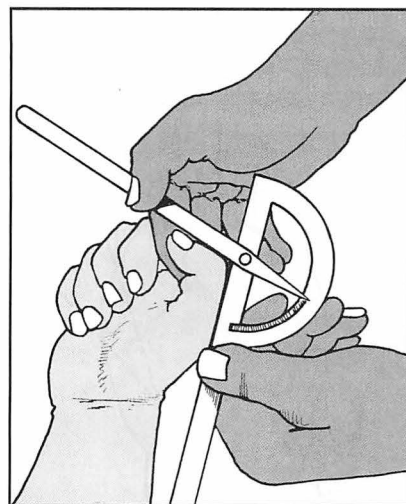
7.37. Movements (10): This important restriction of functional ability may be measured by noting the distance that the fingers stand proud of the palm on maximum flexion.



7.38. Assessment of the causes of loss of movements in the IP joints: *The*

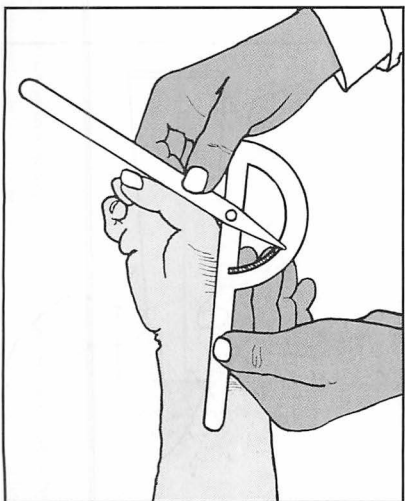
Bunnell-Littler test: Hold the MP joint of the affected finger in extension and passively flex it, noting the total movement obtained. Now repeat with the MP joint flexed, noting any difference.

Diagnosis: *if now greater,* contracture of the intrinsic muscles; *if the same,* joint capsule contractures; *if less,* an extensor tendon contracture.



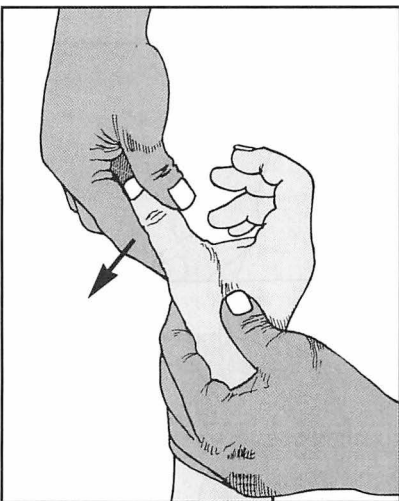
7.39. Movements (11): The thumb: The interphalangeal joint:

Normal flexion = 80°; Normal hyperextension = 20° (i.e. the IP joint can be extended 20° beyond the neutral position). Total range 100°.

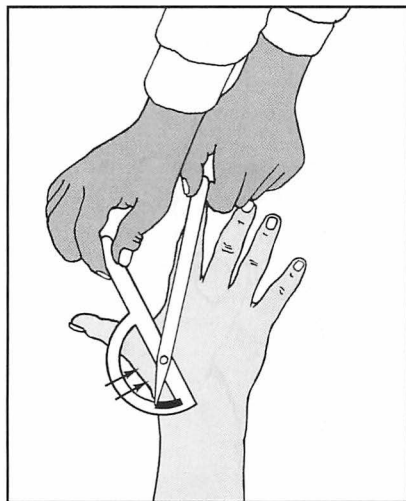


7.40. Movements (12): The thumb: The metacarpophalangeal joint:

Normal flexion = about 55°; Normal hyperextension = 5°.

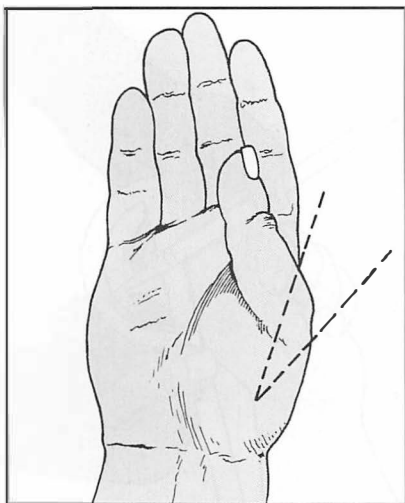


7.41. Movements (13): At this stage, test the stability of the metacarpophalangeal joint in a side-to-side plane. Extend the joint and stress the medial collateral ligament. Compare the sides. Excess mobility follows tears ("gamekeeper's thumb") and rheumatoid arthritis, and can be very disabling.



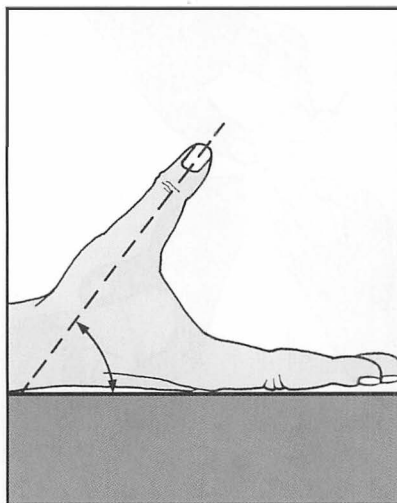
7.42. Movements (14): Carpometacarpal joint: test extension (abduction parallel to the plane of the palm) by placing the hand palm down and measuring the range from a position in contact with the index to its fully extended position.

Normal range of carpometacarpal extension = 20°.



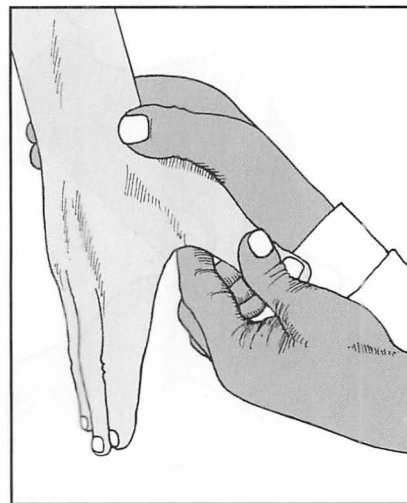
7.43. Movements (15): *Carpometacarpal joint: test flexion:* Measure this starting from the neutral position with the thumb in contact with the index.

Normal range of carpometacarpal flexion = 15°. This angle is difficult to measure, and an accurate assessment is seldom of value.

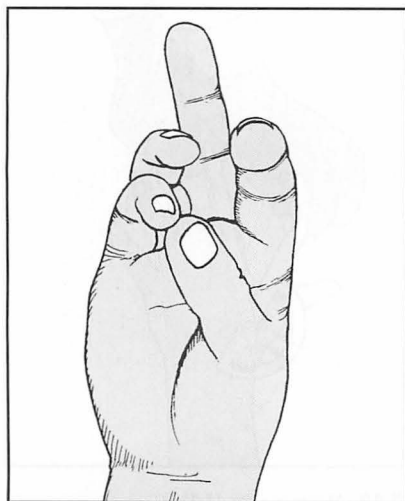


7.44. Movements (16): *Abduction of the thumb in a plane at right-angles to the palm:* The patient attempts to point the thumb at the ceiling, with the back of the hand resting on a table.

Normal range of thumb abduction = 60°.

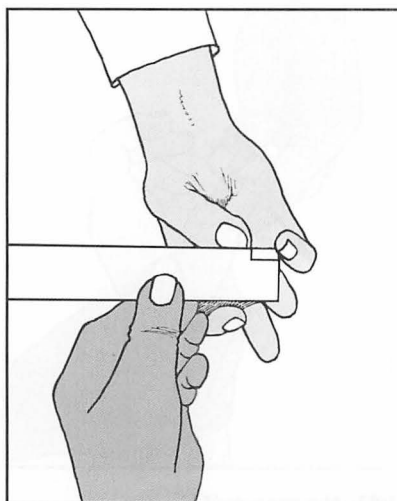


7.45. Movements (17): While examining the carpometacarpal joint of the thumb, note any crepitus in the joint. This finding is common when osteoarthritis and rheumatoid arthritis involve this joint, and there is often prominence of the base of the metacarpal.



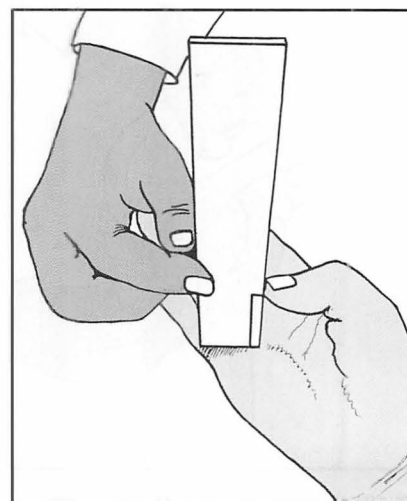
7.46. Movements (18): *Opposition (1):*

This tests several components of overall thumb and little finger movement, and involves abduction of the thumb at right-angles to the palm, and thumb flexion and rotation. Normally the thumb should be able to touch the tip of the little finger.



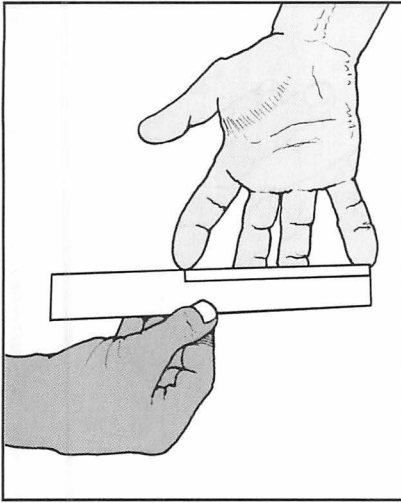
7.47. Movements (19): *Opposition (2):*

Loss of opposition may be assessed by measuring the distance between the tip of the thumb and the little finger.

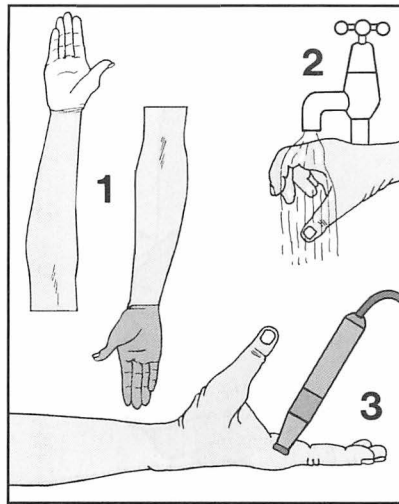


7.48. Movements (20): *Opposition (3):*

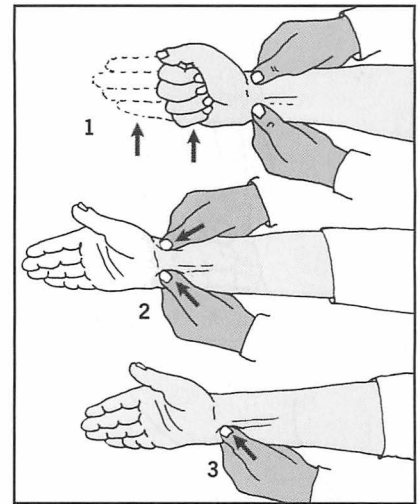
Alternatively, the distance between the tip of the thumb and the metacarpophalangeal joint of the little finger may be recorded.



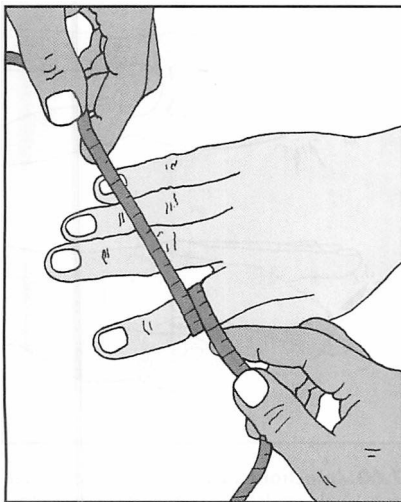
7.49. Movements (21): Finger abduction may be assessed by measuring the spread between the index and little fingers, or the spread between individual fingers. Excessive abduction of the little finger is found in Ehlers–Danlos syndrome.



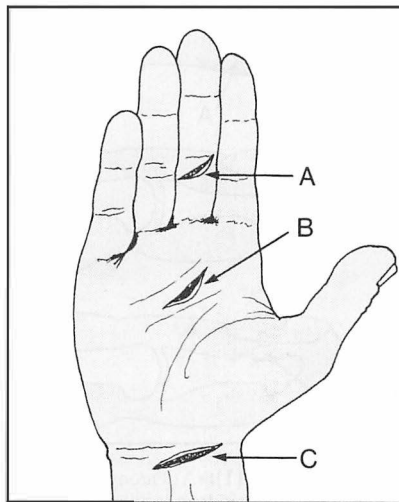
7.50. Vibration syndromes: In vibration white finger, although little clinical abnormality may be found, (1) note if the hand becomes pale on elevation, and the speed with which it pinks up on depression; (2) see if an attack is precipitated by holding the hand under cold water for 2 minutes; (3) and check the flow in the digital vessels with a Doppler flowmeter. Note that the peripheral circulation may be disturbed by oral antihypertensives.



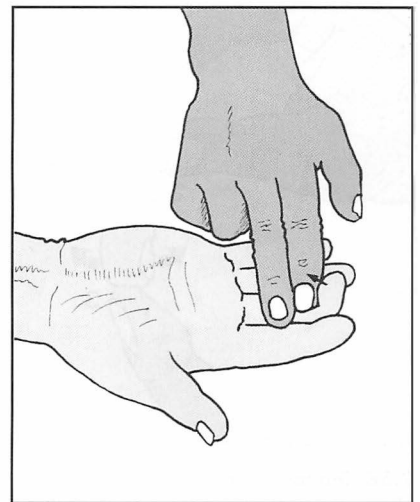
7.51. The Allen test for hand circulation: Place your thumbs over the patient's radial and ulnar arteries and get him to clench his hand three times in quick succession (1). Compress the vessels and ask him to extend the fingers. The hand should be blanched (2). Now release the radial artery and note whether the return of skin colour is delayed for more than 3 seconds (3). Repeat the test, this time releasing the ulnar artery. This gives a measure of the contribution made by each artery to the circulation of the hand.



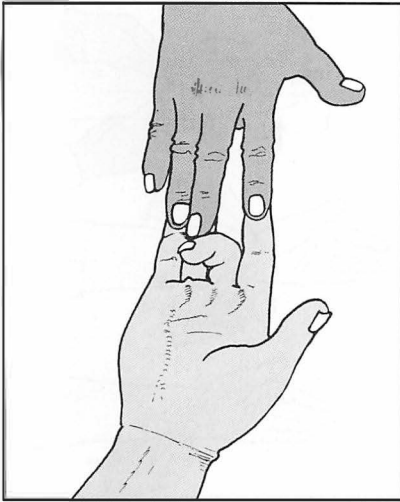
7.52. Joint thickening and swelling: The activity of the inflammatory process in a swollen joint is sometimes assessed by measuring the joint circumference from time to time. Accuracy without special equipment is difficult to achieve and the results are of limited value.



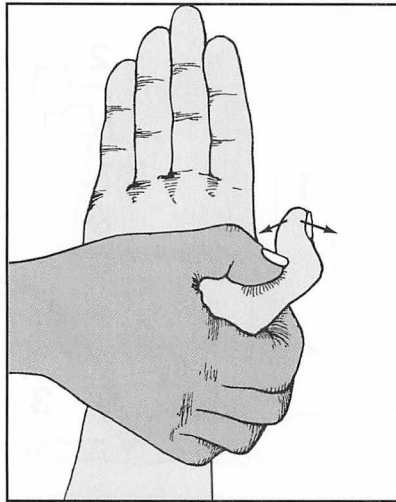
7.53. Tendon injuries (1): Note first the position of any wound, and try to work out the structures at risk, e.g. (A) flexor profundus, (B) flexor digitorum superficialis (sublimis), and if deeper, flexor digitorum profundus, (C) median nerve, flexor carpi radialis longus, flexor digitorum superficialis, and more deeply the flexor digitorum profundus tendons.



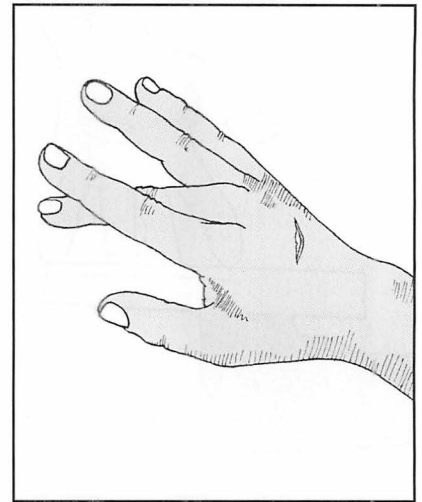
7.54. Tendon injuries (2): If the profundus tendon is suspect, support the finger and ask the patient to bend the tip. Loss of the ability to flex the terminal phalanx occurs when the flexor digitorum profundus tendon is divided.



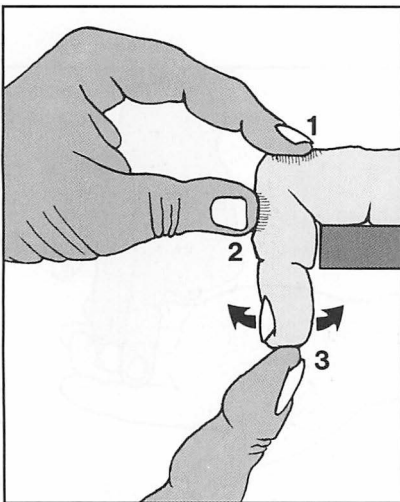
7.55. Tendon injuries (3): If the superficialis tendon is suspect, hold all the fingers except the suspect one in a fully extended position to neutralize the effect of flexor profundus. If the patient is able to flex the finger at the proximal interphalangeal joint then superficialis is intact.



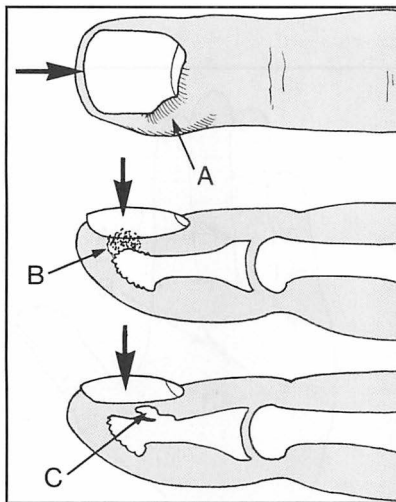
7.56. Tendon injuries (4): *Flexor and extensor pollicis longus:* Support the proximal phalanx and ask the patient to flex and extend the tip.



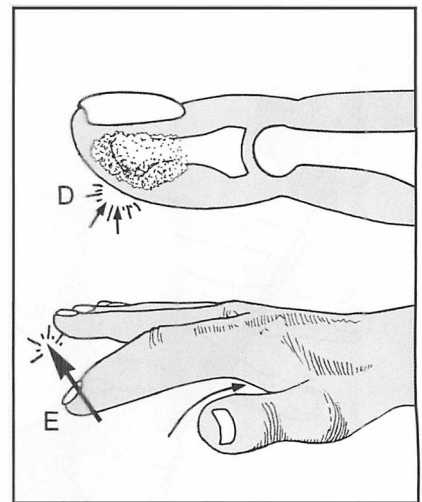
7.57. Tendon injuries (5): *Extensor digitorum communis:* Ask the patient to extend the fingers. Any extensor tendon divided on the dorsum of the hand or finger will be obvious by the lack of extension in the finger, assuming the finger joints have been checked for mobility. To assess the distal slips, grasp the middle phalanx and ask the patient to try to extend the DIP joint.



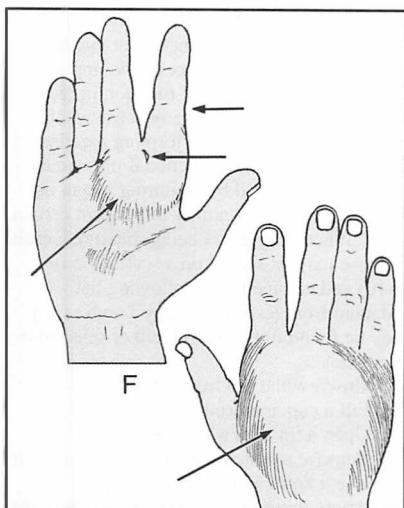
7.58. Tendon injuries (6): *Elson's middle slip test:* Flex the PIP joint of the finger over the edge of a table and steady the proximal phalanx (1). Ask the patient to try to extend the PIP joint, and feel for any activity (2): PIP extension occurs if the middle slip is intact, but the DIP joint will be flail (3). If the middle slip is ruptured, extension at the PIP joint does not occur and the DIP joint stiffens and extends.



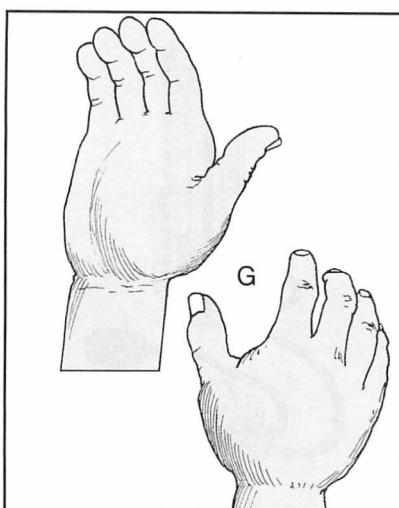
7.59. Infections (1): (A) Paronychia is the commonest infection. Pain is aggravated by pressure on the end of the nail. (B) Apical infections give pain which is aggravated by downward pressure on the nail. A subungual exostosis (C) (which can be confirmed by radiographs) may sometimes cause confusion.



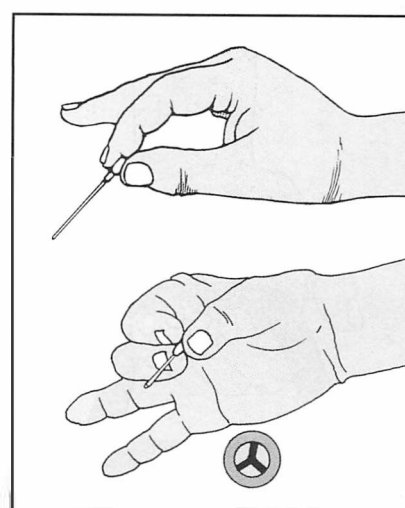
7.60. Infections (2): (D) Pulp infections are exquisitely tender and may lead to destruction of the distal phalanx. (E) Tendon sheath infections lead to a fusiform flexed finger. Any attempt to straighten the finger causes pain. Tenderness is marked and localized (usually to the base of the sheath).



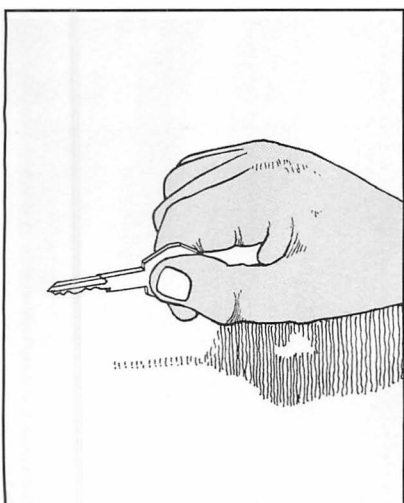
7.61. Infection (3): (F) In web space infections there is usually marked swelling of the back of the hand and web, with spreading of the fingers. Note the site of any causal wound.



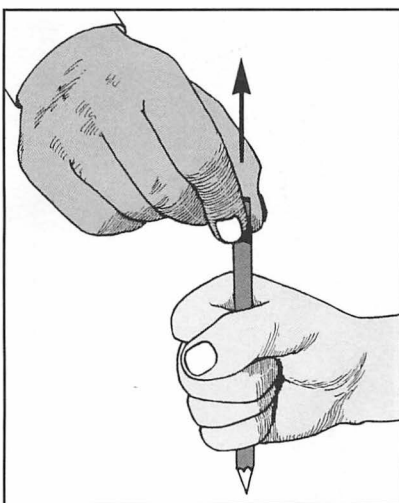
7.62. Infections (4): (G) In thenar and midpalmar space infections there is gross swelling of the hand involving both the dorsal and palmar surfaces. In the case of the thenar space, the swelling may be more pronounced on the radial side of the palm.



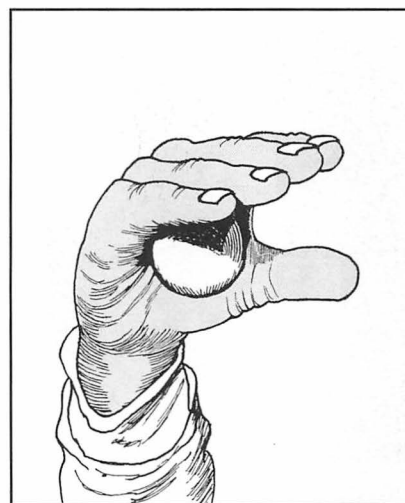
7.63. Assessment of the principal functions of the hand (1): Pinch grip: Ask the patient to pick up a small object between the tips of the thumb and index. Intact sensation is necessary for a satisfactory performance. The patient should be asked to repeat the test with his eyes closed. Note whether the tip of the adjacent middle finger can assist (chuck grip).



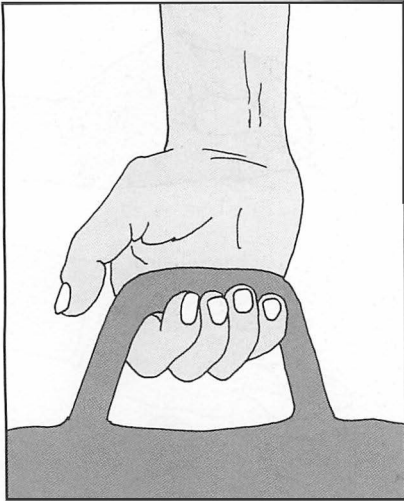
7.64. Hand function (2): Thumb to side of index grip: The patient should be asked to grip a key between the thumb and side of the index in the normal fashion. Test the firmness of the grip by attempting to withdraw the key using your own pinch grip.



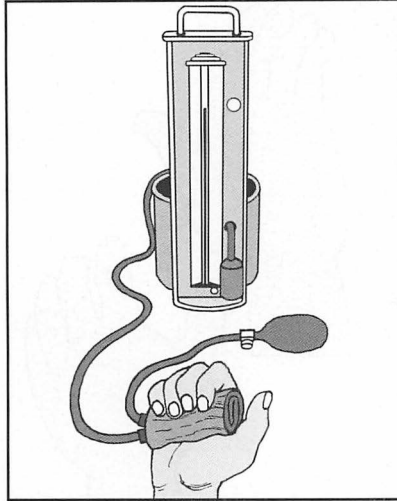
7.65. Hand function (3): Grasp: Ask the patient to grasp a pen firmly in the hand, using the thumb and fingers. Attempt to withdraw the pen and note the resistance offered. Where finger flexion is restricted, repeat using an object of greater diameter.



7.66. Hand function (4): Palmar grasp: Test the cupping action of the hand by asking the patient to grasp a small ball in the palm of the hand. Note the patient's ability to resist the ball being withdrawn.



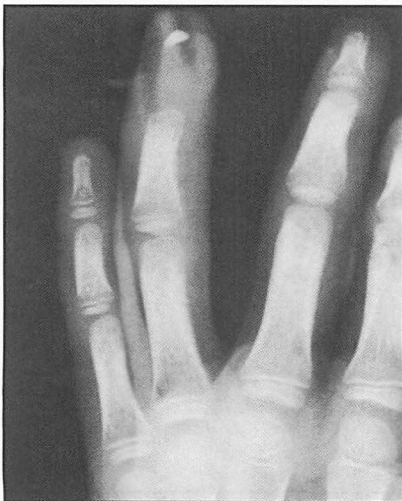7.67. Hand function (5): When function is markedly impaired, note whether hook grasp is retained.



7.68. Hand function (6): Grip strength: This may be tested using a dynamometer; alternatively, inflate a rolled sphygmomanometer cuff to 20 mmHg and ask the patient to squeeze it as hard as he can. A normal hand should be able to achieve a reading of 200 mmHg or over.

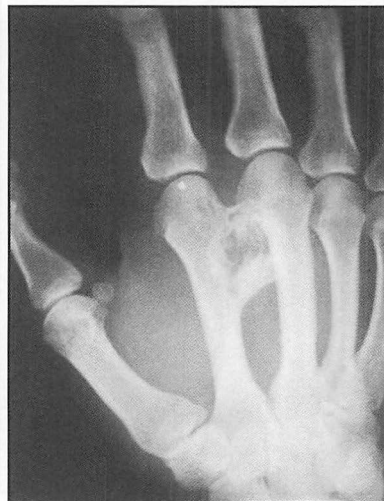7.69. Hand function (7): Bilateral function: Although the function in one hand may be assessed as described, it is important to note that impairment of function in one hand may clearly affect many activities that normally involve both performing together. The degree of overall functional impairment may be investigated by enquiring about, or testing, the patient's ability to perform certain tasks. When progress is being measured, each of these may be scored on a scale (0–5 or 0–10) and summed. The following list (adapted from tests devised by Lamb et al.) may be found to be helpful, either selected or as a whole:

1. Unscrew the top from a bottle.
2. Fill a cup and drink.
3. Open a tin with a tin-opener.
4. Remove a match from its box and light it.
5. Use a knife and fork for eating.
6. Apply paste to a toothbrush and clean the teeth.
7. Put on a jacket.
8. Do up buttons.
9. Fasten a belt round the waist.
10. Tie shoe laces.
11. Sharpen pencil.
12. Write messages.
13. Staple papers together.
14. Wrap string round a parcel.
15. Use playing cards.



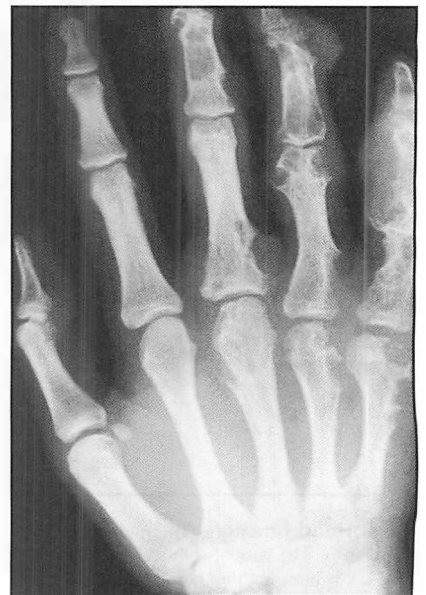7.70. Hand radiographs: examples of pathology (1): in this radiograph of a child's hand most of the terminal phalanx of the ring finger is no longer visible, and the soft tissue shadow suggests swelling of the digit.

Diagnosis: osteitis and destruction of the terminal phalanx secondary to a pyogenic infection of the pulp of the ring finger.



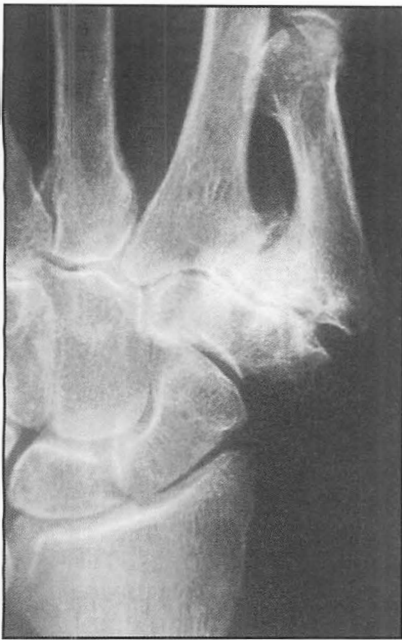7.71. Pathology (2): There is a partially ossified swelling arising from the region of the neck and distal portion of the index metacarpal.

Diagnosis: solitary (benign) enchondroma.

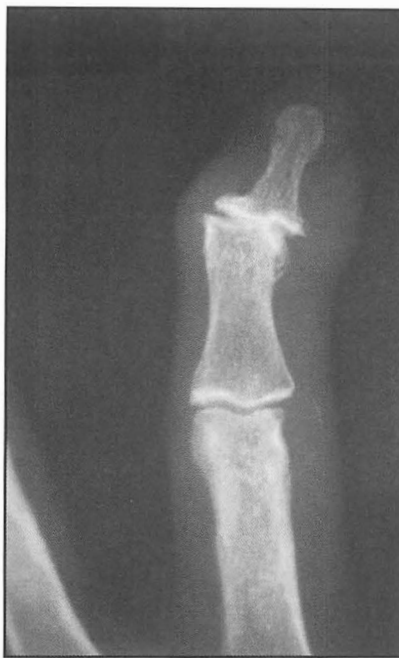

7.72. Pathology (3): The thumb and index appear quite normal, but the metacarpals and phalanges of the other fingers are distorted with many cystic tumours.

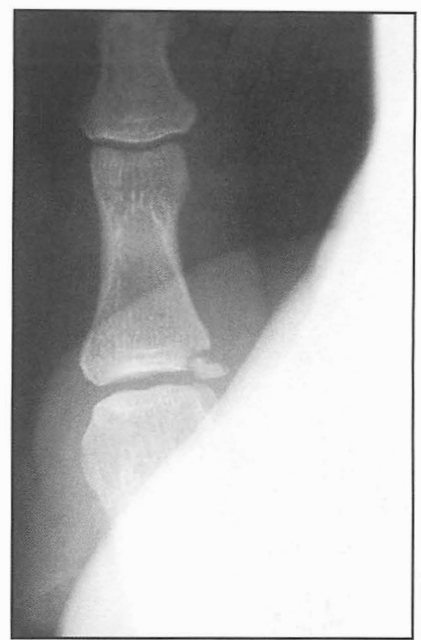
Diagnosis: multiple enchondromata typical of Ollier's disease (multiple enchondromatosis).



7.73. Pathology (4): There is broadening and distortion of the proximal end of the thumb metacarpal, narrowing of the carpometacarpal joint space, and lipping.
Diagnosis: the appearances are typical of advanced osteoarthritic changes in the carpometacarpal joint of the thumb.



7.74. Pathology (5): There is narrowing of the distal interphalangeal joint and subluxation of the distal phalanx of this finger.
Diagnosis: the appearances are typical of osteoarthritis, and Heberden's nodes were present clinically.



7.75. Pathology (6): There is a bony fragment lying in relation to the medial side of the base of the proximal phalanx of the thumb.
Diagnosis: an avulsion fracture of the base of the proximal phalanx of the thumb where the medial collateral ligament is attached. This was associated clinically with instability in the metacarpophalangeal joint (gamekeeper's thumb).

CHAPTER

8

The thoracic and lumbar spine

- The spine: anatomical features 130
- Back pain 131
- Scoliosis 133
- Kyphosis 135
- Scheuermann's disease (spinal osteochondrosis) 135
- Calvé's disease 136
- Ankylosing spondylitis 136
- Diffuse idiopathic skeletal hyperostosis (DISH) 136
- Senile kyphosis 137
- Paget's disease 137
- Tuberculosis of the spine 137
- Pyogenic osteitis of the spine 138
- Metastatic lesions of the spine 139
- Spondylolysis, spondylolisthesis 139
- Osteoarthritis (osteoarthrosis) 140
- Rheumatoid arthritis 140
- Spina bifida 140
- Spinal stenosis 141
- The prolapsed intervertebral disc (PID) 141
- Mechanical back pain 143
- Coccydynia 144
- Commoner causes of back complaints in the various age groups 145
- Inspection 146–148
- Percussion 148
- Movements 149–150
- Suspected PID 150–153
- Suspected functional overlay 151–152
- Suspected thoracic cord pathology 153
- Suspected ankylosing spondylitis 153
- Radiographs 154–160
- Pathology 160–164

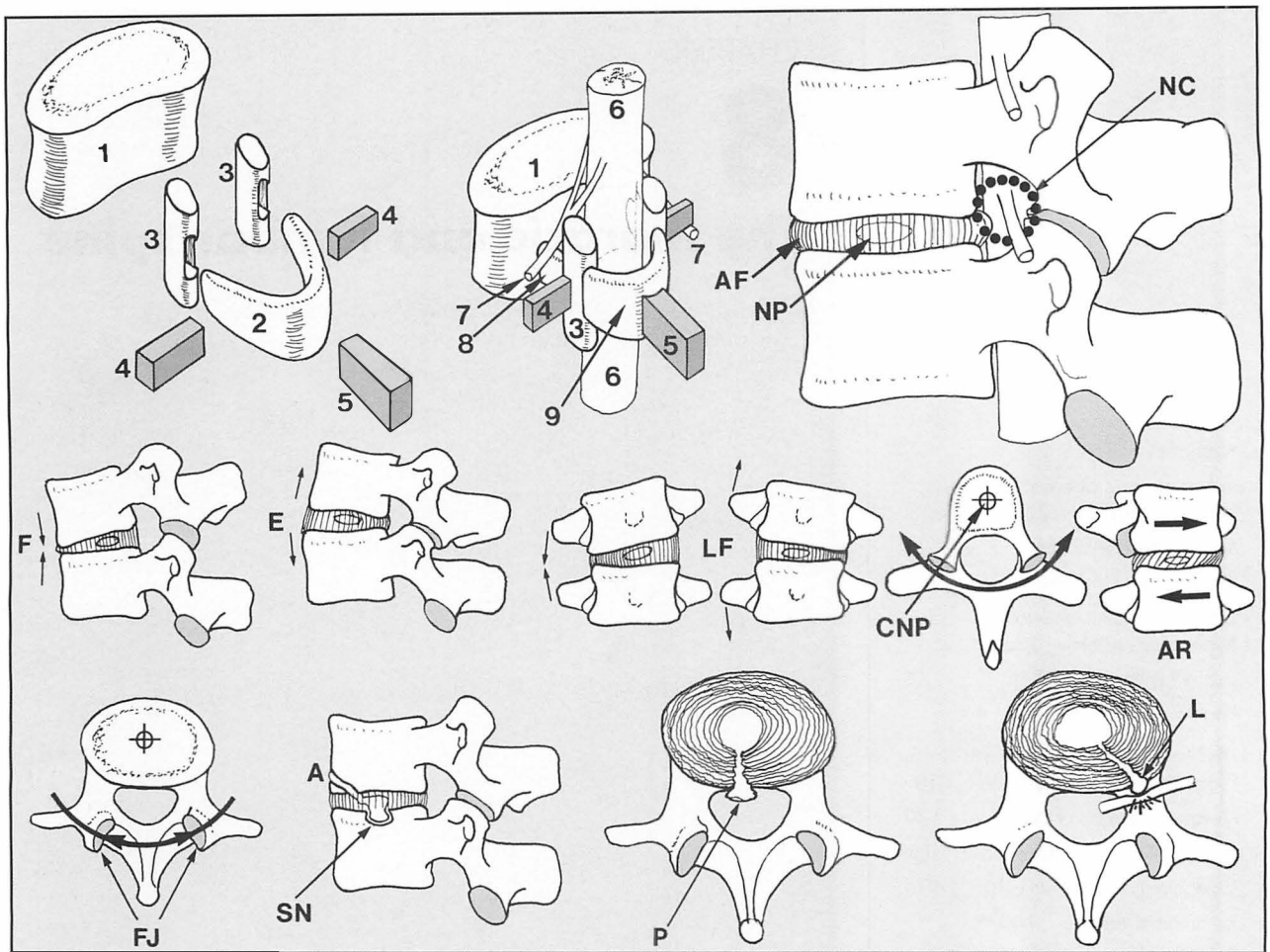


Fig. 8.A

THE SPINE: ANATOMICAL FEATURES

The complex relationships of the components of a typical vertebra may be illustrated by an exploded diagram (shown here after Kapandji). The bony elements comprise the vertebral body (1), composed of cancellous bone covered with an outer shell of cortical bone; the horseshoe-shaped neural arch (2); two articular masses or processes (3) which take part in the facet (interarticular) joints; the transverse processes (4); and the spinous processes (5). When these components are brought together they form a protective covering for the cord (6) and issuing nerve roots (7). The neural arch (2) is divided by the articular processes (3) into pedicles (8) and laminae (9).

Each vertebra articulates with the one above and below by means of the facet joints and the intervertebral discs. Each disc, lying between the hyaline cartilage endplates of adjacent vertebral bodies, is composed of a nucleus pulposus (NP) surrounded by concentric sheets of fibrous tissue (annulus fibrosis) (AF).

Movements between the vertebrae are possible in several planes, and the axes of these movements pass through the approximate centres of the intervertebral discs. At all levels of the spine, flexion (F) and extension (E),

and lateral flexion (LF) to both sides are possible. In the thoracic spine, the plane of the facet joints lies in the arc of a circle which has its centre in the nucleus pulposus (CNP); as a result, (axial) rotation (AR) is possible in this part of the spine. In contrast, the orientation of the facet joints (FJ) in the lumbar region is such that rotation is blocked, i.e. *virtually no vertebral rotation occurs in the lumbar spine*.

As a result of the elasticity of the annulus the nucleus pulposus is under constant pressure, and may (uncommonly) herniate into a vertebral body anteriorly (A), or centrally (Schmorl's node) (SN). A much more common occurrence is for the annular fibres to tear (as a result of trauma or degenerative changes) so that the nucleus can bulge posteriorly (P) or laterally (L): ('slipped discs' – central or lateral protrusions). A posterior (central) disc protrusion may affect the cord directly (or the cauda equina in the lower lumbar spine); this may lead to bilateral lower limb signs with or without bladder involvement. With lateral protrusions the neurological disturbance usually results from pressure on one or two nerve roots only, so that the effects are more localized and usually predominate on one side. In the neural canals (NC, circled, top right) the space for the segmental nerves is restricted, and in this region symptoms may be caused not only by disc prolapse but by any other pathology compromising the space available (e.g. arthritic facet joint lipping).

BACK PAIN

Back pain is one of the commonest and most troublesome of complaints; its causes are legion and an exact diagnosis is often difficult. The disability with which it is usually associated is often severe and prolonged; therapy is often ineffective, and the anxious, impatient and dissatisfied sufferer often resorts to lines of treatment which are unproven, illogical and irrational. In this difficult area it is not possible to provide a guide to pathology and diagnosis which is simple and at the same time comprehensive and foolproof.

Nevertheless, it may be helpful to consider this subject under three headings:

1. *Back pain due to clearly defined spinal pathology*, such as vertebral infections, tumours, ankylosing spondylitis, polyarthritis, Paget's disease, and primary neurological disease, osteoporotic spinal fractures, senile kyphosis, spondylolisthesis, Scheuermann's disease (spinal osteochondrosis), and osteoarthritis.
2. *Back pain associated with nerve root pain*, where the commonest causes are intervertebral disc prolapse and compression of nerve roots within the neural canals.
3. *Back pain caused by a disturbance of the mechanics of the spine* (mechanical back pain), where in the majority of cases it is not possible to discover the exact cause with any degree of accuracy. This is the largest group of conditions causing back pain, and formerly attracted many emotive but valueless names (such as lumbago, low-back strain etc).

In taking a history, examining and investigating a patient suffering from back pain, possible extraspinal causes should be excluded and an attempt should be made to place the patient in one of the three groups described above. Thereafter, and if possible, a more precise diagnosis may be attempted.

Important points in history taking:

1. Note the patient's age and occupation: both may be relevant.

2. Ask about the onset of the pain:
 - (a) When did the symptoms commence?
 - (b) Was the onset slow and insidious, rapid, or sudden? The latter is strongly suggestive of mechanical factors.
 - (c) Was there a history of an injury, such as, for example, a sudden twist or strain, or a sneeze occurring when the patient was in a flexed position? (This is a common history in cases of intervertebral disc prolapse.)
3. Ask about any directly relevant previous history:
 - (a) Is there a history of a previous similar attack?
 - (b) Is there a history of any previous trouble with the spine?
4. Ask about the site and nature of the pain:
 - (a) Where is the pain situated? Is it well localized, or is it diffuse?
 - (b) Is the pain always present, or does it disappear at times? The latter is suggestive of a mechanical cause.
 - (c) Are there any factors that aggravate or alleviate the pain? Note that with mechanical back pain bending or sudden movement may make the pain worse, whereas lying flat, particularly on a hard surface, or applying local heat, or even sitting, may relieve the pain. In the case of backache associated with spinal pathology – particularly in the case of tumour, infections or inflammatory disease – the patient may be unable to find a position of rest; constant night pain (as distinct from short-lived pain when turning in bed) is a feature.
5. Ask about radiation of the pain:
 - (a) Does the pain radiate into the legs?
 - (b) If so, exactly how far down does the pain go, and what area is involved? (Note that the commonly affected roots of the sciatic nerve (L4, L5, S1) supply areas of sensation *below* the knee.)
 - (c) What is the pain like?
 - (d) Is there paraesthesia?

Note that pain radiating into the legs is not necessarily due to nerve root involvement: it seems that irritation of facet joints, ligaments and muscles may produce dull, aching pain in the buttocks and backs of the thighs. In contrast, pain arising from nerve roots is usually sharp and knife-like, and in addition, in the case of the commonly affected L5 and S1 roots, it often extends below the knee to the ankle or foot. In the common situation where there is involvement of one, or at the most two, nerve roots, the whole limb cannot be affected; instead, the area of sensory disturbance should correspond with the relevant dermatome(s); and it should be noted whether paraesthesia occurs within the same restricted territory.
6. Ask about motor involvement:
 - (a) Has the patient noted any weakness in the lower limbs, or any muscle wasting or fibrillation?
 - (b) Has there been any disturbance of gait or balance, any tendency to giving-way of the legs, any sign of drop foot?
7. Make enquiries in the following areas:
 - (a) Has there been any malaise, fever, or involvement of other joints?
 - (b) Has there been any weight loss?
 - (c) Has the patient had any large bowel or other gastrointestinal problem?
 - (d) Have there been any genitourinary symptoms, especially retention or incontinence?
 - (e) Has the patient had any respiratory difficulty?

- (f) Has the patient any symptoms suggestive of a major neurological disturbance?

A positive answer to any of these questions will generally necessitate appropriate further investigation. The possibility of an invasive primary tumour or metastatic lesion must always be kept in mind, and examination of the abdomen, rectum, and common sites of primary tumour is wise if there is any likelihood of malignancy.

The spine should then be examined clinically: if the symptoms have remained unchanged over a 2-week period, radiological examination and estimation of the sedimentation rate should be carried out. At this stage any well defined spinal pathology should be detected (such as spondylolisthesis, ankylosing spondylitis, osteitis of the spine etc.). If conditions such as these have been eliminated, the question as to whether the symptoms are due to a prolapsed intervertebral disc should be considered. The history, clinical findings, and plain radiographs of the spine should be in harmony before it is reasonable to make this diagnosis. By the process of elimination, if a diagnosis has not yet been made the patient is likely to be suffering from mechanical back pain: but note that both the history and findings should be in accord with this. If not, caution must be exercised, close surveillance should be maintained, and further investigation may be indicated.

SCOLIOSIS

Scoliosis is primarily a lateral curvature of the spine, but there is often a degree of associated kyphosis. Mathematical analysis of the curves has revealed several distinct patterns, which are dependent on the relative contributions of these two deformities.

In the management of any case, the first and most important decision to make is whether there is any deformity of the vertebrae (structural scoliosis). If the vertebrae are normal (non-structural scoliosis) the deformity is usually due to one of the following conditions: it may be *compensatory*, resulting from tilting of the pelvis from real or apparent shortening of one leg. It may be *sciatic* and due to unilateral protective muscle spasm, especially that accompanying a prolapsed intervertebral disc. *Postural scoliosis* occurs most commonly in adolescent girls and generally resolves spontaneously.

In *structural scoliosis* there is alteration in vertebral shape and mobility, and the deformity cannot be corrected by alteration of posture. A careful history and examination is required in an attempt to find a cause and give a prognosis, the two factors on which treatment depends. Structural scoliosis may be *congenital*, the deformity being due, for example, to a hemivertebra (only half of a single vertebra is fully formed), fused vertebrae, or absent or fused ribs.

In *paralytic scoliosis* the deformity is secondary to loss of the supportive action of the trunk and spinal muscles, nearly always as a sequel to anterior poliomyelitis.

Neuropathic scoliosis is seen as a complication of neurofibromatosis, cerebral palsy, spina bifida, syringomyelia, Friedreich's ataxia and neuropathic conditions. Primary disorders of the supportive musculature of the spine are responsible for *myopathic scoliosis* (e.g. in muscular dystrophy, arthrogryphosis). *Metabolic scoliosis* is uncommon, but occurs in cystine storage disease, Marfan's syndrome and rickets.

Idiopathic scoliosis is the commonest and by far the most important of the structural scolioses, and its cause remains obscure. Several vertebrae at one or, less commonly, two distinct levels are affected (*primary curve*). In the area of the primary curve there is loss of mobility (the fixed curve) and rotational deformity of the vertebrae (the spinous processes rotate into the concavity, and the bodies that carry the ribs in the thoracic region rotate into the convexity). Above and below the fixed primary curves, *secondary* curves which are mobile develop in an effort to maintain the normal position of the head and pelvis. The spinal deformity is accompanied by shortening of the trunk (which may be assessed by using anthropometric tables of normal values) and there is often impairment of respiratory and cardiac function. In severe cases this may lead to invalidism. Cor pulmonale may feature in cases where the primary curve exceeds 80°.

Once scoliosis has appeared in the growing child the natural tendency is to deterioration. The prognosis of a given case is dependent on the age of onset, the level of the spine affected, the size and number of the primary curves, and the type of structural scoliosis (e.g. idiopathic or congenital). Deterioration may stop when skeletal maturity is reached, but sometimes continues as a result of disc degeneration and vertebral subluxation: 17° deterioration in 70° thoracic curves, and 20° deterioration in 30° lumbar curves have been recorded. Generally speaking, the higher the level of the spine involved in the primary curve, and the younger the patient, the worse the prognosis. There is the notable exception that in some cases occurring in infancy there is spontaneous recovery, which is as remarkable as its mysterious onset. Favourable factors are left-sided curves occurring in the first year of life in males where there is a rib-vertebral angle of less than 20°. Life expectancy may be reduced in congenital and paralytic scolioses, but not in idiopathic scoliosis.

In all cases of structural scoliosis appropriate investigation, radiographic measurement of the curves and careful observation is essential. Note in particular:

1. Syringomyelia is present in 25% of cases of juvenile idiopathic scoliosis. As decompression may lead to improvement, and failure to decompress before attempted surgical correction or stabilization may lead to neurological complications, an MRI scan is mandatory in all cases of juvenile idiopathic scoliosis.
2. Scoliosis is not normally a painful condition at onset. When there is pain (especially night pain relieved by aspirin) the commonest cause in the adolescent is an osteoid osteoma of a pedicle.

Treatment may be advised in the face of a poor prognosis, evidence of rapid deterioration, or for cosmetic purposes. (Curves are not usually considered for correction unless they are in excess of 25–30°.) The methods available are highly specialized, as is the decision regarding their use and timing. Deterioration in a curve may be controlled by use of the Milwaukee brace (a device incorporating moulded supports for the chin, occiput and pelvis, interconnected by vertical metal struts). This support is employed in older children approaching skeletal maturity who have just acceptable curves, or it may be used in the young child until an age suitable for spinal fusion (10 or over) is reached. Other patterns of support are available, although none has been shown to have statistical superiority (and some doubts have been recently cast on their overall effectiveness). Fusion of the entire primary

curve is aimed at preventing further deterioration and at allowing braces to be discarded. Prior to fusion it is necessary to correct the primary deformity as much as is possible. Often a hinged plaster spica (Risser jacket) or the surgical insertion of internal apparatus (e.g. Harrington instrumentation) is employed.

KYPHOSIS

Kyphosis is the term used to describe an increased convexity of the thoracic spine. This is usually obvious when the patient is viewed from the side. (*Diminution* of the lumbar concave curve is referred to as loss of lumbar lordosis or flattening of the lumbar curvature; in extreme cases there is reversed lordosis, or posterior convexity of the lumbar curve.)

Kyphosis generally affects a major part of the thoracic spine (i.e. several vertebrae are affected), and the increased curvature is then said to be *regular*. In *angular* kyphosis, which must be carefully distinguished, there is an abrupt alteration in the thoracic curvature which is usually accompanied by undue prominence of a spinous process (gibbus).

Where mobility is normal in the kyphotic spine, the deformity is most frequently postural in origin; this is often seen (as is postural scoliosis) in adolescent girls. In some cases the deformity is secondary to an increased lumbar lordosis (which in turn may be due to abnormal forward tilting of the pelvis, and sometimes to flexion contracture of the hips or congenital dislocation of the hips). Less commonly, kyphosis may result from muscle weakness secondary to anterior poliomyelitis or muscular dystrophy.

When the thoracic curvature is not mobile but fixed, the most frequent causes are senile kyphosis, Scheuermann's disease (spinal osteochondrosis), ankylosing spondylitis and Paget's disease. When there is an angular kyphosis the most common causes are tuberculous or other infections of the spine, fracture (traumatic or pathological, e.g. secondary to osteoporosis), or tumours. In adults the commonest tumour is the metastatic deposit, and in children the eosinophilic granuloma.

SCHEUERMANN'S DISEASE (SPINAL OSTEOCHONDROSIS)

This condition (whose exact aetiology is unknown, although there is a strong familial tendency), results in a growth disturbance of the thoracic vertebral bodies which in lateral radiographs of the spine are seen to be narrower anteriorly than posteriorly (anterior wedging). There may be associated back pain. The diagnostic protocol for the condition specifies that no fewer than three adjacent vertebrae should have at least 5° of anterior wedging. The epiphyses of the vertebral bodies are often irregular and may be disturbed by herniations of the nucleus pulposus. Nuclear herniation may occur between the epiphyses and bodies anteriorly, or into the centre of the bodies (Schmorl's nodes). Mobility is impaired, thoracic kyphosis is regular and often quite marked, and there is a compensatory increase in lumbar lordosis. Secondary osteoarthritic changes may supervene in the thoracic and lumbar spine.

The normal upper limit of the convexity of the thoracic spine (as measured by the Cobb method) is reckoned to be 45°, and cases of Scheuermann's disease in adolescence with curves of 50° or less should be observed. Where the curve is in excess of this, a Milwaukee brace, worn

continuously for not less than 12–18 months (and afterwards till skeletal maturity) may be advised in an attempt to prevent deterioration. (Some question the efficacy of this method of spinal bracing.) If the curve cannot be controlled and reaches 75° , correction by surgical instrumentation should be considered. In the adult with uncontrollable pain and a curve in excess of 60° , surgical fusion may be performed.

CALVÉ'S DISEASE

Back pain in children may be accompanied by gross flattening of a single vertebral body. Symptoms usually resolve spontaneously. In many cases the pathology is due to an eosinophilic granuloma.

ANKYLOSING SPONDYLITIS

In this disease there is progressive ossification of the joints of the spine; its aetiology is unknown but there is a hereditary tendency, with the overall risks of children of an affected parent developing the condition being 1 in 6. The incidence is greatest in males during the third and fourth decades. Unlike rheumatoid arthritis, to which it is often related, it is comparatively rare in women.

The joints between T12 and L1 are often first affected, but the rest of the thoracic and lumbar spine is rapidly involved. The costovertebral joints are usually affected, leading to a reduction in chest expansion and vital capacity. Pulmonary tuberculosis, or pulmonary infections with *Aspergillus* are sometimes found as a complication. Stiffness of the back and pain are the presenting symptoms in the majority of cases, but on occasion involvement of the knees or hips may first attract attention. There may be pain at the insertions of the Achilles tendons or the plantar fascia (enthesopathy).

The disease is progressive, and although it sometimes arrests spontaneously at an early stage it usually leads to complete ankylosis of the spine, with characteristic changes in the radiographs (bambooning of the spine). Progressive flexion of the spine may be severe, so that forward vision becomes impossible as the head is flexed on to the chest. The sacroiliac joints are almost invariably involved at an early stage, and there may be fusion of the manubriosternal joint. There may be a history of iritis or its sequelae. The sedimentation rate is high (40–120 mm/h), rheumatoid factor is not present, and estimations of HLA-B27 are usually positive. There is often associated anaemia, muscle wasting and weight loss.

The progress of ankylosing spondylitis may be controlled by anti-inflammatory drugs, and sometimes deep X-ray therapy (in spite of the risks of aplastic anaemia) is used. Where deformity of the spine is gross, spinal osteotomy is occasionally undertaken to give the patient a tolerably erect posture. Replacement arthroplasty of the hips or knees is often carried out, even if these joints have progressed to fusion.

DIFFUSE IDIOPATHIC SKELETAL HYPEROSTOSIS (DISH)

This comparatively benign condition, also known as Forestier's disease, is sometimes mistaken for ankylosing spondylitis. It is characterized and diagnosed by the presence of flowing calcification and ossification along the anterolateral borders of at least four contiguous vertebral bodies. The disc

spaces are, however, preserved (unlike in ankylosing spondylitis), without loss of height or other degenerative changes, and the sacroiliac and the facet joints do not ankylose. Most cases are asymptomatic, or have mild or moderate restriction of movements in the parts of the spine affected. No treatment is effective.

SENILE KYPHOSIS

In true senile kyphosis the ageing patient becomes progressively stooped and shorter in stature through degenerative thinning of the intervertebral discs. Pain may occur if there is associated osteoarthritis.

In elderly women the kyphosis may be aggravated by senile osteoporosis or osteomalacia, which lead to anterior vertebral wedging and often pathological fractures. There is usually radiographic evidence of decalcification, the serum chemistry may be disturbed, and pain is a feature if there are recent vertebral body fractures.

Treatment is directed towards controlling the underlying osteoporosis or osteomalacia. Thoracic spinal supports are not particularly effective and cannot be tolerated by the elderly, but often a simple lumbar corset is helpful in relieving pain arising from the secondary increase in lumbar lordosis.

PAGET'S DISEASE

Paget's disease of the spine is comparatively uncommon, and although the diagnosis is made on the radiographic findings, it may be suggested clinically by other stigmata of the disease. Paget's disease may lead to disturbance of cord function, which may often be successfully treated with bisphosphonates (e.g. etidronate and pamidronate).

TUBERCULOSIS OF THE SPINE

Bone and joint tuberculosis is uncommon in Britain, but the incidence is increasing. The factors responsible include the increase in numbers of immunosuppressed individuals, the development of drug-resistant strains of *Mycobacterium tuberculosis*, and an ageing population. HIV is the leading risk factor for the reactivation of latent tuberculous infections. The World Health Organization reckons that a third of the global population is infected with the organism, and that it is the commonest cause of death and disability on a worldwide basis. About a fifth of newly diagnosed cases are extrapulmonary, and the spine is involved in 50% of cases of bone and joint tuberculosis.

The onset of spinal tuberculosis is often slow, with aching pain in the back and stiffness of the spine. There may be fever and weight loss. Radiographs taken in the earliest stages of the disease show narrowing of a single disc space; later, as the anterior portions of the vertebral bodies become progressively involved, they collapse, leading to anterior and sometimes lateral wedging of the spine. This may produce angular kyphotic or scoliotic deformities. The local abscess may expand and track distally.

The spinal cord may be compromised extrinsically or intrinsically, and weakness of the limbs or paraplegia may ensue. *Extrinsic* causes include caseous abscesses, granulation tissue and fluid, sequestered bone or disc

material, and spinal angulation leading to kinking of the cord over an internal gibbus. *Intrinsic* causes include the spread of tuberculous inflammation through the cord and meninges.

Initial investigation should include radiographs of the chest, culture of urine and any sputum, Mantoux testing, brucellosis complement fixation testing and, in the case of the lumbar spine at least, an IVP (renal spread being not uncommon). CT and MRI scans of the spine are also invaluable in demonstrating the extent of bone and soft tissue involvement.

The clinical and radiological features of tuberculosis of the spine are mimicked in the early stages by other infections (especially those due to *Staphylococcus aureus*), and the only certain method of establishing the diagnosis in the majority of cases seen at this stage is by obtaining specimens for histological and bacteriological examination. CT-guided needle aspiration biopsy may be employed if this facility is available. Again, as the abscess is small at first and the early removal of necrotic bone and pus is generally of value from the point of view of accelerating healing, many surgeons combine these procedures. In the later stages, where there is gross bone destruction, minimal new bone formation and the formation of large abscesses, the diagnosis is seldom in doubt.

The aim of treatment is to overcome the infection, eliminate abscesses and sequestra, and promote sound fusion in the affected spinal segment to prevent any recrudescence. The mainstay of treatment is the use of the antituberculous drugs, although the emergence of resistant strains is causing problems. Sensitivity testing is advisable, and drugs should not be used in isolation. Drug therapy for periods up to 2 years was formerly advised, but it has been shown that regimens employing a combination of rifampicin and isoniazid for 6 months only seem equally effective. This is of particular importance where compliance is low. It has been noted that the addition of streptomycin to the drug regimen, bed rest, or a plaster cast do not seem to affect the outcome.

Conservative treatment alone leads to a comparatively low fusion rate, and in about 70% of adult cases there is a deterioration in the kyphosis. In those parts of the world where resources are good, there is at present a trend to early surgical intervention to achieve or accelerate the healing process and assist fusion by early drainage of abscesses and bone grafting. Where paraplegia is due to intrinsic causes, it may resolve following antituberculous therapy, but in many cases the causes are extrinsic, and surgery is indicated to decompress the cord. An MRI scan may give valuable assistance in selecting cases and delineating the scope of the surgery required. If adequately dealt with in the early stages (i.e. within 6–9 months of the onset of paraplegia) complete cure is often achieved. In paraplegia of late onset, where the cord is often acutely angled over an internal gibbus, surgical intervention should always be carried out, but the *prognosis here is less good*.

PYOGENIC OSTEITIS OF THE SPINE

Pyogenic osteitis of the spine is relatively uncommon. In the early stages of the disease differentiation from tuberculosis of the spine is often extremely difficult, so that the diagnosis may not be clearly established unless material is provided for bacteriological examination. Specimens may be obtained by needle biopsy with the use of an image intensifier, or by exploration. At a

later stage (and many cases may delay in their presentation) exuberant new bone formation in the region of the lesion may favour this diagnosis. The presenting features are of pain and stiffness in the back, often insidious in onset, but sometimes occurring quite rapidly. Nearly all cases resolve with prolonged treatment with the appropriate antibiotic (the majority are due to a staphylococcal infection, but *Salmonella*, *B. typhosus* and other organisms are sometimes causal).

METASTATIC LESIONS OF THE SPINE

Metastatic disease of the spine is seen particularly in the elderly and may be complicated by paraplegia. The diagnosis is made on the radiographic findings. Treatment of the uncomplicated lesion is dependent on the nature of the primary tumour; in some cases deep X-ray therapy and supportive measures may help the local lesion and give relief of pain. Where paraplegia is present, decompression should be undertaken unless the case is terminal. Primary tumours of the spine are rare; the common types are mentioned in the Cervical spine section.

SPONDYLOLYSIS, SPONDYLOLISTHESIS

In the erect position there is a tendency for the body of the fifth lumbar vertebra (carrying the weight of the trunk) to slide forwards on the corresponding surface of the sacrum, as the plane of the L5–S1 disc is not horizontal but slopes downwards anteriorly. This movement is usually prevented by the downward-projecting inferior articular processes of the fifth lumbar vertebra impinging on the corresponding upward-projecting articular processes of the sacrum. This mechanism may fail if there is a fracture or defect in the part of the fifth lumbar vertebra lying immediately anterior to its inferior articular process. A defect in this region, if unaccompanied by any significant forward movement of the vertebral body, is known as spondylolysis. The defect may be unilateral or bilateral. When forward slip occurs, the condition is known as spondylolisthesis. Less commonly, the fourth lumbar vertebra may be involved, the slip occurring between L4 and L5.

Both congenital and developmental factors have been recognized in the causation of the condition. There is a higher incidence in the families of those affected (30–70%, with dominant transmission), in certain Inuit tribes (where it reaches 54%), and among the Japanese. The lowest incidence is in black females (1.1%), and in white males it is 6.1%. Defects are rare at birth and before the age of 5, but the incidence in the population goes on increasing up to the end of the fourth decade. Fractures due to trauma or fatigue are thought to be the most likely cause, and this explains the high incidence amongst gymnasts, weightlifters, labourers, loggers and backpackers. It may be associated with sacral spina bifida and Scheuermann's disease.

Both spondylolysis and spondylolisthesis give rise to low back pain which radiates into the buttocks. In adolescents, the majority of whom are active in sports, resolution of symptoms may be achieved in 80% of cases by the avoidance of sports and the use of a corset support. This may lead to the healing of hairline fractures, or to the spine stabilizing as a result of degenerative changes occurring at the level of the slip. In more severe cases,

where there is significant forward slip, local spinal fusion is the treatment of choice. This may be performed with or without reduction of the deformity.

A number of patients may suffer from neurological disturbances in the lower limbs, either initially or as an uncommon complication of a local fusion. In the *cauda equina syndrome* there is usually low back pain with radiation into the buttocks, spinal stiffness, hamstring spasm, gait abnormalities, and disturbance of bladder and bowel control. This may be due to an associated disc protrusion, or be caused by the cauda equina and roots of the lumbosacral plexus being stretched over the prominent upper edge of the fifth lumbar vertebra or the sacrum. These complications should be dealt with by an immediate decompression procedure.

OSTEOARTHRITIS (OSTEOARTHROSIS)

Primary osteoarthritis of the spine is extremely common, especially in the elderly, and is often asymptomatic. In the majority of cases there are no obvious causes, apart from those associated with the degenerative processes of age. Sometimes obesity and excessive use of the spine by manual workers may be factors. In secondary osteoarthritis, previous pathology in the spine accelerates normal wear and tear processes.

Occasionally osteoarthritis may be localized to one spinal level, at for example the site of a previous fracture or a prolapsed intervertebral disc. Often, however, many vertebral levels are affected, particularly where there is some alteration in the normal curves of the spine; for example, secondary osteoarthritic changes may occur in the lumbar spine when lumbar lordosis is increased as a sequel to Scheuermann's disease of the thoracic spine.

Osteoarthritis of the spine may be accompanied by disc degeneration, anterior and posterior lipping of the vertebral bodies, narrowing and lipping of the facet joints, and sometimes abutment of the vertebral spines (kissing spines) as a result of disc degeneration bringing the vertebrae nearer together.

When osteoarthritis gives rise to symptoms, these are usually of pain and stiffness in the back; once other conditions have been eliminated, the radiological appearances are diagnostic. Treatment is by weight reduction where applicable, spinal exercises to improve the back musculature, and analgesics. Short-wave diathermy is sometimes helpful. In the commonest area, the lumbar spine, a corset support is a widely used and generally very helpful line of treatment. Only rarely is spinal fusion indicated, but this is sometimes considered in the younger patient suffering from secondary osteoarthritis localized to a single level of the spine.

RHEUMATOID ARTHRITIS

Rheumatoid arthritis may affect the spine; other peripheral sites are normally involved, so that the diagnosis is not normally difficult. Radiographs of the spine in rheumatoid arthritis generally show widespread osteoporosis, disc space narrowing, narrowing of the facet joints, and often reduction in the height of vertebral bodies. The treatment is that of generalized rheumatoid arthritis; locally, corset supports may give considerable relief of symptoms.

SPINA BIFIDA

Spina bifida is a condition in which there is a congenital failure of fusion of the posterior elements of the spine, through which the contents of the spinal

canal may herniate. The grosser forms in the newly born child present no difficulty in diagnosis. A number require and are amenable to immediate surgery, which may prevent early death from ascending meningitis and ameliorate the frequently concomitant neurological and hydrocephalic problems. The residual neurological defect may unfortunately be profound, and the selection of cases for surgery is specialized and to some extent controversial.

The older child or adult may present with spina bifida occulta, which is diagnosed by radiological examination, although it may be suspected by the presence of a hairy patch, naevus or fat pad, or dimpling of the skin at the site of the abnormality. Many cases are symptom free. In some the only manifestation may be the presence of pes cavus. In others there may be progressive bladder dysfunction, weakness and incoordination of the legs, or trophic changes in the feet.

SPINAL STENOSIS

A decrease in the sagittal diameter of the spinal canal, perhaps associated with narrowing of the nerve root tunnels, may give rise to symptoms of vague backache and morning stiffness. Occasionally there may be temporary motor paralysis or neurogenic claudication, where there are lower limb pains, cramps and paraesthesiae related to walking or exercise. There may be weakness or giving-way of the legs. The claudication distance is variable, and pain may be rapidly relieved by forward flexion of the spine or by sitting. The sensory loss is segmental, and impulse symptoms are usually present. (In claudication due to vascular insufficiency the claudication distance is constant, the peripheral pulses are usually absent, and the sensory loss generally of the stocking type.) The average age of presentation is 65. Clinically the straight leg-raising test is hardly ever affected, but motor disturbances and absence of the knee jerk are common.

Spinal stenosis is common in achondroplasia, but is more commonly found as a complication of osteoarthritis of the lumbar spine, spondylolisthesis, Paget's disease, previous fracture or spinal surgery. In others the condition may be suspected on clinical grounds. Analysis of the dimensions of the pedicles and the spinal canal in the plain radiographs may be helpful in establishing the diagnosis, but CT and MRI scans reliably demonstrate the space available within the spinal canal for the neurological structures.

If symptoms are marked and the patient is otherwise fit, gratifying relief is often achieved by a decompression procedure.

THE PROLAPSED INTERVERTEBRAL DISC (PID)

In the commonest pattern of intervertebral disc prolapse, a tear in the annulus allows protrusion of the semiliquid nucleus pulposus. This may be limited by intact fibres at the periphery of the annulus (*contained prolapse*). In other cases extrusion of the nucleus is usually more extensive and the prolapsed material may be cut off from its source (*sequestered disc prolapse*).

Lumbar disc prolapses are by far the most common, and the diagnosis is usually made on the clinical evidence alone. Confirmation may be obtained by means of non-invasive procedures such as CT and MRI scans.

Discography often yields valuable information, as does radiculography. Nevertheless, it is most important to note that the investigative findings must be interpreted in conjunction with the history and clinical findings. (In a recent study of a control group completely free from symptoms, abnormalities were found in the MRI scans in 57%: 36% had evidence of disc prolapse, and 21% had spinal stenosis. In addition, among proven cases of disc prolapse the MRI scan is negative in 20% of cases, or shows incompatible abnormalities in 30%.)

The disc between L5 and S1 is most commonly involved, followed in order by L4–L5, and that between L3 and L4. In a typical case there is a history of a flexion injury which tears the annulus fibrosus, allowing the nucleus pulposus to herniate through. Back pain is produced by the annular tear and protective lumbar muscle spasm may contribute to it. Pain is felt in the lumbar region. There is usually tenderness between the spines at the affected level, and sometimes at the side over muscles in spasm, although this is a somewhat unreliable and controversial sign. Muscle spasm often leads to loss of the normal lumbar lordotic curve, to restriction of movements in the lumbar spine, and a protective scoliosis. The extruding nucleus frequently presses on a lumbar nerve root, giving rise to sciatic pain, paraesthesiae in the leg, and sometimes muscle weakness, sensory impairment, and diminution or abolition of the ankle jerk. At higher levels the knee jerk may be lost. The neurological disturbance is *segmental in pattern, and is dependent on the side and level of the prolapse*. Impulse symptoms are common. When the prolapse is large and central the cauda equina may be affected, producing bladder disturbance, diminished perineal sensation, and even paraplegia. Such an occurrence is a surgical emergency and immediate exploration imperative.

When a disc prolapse occurs in the adolescent there is striking restriction of movements in the lumbar spine. In the older patient, where degenerative changes have occurred in the annulus, symptoms may be produced by an extensive backward bulging of the disc without there being a frank localized annular tear.

Disc prolapses in the thoracic spine are rare and have a variety of presentations, often with a confusing clinical picture. There may be bandlike chest pain, scoliosis, bizarre neurological disturbances with peripheral temperature changes, altered reflexes, and weakness of the limbs. A number are misdiagnosed as multiple sclerosis or amyotrophic lateral sclerosis. They may be diagnosed by MRI scan, and treated by transthoracic excision.

In the long term, the extrusion of disc material from between the vertebral bodies leads to narrowing of the disc space. The facet joints are disturbed, and tend to develop secondary arthritic changes which decrease the mobility of the spine at that level, and themselves be a source of pain and sometimes nerve root irritation.

Occasionally, in the young in particular, the nucleus may herniate into the substance of the vertebral bodies, giving rise to mild backache without root symptoms. This pattern of herniation (Schmorl's nodes) is diagnosed radiographically.

Apart from the large central prolapse all cases of acute disc prolapse are first treated by conservative methods. The present view is that prolonged periods of bed rest should be avoided, but an initial 2-week period of bed rest with the use of strong analgesics may be required. If the response is good the patient is then allowed up, although he is warned to avoid lifting

and bending in case of recurrence. In some centres spinal extension exercises may be advocated at this stage. If the response has only been moderate, a number of surgeons nevertheless allow the patient to become ambulant wearing a corset back support. If there is no response to 2 weeks' bed rest, the case must be carefully reassessed before further treatment by bed rest is continued. Where ultimately there is an unsatisfactory response, or where residual symptoms are severe, further investigation by CT or MRI scan, discography or myelography is usually undertaken, with a view to specific treatment of the lesion. The methods available include surgical excision by means of a laminectomy, microsurgery, percutaneous endoscopic surgery, or by chemonucleolysis. The results of treatment, particularly as far as return to work is concerned, are surprisingly little affected by either the physical findings, the extent of the local pathology or the effects of surgery. (Social or work-related factors have the greatest influence on the results.)

The following table (based on the findings of Jonson and Stomquist) may be helpful in differentiating between cases of disc prolapse and spinal stenosis.

Finding	PID	Lateral stenosis	Central stenosis
Average age	43	41	65
Duration of symptoms (prior to surgery)	shortest		
Pain at rest, at night, and on coughing	+ EQUAL +		
Positive straight leg raising	+++	sometimes	hardly ever
Motor disturbance	commonest, especially of knee jerk		
Sensory changes	commonest		

MECHANICAL BACK PAIN

Although usually suspected following history taking, clinical examination and the study of appropriate radiographs, the diagnosis is made largely by a process of elimination: it is back pain which is not due to a prolapsed intervertebral disc or any other clearly defined pathology. The patient is usually in the 20–45-year age group, and complains of dull backache aggravated by activity. There is often a history of morning stiffness which is gradually relieved as the patient moves about. Physical signs are often slight, and extensive radiation of pain and positive neurological signs are not a feature.

Acute cases may be precipitated by a traumatic incident, such as the flawed lifting of a heavy weight, a fall, or a head-on impact pattern road traffic accident. There may be intense protective muscle spasm. As far as treatment is concerned, analgesics should be prescribed for a short period and prolonged bed rest should be avoided. An early return to work should be encouraged, even in the presence of some degree of residual pain. Physiotherapy should be started after a week if symptoms are still marked.

In the majority of cases symptoms resolve completely over a 4–6-week period. In a number of cases, however, symptoms become prolonged, with the impatient sufferer often trying any of the large number of alternative medicine treatments now so widely available.

In chronic cases there is often a long history of intermittent low back pain over a number of years. The cause is often obscure, although degenerative changes in the spine are not uncommonly present. Resistance to treatment is a frequent problem, and many are ultimately referred to pain clinics. Sometimes a change of employment to work of a lighter character may have to be contemplated.

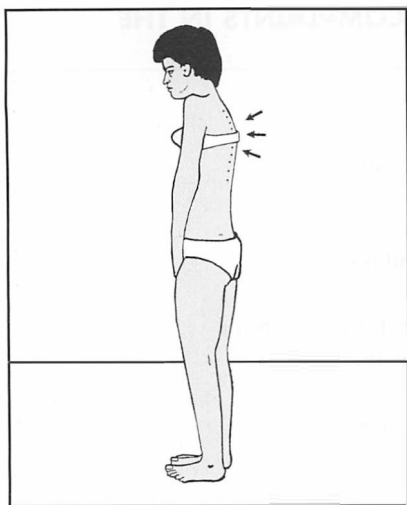
COCCYDYNIA

In patients with this complaint of pain in the coccygeal area there is often a history of a fall in the seated position on to a hard surface; consequently, in a number of cases radiographs may reveal a fracture of the end piece of the sacrum, or show the coccyx to be subluxed into the anteverted position. Symptoms of pain on sitting and defecation are often protracted for 6–12 months, but tend to resolve spontaneously. It was formerly thought that if symptoms proved persistent either a disc lesion in the lumbar spine (with distal referral) or a functional problem was likely to be the problem, but this is now discounted.

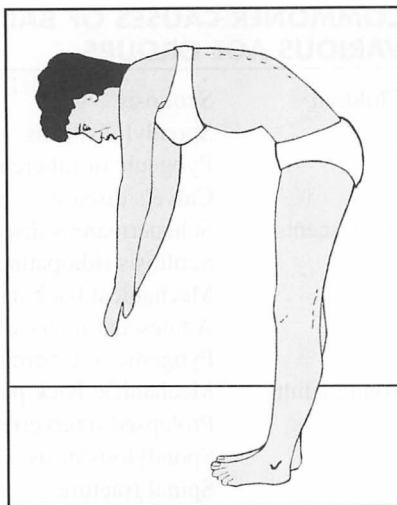
In stubborn cases conservative treatment should invariably be first employed: 60% of cases respond to local injections of steroids, and 85% to the injection of a long-acting local anaesthetic followed by manipulation. If there is complete failure to respond to a substantial period of conservative treatment (this occurs in about 20% of cases), excision of the coccyx is reported as being successful in 80% of cases.

COMMONER CAUSES OF BACK COMPLAINTS IN THE VARIOUS AGE GROUPS

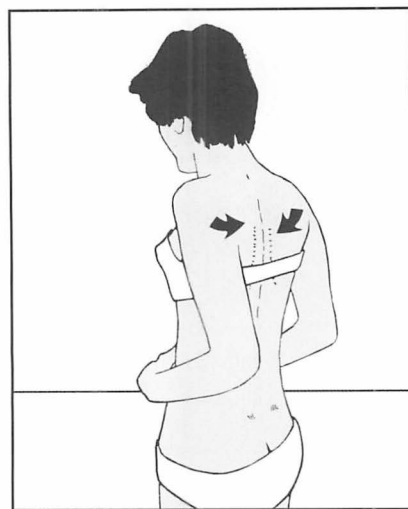
Children	Scoliosis
	Spondylolisthesis
	Pyogenic or tuberculous infections
	Calvé's disease
Adolescents	Scheuermann's disease
	Scoliosis (idiopathic and postural)
	Mechanical back pain
	Adolescent intervertebral disc syndrome
Young adults	Pyogenic or tuberculous infections
	Mechanical back pain
	Prolapsed intervertebral disc
	Spondylolisthesis
	Spinal fracture
	Ankylosing spondylitis
	Coccydynia
	Pyogenic or tuberculous infections
	Spinal stenosis
Middle-aged	Mechanical back pain, including primary osteoarthritis
	Prolapsed intervertebral disc
	Scheuermann's disease and old fracture
	Spondylolisthesis
	Rheumatoid arthritis
	Spinal stenosis
	Paget's disease
	Coccydynia
	Spinal metastases
Elderly	Pyogenic osteitis of the spine
	Osteoarthritis, primary and secondary
	True senile kyphosis
	Osteoporosis, with or without fracture
	Osteomalacia, with or without fracture
	Spinal metastases



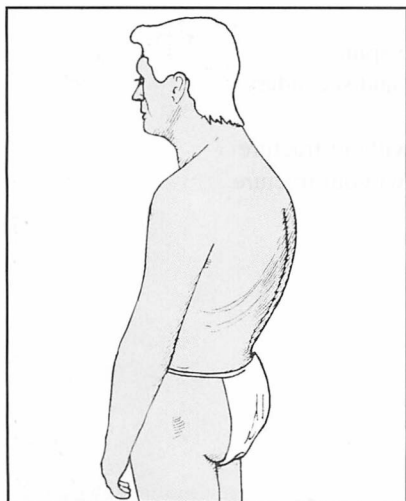
8.1. Inspection (1): Ask the patient to stand. Look at the spine from the side. Although normal posture is difficult to define, try to make an assessment of the thoracic curvature, noting whether the curve is quite regular and if it appears to be increased.



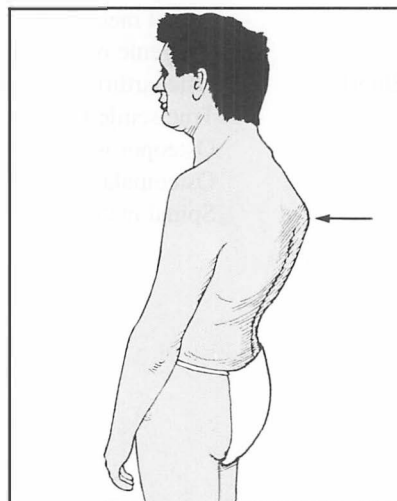
8.2. Inspection (2): It is valuable to know whether the thoracic spine is mobile, especially if there is a kyphosis. Ask the patient to bend forward, carefully examining the flow of movement in the spine, and whether the curvature increases. As the range of flexion in the thoracic spine is small it may also help to check *rotation*, which is the main movement occurring in the thoracic spine (see later).



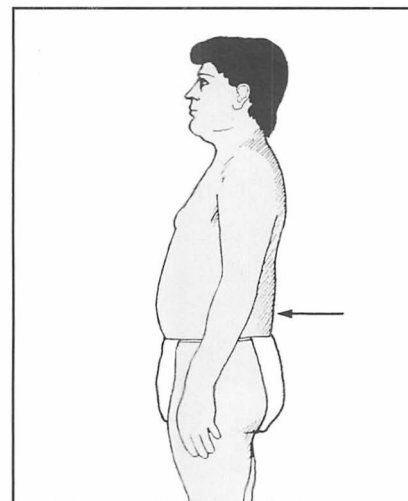
8.3. Inspection (3): Now ask the patient to stand upright and brace back the shoulders to produce extension. An increased curvature (kyphosis) which is regular and mobile is found in postural kyphosis.



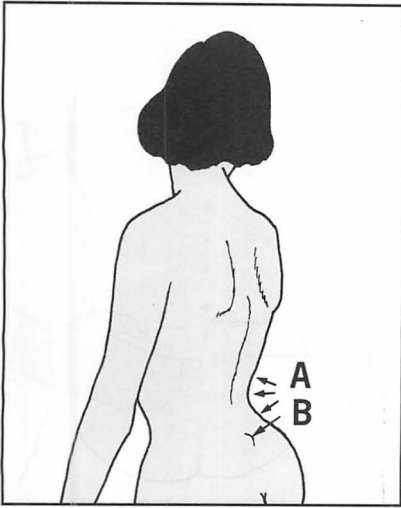
8.4. Inspection (4): If a regular but fixed kyphosis is found, the commonest causes are senile kyphosis (sometimes with osteoporosis, osteomalacia or pathological fracture), Scheuermann's disease and ankylosing spondylitis.



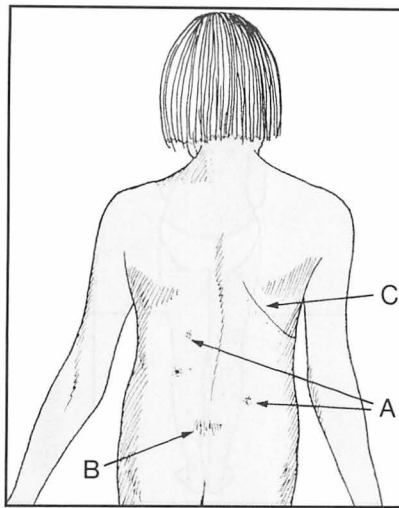
8.5. Inspection (5): If there is an angular kyphosis, with a gibbus or prominent vertebral spine, the commonest causes are fracture (traumatic or pathological), tuberculosis of the spine, or a congenital vertebral abnormality.



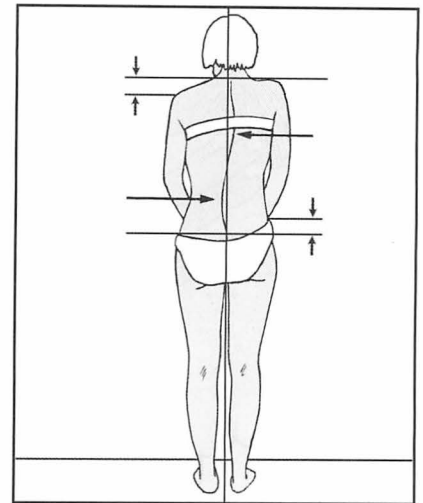
8.6. Inspection (6): Note the lumbar curvature. Flattening or reversal of the normal lumbar *lordosis* is a common finding in prolapsed intervertebral disc, osteoarthritis of the spine, infections of the vertebral bodies and ankylosing spondylitis. Flexion of the spine, hips and knees (simian stance) is suggestive of spinal stenosis.



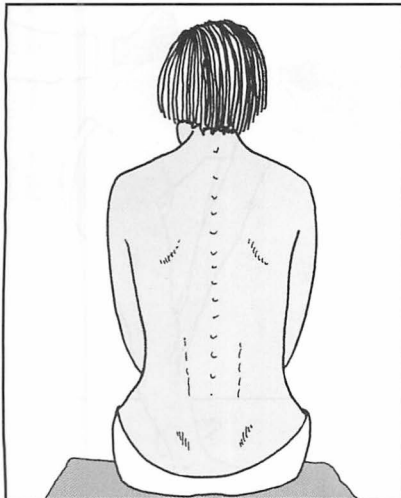
8.7. Inspection (7): (A) An increase in the lumbar curvature may be normal (especially in women) or be found in association with the prominence of the spine of L5 and the sacrum (B) in spondylolisthesis. It may be *secondary* to an increased thoracic curvature, or to flexion deformity of the hip(s). Always screen test the hips.



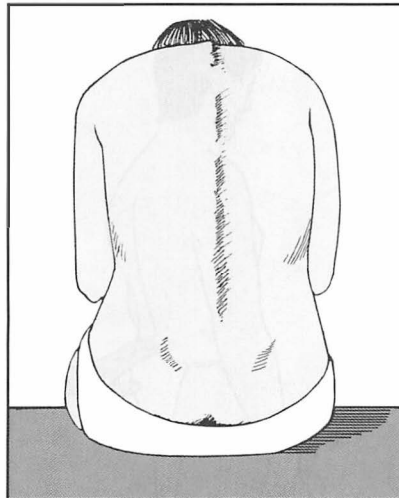
8.8. Inspection (8) *From behind:* Note (A) café-au-lait spots, which may suggest neurofibromatosis and associated scoliosis; (B) a fat pad or hairy patch suggestive of spina bifida; (C) scarring suggestive of previous thoracotomy (and possible thoracogenic scoliosis) or spinal surgery.



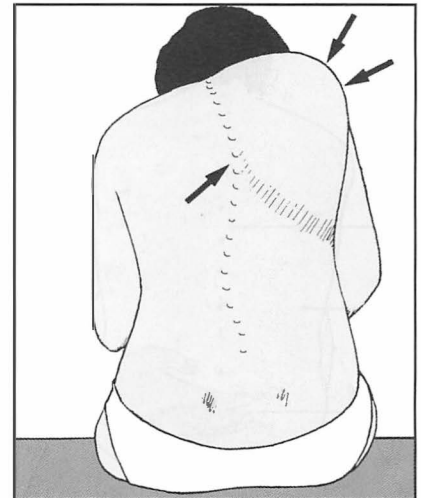
8.9. Inspection (9): Note the presence of any lateral curvature (scoliosis). The commonest scoliosis is a protective scoliosis, or list, in the lumbar region secondary to a prolapsed intervertebral disc. Note whether the shoulders and hips are level.



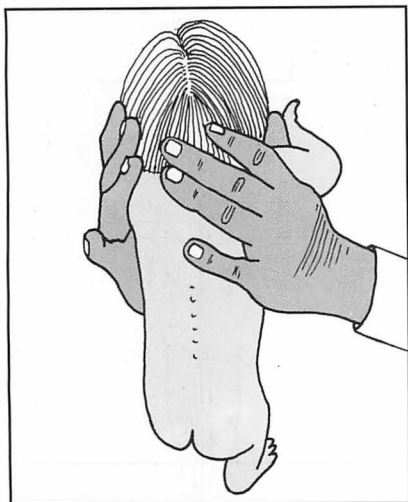8.10. Inspection (10): In considering other causes of scoliosis, examine the spine with the patient sitting. Obliteration of an abnormal curve suggests that the scoliosis is mobile and may be secondary to shortening of a leg. Certainly the next step to take is to check and compare the leg lengths.



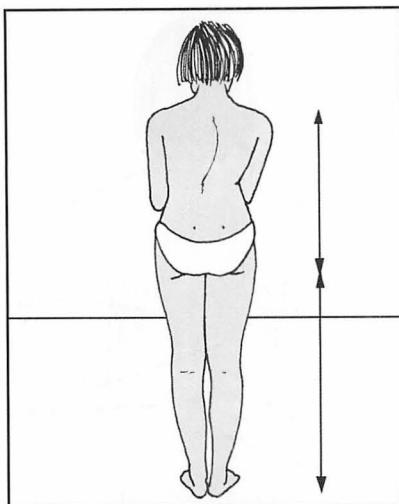
8.11. Inspection (11): If, on sitting, the scoliosis persists, ask the patient to bend forward. If the curve disappears, this suggests that it is quite mobile and most likely to be postural in origin.



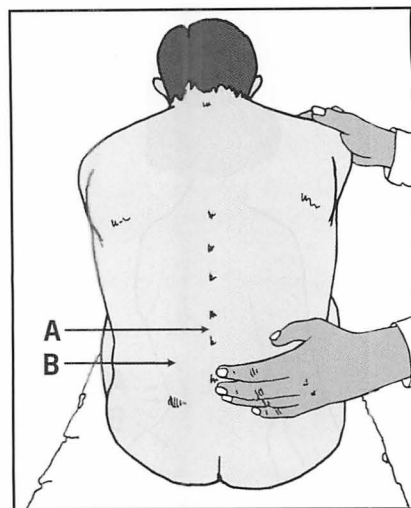
8.12. Inspection (12): If the curvature remains, this suggests that the scoliosis is *fixed* (structural scoliosis). If a *rib hump* is present, this confirms the diagnosis. Note should be made of its severity. (Goniometers for measuring the angle of the hump are available.) Remember that syringomyelia is present in about a quarter of cases of juvenile idiopathic scoliosis, and an MRI scan is mandatory.



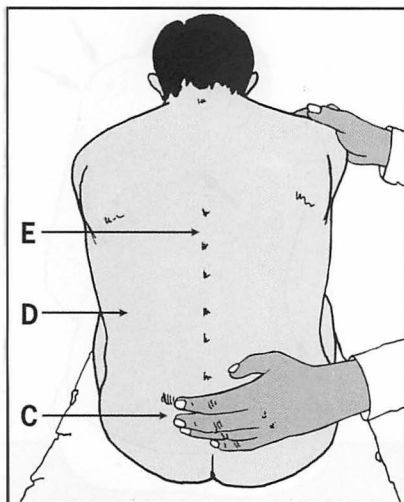
8.13. Inspection (13): In the case of infantile scoliosis, assess the rigidity of a curvature by noting any alterations as the child is lifted by the armpits.



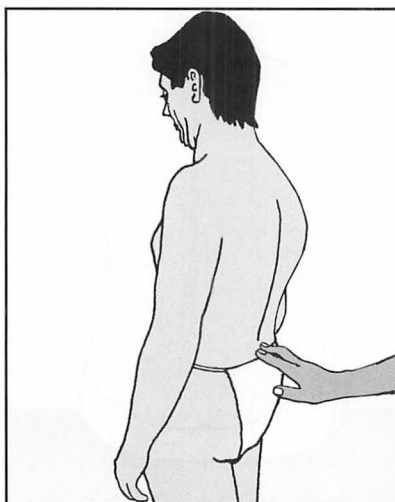
8.14. Inspection (14): Note that in idiopathic scoliosis with double fixed (primary) curves the deformity may not be obvious. There will, however, be shortening of stature, with a trunk which is short in proportion to the limbs. (If desired, this may be assessed using the anthropometric tables of Aldegheri and Agostini, which give values for the ratio of sitting height to standing height in each sex at different ages.)



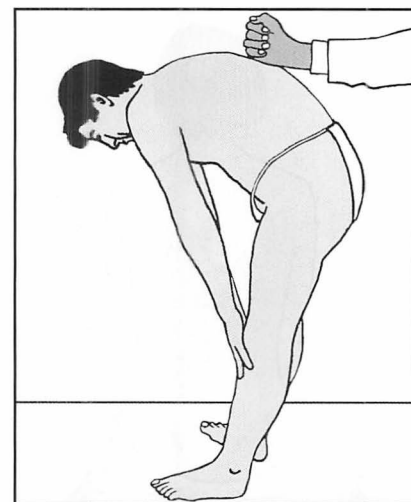8.15. Palpation (1): Ask the patient to lean forward if possible. Look for tenderness: (A), between the spines of the lumbar vertebrae and at the lumbosacral junction (common in prolapsed intervertebral disc, but thought difficult to explain and unreliable) and (B), over the lumbar muscles; this is especially likely to be found where there is protective muscle spasm in cases of PID and mechanical back pain.



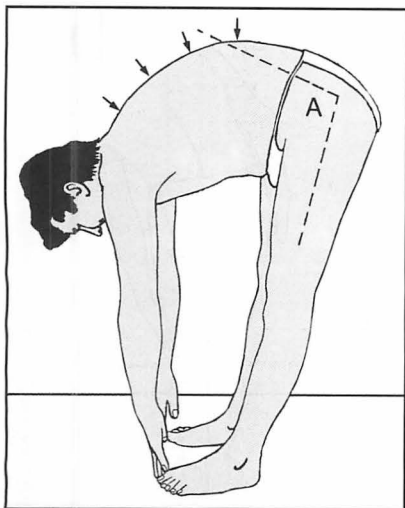
8.16. Palpation (2): Tenderness over the sacroiliac joints (C) may also occur in cases of mechanical back pain and in sacroiliac joint infections. Re-examine with the patient prone. Renal tenderness (D) must be investigated fully. Look also for tenderness higher in the spine (E), e.g. from vertebral body infections.



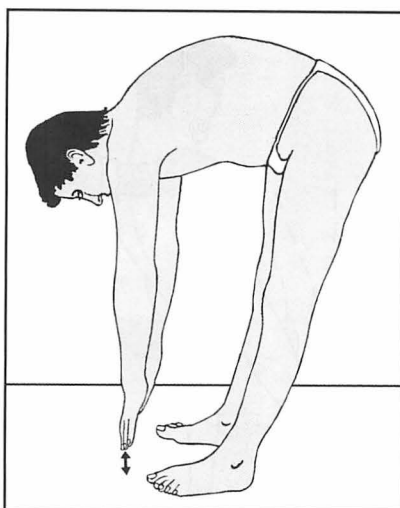
8.17. Palpation (3): With the patient standing, slide the fingers down the lumbar spine on to the sacrum. A palpable step at the lumbosacral junction is a feature of spondylolisthesis. Note any other curve irregularity (e.g. gibbus). Note also any change in friction (due to alterations in sweating patterns), which may help in the localization of any pathology.



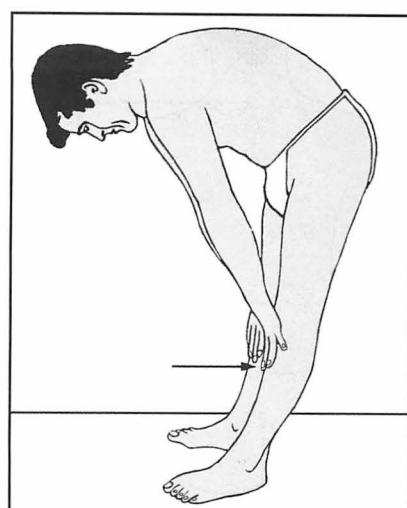
8.18. Percussion: Ask the patient to bend forward. Lightly percuss the spine in an orderly progression from the root of the neck to the sacrum. Significant pain is a feature of tuberculous and other infections, trauma (especially fractures) and neoplasms. Otherwise a marked response may be a feature of a non-organically based complaint.



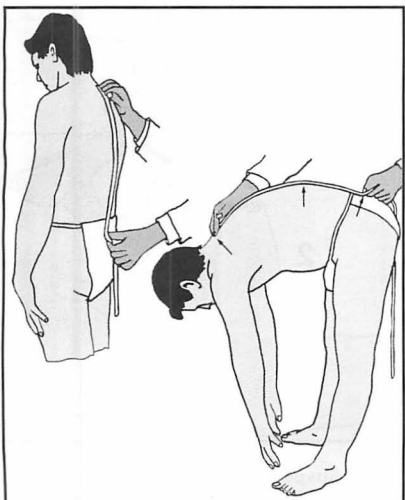
8.19. Movements: flexion (1): Ask the patient to attempt to touch his toes while you watch the spine closely for smoothness of movement and any areas of restriction. Note the importance of hip flexion (A), which can account for apparent motion in a rigid spine.



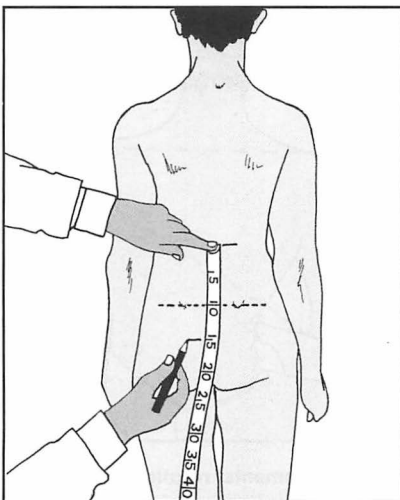
8.20. Movements: flexion (2): Flexion may be recorded in several ways, the commonest being to note the distance between the fingers and the ground, e.g. 'the patient flexes to within 10 cm of the floor'. This is an indication of the summation of thoracic, lumbar and hip movements: it does not distinguish between them, and is under voluntary control.



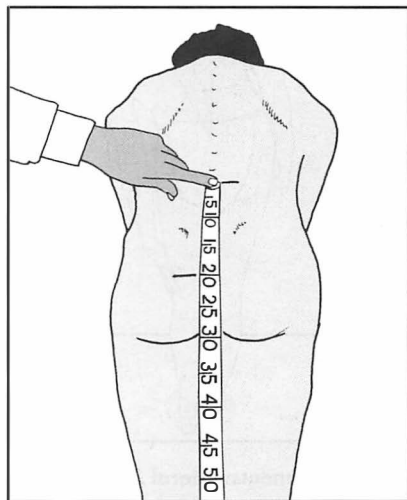
8.21. Movements: flexion (3): Flexion may also be recorded as: 'the patient flexes so that the fingertips reach mid-tibia', or some other appropriate level. The majority of normal patients can reach the floor or within 7 cm from it. (Actual maximum range flexion is approximately 45° thoracic, 60° lumbar.) Again, this does not indicate the relative contributions of the hips and spine.



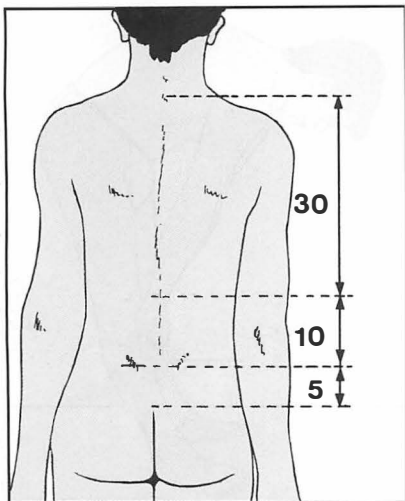
8.22. Movements: flexion (4): When the spine flexes, the distance between each pair of vertebral spines increases. By measuring the spine when the patient is erect, and then when bent forward, any gain is clear evidence of spinal flexion. In practice this is used most frequently in assessing movements in the lumbar spine (where flexion is greatest and pathology more common).



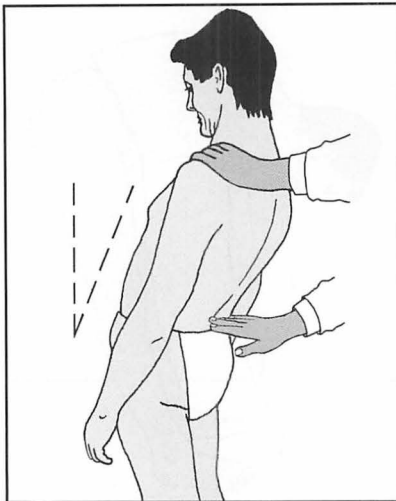
8.23. Movements: flexion (5): In *Schober's method* a 10 cm length of lumbar spine is used as a base. Greater accuracy is claimed for the *modified Schober's method* (most often used in the UK), where a 15 cm length of spine is employed. Begin by positioning a tape measure with the 10 cm mark level with the dimples of Venus (which mark the posterior superior iliac spines). Mark the skin at 0 and 15 cm.



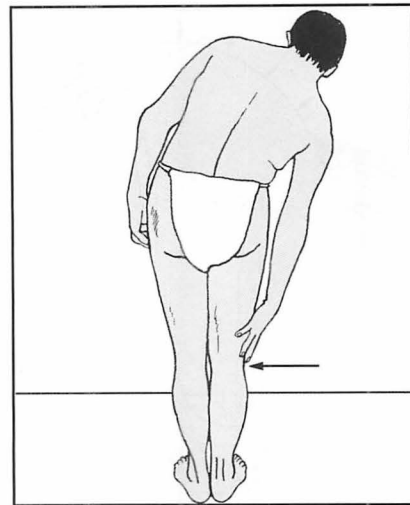
8.24. Movements: flexion (6): Anchor the top of the tape with a finger and ask the patient to flex as far forward as he can. Note where the 15 cm mark strikes the tape and work out the increment, which is entirely due to lumbar spine flexion. This is normally about 6–7 cm. Less than 5 cm is indicative of organic spinal pathology.



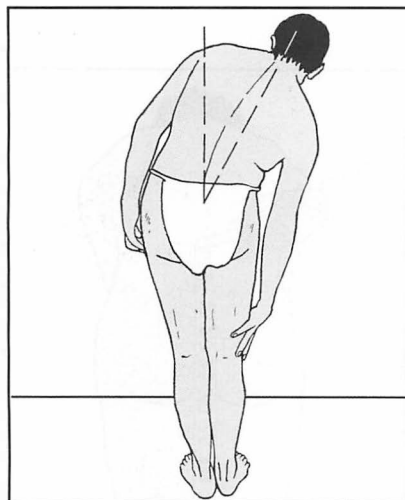
8.25. Movements: flexion (7): Flexion in the thoracic spine may be measured with the upper point 30 cm from the previous zero mark. Thoracic flexion is not great, and is normally in the order of 3 cm. NB: to exclude the possibility of overlay, repeat these measurements with the patient distracted, sitting up, and leaning forward on the examination couch.



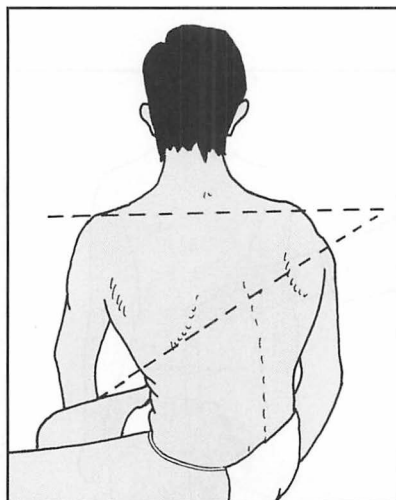
8.26. Movements: extension: Ask the patient to arch his back, assisting him by steadying the pelvis and pulling back on the shoulder. Pain is common in prolapsed intervertebral disc and in spondylolysis. Accurate assessment with a goniometer is difficult. The maximum theoretical range is thoracic 25°; lumbar 35°; normal total range about 30°. The decrease in distance between L1 and S1 on extension may also be measured with a tape.



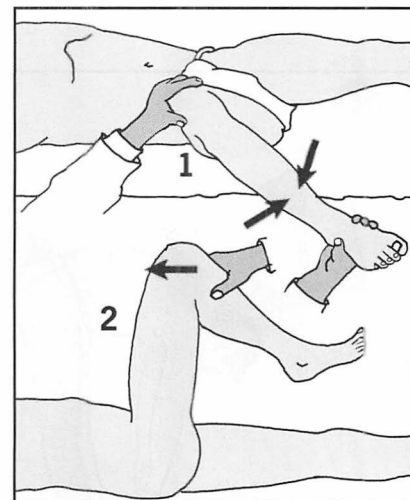
8.27. Movements: lateral flexion (1): Ask the patient to slide the hands down the side of each leg in turn, and record the point reached, either in centimetres from the floor, or the position that the fingers reach on the legs.



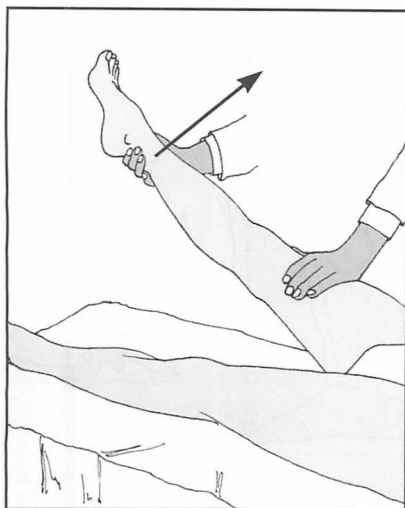8.28. Movements: lateral flexion (2): Alternatively, measure the angle formed between a line drawn through T1, S1 and the vertical. The average range is 30° to either side, and the contributions of the thoracic and lumbar spine are usually equal.



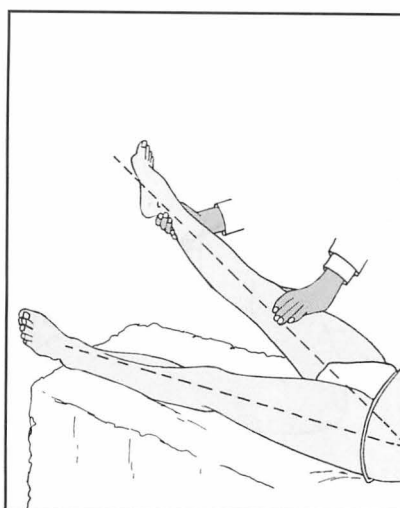
8.29. Movements: rotation: The patient should be seated, and asked to twist round to each side. Rotation is measured between the plane of the shoulders and the pelvis. The normal maximum range is 40° and is almost entirely thoracic. (Lumbar contribution is 5° or less.) Some claim a more accurate assessment may be made if the test is carried out with the patient's arms folded across the chest.



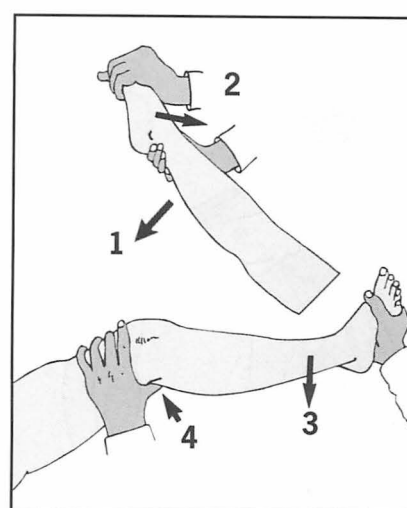
8.30. Suspected prolapsed intervertebral disc: Always start by screening the hips. Osteoarthritis of the hip and prolapsed intervertebral disc are frequently confused. A full range of rotation in the hips, performed at 90° flexion (1) without pain at the extremes, is generally sufficient to exclude osteoarthritis as a significant cause for the patient's complaints. Note that if there is complaint of pain on flexing the hip with the knee flexed (2) this negates a positive straight leg-raising test, and suggests osteoarthritis or overlay.



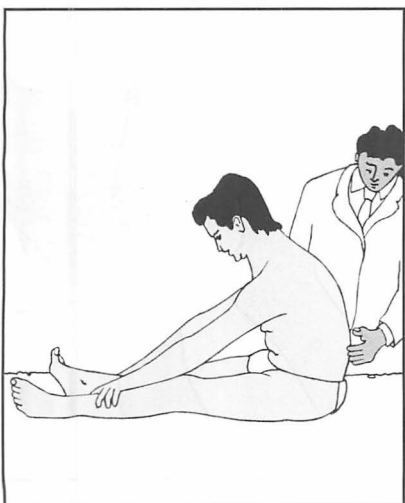
8.31. Suspected prolapsed intervertebral disc: Straight leg-raising test (1): If the hips are normal, raise the leg from the couch while watching the patient's face. Stop when the patient complains, and confirm that he is complaining of back or leg pain and not hamstring tightness (the test is negative if there is no pain). The production of paraesthesia or radiating root pains is highly significant, indicating nerve root irritation. Pain from S1 generally occurs before that from L5.



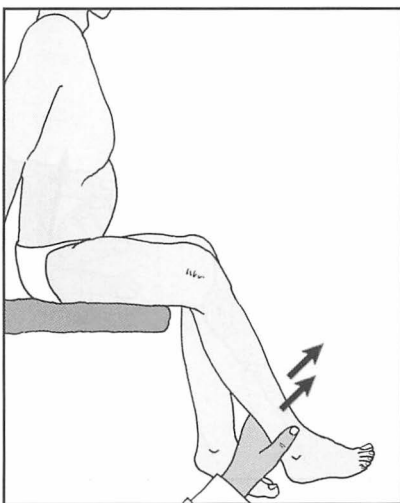
8.32. Straight leg raising (2): Note the result (e.g. SLR (R) +ve at 60° or straight leg raising (R) full (no pain)). Note the site of pain: back pain suggests a central disc prolapse, leg pain a lateral protrusion. Distinguish and ignore hamstring tightness. Repeat on the good side. If well-leg raising produces pain and paraesthesia on the affected side, this is highly suggestive of a large prolapse close to the midline. Note that pain *must be below the knee* if the roots of the sciatic nerve are involved.



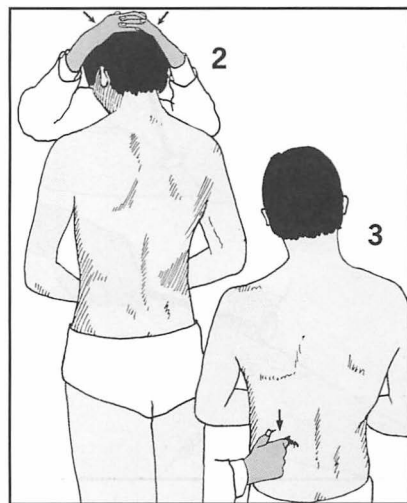8.33. Straight leg raising (3): Now lower the leg until pain disappears (1); then dorsiflex the foot (2). This increases tension on the nerve roots, generally aggravating any pain or paraesthesia ('+ve sciatic stretch test'). Try this, and record the response. Alternatively, once the level of pain has been reached, flex the knee slightly (3) and apply firm pressure with the thumb in the popliteal fossa over the stretched tibial nerve (4): radiating pain and paraesthesia suggest nerve root irritation (*bowstring test*).



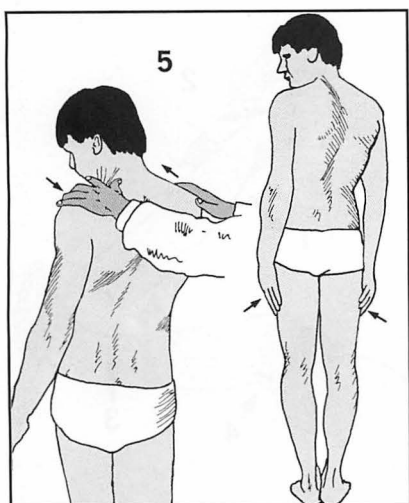
8.34. Straight leg raising (4): If there is some doubt regarding the severity or genuineness of the patient's complaints, ask him to sit up under the pretext of examining the back from behind. (Flexion of the spine may also be remeasured with the tape in this position.) The malingerer will have no difficulty, but the genuine patient will either flex the knees or fall back on the couch with pain (*flip test*).



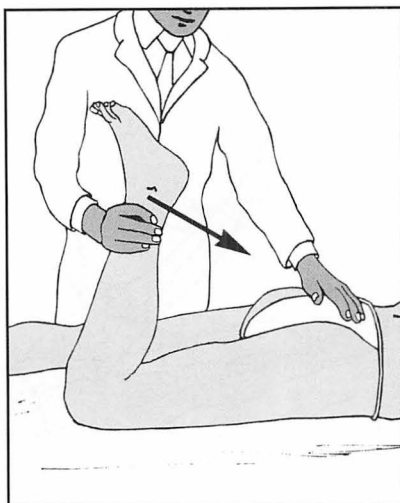
8.35. Straight leg raising (5): Aird's test: Alternatively, ask the patient to sit with the legs over the edge of the examination couch. Now try to lift the leg until the knee is fully extended, and note the response. If extension is achieved, this is equivalent to a straight leg raising of 90°, and suggests that there is not a sound organic basis for any positive straight leg raising obtained when the patient is supine.



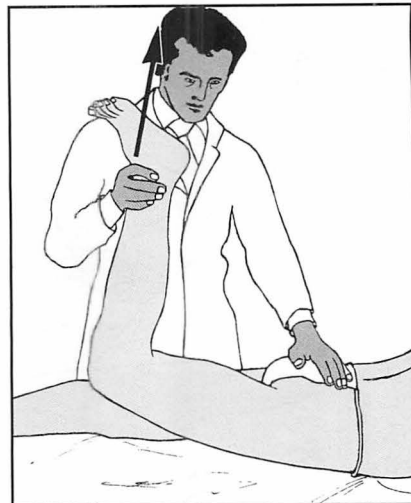
8.36. Suspected prolapses intervertebral disc: Functional overlay, continued: (2) Apply pressure to the head. Overlay is suggested if this aggravates the back pain. (3) Pinch the skin at the sides. Such superficial stimulation should not produce deep-seated back pain. (4) Any motor or sensory disturbance should be segmental and localized. Widespread weakness and/or stocking anaesthesia also suggest overlay (but do carry out a thorough neurological and circulatory examination).



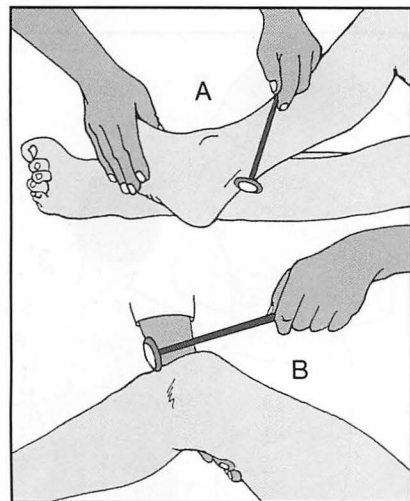
8.37. Suspected prolapsed intervertebral disc: Functional overlay, continued: (5) Note the amount of rotation required to produce pain in the back. Now ask the patient to keep his hands firmly at his sides and repeat: the major part of the movement will now take place in the legs. Pain occurring with the same amount of apparent rotation again suggests overlay. In many centres, if three or more of the preceding tests are positive surgery is considered to be contraindicated.



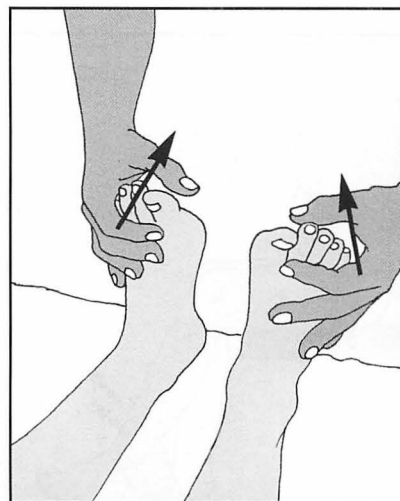8.38. Suspected prolapsed intervertebral disc: Reverse Lasague test (1) The patient should be prone. Flex each knee in turn. This gives rise to pain in the appropriate distributions (by stretching of femoral nerve roots) in *high lumbar disc lesions*.



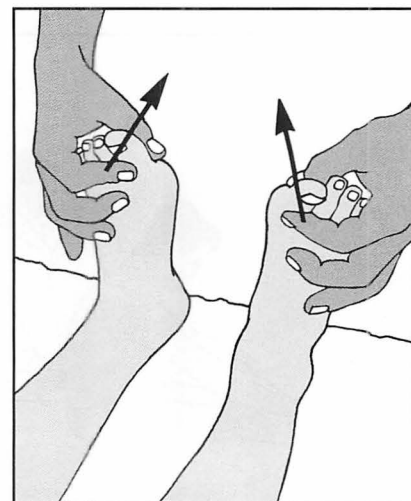
8.39. Reverse Lasague (2): The pain produced in such a test, if positive, is normally aggravated by extension of the hip, and this should be noted. Attempt this with the knee flexed to 90° (illustrated) and also fully flexed. High disc lesions are rare compared with those affecting the L5-S1 and L4-L5 spaces. Note also that pain in the *ipsilateral buttock or thigh* on full knee flexion may occur in more distally situated disc prolapses.



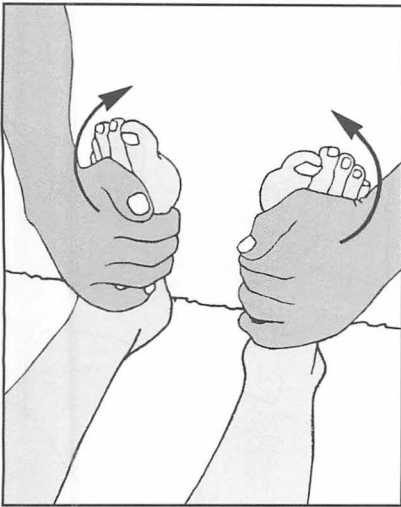
8.40. Suspected prolapsed intervertebral disc (2): Look for further evidence of neurological involvement. A reduced or absent tendon reflex is a highly significant finding accompanying positive straight leg raising or positive reverse Lasague tests, but in practice confirmatory findings of this nature may not be present. Although two spinal segments are involved in both the knee and ankle reflexes, it is common practice to assess the integrity of L4 by the presence of the knee jerk (B), and that of S1 by the ankle jerk (A).



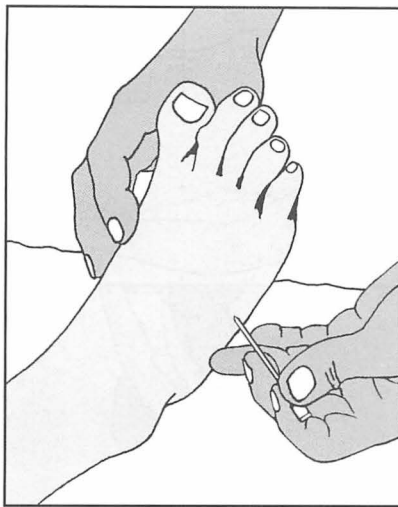8.41. Suspected prolapsed intervertebral disc (3): Root pressure from a disc may affect myotomes and dermatomes in a rather selective fashion (see Segmental Innervation). Note the presence of any muscle wasting. Ask the patient to dorsiflex both feet. Now attempt to force them into plantarflexion against his resistance (L4, 5).



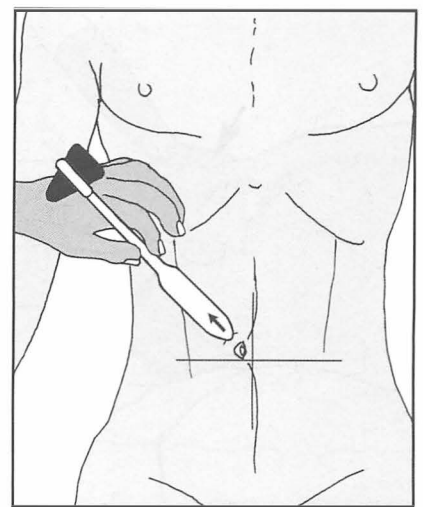
8.42. Suspected prolapsed intervertebral disc (3): Shift the grip to the great toes and test the power of dorsiflexion. Repeat with the lesser toes (L4, 5). *Note that many regard weakness of dorsiflexion of the great toe as a most sensitive test of the L5 root alone*, a root where there is no appropriate tendon reflex available for assessment. Now test the power of plantarflexion of the great and lesser toes (S1, 2).



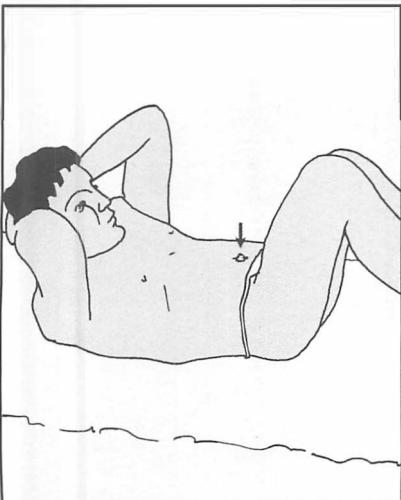
8.43. Suspected prolapsed intervertebral disc (4): Encircle the feet with the hands and test the power of the peronei against the patient's resistance (L5, S1). Test the power of the quadriceps (L3, 4) when a high disc lesion is suspected. *Note that prolonged muscle weakness will be accompanied by muscle wasting.* Look for this clinically, and if you suspect it compare the girths of both the calves.



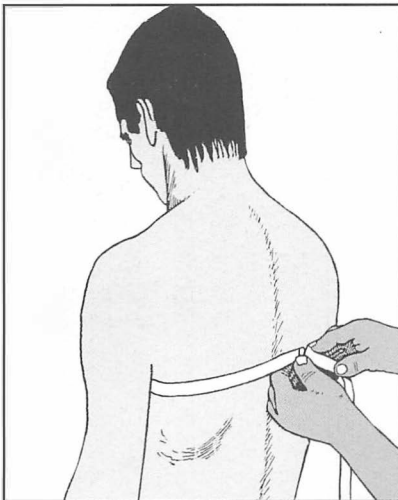
8.44. Suspected prolapsed intervertebral disc (5): Test sensation to pinprick in the dermatomes of the lower limb. Test perineal sensation in suspected central disc prolapse. Diminution of sensation at the side of the foot (S1) is one of the commonest findings (see also Segmental and Peripheral Nerves of the Limbs). Note also that stocking anaesthesia may be found in diabetic neuropathy and peripheral vascular disease, and is not necessarily evidence of a non-organic problem.



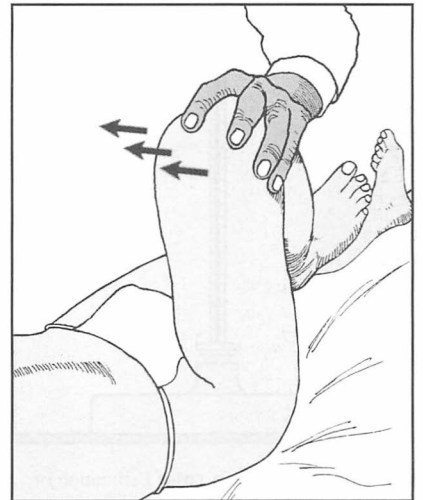8.45. Suspected thoracic cord compression: This may be crudely assessed by testing the abdominal reflexes. Use a blunt object such as the handle of a tendon hammer to stroke the skin in each paraumbilical skin quadrant. Failure of the umbilicus to twitch in the direction of the stimulated quadrant suggests cord compression on that side at the appropriate level. (The muscles of the upper quadrants are supplied by T7–10, and the lower by T10–L1.)



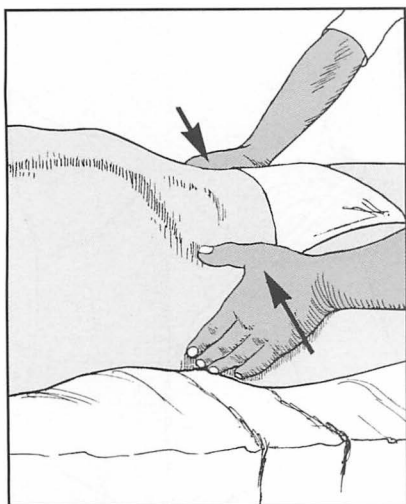
8.46. Suspected thoracic motor root dysfunction: Beevor's sign: The patient is asked to place his hands behind his head, flex his knees, and sit up. Movement of the umbilicus to one side (and up or down) suggests that the abdominal muscles on that side are unopposed, i.e. there is weakness on the opposite side. (See Frame 45 for the relevant muscle innervation.) This may result from nerve root compression by an osteophyte, from a local tumour, poliomyelitis or spinal dysraphism.



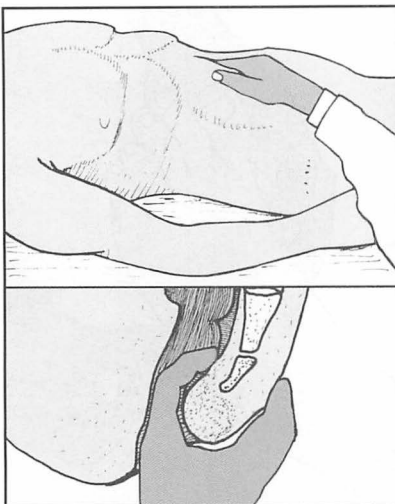8.47. Suspected ankylosing spondylitis: Check the patient's chest expansion at the level of the fourth interspace. The normal range in an adult of average build is at least 6 cm. Less than 2.5 cm is regarded as highly suggestive of ankylosing spondylitis. In addition, look for evidence of iritis, which is often associated with this condition.



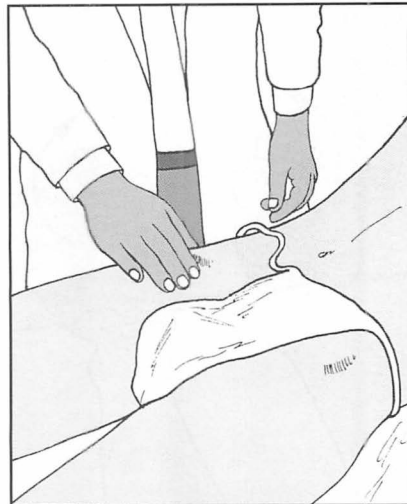8.48. Suspected sacroiliac joint involvement (1): Flex the hip and knee and forcibly adduct the hip. Pain may accompany this manoeuvre in early ankylosing spondylitis, tuberculosis and other infections, and Reiter's syndrome, but many false positives do occur with this test.



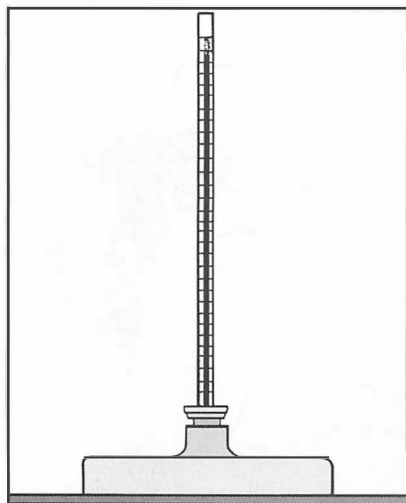
8.49. Suspected sacroiliac joint involvement (2): Note whether pain is produced by pelvic compression or by trying to 'open out' the pelvis with the thumbs hooked round the anterior spines. Alternatively, with the patient in the prone position, place the side of one hand over the sacrum and upper natal cleft; press down hard, using the other hand to assist. True sacroiliac pain may occur in women shortly before and after childbirth.



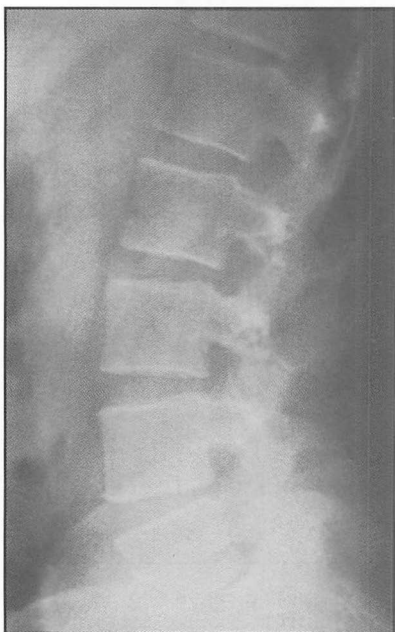8.50. Abdominal examination: This is an essential part of the investigation of all cases of back pain. Rectal or vaginal examination may be required on the indication of the history and any other elements in the case. The sacrococcygeal joint may be examined by first grasping the coccyx between the index (in the rectum) and the thumb outside, and then gently moving the joint. In coccydynia, marked pain normally accompanies this manoeuvre.



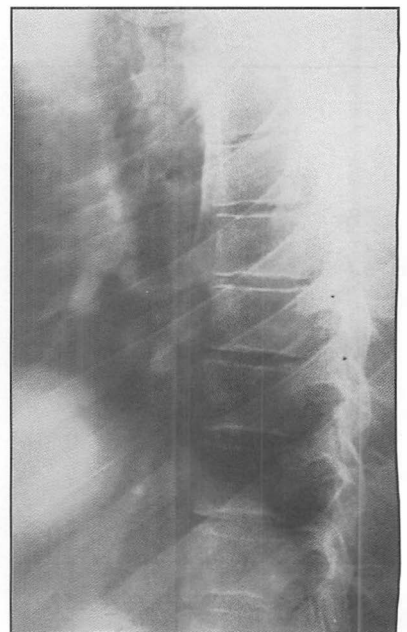8.51. Circulation: The peripheral pulses and circulation should also be checked in all cases. Back and leg pain caused by arterial insufficiency is usually aggravated by activity, and absence of femoral pulsation is of particular significance.



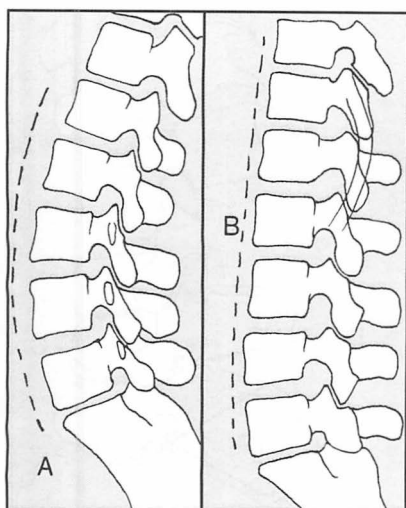
8.52. Sedimentation rate: Estimation of the sedimentation rate is a valuable screening test in the investigation of all spinal complaints. It is normal in prolapsed intervertebral disc, mechanical back pain, spinal stenosis and Scheuermann's disease, but elevated in ankylosing spondylitis, many infections and neoplasms. It is best if 25 mm is taken as the upper limit of normal. False positives are not uncommon, but false negatives are rare.



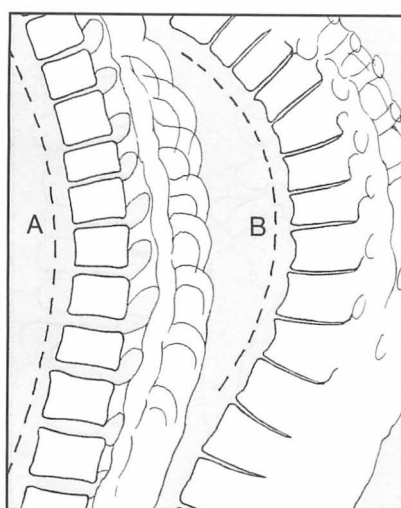
8.53. Radiographs (1): An anteroposterior and lateral are the standard projections for both the lumbar and thoracic spine. Localized views of the lumbosacral junction are a useful addition. This is a typical example of a normal lateral radiograph of the lumbar spine. In filling out the request card, if a specific area is under suspicion state this if possible, so that the central ray of the projection can be appropriately positioned.



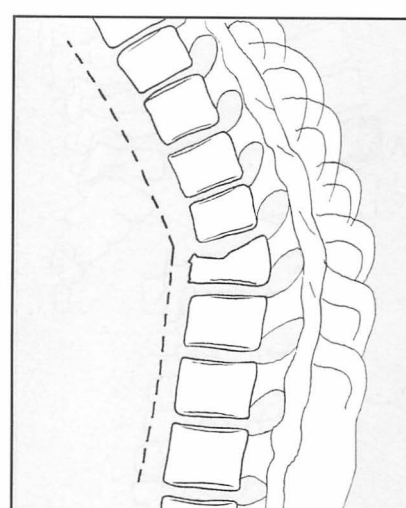
8.54. Radiographs (2): Normal lateral thoracic spine.



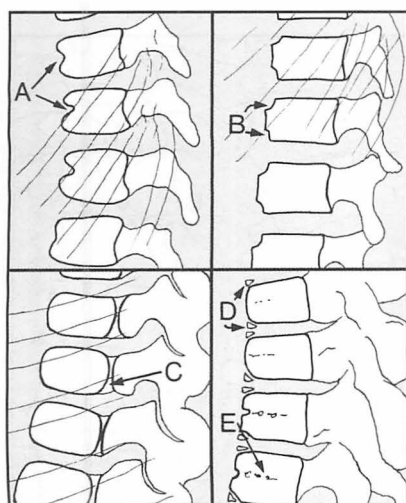
8.55. Radiographs (3): In the lateral, note first the lumbar curve: (A) typical normal: (B) loss of lordosis (most often seen in prolapsed intervertebral disc as a result of protective muscle spasm, but not confirmatory).



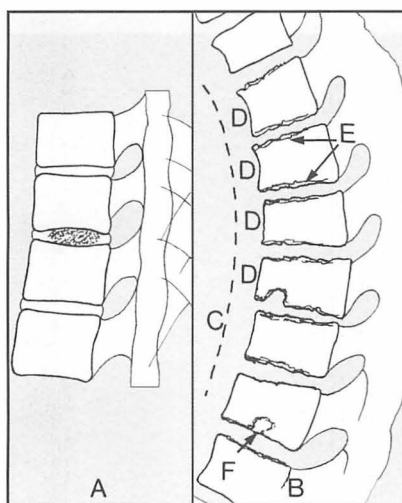
8.56. Radiographs (4): In the thoracic spine note (A) a typical normal curve: (B) an increased but regular curve typical of senile kyphosis. Scheuermann's disease is another frequent cause of a regular dorsal kyphosis. Kyphosis may be measured on the radiographs with the technique for assessing scoliosis (see later). 45° is taken as the upper limit of normal.



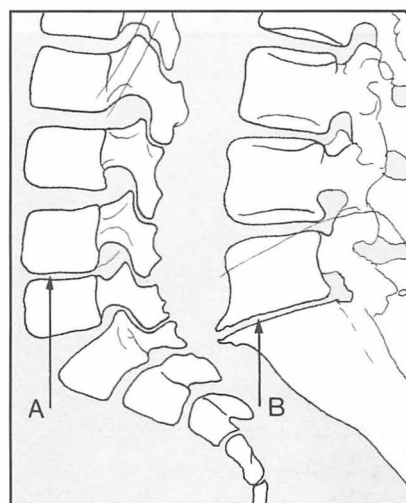
8.57. Radiographs (5): In both the lumbar and the thoracic spine note any sharp alteration in the curvature (angular kyphosis), found typically where there is pathology restricted to one or two vertebral bodies, e.g. from fractures, TB or other infections, tumour, osteoporosis and osteomalacia with local vertebral body collapse.



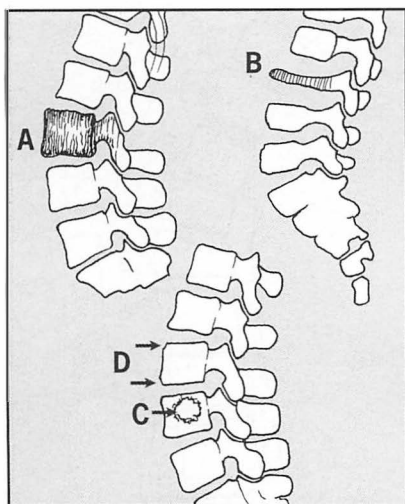
8.58. Radiographs (6): Now look at the shape of the bodies and the size of the discs. Compare with the bodies and disc spaces above and below. The following are normal in the child's spine: (A) anterior clefts, (B) anterior notches, (C) incomplete fusion of elements, (D) epiphyses, (E) vascular tracks (which may persist).



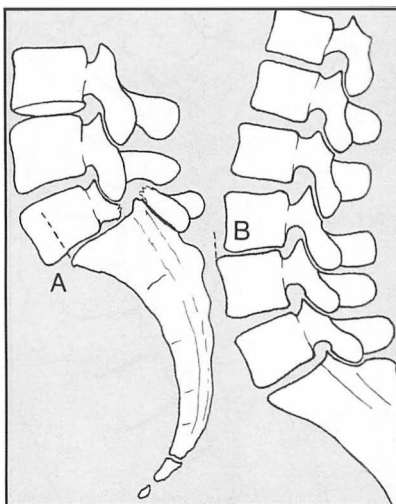
8.59. Radiographs (7): Note (A) disc calcification; (B) the typical appearance of Scheuermann's disease, with (C) kyphosis, (D) anterior wedging of not less than 5° involving at least three sequential vertebrae, (E) ragged appearance of the epiphyses. Note (F) a central disc herniation (Schmorl's node); this is not always associated with Scheuermann's disease.



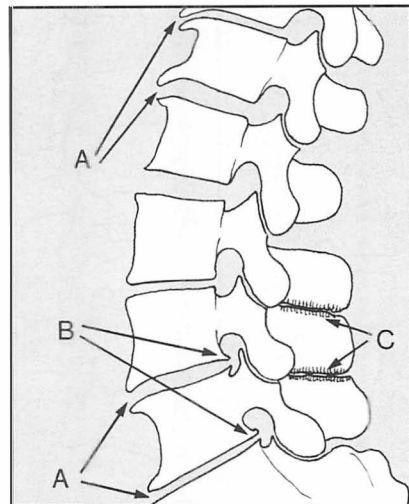
8.60. Radiographs (8): Note (A): disc narrowing at any level in the spine is the earliest evidence of tuberculosis and other infections; (B) Narrowing at L5-S1 and, less commonly, in the two spaces above occurs in long-standing disc lesions and is often associated with anterior lipping.



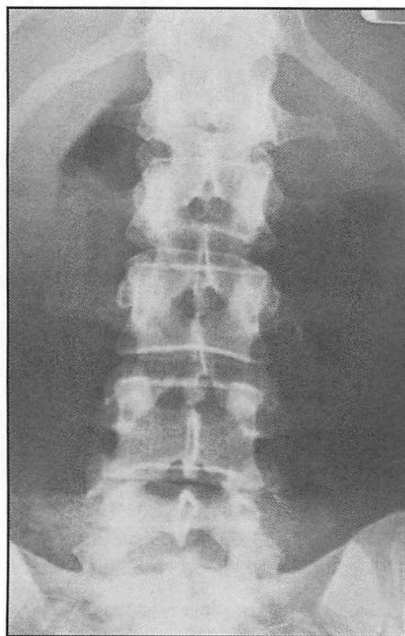
8.61. Radiographs (9): Note (A) increased density and the 'picture-frame' appearance of the vertebral bodies in Paget's disease; (B) marked narrowing and increased density seen in Calvé's disease (vertebra plana); (C) any space-occupying lesion in a vertebral body (usually due to tumour or infection (but note Schmorl's nodes)); (D) corner vertebral erosions (Romanus lesions), seen in ankylosing spondylitis.



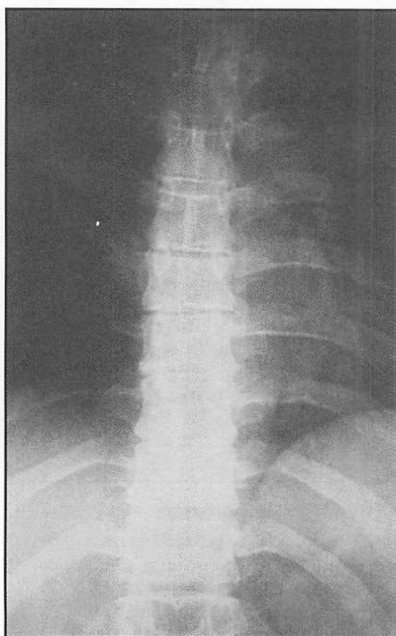
8.62. Radiographs (10): Note the relationship of each vertebra to its neighbour. In particular, note (A) spondylolisthesis (see also later); (B) retrospondylolisthesis (usually associated with disc degeneration).



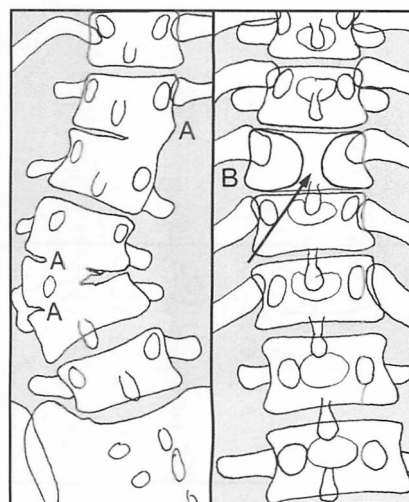
8.63. Radiographs (11): Lippling is seen in chronic disc lesions, mainly at L5-S1, but also at the other rarer disc prolapse sites. Note (A) anterior lipping; (B) posterior lipping. Lippling is also the main feature (at all levels) of osteoarthritis. Note (C) impingement of spinous processes ('kissing spines').



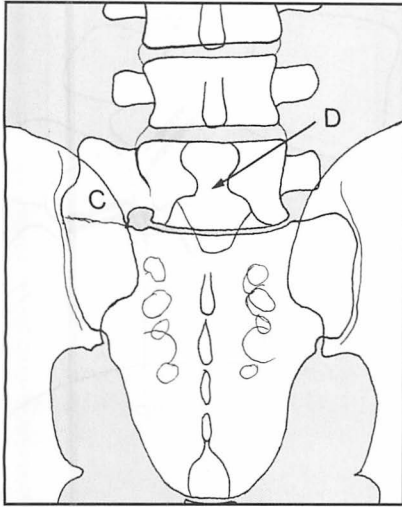
8.64. Radiographs (12): Normal anteroposterior view of the lumbar spine.



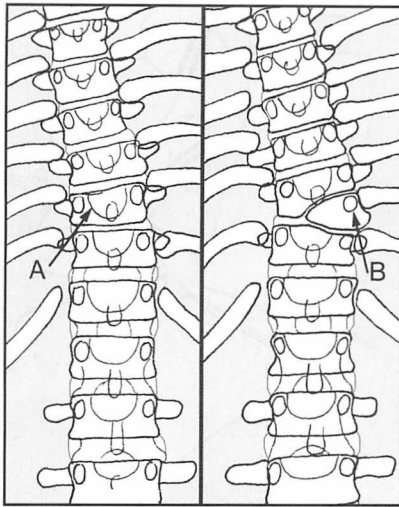
8.65. Radiographs (13): Normal anteroposterior view of the thoracic spine.



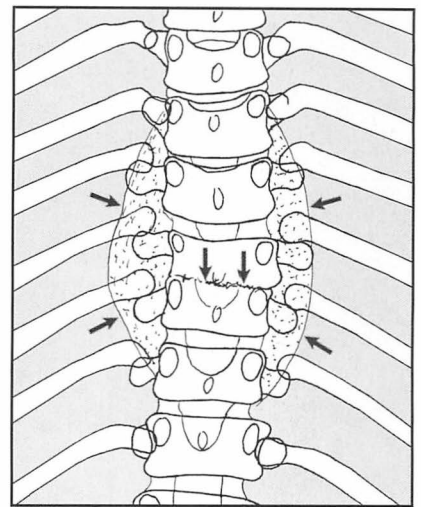
8.66. Radiographs (14): In the anteroposterior view note the presence of any congenital abnormalities, such as (A) congenital vertebral fusion, often associated with a congenital scoliosis; (B) anterior spina bifida, in which there is failure of fusion of the vertebral body elements (this is usually symptom free).



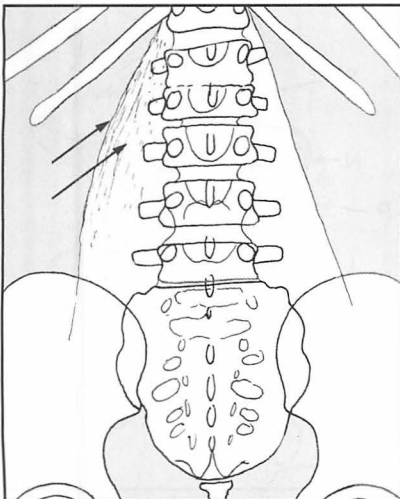
8.67. Radiographs (15): Note also any anomalies of the lumbosacral articulation, such as (C) partial sacralization of the fifth lumbar vertebra, a possible cause of low back pain. Note also (D) the presence of (posterior) spina bifida.



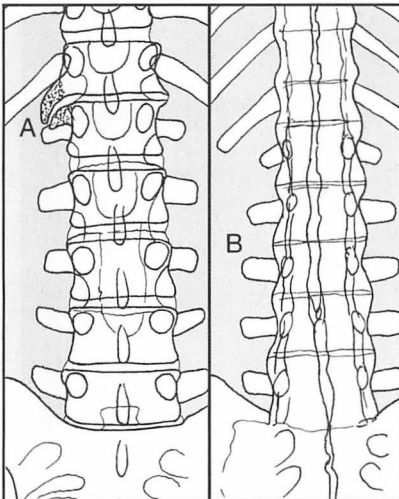
8.68. Radiographs (16): Note (A) the presence of any localized lateral angulation of the spine due to lateral vertebral collapse, e.g. from fracture, infection, tumour, osteoporosis or other causes; (B) hemivertebra, a common cause of congenital scoliosis (note that, as illustrated, this is usually associated with an extra rib).



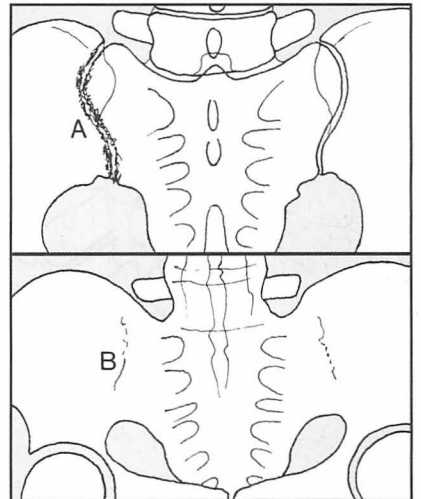
8.69. Radiographs (17): Look at the soft tissue shadows at the sides of the vertebrae, observing, for example, the fusiform increased density typical of a tuberculous abscess. Note disc obliteration and early lateral wedging.



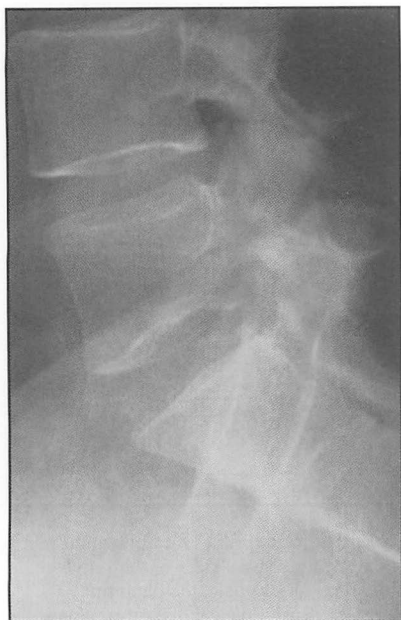8.70. Radiographs (18): Examine the psoas shadows for symmetry. Lateral displacement of the edge of the shadow, and increased density within the main area occupied by psoas, suggests a psoas abscess, typically found in tuberculosis of the lumbar or lowermost thoracic spine.



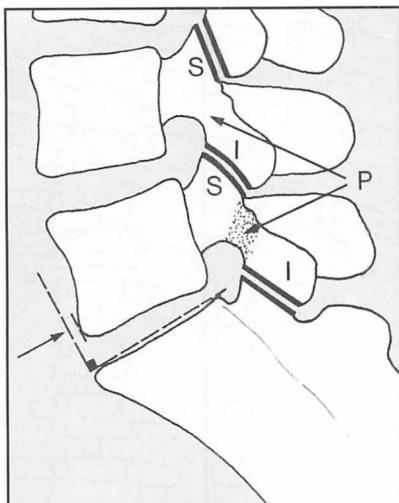
8.71. Radiographs (19): Look for lateral lippling, (A); at D12–L1 it may be an early sign of ankylosing spondylitis, but there and elsewhere it usually indicates osteoarthritis. 'Bamboo spine' (B) is diagnostic of ankylosing spondylitis. Note any body and facet joint fusions and ligament calcification.



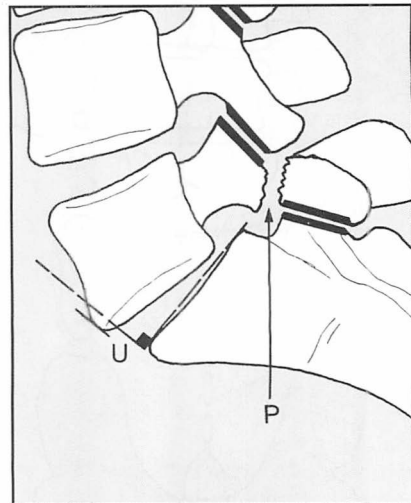
8.72. Radiographs (20): Look at the sacroiliac joints. (A) Unilateral involvement (sclerosis, cystic changes or obliteration) may occur in tuberculosis and other infections. Any asymmetry should be investigated by oblique projections and, if necessary, tomography or CT scans. Bilateral involvement (B) is common in ankylosing spondylitis, and should always be sought when this condition is suspected.



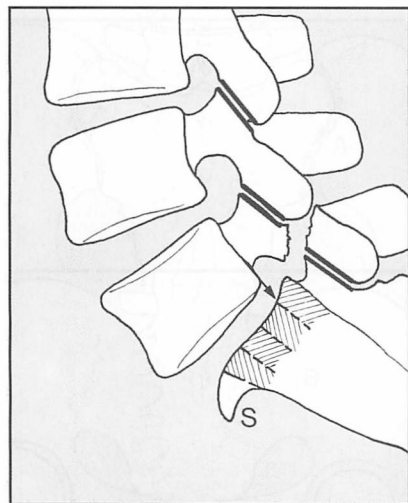
8.73. Radiographs (21): Normal localized lateral view of the lumbosacral junction.



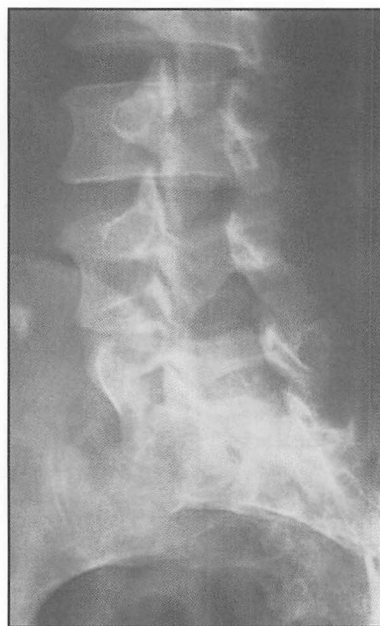8.74. Radiographs (22): Look for evidence of spondylolisthesis. In the normal spine the pars interarticularis (P) lying between (S) the superior and (I) the inferior articular facets is intact, and a vertical raised from the anterior margin of the sacrum lies in front of L5.



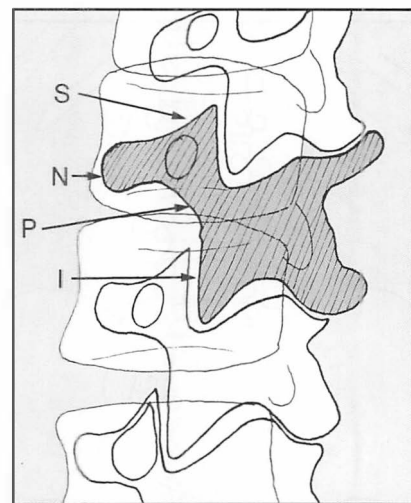
8.75. Radiographs (23): If spondylolisthesis is suspected, the lateral should always be taken with the patient standing. Note any defect (P) and any forward slip (U). The deformity may occur between L5 and S1, and much less frequently between L4/L5 or L3/L4.



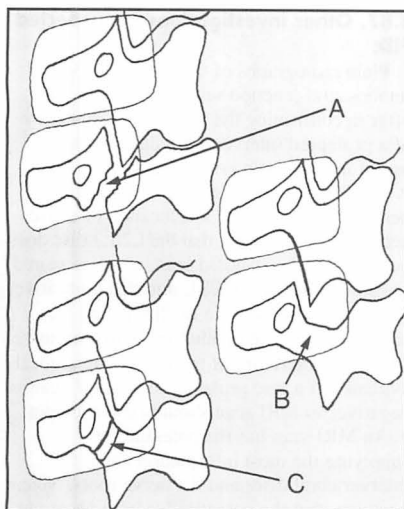
8.76. Radiographs (24): Note that (S) new bone formation (buttressing), if present, may make use of the anterior edge of the sacrum as a reference unreliable. Instead, note the relationship between the posterior edge of the slipping vertebra to the one below. The example shows a forward slip of 25%.



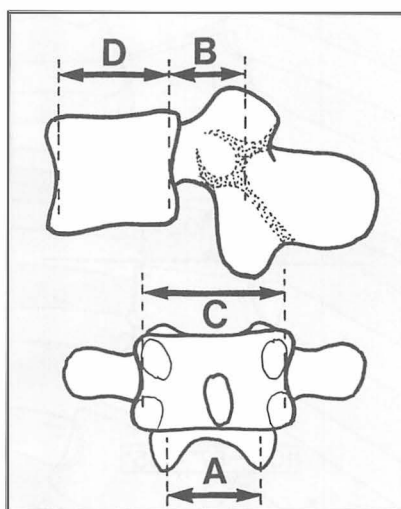
8.77. Radiographs (25): Normal oblique view of the lumbosacral junction.



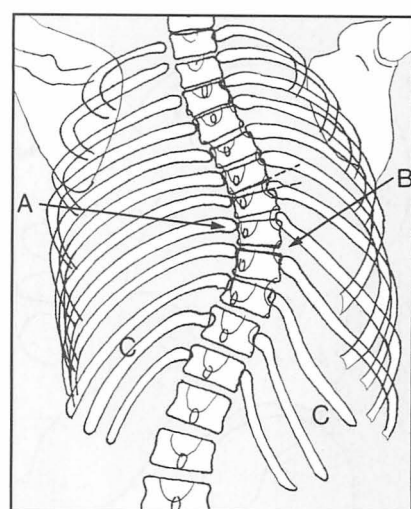
8.78. Radiographs (26): Oblique views are invaluable, provided they are taken in the plane of any defect. In interpreting these, identify the 'Scotty dog' shadows (shown dark grey and hatched). The nose (N) is formed by a transverse process; the ear (S) by a superior articular process; the front legs (I) by an inferior articular process; the neck (P) by the pars interarticularis.



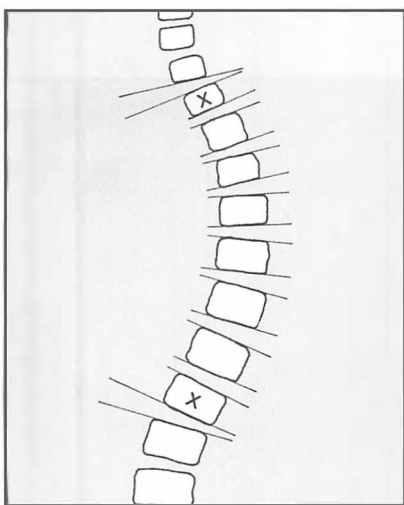
8.79. Radiographs (27): In spondylolisthesis (A) the 'dog' becomes decapitated owing to forward slip, and the inferior articular process of the vertebra above encroaches on the neck. In spondylolysis, where no slip has occurred, the neck (B) is elongated or (C) develops a collar. CT scans can also be of value provided the so-called gantry angle of the projection is at right-angles to the plane of the table.



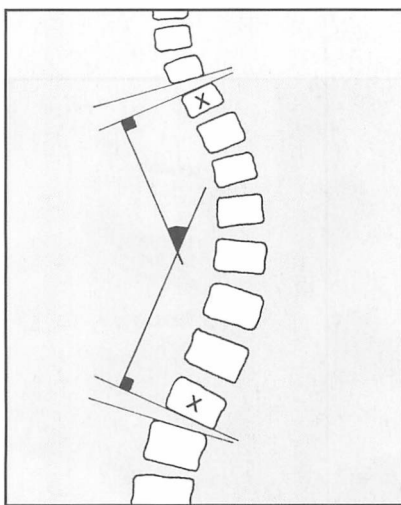
8.80. Radiographs (28): Where spinal stenosis is suspected, calculate the canal to body ratio, $A \times B : C \times D$, where A = interpedicular distance, B = spinal canal front-to-back (measured to the root of the spinous process), C = width of vertebral body, D = body, front-to-back. The normal range is from approximately 1:2–1:4.5. Values greater than 4.5 suggest spinal stenosis, but CT scans are of particular value in clarifying the site and extent of any narrowing.



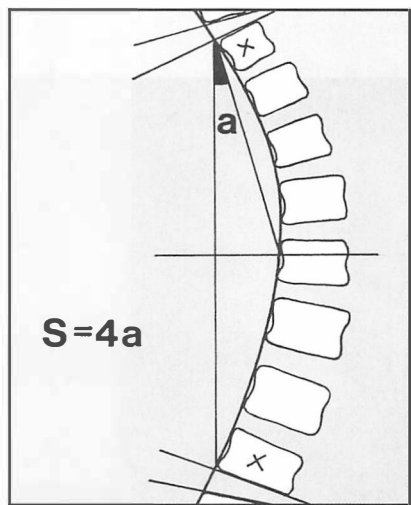
8.81. Radiographs (29): Note the presence of any structural scoliosis. This is associated with rotation of the vertebral spines towards the concavity (A), and narrowing of pedicles. On the convexity of the curve there is widening of disc spaces (B). In the thorax, there is ribcage distortion, (C). Identify the primary curves clinically, or by assessing absence of movement in lateral flexion radiographs.



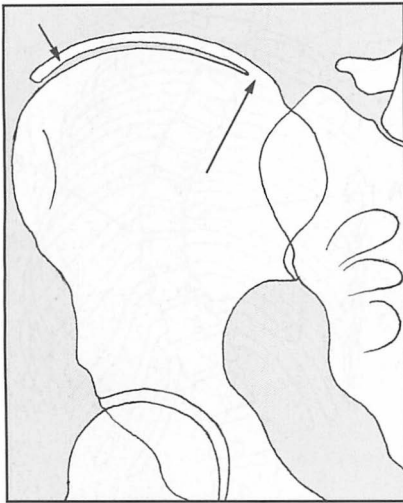8.82. Radiographs (30): To assess the severity of a scoliotic curve, and to allow its progress to be monitored it is necessary to measure the deformity. The Cobb method is most popular, although it is difficult to obtain consistent results with it. First, find the upper and lower limits of the primary curve by drawing tangents to the bodies and noting where the disc spaces begin to widen on the concavity of the curve.



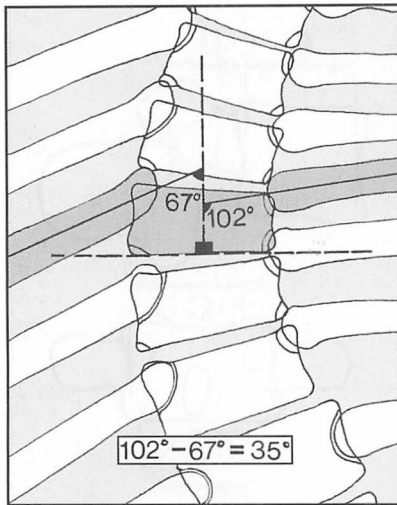
8.83. Radiographs (31): Now erect perpendiculars from the vertebrae that form the limits of the curve (marked 'X'). Note the angle between them. This is a measure of the primary curve, and can be used for comparison with past and future radiographs. Kyphotic curves may be measured in a similar way. Any decision regarding treatment must take into account the clinical picture, and not rely on the radiographs alone.



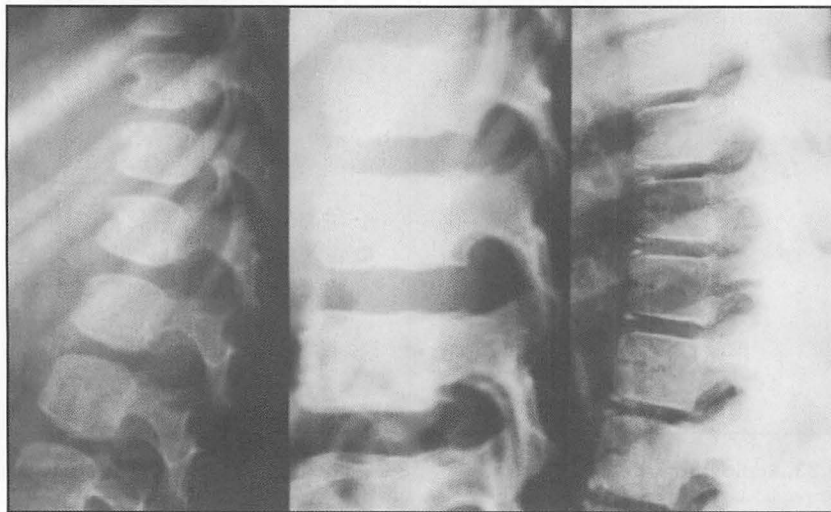
8.84. Radiographs (32): Capasso's method of measuring scoliotic curves is said to be more sensitive and accurate. The magnitude of the scoliotic curve (S) in degrees is obtained by multiplying by 4 the angle (a) subtended by a line joining the ends of the curves, with one running from the centre of the curve to one end of the curve: i.e. $S = 4a$. Again, note that in any case of suspected idiopathic scoliosis an MRI scan is mandatory to exclude syringomyelia, which is said to occur in 25% of cases.



8.85. Radiographs (33): *Risser's sign:* In late adolescence the appearance and progressive fusion of the iliac apophysis from behind forwards heralds skeletal maturity. It would appear, however, that very slight growth may continue in the spine for up to 10 years after cessation of limb growth. This, along with disc degeneration and other factors, can lead to late deterioration in scoliotic curves, particularly those greater than 60° , so that this sign is of somewhat limited value.



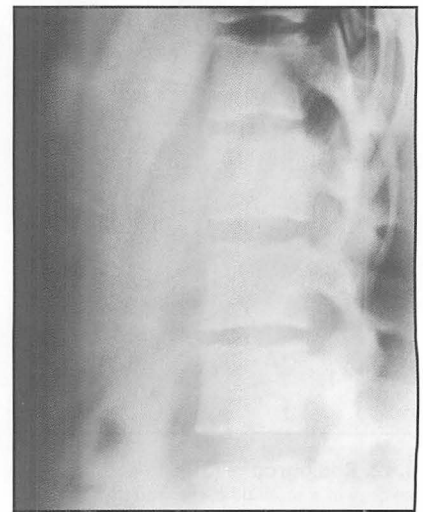
8.86. Radiographs (33): In infantile scoliosis note the difference in rib angles at the apex of the curve by the shown construction. A difference of 20° or more must be regarded as indicating a potentially progressive scoliosis. An improvement over a 3-month period carries a good prognosis (Mehta). The best prognosis in infantile scoliosis is in males where the onset occurs in the first year of life and the RVAD (rib-vertebral angle difference) is less than 20° .



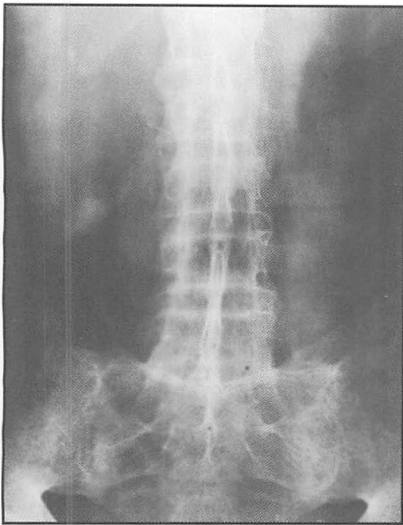
8.88. Spinal radiographs: special features: These three radiographs demonstrate anterior clefts, anterior notches, epiphyses and vascular tracks – normal features of the growing spine.

8.87. Other investigations in suspected PID:

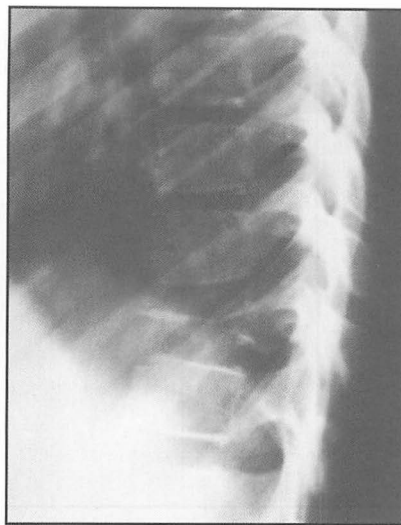
1. Plain radiographs of the lumbar spine and lumbosacral junction seldom have much to offer in confirming the presence or otherwise of a prolapsed intervertebral disc, but are useful in eliminating other pathology.
2. A CT scan is still a good procedure for demonstrating the size and location of a disc hernia. Note, however, that the L2/L3 disc does not show on the standard scan, which is geared to show L4/L5 and L5/S1, and that a negative CT scan is of less value in eliminating the presence of relevant pathology than a negative MRI scan; therefore, if there is strong clinical evidence of a disc prolapse and the CT scan is negative, an MRI scan should be carried out.
3. An MRI scan has the potential for supplying the most information about the intervertebral discs and the nerve roots. Note, however, that the potential for false negatives in MRI scans in cases of suspected PID is of the order of 10%, and that in about a third the findings are not compatible with the clinical picture. Where surgery or chemonucleolysis is being planned for a disc prolapse, an MRI scan should be carried out to confirm the size and location of the problem.
4. Myelography carries a high risk of complications, but may be required when the CT scan is inconclusive and MRI scanning is not possible; it is invaluable in demonstrating filling defects in the coverings of the cord or cauda equina, or of the root sleeves.



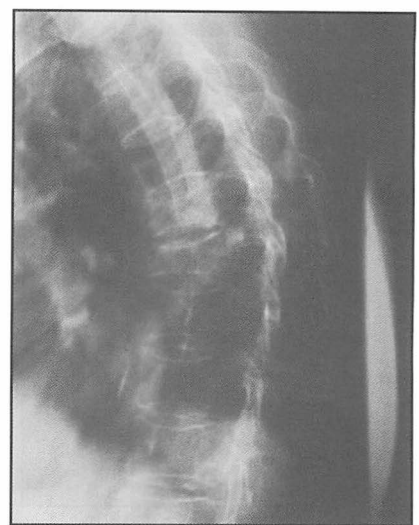
8.89. Spinal radiographs: examples of pathology (1): The radiograph shows narrowing of a single disc space.
Diagnosis: in this case the diagnosis was of tuberculosis of the spine. In most cases of spinal infections loss of disc height is the earliest sign.



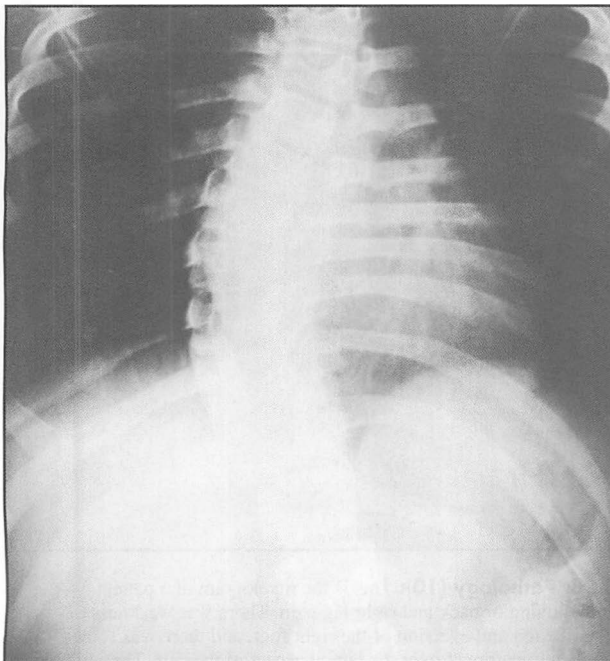
8.90. Pathology (2): The vertebral bodies throughout the thoracic and lumbar spine are fused, with early bambooing of the spine. The facet joints and the sacroiliac joints are also fused. There is ossification of the interspinous ligaments.
Diagnosis: ankylosing spondylitis.



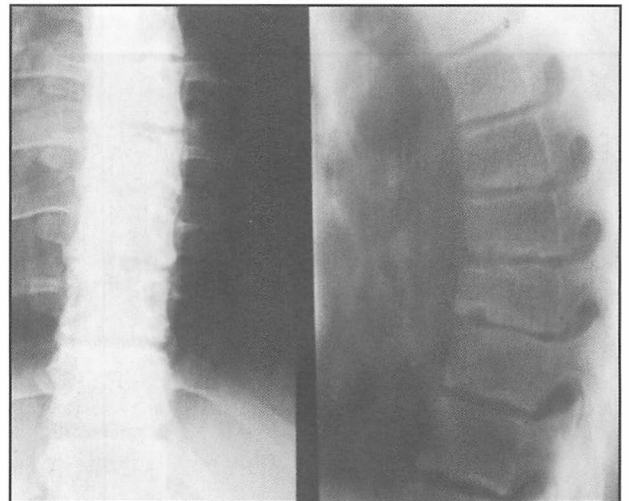
8.91. Pathology (3): In this radiograph of a girl of 10 there is complete flattening of a single vertebral body, with preservation of the disc spaces above and below.
Diagnosis: vertebra plana (Calvé's disease) due to eosinophilic granuloma. Note also the vertebral notches.



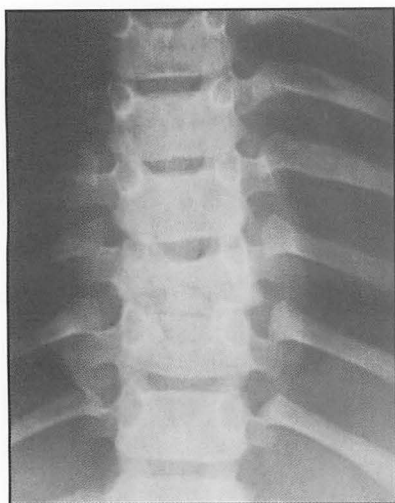8.92. Pathology (4): There is an angular kyphosis, with anterior wedging of D9.
Diagnosis: pathological fracture associated with osteomalacia. Similar appearances are found in the presence of spinal metastases.



8.93. Pathology (5): The radiograph shows a thoracic scoliosis, convex to the patient's right. There is vertebral rotation and asymmetry of the rib cage.
Diagnosis: idiopathic scoliosis, with fixed primary thoracic curve.

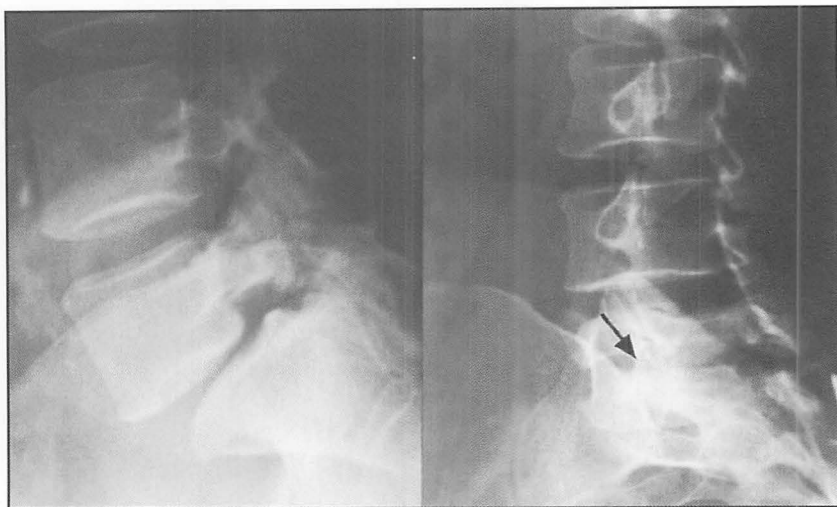


8.94. Pathology (6): There is a regular kyphosis, with slight anterior wedging of the vertebral bodies, irregularity of the disc margins and central disc herniation (Schmorl's nodes).
Diagnosis: the appearances are typical of Scheuermann's disease. Clinically the kyphosis was obvious, and spinal movements were greatly reduced.



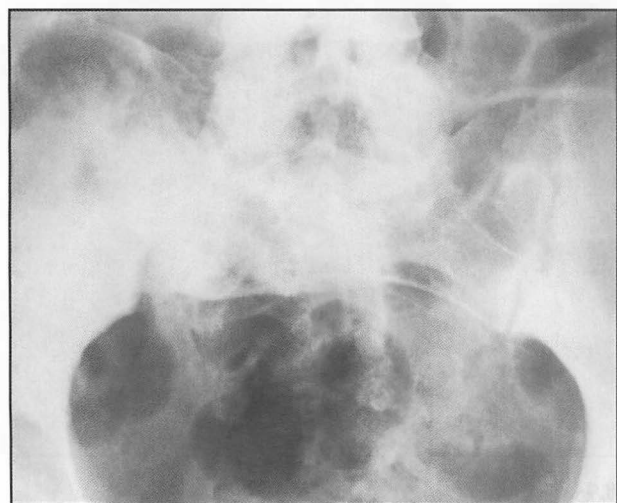8.95. Pathology (7): The radiograph is of an 8-year-old boy complaining of back pain, malaise, night sweats, loss of spinal movements, and pain on percussion over the spine. There is loss of a disc space, slight vertebral wedging, and a fusiform abscess shadow on both sides of the spine.

Diagnosis: the appearances are typical of tuberculosis of the spine.



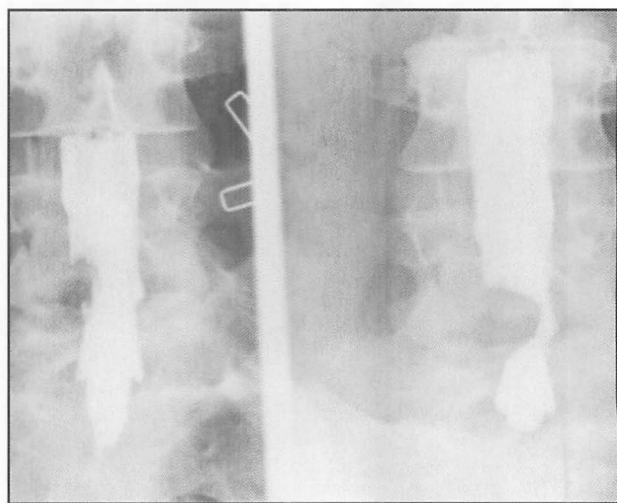
8.96. Pathology (8): The lateral radiographs show that there is forward slip of L5 on S1 of a little less than 25%. There is an associated defect in the pars interarticularis of L5. In the oblique projection the 'Scotty dog' has been decapitated. The patient complained of low back and buttock pain.

Diagnosis: long-standing spondylolisthesis of L5 on S1.



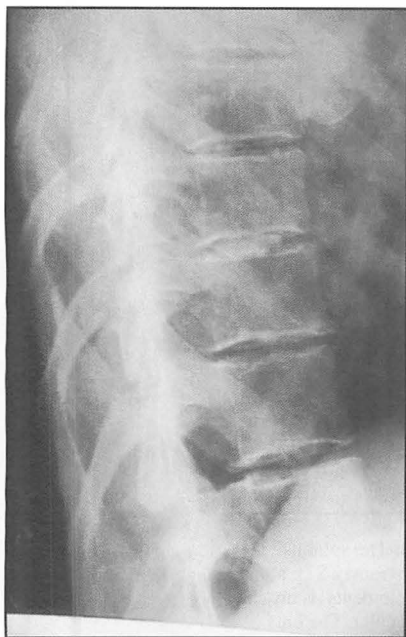
8.97. Pathology (9): There is increased density of the bony shadows in the region of the right sacroiliac joint, whose outline has become obscured. There was associated local pain, malaise and pyrexia. Attempts to spring the sacroiliac joints produced great pain.

Diagnosis: The appearances are typical of an infective (pyogenic) arthritis of the sacroiliac joint.



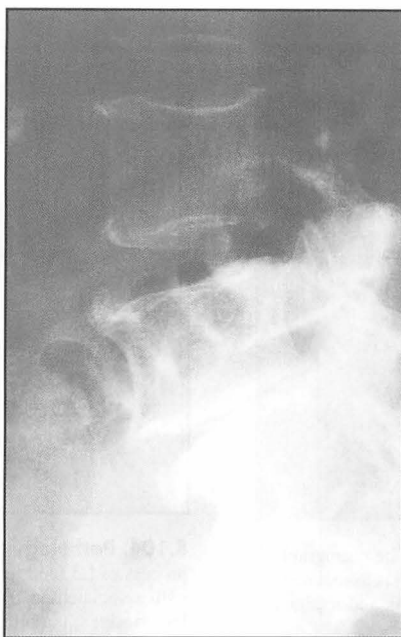8.98. Pathology (10): This is the myelogram of a patient complaining of back and right leg pain. There was weakness of dorsiflexion and eversion of the right foot, and there was some sensory impairment over the lateral aspect of the calf. The myelogram shows a well defined indentation of the contrast medium at the L4/5 level.

Diagnosis: prolapsed intervertebral disc. At operation the L5 root was found stretched over the prolapse.



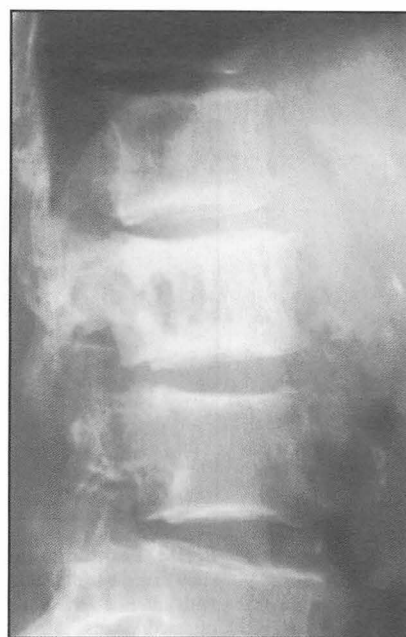8.99. Pathology (11): There is calcification in an intervertebral disc with no significant narrowing of the corresponding disc space.

Diagnosis: This is an incidental finding, and is of no particular significance as a cause of low back pain.



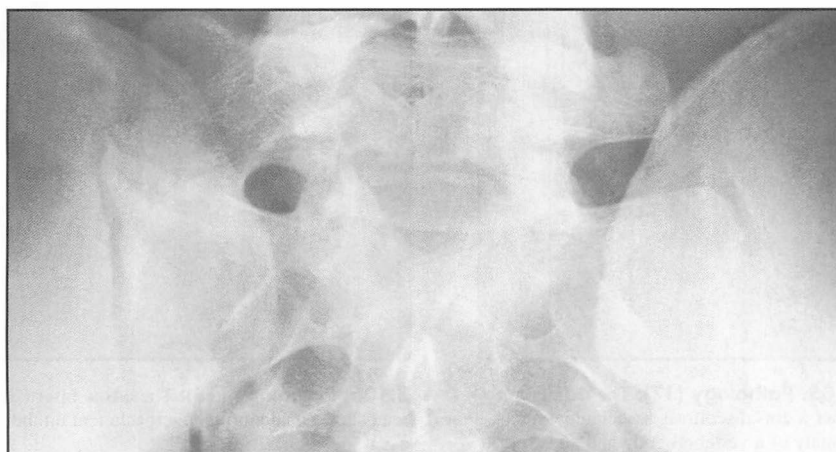
8.100. Pathology (12): There is narrowing of the L5-S1 disc space, with anterior lipping of the corresponding vertebrae.

Diagnosis: the appearances are typical of degenerative disc disease and lumbosacral osteoarthritis.



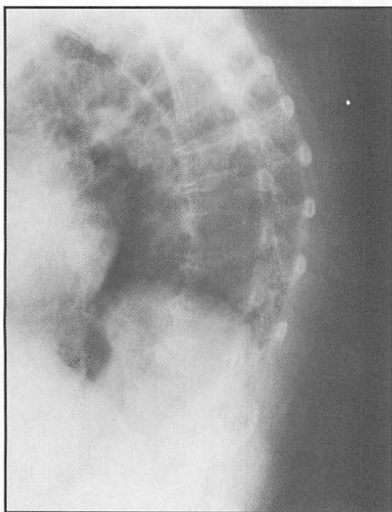
8.101. Pathology (13): There is striking alteration of bone texture affecting a single vertebra.

Diagnosis: this 'picture frame' appearance is typical of Paget's disease. At this site there would not necessarily be any associated symptoms.

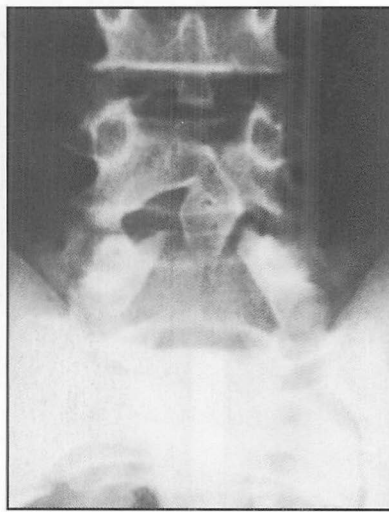


8.102. Pathology (14): There is a transitional vertebra, with the transverse process on one side articulating with both the sacrum and ilium.

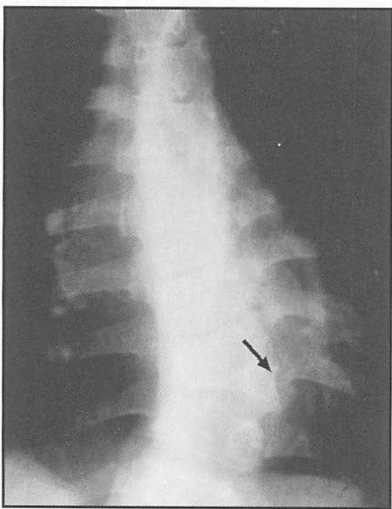
Diagnosis: congenital abnormality of lumbosacral articulation. Some consider that this pattern of spinal anomaly, because it produces an asymmetrical distribution of local stresses, may be a cause of back pain.



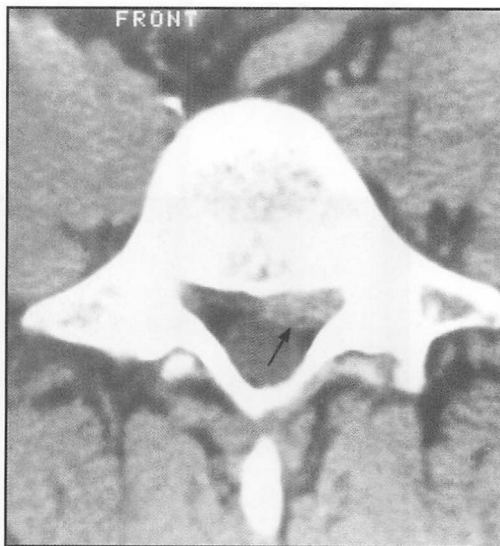
8.103. Pathology (15): The radiographs show a regular dorsal kyphosis associated with anterior vertebral lipping and a degree of osteoporosis.
Diagnosis: senile kyphosis.



8.104. Pathology (16): The spinous process of L5 (and less obviously S1), along with associated posterior elements, is absent.
Diagnosis: spina bifida occulta. The only disturbance noted in the lower limbs was a bilateral pes cavus.



8.105. Pathology (17): The radiographs shows a dorsal scoliosis associated with an anomaly of a vertebral body and an extra rib on the convexity of the curve.
Diagnosis: hemivertebra and structural scoliosis.



8.106. Pathology (18): The arrow inserted in this CT scan shows an abnormal encroachment on the spinal canal.
Diagnosis: there is a left-sided intervertebral disc prolapse (note the orientation to the right of the illustration), with distortion of the thecal shadow. It was associated with left-sided sciatic symptoms.

CHAPTER

9

The hip

Developmental dislocation of the hip (DDH) 166

DDH in the older child 167

DDH in the adult 167

The dysplastic hip 167

The irritable hip 168

Acute pyogenic arthritis of the hip 169

Slipped femoral epiphysis 170

Primary osteoarthritis of the hip 170

Secondary osteoarthritis of the hip 170

Rheumatoid arthritis 171

Other conditions affecting the hip 171

Conditions associated with total hip joint replacement 172

Hip assessment 174

Inspection 177

Leg shortening 177–181

Palpation 181

Movements 182–186

Patrick's test 183

Trendelenburg's test 186

Testing the gluteal muscles 187

Aspiration of the hip 187

Ortolani's test 187

Barlow's test 188

Radiographs of the neonate 188

DDH in the older child 188–189

Radiographs 189–195

Perthes' disease 192

Slipped femoral epiphysis 193

DDH 194

After total hip replacement 195

Pathology 195–199

DEVELOPMENTAL DISLOCATION OF THE HIP (DDH)

This condition occurs in the perinatal period and involves displacement of the femoral head relative to the acetabulum; if untreated it disrupts the normal development of the hip joint. The term 'congenital dislocation of the hip' (CDH), now less frequently used, is for the main part virtually synonymous. Note, however, that the contraction 'DDH' may be somewhat confusingly used for 'developmental dysplasia of the hip'.

The term 'neonatal instability of the hip' (NIH) is of particular value as it is clearly defined: it describes a condition in which the hip is dislocated, able to be dislocated, or is unstable at examination during the first 5 days after delivery. Similarly, 'late-diagnosed DDH' is used to describe a dislocated or dislocatable hip diagnosed after the age of 1 week.

The condition is much more common in girls than in boys; there is a familial tendency, and a well established geographical distribution of the disorder. It is commoner after breech presentations, and it may occur in conjunction with other congenital defects.

A simple test devised by Ortolani in the 1960s was found to show instability in the hips of some newborn children, and it was thought that this instability was directly related in every case to congenital dislocation of the hip. As a result, it was considered that if all the newborn could be screened with this test, and treated promptly if instability were found, that the condition would no longer pose a problem. Unfortunately, later experience showed that a number of children who had passed the screening test went on to develop hip dislocations. It also became clear that some unstable hips could resolve without treatment; and that treatment itself (in an abduction splint) was not free from complications (about 10% developing avascular necrosis). When ultrasound screening is added to the clinical examination, there is a dramatic increase in the number of positive results, most of which resolve without treatment.

To accommodate these confusing facts, a number of regimens have been developed. One typical example recommends the following:

1. All children should be examined during the first 3 months of life on at least two occasions, by those expert in the performance of the screening tests.
2. If the child is in a high-risk group (breech presentation, family history of DDH, clicking hip, the presence of other deformities etc.), then ultrasound screening should be added. If some doubt remains, the hips should be X-rayed at 3–4 months. (Note that X-ray examination of the hips is not of much diagnostic value at birth (owing to skeletal immaturity), but can be helpful by about 3–4 months.) If still negative, the hips should be re-examined clinically at 6 months and when weight bearing commences.
3. If the hip is clearly dislocated, then splintage should be commenced immediately.
4. If the hip is not dislocated, but *can* be dislocated (Barlow's test), it should be re-examined at weekly intervals for 3 weeks. If instability remains, then some recommend that splintage (in abduction) should then be commenced, although others prefer to have both X-ray and ultrasound confirmation. There are a number of splints available for the treatment of DDH (Malmö, van Rosen, Barlow, Pavlik harness, frog pattern plaster cast etc.), and whatever is used it is continued until the hip becomes stable (often by about 12 weeks).

DDH IN THE OLDER CHILD

This must be suspected in any child where there is disturbance of gait or posture, shortening of a limb, or indeed any complaint in which the hip might be implicated. If dislocation of the hip is diagnosed late, treatment is aimed at restoring the hip to as near normal as possible. Each case must be assessed on its own merits, but the general principles of treatment are common to all:

1. The head of the femur must be reduced into the acetabulum. This may be possible by manipulation alone, with or without a preliminary period of traction (to bring the femoral head down to the level of the acetabulum). An MRI scan can provide important information regarding any tissue that has the potential to prevent the femoral head from entering the socket (such as adhesion of the joint capsule to the ilium, an inverted limbus (the thickened acetabular labrum) or a displaced transverse ligament), and be a guide regarding the necessity for open reduction.
2. Once the hip has been reduced, the position must be maintained until stability is achieved; and from an early stage as much movement as possible should be allowed, to encourage concentric development of the head of the femur and the acetabulum. A popular method is to hold the hip in internal rotation by the application of a Batchelor plaster; this permits movements of the hip in other planes. Such a plaster is usually retained for about 12 weeks.
3. In a very high percentage of cases there is an associated anteversion deformity of the femoral neck. To help retain the femoral head in the acetabulum and encourage concentric development, this is often corrected surgically by a rotational osteotomy of the proximal femur, performed at the end of the period of plaster fixation.
4. If the acetabular roof fails to develop properly and remains shallow (acetabular dysplasia), so that the femoral head is poorly contained (predisposing the joint to secondary osteoarthritic change), a Salter osteotomy of the pelvis may be advised.

DDH IN THE ADULT

Where treatment in childhood has been unsuccessful, or even where the condition has not been diagnosed, a patient may seek help during the third and fourth decades of life. Symptoms may arise from the hips or the spine. In the hips, secondary arthritic changes occur in the false joint that may form between the dislocated femoral head and the ilium with which it comes in contact. In the spine, osteoarthritic changes are a result of long-standing scoliosis (in the unilateral case), increased lumbar lordosis (in both unilateral and bilateral cases), or excessive spinal movements that occur in walking. In a few cases hip replacement surgery may be considered, otherwise the treatment follows the lines for the conservative management of osteoarthritis of the hips and spine.

THE DYSPLASTIC HIP

Hip dysplasia is a condition in which the principal feature is that the femoral head is imperfectly contained by the acetabulum. The slope of acetabulum is frequently greater than normal, and it may be relatively small in comparison

with the femoral head. In early life this may be a major factor in developmental dislocation of the hip, but if the hip does not dislocate it may nevertheless give trouble later in life. In the dysplastic hip the central area only of the femoral head transmits the forces of weightbearing to the acetabulum, increasing the joint loadings and predisposing the hip to osteoarthritis and in some cases instability. The symptoms are those of osteoarthritis of the hip, and they may present during the second and third decades of life. Rapid deterioration is the rule. In the younger patient a Chiari osteotomy of the pelvis, an acetabular shelf operation or a high femoral osteotomy may improve the containment of the femoral head, relieve symptoms and slow the onset of osteoarthritis. In the older patient, replacement arthroplasty may be considered.

THE IRRITABLE HIP

In childhood there are a number of conditions affecting the hip which may be indistinguishable in their initial stages. They all give rise to a limp, restriction of movements, and sometimes pain in the joint (irritable hip). Children with this history are admitted routinely and treated by light traction until a firm diagnosis has been made. The commonest conditions responsible for irritable hip are transient synovitis, Perthes' disease and tuberculosis of the hip.

TRANSIENT SYNOVITIS

This is the commonest cause of the irritable hip syndrome. The child presents with a limp, and there is sometimes a history of preceding minor trauma which in some cases at least is coincidental. Raised interferon levels have been found, which suggests that a viral synovitis may often be the cause. There is restriction of extension and internal rotation in the affected joint, but there is no systemic upset and the sedimentation rate is generally normal. Radiographs of the hip sometimes give confirmatory evidence of synovitis, as does ultrasound examination, but no other pathology is usually demonstrable. Aspiration and culture of synovial fluid (which is not routinely performed) generally fail to provide any evidence of bacterial infection. A full recovery after 3–6 weeks' bed rest is the rule. In a number of cases that have been slow to respond there have been positive faecal cultures of *Campylobacter*, and it is advised that this examination be performed routinely.

PERTHES' DISEASE

In this condition there is a disturbance of the blood supply to the epiphysis of the femoral head, so that a variably sized portion undergoes a form of avascular necrosis. The cause is unknown. It is commoner in boys than in girls, there is an association with anteversion of the femoral neck, and one or both hips may be involved. When both hips are affected they may be involved simultaneously or with an interval between them. Vague pain in the region of the hips, thighs or knees is a frequent accompaniment. Clinically, Perthes' disease may be suspected by the history, the child's age and sex, and by the restriction of rotation in the affected hip. As a rule, radiological changes are well established by the time the child presents with symptoms, and these will confirm the diagnosis. (Ultrasound examination shows capsular distension due to synovial thickening, with *both* hips being

generally affected at the earliest stages (as opposed to the findings in transient synovitis).) A pattern where the age of onset is late (i.e. over 12) has been described and is noted for its poorer prognosis.

The severity of the condition is dependent on the position and extent of the area of the femoral head involved. When a large part of the epiphysis is affected, there is a tendency to flattening and lateral subluxation of the femoral head; these changes are mirrored by the acetabulum, and the resultant deformity predisposes the hip to osteoarthritis later in life. If there is some doubt regarding the extent of these changes, an MRI scan will allow an accurate assessment. Thereafter, as a guide to management and prognosis, the investigative findings are used in an attempt to grade the case. This can be difficult in practice, and the results somewhat inconsistent. The most popular classification is that of Catterall, but those by Salter-Thompson and Herring have their advocates.

The aims of treatment have been summarized as the relief of symptoms, the containment of the femoral head, and the restoration of movements. The majority of patients, especially in the younger age groups (i.e. under 6), make a good recovery. The long-term results are dependent on the growth of the femoral head, and it is unfortunately the case that treatment has not been shown to materially affect this, or to influence the ultimate outcome. Nevertheless, it is accepted that in all cases the *acute* symptoms of pain and severe restriction of movements should be treated by bed rest and traction, followed by physiotherapy. In mild cases, where the prognosis by grading is judged to be good, no further treatment (apart from prolonged observation) is generally advocated, although some prescribe weight-relieving measures for a further period of some months to reduce the chances of weightbearing stresses leading to further deformation of the femoral head. The results of intervention in those cases judged to carry a poor prognosis are perhaps less clear. The lines of treatment frequently advocated aim at improving the congruity of the femoral head and acetabulum, and improving the effective range of movements in the hip (e.g. by a varus osteotomy of the femoral neck, or a Salter innominate osteotomy).

TUBERCULOSIS

Tuberculosis of the hip is now rare in Britain. The affected child walks with a limp and often complains of pain in the groin or knee. Night pain is a feature. Hip rotation becomes limited, a fixed flexion deformity develops and muscle wasting occurs. Radiographs of the hip in the early stages show rarefaction of bone in the region of the hip and widening of the joint space. As the disease advances there is progressive joint destruction, with abscess formation and sometimes dislocation. The diagnosis is usually confirmed by histological and bacteriological examination of synovial biopsy specimens, or by bacteriological examination of the aspirate.

In early cases complete resolution may be hoped for by antituberculous therapy, bed rest and traction. In the advanced case, joint debridement is carried out with efforts to obtain a bony fusion of the joint.

ACUTE PYOGENIC ARTHRITIS OF THE HIP

Staphylococcus is the organism most frequently responsible for acute infections in the hip joint. The infection is bloodborne and the diagnosis is seldom difficult. The onset is rapid, with high fever and toxæmia. All

movements of the hip are severely impaired and accompanied by great pain and protective muscle spasm. The organism responsible may be isolated by blood culture or joint aspiration. Treatment is by use of the appropriate antibiotics in doses large enough to obtain high local concentrations. Bed rest and immobilization are also essential.

SLIPPED FEMORAL EPIPHYSIS

This is a disease of adolescence and is commoner in boys than in girls. The attachment of the femoral epiphysis to the femoral neck loosens, so that the head appears to slide downwards on the femoral neck, giving rise eventually to a coxa vara deformity of the hip. The cause is unknown. In a number of cases there is a history of preceding trauma. A striking feature, however, is that in a high proportion of cases there is the suggestion of a hormonal disturbance. Many are fat, having the appearance of those suffering from the Frölich syndrome. Some cases have been noted to occur in association with hypothyroidism. The condition is frequently bilateral (25% at first presentation, rising later to 60%), and it is *essential* that the contralateral hip be kept under careful surveillance, particularly during the first 3 months.

Pain may occur in the groin or knee, and if the onset is very acute weightbearing may become impossible. There is usually restriction of internal rotation and abduction in the affected hip. The diagnosis is confirmed radiographically, the earliest changes being seen in the lateral projections. Late complications of slipped femoral epiphysis include avascular necrosis of the femoral head and chondrolysis.

Slight degrees of slip are treated by internal fixation of the epiphysis without reduction. If there is a large amount of acute displacement a gentle reduction may be attempted before fixation, although some are unwilling to undertake this as they are of the opinion that it may increase the risks of avascular necrosis. If the slip is long standing, osteotomy of the femoral neck (to correct the deformity) is often advised.

PRIMARY OSTEOARTHRITIS OF THE HIP

Primary osteoarthritis of the hip occurs in the middle-aged and elderly, and is often associated with overweight and overwork, although in many cases no obvious cause may be found.

Pain is often poorly localized in the hip, groin, buttock or greater trochanter, and may be referred to the knee. There is increasing difficulty in walking and standing. Sleep is often disturbed, and the general health of the patient becomes undermined as a result. Stiffness may first declare itself when the patient notices difficulty in putting on stockings and cutting the toenails.

Fixed flexion and adduction contractures are common, with apparent shortening of the affected limb. In the early stages weight reduction, physiotherapy and analgesics may be helpful; total hip replacement is the treatment of choice if the condition is advanced.

SECONDARY OSTEOARTHRITIS OF THE HIP

The symptoms of secondary osteoarthritis of the hip are identical to those of primary osteoarthritis. The condition occurs most frequently as a sequel to

developmental dislocation of the hip, congenital coxa vara, hip dysplasia, Perthes' disease, tuberculous or pyogenic infections, slipped femoral epiphysis, and avascular necrosis secondary to femoral neck fracture or traumatic dislocation of the hip.

In secondary osteoarthritis a younger age group is generally involved than in the case of primary osteoarthritis. In the young patient, where it is thought desirable to avoid the uncertain long-term morbidity of total hip replacement, a hip joint fusion may be considered in unilateral cases. Where pain is more a problem than stiffness, McMurray's osteotomy of the hip may sometimes be of value.

RHEUMATOID ARTHRITIS

The hip joints are frequently involved in rheumatoid arthritis. When both hips and knees are affected, the disability may be profound. In the well selected case, replacement of one or both hips may give a striking improvement in the patient's symptoms and mobility.

OTHER CONDITIONS AFFECTING THE HIP

Of the rarer conditions affecting the hip joint, the following are not infrequently overlooked:

1. Ankylosing spondylitis may present as pain and stiffness in the hip in a young man. There may be no complaint of back pain, but there is almost invariably radiographic evidence of sacroiliac joint involvement.
2. Reiter's syndrome may also first present in the hip.
3. Primary bone tumours are uncommon; of these, osteoid osteoma involving the femoral neck may be a cause of persistent hip pain. As this tumour is always small, repeated radiographic examination with well exposed films may be required to show it. The tumour may also be revealed as a 'hot spot' in isotope bone scans.
4. The snapping hip. 'Clunking' sounds emanating from the region of the hip on certain movements may be a source of annoyance to a patient. In most cases no more than reassurance should be offered, but where pain is a feature an effort should be made to trace the source and, if found, to consider surgery for the relief of the mechanical problem responsible. The two commonest sources are the iliotibial tract (which flicks over the prominence of the greater trochanter) and the iliopsoas at its musculotendinous junction. The latter may be tested specifically by flexing, abducting and externally rotating the hip; a click on extension from that position is diagnostic. Both are amenable to a Z-plasty.

The following important points should always be remembered in dealing with the hip joint:

1. *The commonest cause of hip pain in the adult is pain referred from the spine, e.g. from a prolapsed intervertebral disc.* Hip movements are not impaired, and there are almost invariably signs of the primary pathology, e.g. diminution of straight leg raising.
2. *In the elderly, pain in the hip with inability to bear weight is frequently due to a fracture of the femoral neck or of the pubic rami.* In an appreciable number of cases there is no history of injury, and radiographic examination is essential to clarify the problem.

3. *Flexion contracture of the hip may result from psoas spasm secondary to inflammation or pus in the region of its sheath in the pelvis.* This is seen, for example, in appendicitis, appendix abscess or other pelvic inflammatory disease. Examination of the abdomen is essential.

CONDITIONS ASSOCIATED WITH TOTAL HIP JOINT REPLACEMENT

Because of the success of hip joint replacement procedures many of these operations have been performed, and complications, which occur in about 5% of cases, are being seen with increasing frequency.

The most widely used replacement is the Charnley low-friction arthroplasty (LFA) or one of its many variants. In this, the socket is formed from high-density polyethylene and the replacement head from stainless steel. Both components are anchored with quick-setting acrylic cement. During the surgical approach to the hip the greater trochanter may be detached to gain better access; if so, it has to be reattached at the end of the operation; this often done with stainless steel wires.

There are a number of other replacements, which vary in the design of the parts, the materials used, and the techniques of their insertion. In some, the components are inserted without the use of acrylic cement, and the surgical exposure may be made without detachment of the trochanter. Where the functional requirements are not expected to be high (e.g. after intracapsular hip fractures in the very elderly) a hemiarthroplasty may be performed, where the femoral head is replaced with a stemmed prosthesis and the acetabulum is not interfered with.

Excluding complications that may arise in the immediate postoperative period, the problems which may subsequently occur may include the following:

1. **Dislocation.** The stability of the replacement is dependent on the precision with which the components have been aligned during their insertion, the design of the acetabular component (e.g. whether it has a posterior lip), the time that has elapsed since surgery and the degree of violence to which the components have been subjected. After any hip replacement, the fibrous capsule that forms round the artificial joint thickens and strengthens with time, leading to a progressive resistance to dislocation. In the first few months following surgery a badly aligned joint may dislocate under comparatively minor stress; in other cases, and at a later stage, considerable violence may be necessary. If dislocation occurs, weightbearing suddenly becomes impossible and there is usually marked pain. The limb shortens and may be externally rotated. The diagnosis is confirmed by X-ray examination. Treatment is by reduction (which occasionally needs to be an open one), usually followed by a period of traction until the hip becomes stable. In those cases where there is a major problem of component malalignment, a revision procedure may have to be considered should the dislocation recur.

2. **Component failure.** Socket failure is rare, but the stem of the femoral prosthesis may occasionally fracture. This is most likely when the patient is overweight or the component has a varus alignment, or loosens. Generally there is immediate loss of the ability to weightbear, and replacement of the fractured component becomes essential.

If the greater trochanter has been reattached with wires, these may fracture and fragment, giving rise to local discomfort and sometimes episodes of sharp, jaggling pain. This may be treated by removal of the broken wires. The trochanter itself may fail to unite and may displace. This may cause local discomfort and a Trendelenburg gait. Normally there is slow, spontaneous improvement, but in the early case where the fragment is large and displaced, reattachment may be considered.

3. Fracture of the femur. The femur may fracture (as it may do without the presence of a stemmed prosthesis) as a result of direct or indirect violence, e.g. from a fall. In other cases the forces responsible for the fracture may be less than normal. The presence of the prosthesis considerably reduces the total elasticity of the femoral shaft, giving rise to high stress concentrations in the region of the tip of the prosthesis (one of the commonest sites of fracture); the bone may also be weakened by fretting at the cement–bone interface (where there may be abrasive particle formation), by cystic changes, and by infection (which may be chronic and low grade).

Treatment is dependent on many factors, including the site and pattern of the fracture, its cause, and the general health of the patient, but in the majority of cases further surgery will usually be advised.

4. Component loosening and infection. When this occurs, it is usually at the interface between the cement and bone. It is commonest in the area of the femoral stem, although both components may be affected. The complaint is of pain and impairment of function, and the diagnosis is usually made on the basis of the radiological appearances. Loosening may be the result of infection; in some cases this may be frank, and in others, organisms of low pathogenicity may be found in the affected area. In many cases, although an element of infection may be strongly suspected, no organism can be found and an alternative cause may be sought. In many, loosening may be associated with particulate wear debris, and in others tissue sensitivity to the metallic elements of the components of the prosthesis has been blamed.

Infection may be introduced at the time of the initial operation and grumble on thereafter, leading to loosening, bone absorption, and distal migration of the femoral component. There may be flare-ups accompanied by more acute pain, malaise, and sometimes abscess formation. In other cases, it would seem that late infections may arise as a result of infection being bloodborne from a septic focus elsewhere.

The treatment of these complications is highly specialized. In the (uncommon) case of secondary infection, investigations by blood culture and aspiration, immobilization, and the prompt administration of the appropriate antibiotics may occasionally lead to resolution. In the case of loosening without the discovery of any organism, a revision procedure may be advised. Where there is evidence of a low-grade infection, a very thorough debridement under antibiotic cover, followed by the insertion of a fresh prosthesis of a pattern designed to accommodate any migration or loss of bone stock, may be attempted (either as a one or two-stage procedure). Additional measures to control recurrence of local infection may include the use of antibiotic-loaded cement. Where infection is well established, removal of the components and cement may be the only solution which will allow the infection to be overcome, even though limb function will obviously be seriously compromised. In some of these cases, however, once

the infection has been eradicated a further replacement procedure may be contemplated.

HIP ASSESSMENT

For over 50 years attempts have been made to devise a method of gauging the performance of a given hip, so that the extent and progress of any disability can be assessed and the results of surgery evaluated. Over 80 rating systems have been suggested, and the lack of standardization has prevented the direct comparison of reported series.

There is general agreement that certain functional parameters should be assessed. These include pain, gait, and the ability to perform certain activities of daily living. A problem is that there are differences in opinion on the weight that should be placed on each of the items that is assessed. In the widely used but often highly modified Harris System¹ a normal hip is rated as scoring 100 points, whereas the hip being examined is described as being so many percent of this theoretical normal. *Pain* (which is subjective and hard to assess with accuracy) is allocated 44 points. *Function*, which is highly detailed, is broken down into gait, the use of supports, and activities, and merits 47 points. *Range of movements* attracts only 5 points, and *absence of deformity* 4 points.

If a hip scoring system is being used to assess the results of a hip replacement (and this is one of the commonest indications), then it is necessary to include details of the radiographic appearances which are so important. This is a feature of many recent methods of assessment. Again, after much consultation among many interested groups, a comprehensive list of questions relating to pain, function, gait movements and radiological appearances has been produced.² The terminology has been described as standard and unalterable in its definition, so that without weighting results can be readily compared between series. Although use of the full list (described in the reference) may have to be considered where publication is intended, the questions in the clinical assessment are of such value in assessing any case that they are appended here.

PAIN

Degree:

- None – no pain
- Mild – slight and occasional pain; patient has not altered patterns of activity or work
- Moderate – the patient is active, but has had to modify or give up some activities or both, because of pain
- Severe – major pain and serious limitations

Occurrence:

- None
- With first steps, then dissipates (start up pain)
- Only after long (30 minutes) walks
- With all walking
- At all times

WORK/LEVEL OF ACTIVITY

Occupation, including housewife

Retired:

- No
- Yes

Nursing home:

- No
- Yes (date entered.....)

LEVEL OF ACTIVITY

- Bedridden or confined to a wheelchair
- Sedentary – minimum capacity for walking or other activity
- Semisedentary – white-collar job, bench work, light housework
- Light work – includes heavy housework, light employment, light athletic activity (e.g. walking 5 km or less)
- Moderate manual labour (e.g. work involving lifting weights of 23 kg or less), moderate athletic activity (e.g. walking or cycling more than 5 km)
- Heavy manual labour (e.g. work frequently lifting 23–45 kg), vigorous sports (e.g. tennis, squash)

WORK CAPACITY IN LAST 3 MONTHS

- 100%
- 75%
- 50%
- 25%
- 0%

PUTTING ON SHOES AND SOCKS

- No difficulty
- Slight difficulty
- Extreme difficulty
- Unable

ASCENDING AND DESCENDING STAIRS

- Normal (foot over foot)
- Foot over foot, using banister
- 2 feet on each step
- Any other method
- Unable

SITTING TO STANDING

- Can rise from chair without using arms
- Can rise from chair using arms
- Cannot rise independently

WALKING CAPACITY

Usual support needed:

- None
- 1 stick for long walks
- 1 stick

- 1 crutch
- 2 sticks
- 2 crutches
- Zimmer frame or equivalent
- Unable to walk

TIME WALKED

Without support:

- Unlimited (more than an hour)
- 31–60 minutes
- 11–30 minutes
- 2–10 minutes
- Less than 2 minutes, or indoors only
- Unable to walk

With support:

- Unlimited (more than an hour)
- 31–60 minutes
- 11–30 minutes
- 2–10 minutes
- Less than 2 minutes, or indoors only
- Unable to walk

REFERENCES

1. Harris W H. Traumatic arthritis of the hip. J Bone Joint Surg 1969; 81-A: 737–755
2. Johnston R C et al. Clinical and radiographic evaluation of total hip replacement. J Bone Joint Surg 1990; 72-A: 161–168

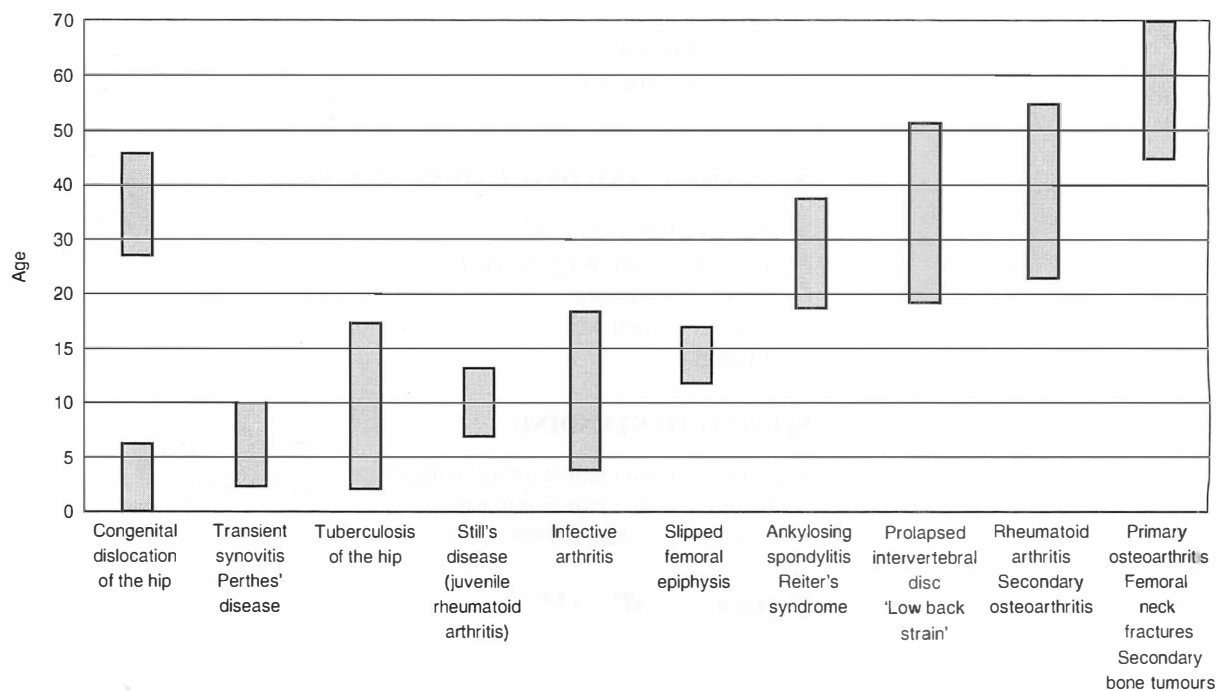
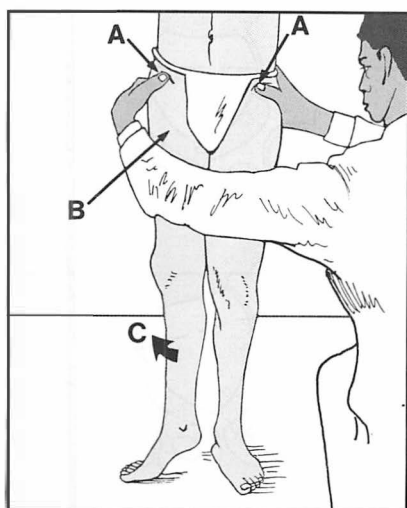
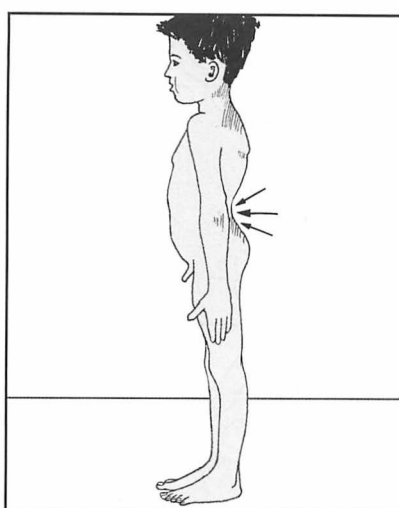


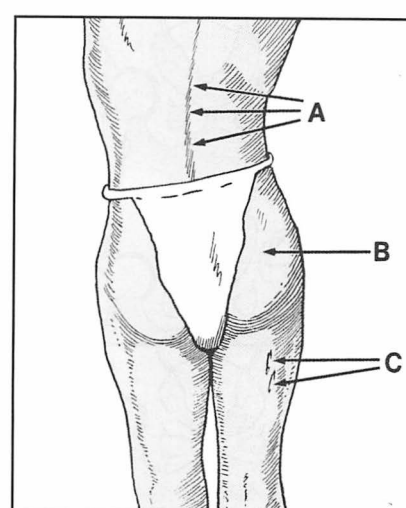
Table 9.1 Age distribution of common hip pathology



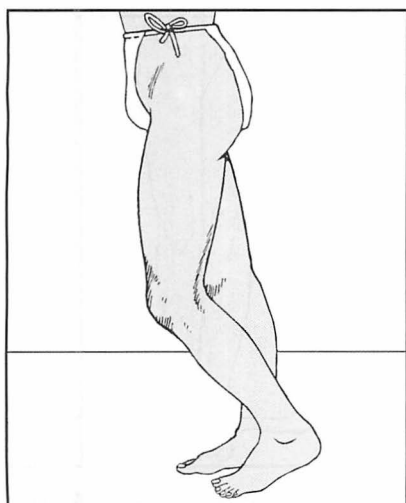
9.1. Inspection (1): Examine the standing patient from the front. Note (A) any pelvic tilting (e.g. from adduction or abduction deformity of the hip, short leg, scoliosis). (B) muscle wasting (e.g. secondary to infection, disuse, polio), (C) rotational deformity (common in osteoarthritis).



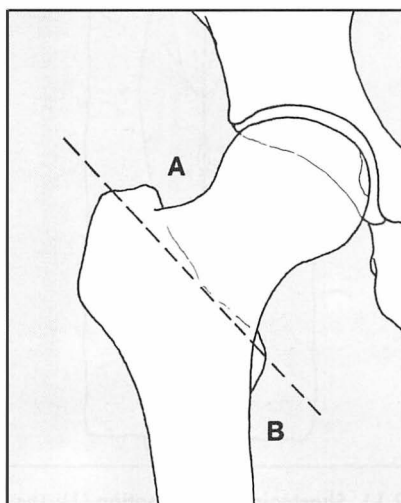
9.2. Inspection (2): Examine the patient from the side. Note any increased lumbar lordosis suggestive of fixed flexion deformity of the hip(s).



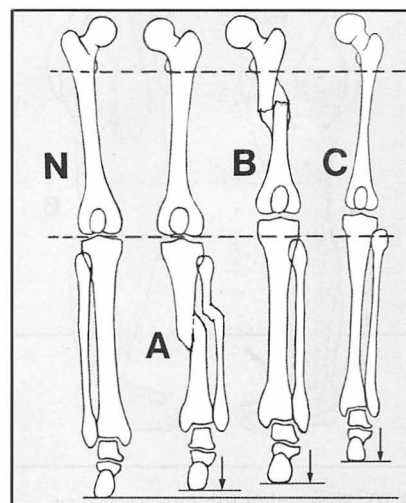
9.3. Inspection (3): Look at the patient from behind. Note (A) any scoliosis (possibly secondary to pelvic tilting from, for example, an adduction deformity of the hip). (B) gluteal muscle wasting (e.g. from disuse, infection), (C) sinus scars (e.g. secondary to tuberculosis).



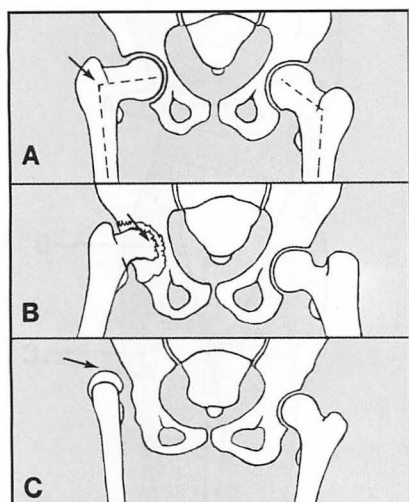
9.4. Gait: Observe the gait from the front, sides and behind. Analysis grows from experience. Try to assess the stride and dwell time on each side, and the possible factors of pain, stiffness, shortening and gluteal insufficiency. Note that a shuffling gait (where each foot is dragged on the ground in the swing phase) or a stomping gait (where the foot hits the ground in a violent manner) may be seen in cases of posterior cord syndrome, and a broad-based gait in cases of spinal cord compression.



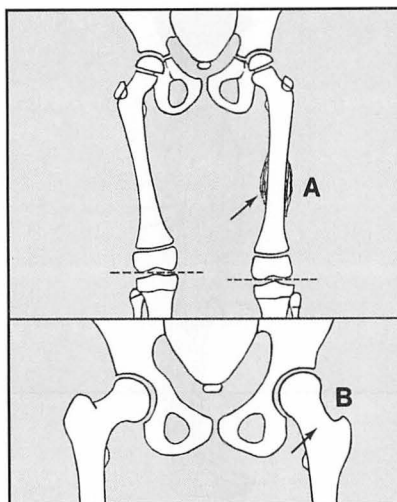
9.5. Shortening (1): It is important in the examination of the hip and the lower limb to determine the presence or absence of shortening. In *true shortening*, the affected limb is physically shorter than the other. This may be caused by pathology (A) above or proximal to the greater trochanter or (B) distal to the trochanters.



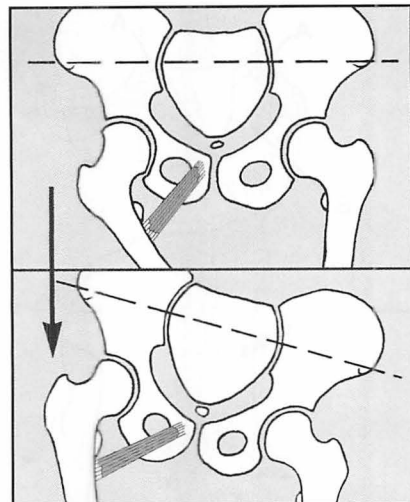
9.6. True shortening (2): True shortening from causes distal to the trochanters most frequently results from (A) old fractures of the tibia or (B) of the femur; (C) growth disturbance (e.g. from polio, bone or joint infections, epiphyseal trauma, or one of many hereditary bone diseases. (N) = normal side for comparison. (Note that in children, likely leg discrepancies at skeletal maturity may be predicted using a number of methods, including that of multiplier factors devised by Dror Paley et al.)



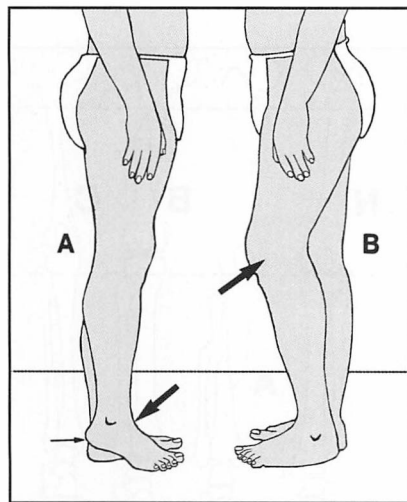
9.7. True shortening (3): Above the trochanter causes include (A) coxa vara (e.g. from femoral neck fractures, slipped upper femoral epiphysis, Perthes' disease, congenital coxa vara); (B) loss of articular cartilage (from infection, arthritis); (C) dislocation of the hip (e.g. secondary to developmental dislocation of the hip).



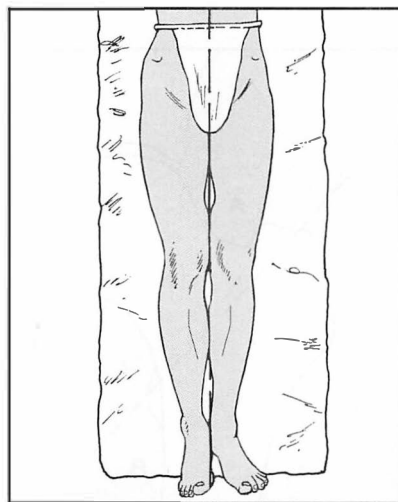
9.8. Shortening (4): Very rarely *lengthening of the other limb* gives relative true shortening. This may be due to (A) stimulation of bone growth from increased vascularity (e.g. after long bone fracture in children, or a bone tumour); (B) coxa valga (e.g. following polio).



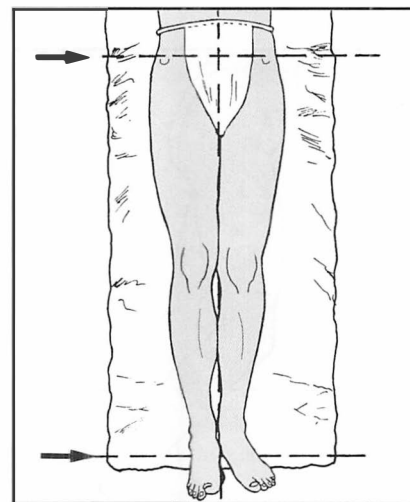
9.9. Shortening (5): In *apparent shortening* the limb is not altered in length, but appears short as a result of an adduction contracture of the hip, which has to be compensated for by tilting of the pelvis.



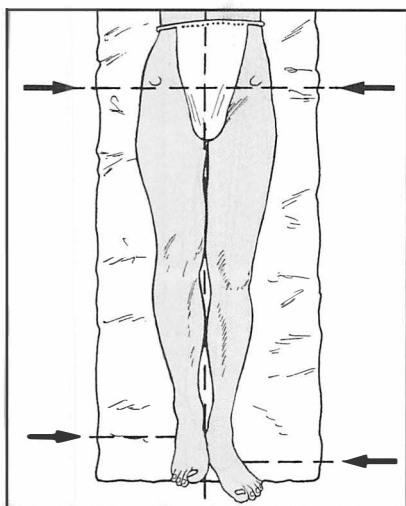
9.10. Shortening (6): Limb shortening may be compensated by (A) plantarflexion of the foot on the affected side, or by (B) flexion of the knee on the other side. Most frequently the discrepancy is countered by *pelvic tilting*. The latter may in turn be compensated for by the development of a lumbar scoliosis.



9.11. Shortening: examination (1): The patient should be adjusted to lie squarely on the couch, with the trunk and legs parallel to its edge. The position of the pelvis should be observed (by the position of the anterior superior iliac spines) and adjusted where possible.

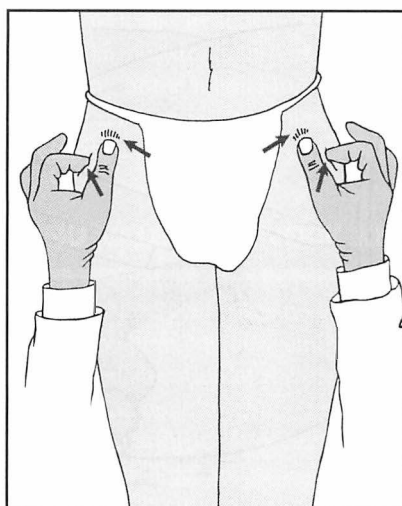


9.12. Shortening: examination (2): In the normal patient the heels should be level, and the plane of the anterior superior iliac spines at right-angles to the edge of the couch.



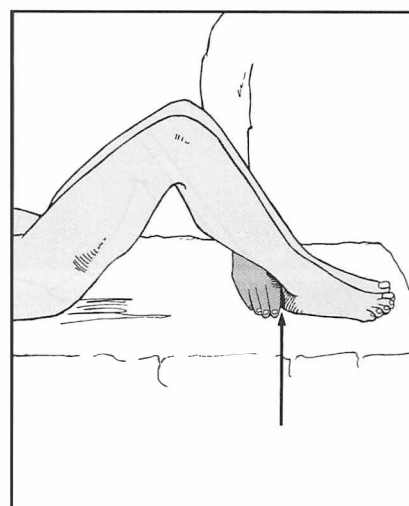
9.13. Shortening: examination (3):

Where there is significant true shortening the heels will not be level (the discrepancy is a guide to the amount of shortening) and the pelvis will not be tilted. The site and amount of shortening must now be further investigated.

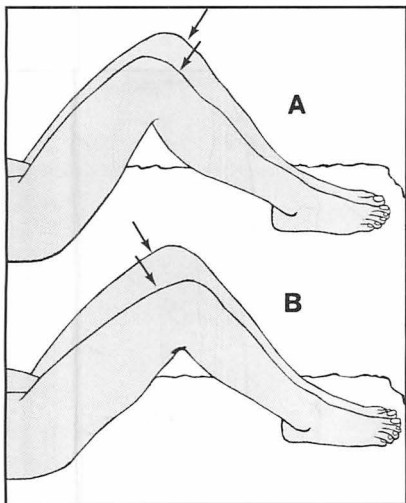


9.14. Shortening: examination (4):

Begin by hooking the thumbs under the anterior spines. Feel for the greater trochanters with the fingers. If the distance between the thumb and fingers is shorter on one side, this suggests that the pathology lies above the trochanters.

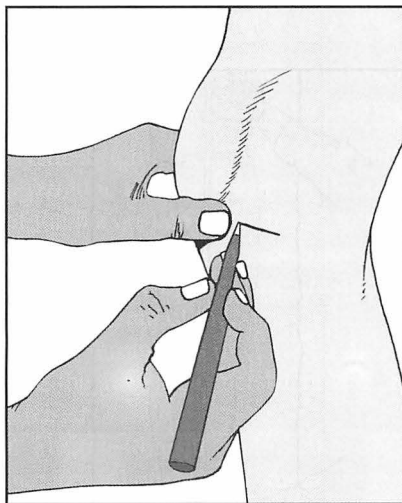


9.15. Shortening: examination (5): If in the last test there was no evidence of shortening above the trochanter, look for causes below the trochanter. Slightly flex both knees and hips, and place a hand behind the heels to check that you now have them squarely together.



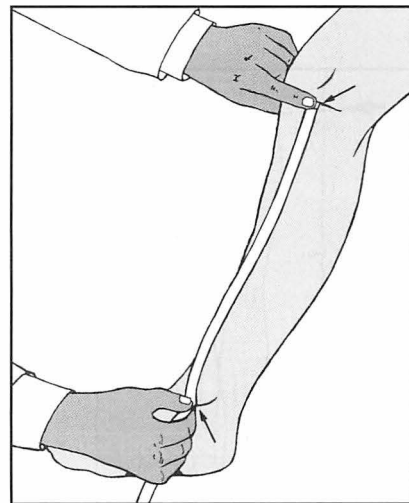9.16. Shortening: examination (6):

The position of the two knees should be compared. (A) This appearance suggests femoral shortening. (B) This appearance is suggestive of tibial shortening (in the diagram, the right side is as usual the site of the pathology).



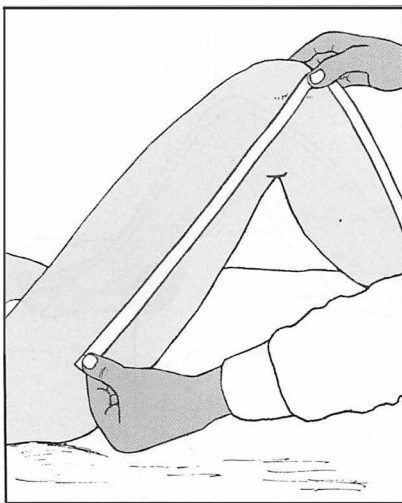
9.17. Shortening: examination (7):

Further confirmation of tibial shortening may be made by direct measurement. Flex one knee, and with the thumb locate the prominences of the femur and tibia, with the joint line lying between. This is best performed on the medial side of the joint. Now mark the joint line, and repeat on the other side.

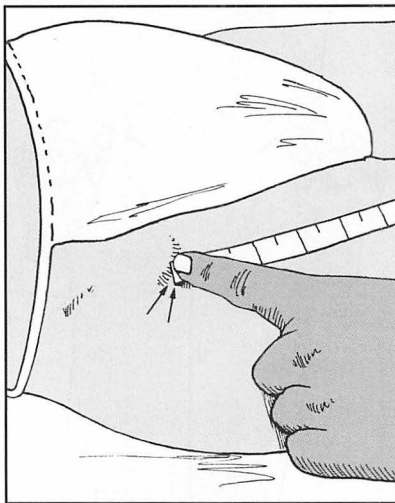


9.18. Shortening: examination (8):

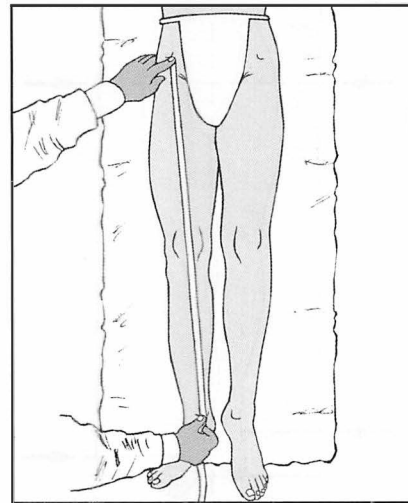
Now measure from the mark to the tip of the medial malleolus. Compare the two sides. Any difference indicates true tibial shortening. Note also any obvious tibial irregularity suggestive of old fracture.

**9.19. Shortening: examination (9):**

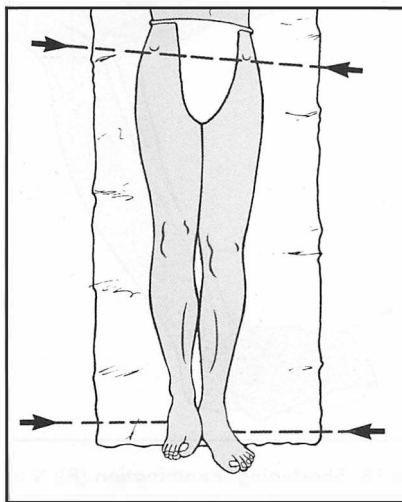
Measurement of femoral shaft shortening can only be attempted in the thin patient where the tip of the greater trochanter is easily palpable. Measure from the trochanter to the lateral joint line and compare the sides.

**9.20. Shortening: examination (10):**

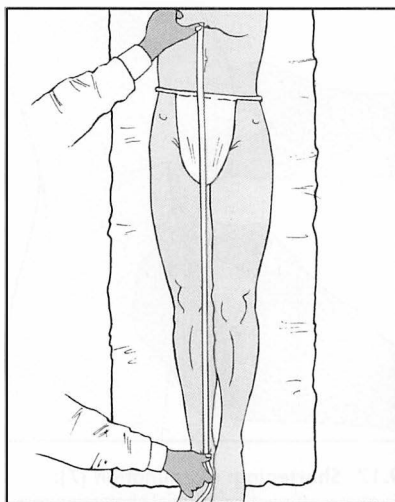
Measurement of total (true) leg shortening is the most valuable single assessment, although in itself it gives no indication of site. Begin by placing the metal end of the tape *over* the anterior spine; now press it backwards until it hooks *under* its inferior edge. In this way the end of the tape comes into firm contact with the iliac spine, and there is less chance of having difficulty in getting a reliable, fixed measuring point at this level.

**9.21. Shortening: examination (11):**

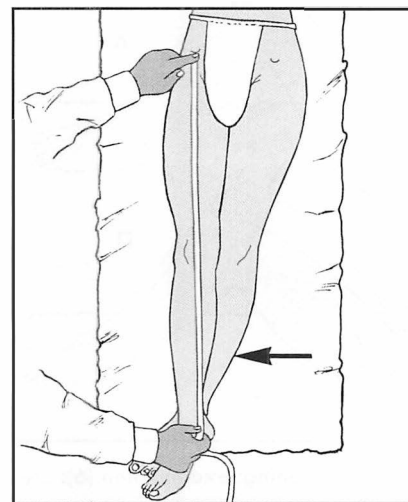
Now measure to the middle or inferior border of the medial malleolus. Compare the sides, and always repeat the measurements until consistency is obtained. Deformity of the pelvis (which is rare) may sometimes lead to errors in assessment.

**9.22. Shortening: examination (12):**

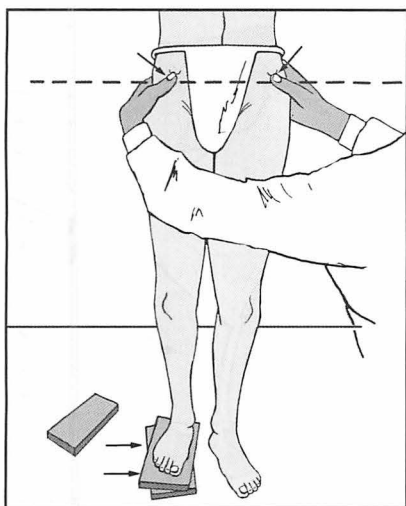
When the patient is carefully positioned on the examination couch, and the pelvis is obviously tilted, try to correct this. If it cannot be levelled, then expect to find some apparent shortening of the limb; the discrepancy between the heels will give a measure of this. (Note, however, that as well as apparent shortening there may be some additional true shortening, which should be assessed by direct limb measurement as just described.)

**9.23. Shortening: examination (13):**

Apparent shortening may also be assessed by comparing the distances between the xiphisternum and each medial malleolus.

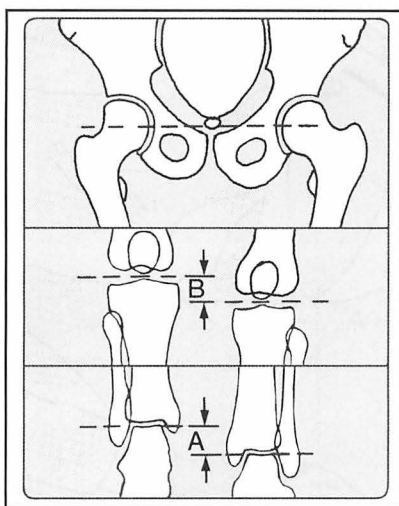
**9.24. Shortening: examination (14):**

When there is an adduction deformity of the hip, and the leg lengths are being measured to assess any accompanying true shortening, the good leg should be adducted by the same amount before commencing measurement between the anterior spines and malleoli.

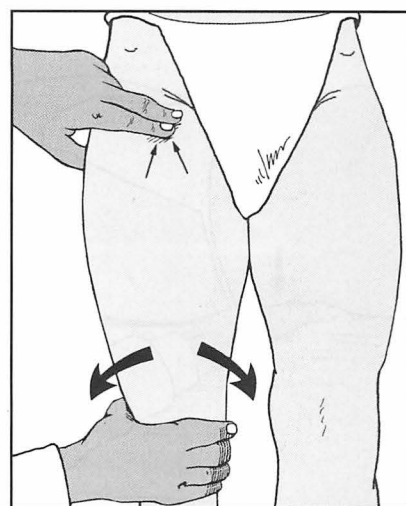


9.25. Shortening: examination (15):

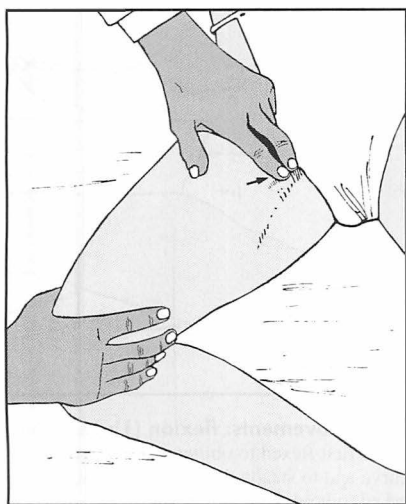
True leg shortening may also be measured by blocking up the short leg until both anterior superior iliac spines and the iliac crests lie horizontally, and the natal cleft is vertical; a further check that the pelvis is level is to see that the posterior iliac spines remain horizontal when the patient flexes forwards.



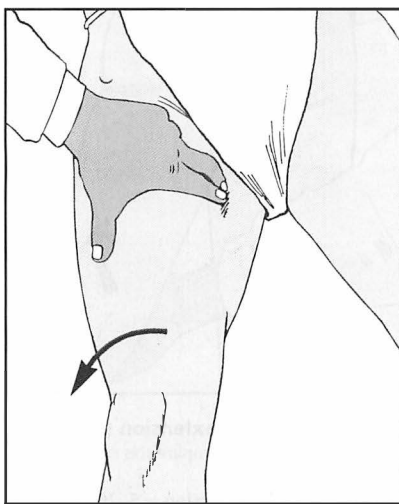
9.26. Shortening: examination (16): In the difficult case, sequential radiographs of the hips, knees and ankles, taken on a single plate without moving the patient, afford accurate comparison of the sides. For example, (A) indicates overall shortening, (B) indicates femoral shortening. (Note that in the older patient a discrepancy of 3–4 cm leads on walking to an increase in heart rate, ventilation and muscle activity which may seriously limit activity, especially if there is already some cardiac, pulmonary or neuromuscular impairment.)



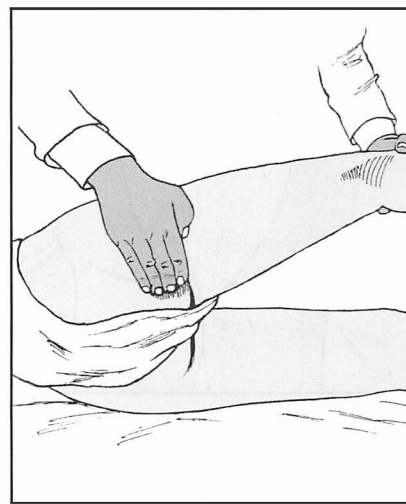
9.27. Palpation (1): Place the fingers over the head of the femur below the inguinal ligament, lateral to the femoral artery. Note any tenderness. Now rotate the leg medially and laterally. Crepitus arising in the hip joint may be detected in this way.



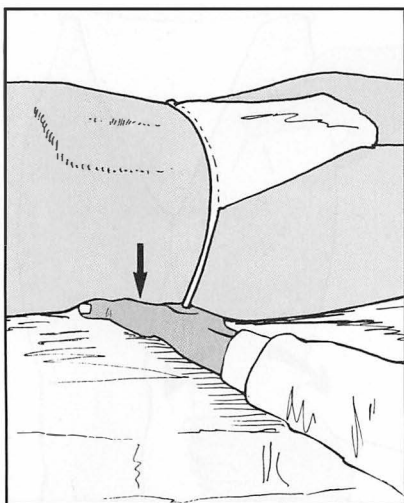
9.28. Palpation (2): Palpate the origin of adductor longus. Tenderness occurs here in sports injuries (strain of adductor longus) and in patients developing adductor contractures in osteoarthritis of the hip.



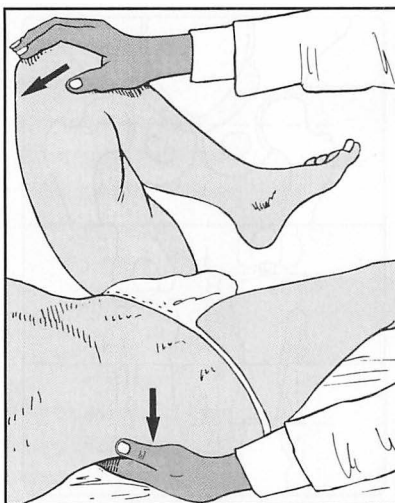
9.29. Palpation (3): Externally rotate the leg and palpate the lesser trochanter. Tenderness occurs here in strains of the iliopsoas as a result of athletic injuries.



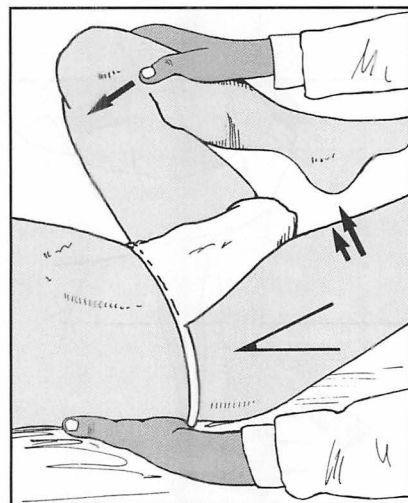
9.30. Palpation (4): Palpate the region of the ischial tuberosity looking for tenderness. Strain of the hamstring origin occurs as a result of athletic activities, especially in children. Less commonly athletic injuries may affect the anterior superior and inferior spines.




9.31. Movements: extension (1): Place a hand behind the lumbar spine so that you can determine whether in the spine at rest there is any increase in lumbar lordosis, and later on in the course of the examination, whether this has been obliterated.



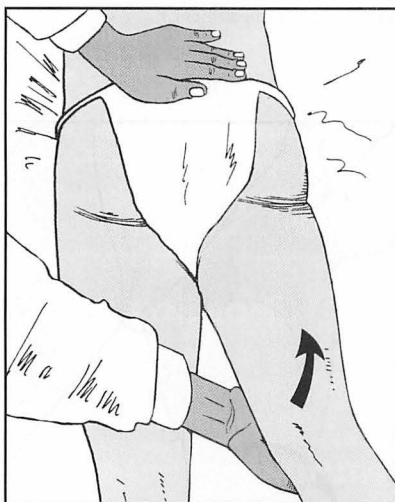
9.32. Movements: extension (2): Now flex the *good* hip fully, observing with the hand that the lumbar curvature is fully obliterated.



9.33. Movements: extension (3): If the hip being examined rises from the couch, this indicates loss of extension in that hip (also described as a fixed flexion deformity of the hip). Any loss should be measured and recorded. This test is usually referred to as *Thomas's test*.

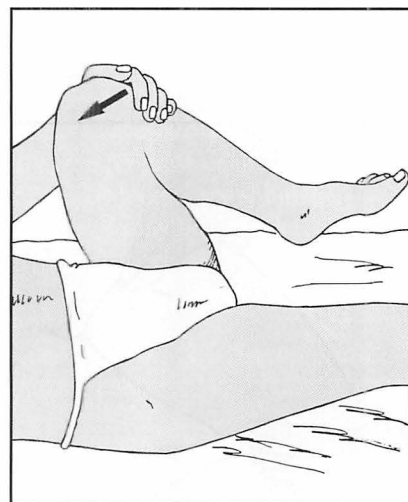


9.34. Movements: extension (4): To check smaller losses of extension, especially when the other hip is normal, turn the patient over on to his face and steady the pelvis with one hand.

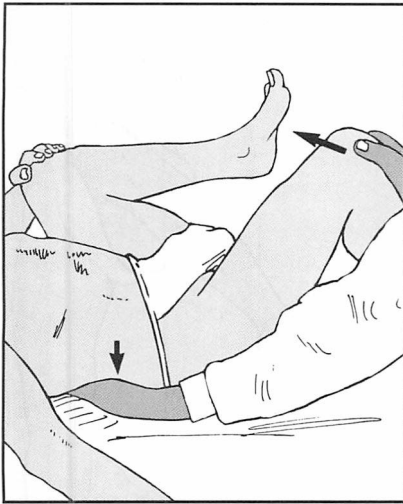


9.35. Movements: extension (5): Lift each leg in turn and compare the range of movements.

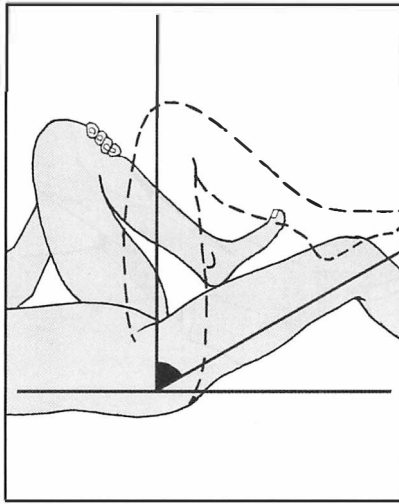
Normal range of extension = 5–20°.
A loss affecting extension only is often the first detectable sign of an effusion in the hip joint.



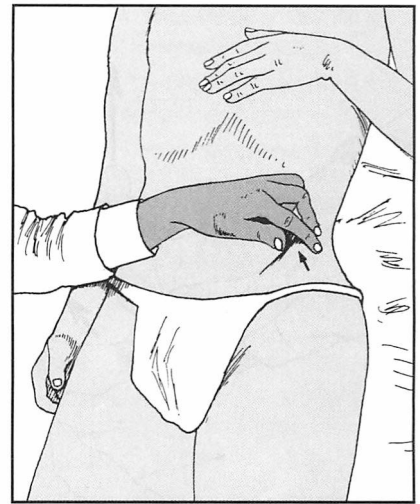
9.36. Movements: flexion (1): The *good* hip is first flexed to obliterate the lumbar curve and to steady the pelvis. The patient is asked to hold the leg in this position.



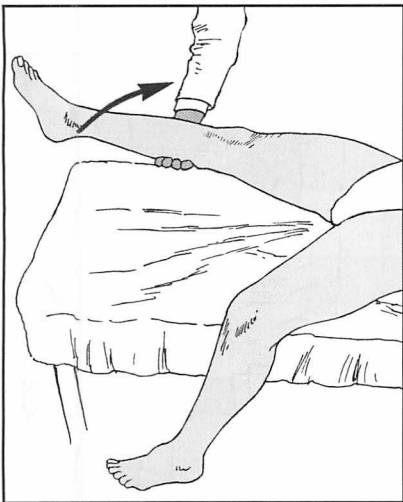
9.37. Movements: flexion (2): The hip is then flexed, using a hand to check that no further pelvic movement occurs. Note the range of movement.
Normal range of flexion = 120°.



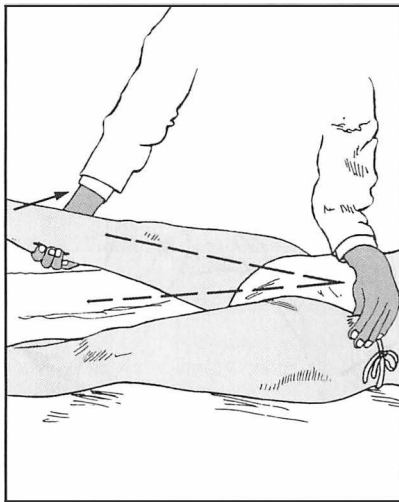
9.38. Movements: flexion (3): The range of flexion may be recorded in this example as 'Flexion (R) hip: 30–90°', or 'Fixed flexion deformity of 30°, and hip flexes to 90°'. Flexion may also be tested with the patient lying on his side.



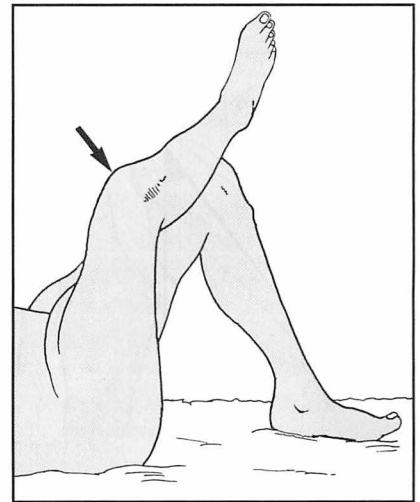
9.39. Movements: abduction (1): A false impression of hip movement may be gained if the pelvis tilts during the examination, so first grasp the opposite anterior superior iliac spine with the fingers and thumb, and anchor the other spine with the forearm.



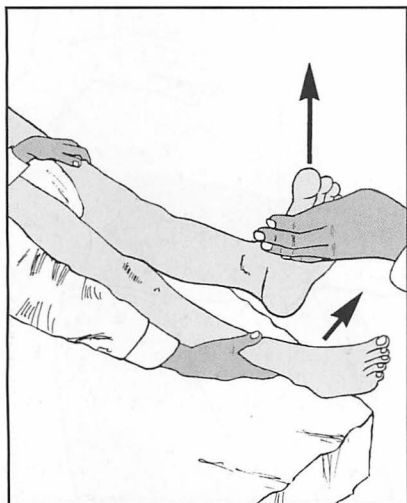
9.40. Movements: abduction (2): An alternative way of fixing the pelvis is to flex the other leg over the edge of the couch and check that the pelvis does not move by holding the anterior superior iliac spine on the side being examined.



9.41. Movements: abduction (3): Now, having fixed the pelvis, move the leg laterally and note the range achieved.
Normal range of abduction = 40°.
Abduction may also be tested from a starting position of 90° hip flexion (see also below). This is of particular value in suspected osteoarthritis of the hip or congenital dislocation.

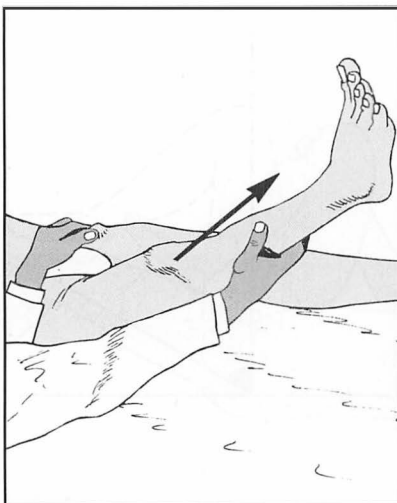


9.42. Patrick's test: Basically, this is a variation of abducting the hip from a position of 90° flexion. Pain during the manoeuvre is regarded as being the very first sign of osteoarthritis in a hip. To perform (on the right), flex both hips and knees, place the right foot on the left knee and gently press down on the right knee. This is also known as the faber sign (flexion, abduction, external rotation).

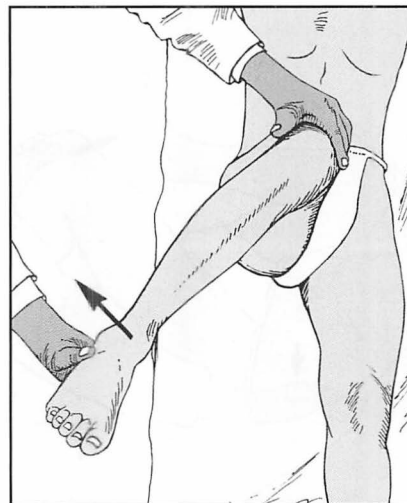

9.43. Movements: adduction (1): Ideally an assistant should lift the good leg out of the way to allow the affected leg to be adducted while in full extension.

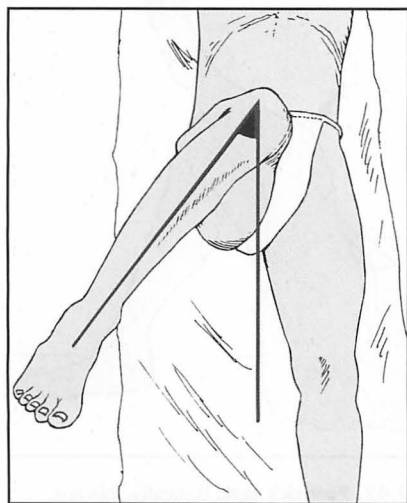
Normal range of adduction = 25°.



9.44. Movements: adduction (2): If an assistant is not available, cross the leg being examined over the other. This brings the leg being examined into slight flexion, but is sufficiently accurate under most circumstances. If the hip is normal, the legs should cross about midhigh. Adduction may also be tested from a starting position of 90° hip flexion.



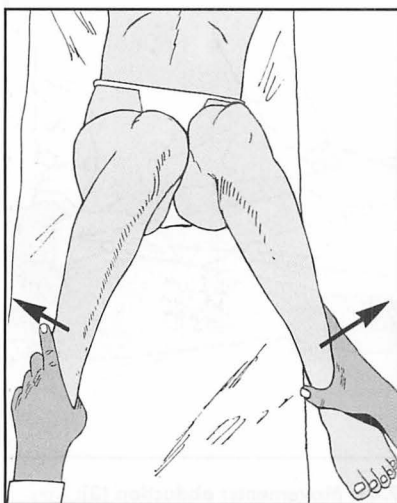9.45. Movements: internal rotation at 90° flexion (1): Steady the flexed hip by holding the knee with one hand, and move the foot laterally to produce internal rotation of the hip. Note that this is a never-ending source of confusion; be sure that this is clear in your own mind. Although the *foot* moves laterally (or externally), the *hip* rotates internally (or medially).



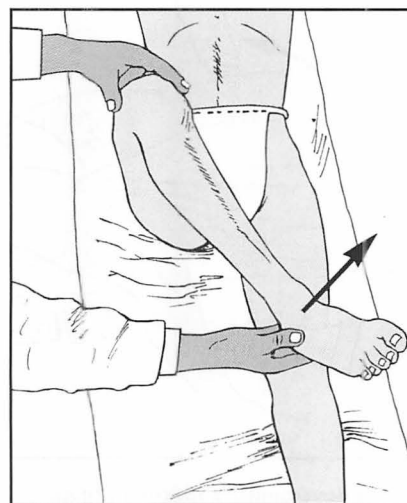
9.46. Movements: internal rotation at 90° flexion (2): Measure the range of internal rotation by comparing the position of the leg and the midline.

Normal range of internal rotation at 90° flexion = 45°.

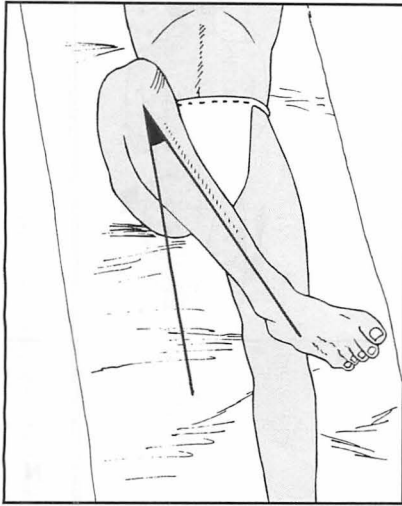Compare the sides. Loss of internal rotation is common in most hip pathologies.



9.47. Movements: internal rotation at 90° flexion (3): A sensitive comparison of the sides may be made by asking the patient to hold the knees together while you move both feet laterally.

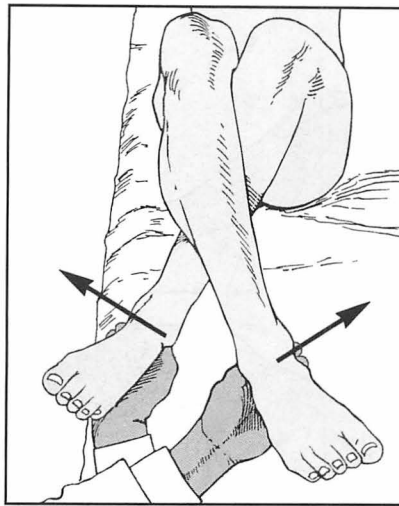


9.48. Movements: external rotation at 90° flexion (1): The position of the hip is the same as for testing internal rotation, but in this case the foot is moved medially.




9.49. Movements: external rotation at 90° flexion (2): Measure external rotation in the same general way.
Normal range of external rotation at 90° flexion = 45°.

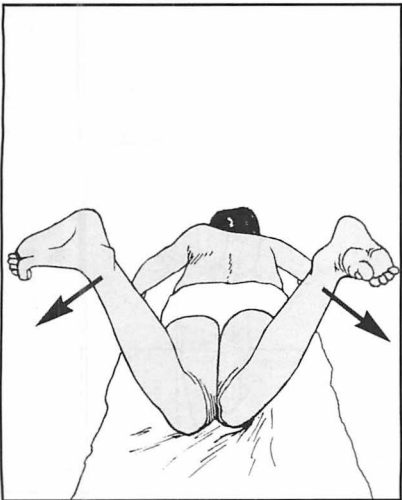External rotation becomes limited in most arthritic conditions of the hip.



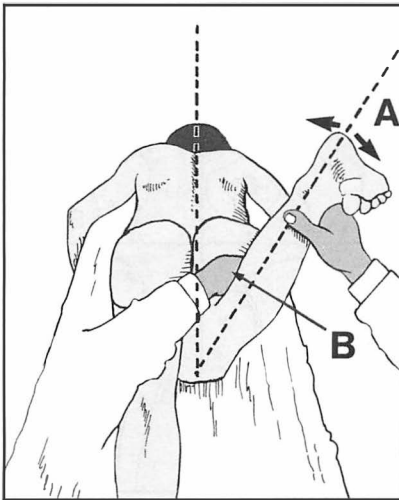
9.50. Movements: external rotation at 90° flexion (3): Comparison between the sides may be made by crossing one leg over the other.



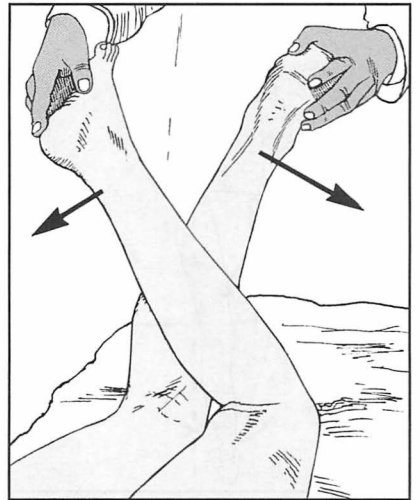
9.51. Movements: rotation in extension (1): For a rough comparison of the sides, roll each leg medially and laterally, observing and allowing, however, for any play at the knee.



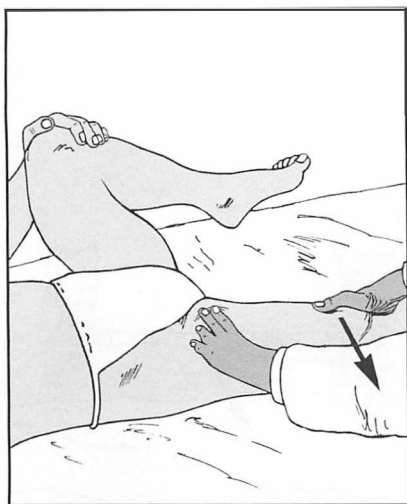9.52. Movements: internal rotation in extension: For a more accurate assessment the patient should be prone, with the knees flexed. The two sides can easily be compared and measurements taken.
Normal range of internal rotation in extension = 35°.



9.53. Anteversion of the femoral neck: An assessment of anteversion may be made when the patient is in the same position. Hold the leg with one hand and rock it from side to side (A) while simultaneously feeling the prominence of the greater trochanter with the other (B). When the trochanter is facing truly laterally, anteversion is equal to the angle between the leg and the vertical. This is the most accurate clinical method of assessing anteversion.

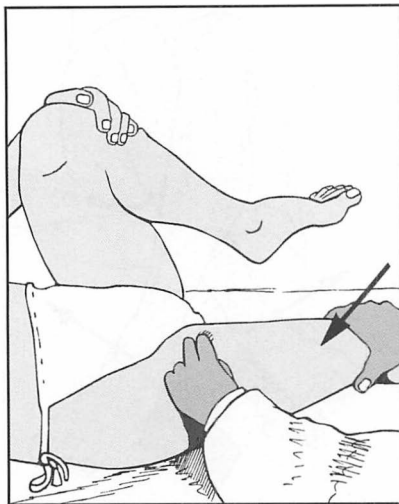


9.54. Movements: external rotation in extension: Comparison and measurement may be made in the same way.
Normal range of external rotation in extension = 45°.



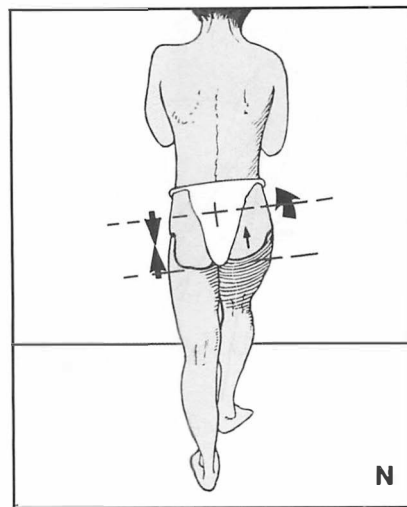
9.55. Movements: testing for hip fusion

(1): When there is doubt regarding the solidity of a hip fusion, it is sometimes helpful to test for protective muscle contraction. Flex the good hip and knee. Feel for involuntary adductor contracture while suddenly attempting to abduct the leg.

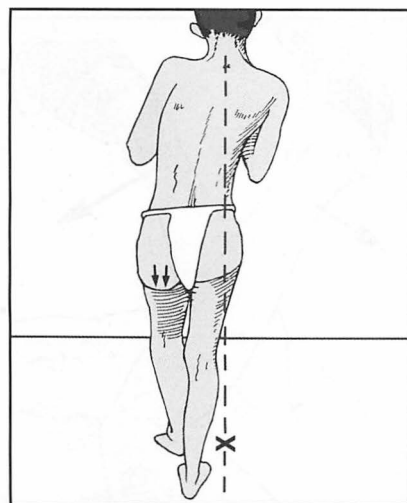


9.56. Movements: testing for hip fusion

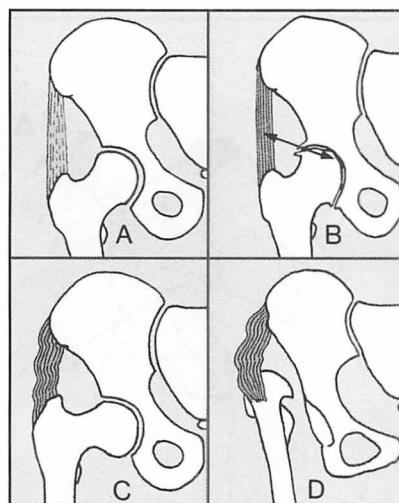
(2): Repeat the test, this time feeling for flexor (iliopsoas) contraction while making a sudden gentle attempt to extend the hip.



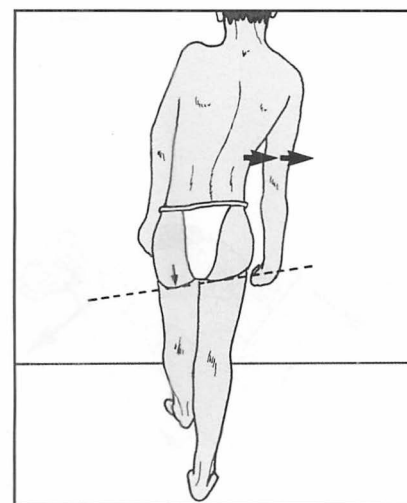
9.57. Trendelenburg's test (1): When standing on one leg (here the left), the centre of gravity (at S2) is brought over the stance foot by the hip abductors (gluteus medius and minimus). This tilts the pelvis and normally elevates the buttock of the non-stance side. The patient should be able to produce a greater pelvic tilt (by being asked to lift the side higher) and hold the position for 30 seconds.



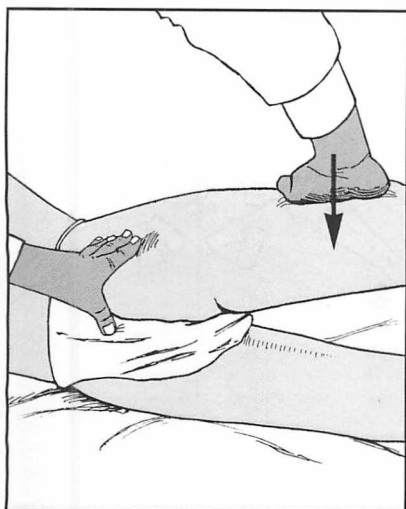9.58. Trendelenburg's test (2): Ask the patient to stand on the affected side: any support (stick or hand) must be on the same side. Now ask him to raise the non-stance leg further. Prevent excessive trunk movements (a vertical dropped from C7 should not fall beyond the foot). If the pelvis drops below the horizontal or cannot be held steady for 30 seconds, the test is positive. It is not valid below age 4: pain, poor cooperation or bad balance may give a false positive.



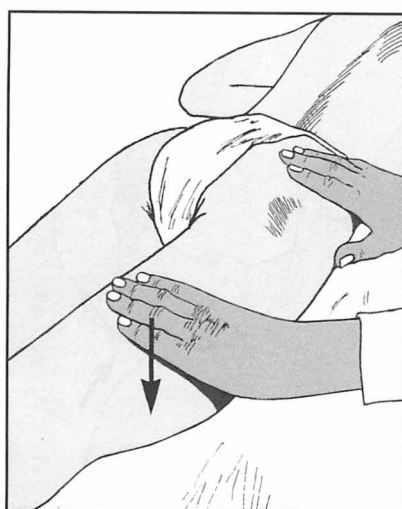
9.59. Trendelenburg's test (3): The test is positive as a result of (A) gluteal paralysis or weakness (e.g. from polio, muscle-wasting disease); (B) gluteal inhibition (e.g. from pain arising in the hip joint); (C) from gluteal inefficiency from coxa vara; or (D) developmental dislocation of the hip (DDH). Nevertheless, false positives have been recorded in about 10% of patients.



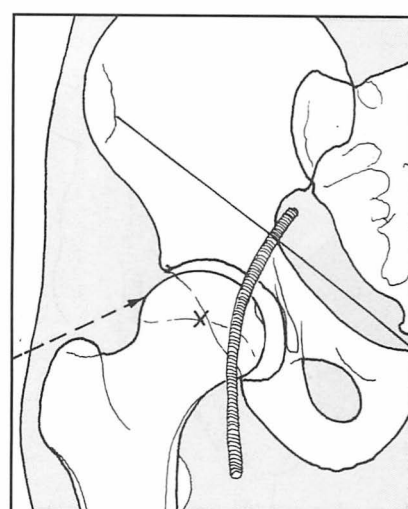
9.60. Duchenne sign: Note whether the patient, when walking, lurches to one side. If present, this is because the patient is trying to reduce pain by shifting his body weight over the hip. This is often also somewhat confusingly referred to as an abductor or Trendelenburg lurch. It is often associated with a positive Trendelenburg sign (ill), but not invariably.



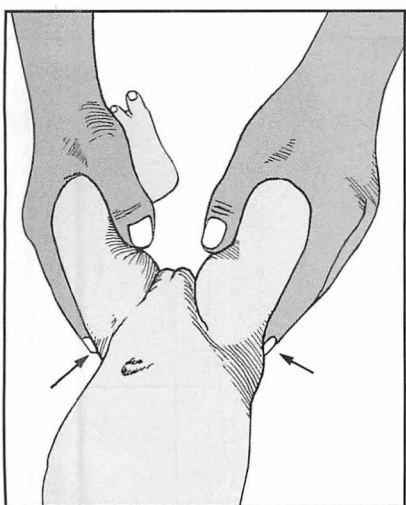
9.61. Gluteal muscles: Test the power of the hip abductors with the patient lying on his side, attempting to abduct the leg against resistance.



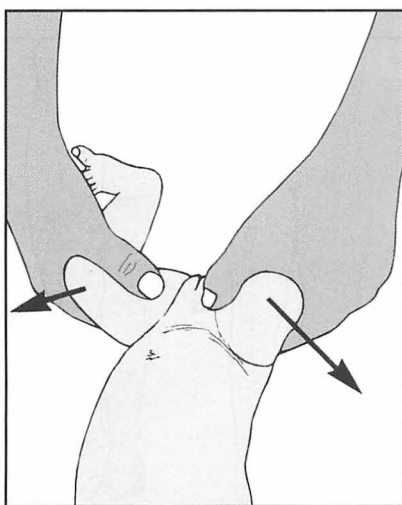
9.62. Gluteal muscles: Test the power in gluteus maximus by asking the patient to extend the hip against resistance, at the same time feeling the tone in the contracting muscle.



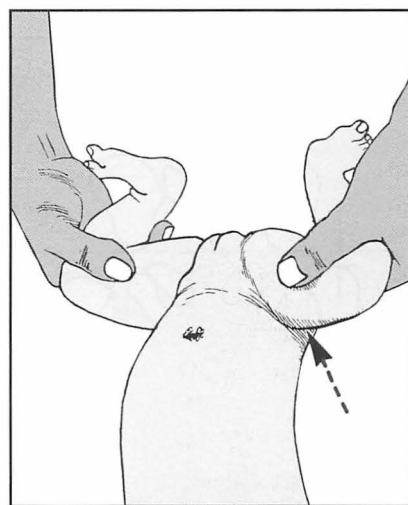
9.63. Aspiration: The hip may be aspirated by inserting a needle above the trochanter, allowing for femoral neck anteversion. Alternatively, a needle may be passed into the joint from in front, a little below the inguinal ligament and lateral to the femoral artery.



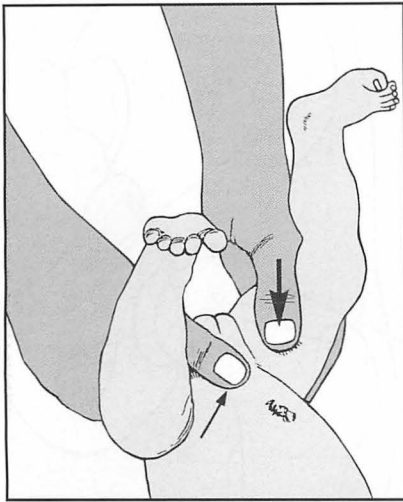
9.64. Ortolani's test (1): To be of any value the examination must be carried out on a relaxed child, preferably after feeding. Flex the knees and encircle them with the hands so that the thumbs lie along the medial sides of the thighs and the fingers over the trochanters.



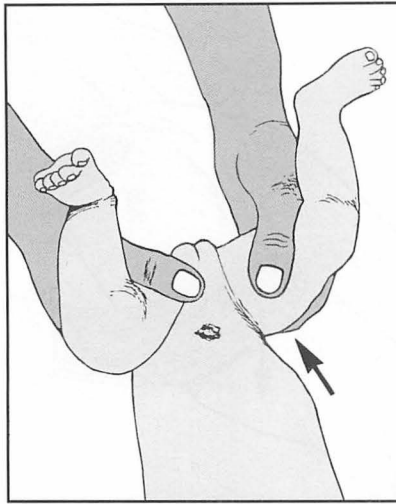
9.65. Ortolani's test (2): Now flex the hips to a right-angle and, starting from a position where the thumbs are touching, abduct the hips smoothly and gently.



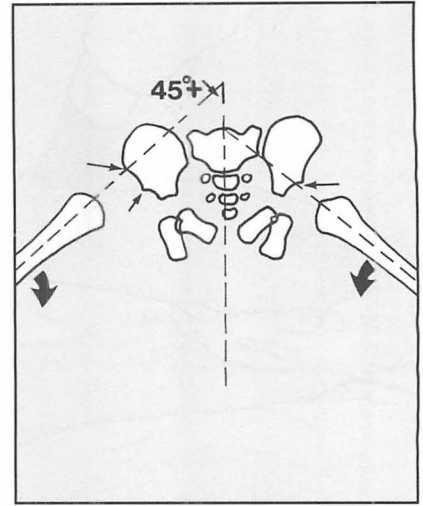
9.66. Ortolani's test (3): If a hip is dislocated, as full abduction is approached the femoral head will be felt slipping into the acetabulum. An audible click may accompany the displacement, but in no way must this be considered an essential element of the test. Note that restriction of abduction may be pathological, and represent an irreducible dislocation. A positive Ortolani test is indicative of neonatal instability of the hip (NIH), and is usually an indication for splintage.



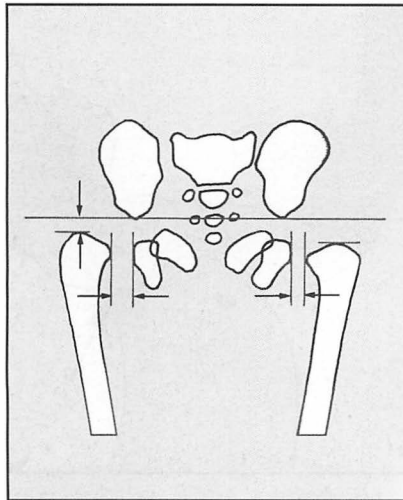
9.67. Barlow's provocative test (1): If the Ortolani test is negative the hip may nevertheless be unstable. Fix the pelvis between symphysis and sacrum with one hand. With the thumb of the other attempt to dislocate the hip by gentle but firm backward pressure. Check both sides.



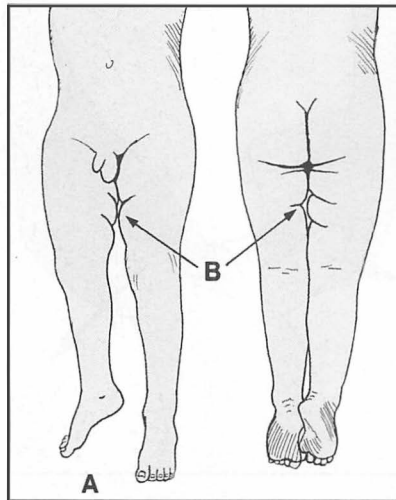
9.68. Barlow's test (2): If the head of the femur is felt to sublux backwards, its reduction should be achieved by forward finger pressure or wider abduction. The movement of reduction should also be appreciated with the fingers. If Barlow's test is positive (and Ortolani's negative), recheck at weekly intervals. Instability persisting for more than 3 weeks is an indication for splintage, or for further investigation with ultrasound and X-ray.



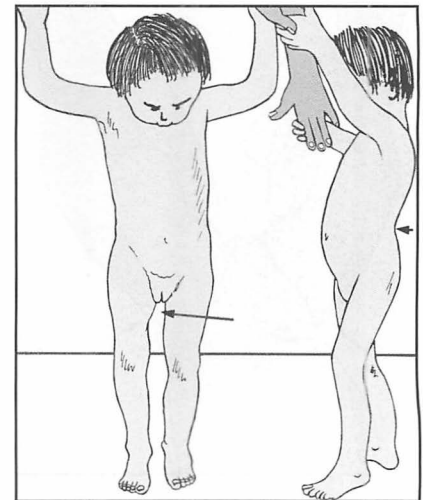
9.69. Radiographic examination of the neonate: (a) *van Rosen method:* An AP view should be taken with the hips in at least 45° abduction and full internal rotation. A line projected along the line of the femur in the normal hip should strike the acetabulum and, in a case of dislocation, the region of the anterior superior spine. Note: To avoid radiation, this somewhat unreliable investigation should be done only where there is still uncertainty after clinical and ultrasound testing.



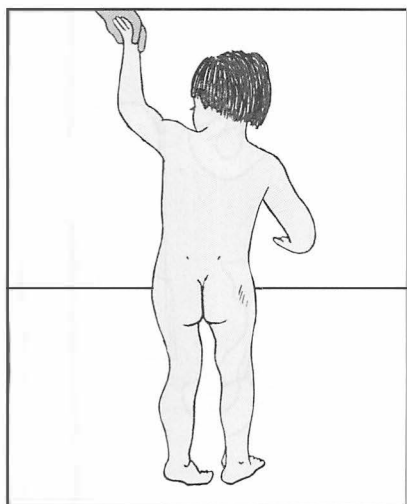
9.70. Radiographic examination: (b) *Edinburgh method:* An AP film is taken with the child's legs held parallel, with slight traction and no external rotation. Centre the beam at a standard distance of 100 cm. Measure the gap between the most medial part of the femur and the lateral edge of the ischium. This is normally 4 mm; over 5 mm is suspicious; 6 mm is regarded as diagnostic of DDH. Proximal migration can also be measured in the same film.



9.71. Developmental dislocation of the hip (DDH): The older child (1): Appearance: (A) The affected leg in a case of unilateral dislocation of the hip may appear slightly shorter, and lie in external rotation. (B) There may be asymmetry of the skin folds in the thigh, although this sign is of limited reliability.




9.72. Developmental dislocation of the hip (DDH): The older child (2): If both hips are involved there is usually widening of the perineum owing to the hip displacement. If the child has been walking, there will be a compensatory increase in lumbar lordosis.



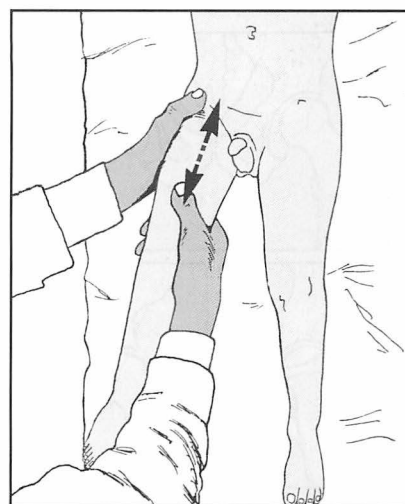9.73. Developmental dislocation of the hip (DDH): The older child (3):

Trendelenburg's test will be positive and the gait will be abnormal, with excessive shoulder sway. In unilateral cases the child will dip on the affected side; in bilateral cases the child will have a waddling gait.



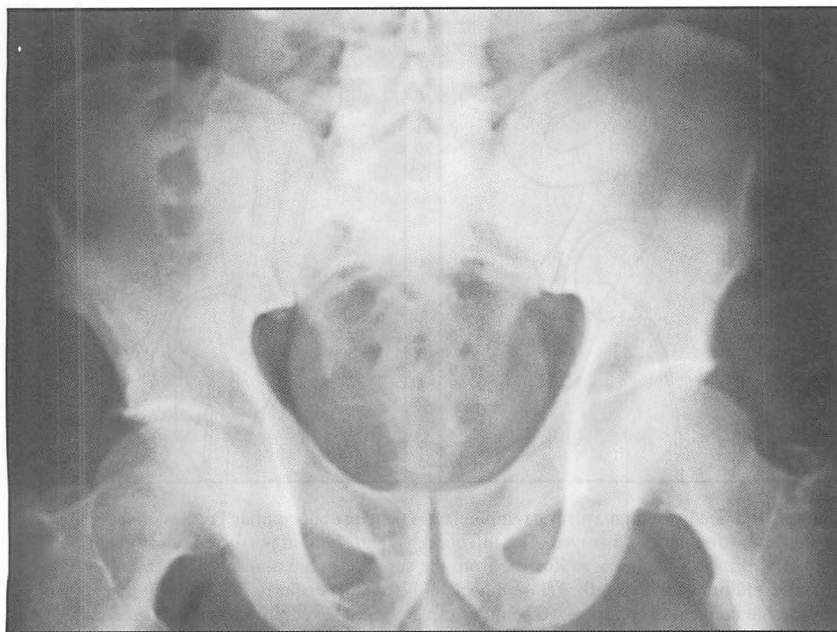
9.74. Developmental dislocation of the hip (DDH): The older child (4):

Test the range of abduction from a position of 90° flexion of the hip. In DDH abduction is restricted in this position, and of course is most obvious in the unilateral case. A 20° difference between the sides, or less than 60° of abduction, is regarded as highly significant, and further investigation is essential. The test should be performed routinely at 3 months, especially in a high-risk case.

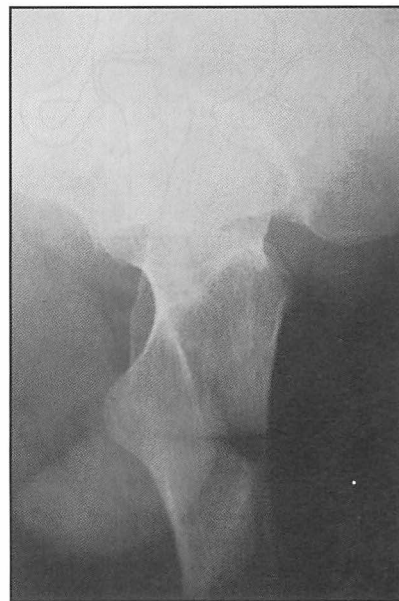

9.75. Developmental dislocation of the hip (DDH): The older child (5):

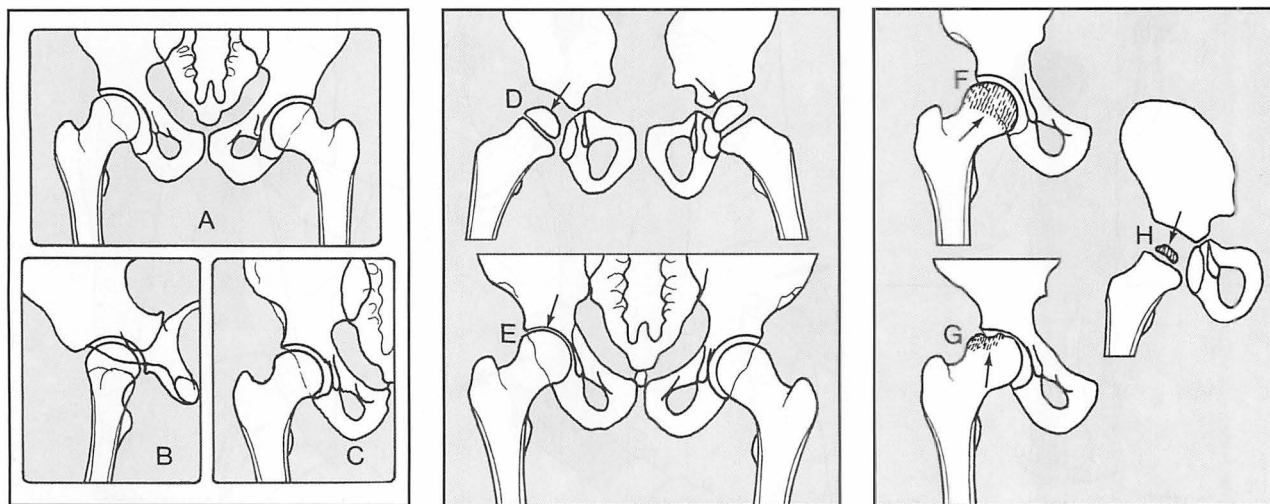
Attempt to elicit telescoping in the affected limb. Steady the pelvis with one hand, and push and pull along the axis of the femur with the other. Abnormal excursion of the limb is suggestive of DDH. Always compare the sides.



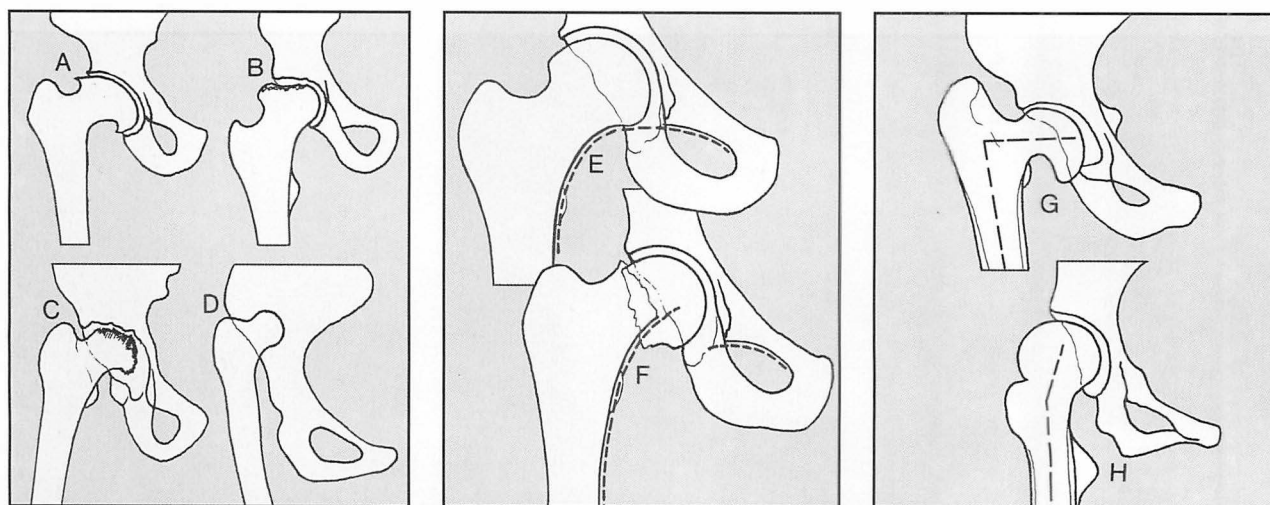
9.76. Radiographs: Normal anteroposterior projection of the pelvis in the adult.



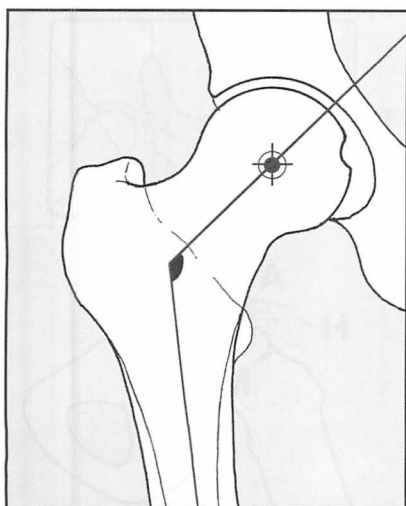
9.77. Radiographs: Normal lateral hip in the adult.



9.78. Radiographs: An anteroposterior view showing both hips (A) is the most useful single screening film, as it allows both sides to be compared. If the joint is strongly suspect, an additional lateral projection (B) and an anteroposterior (C), centred on the suspect hip, are essential. Note first in the films any *disturbance of bone texture* (e.g. in Paget's disease, osteoporosis, tumour). Now note the *joint space* (which indicates the depth of articular cartilage and interposing fluid), which may be (D) increased in Perthes' disease, synovitis and infection, and (E) decreased in the later stages of infection and arthritis. Note the relative *density* of the femoral head, which may be *decreased*, e.g. in rheumatoid arthritis, infection and osteoporosis, and *increased* in avascular necrosis (F), segmental avascular necrosis (G) and Perthes' disease (H).



9.79. Radiographs ctd: Now note the *shape* of the femoral head, which may, for example, be (A) buffer-shaped after Perthes' disease, (B) flattened after avascular necrosis (total or segmental), (C) irregular or destroyed after infection, (D) atrophic in persistent developmental dislocation of the hip. Note *Shenton's line*, which normally forms a smooth curve flowing from the superior pubic ramus to the femoral neck (E). Compare the sides if possible. Distortion occurs in many conditions involving the femoral neck and head, particularly fractures (F) and subluxations. Note the *neck-shaft angle*. This is *decreased* in congenital coxa vara (G), and coxa vara secondary to rickets, Paget's disease, osteomalacia, fracture etc. It is *increased* in coxa valga secondary to polio (H) and other neurological disturbances.

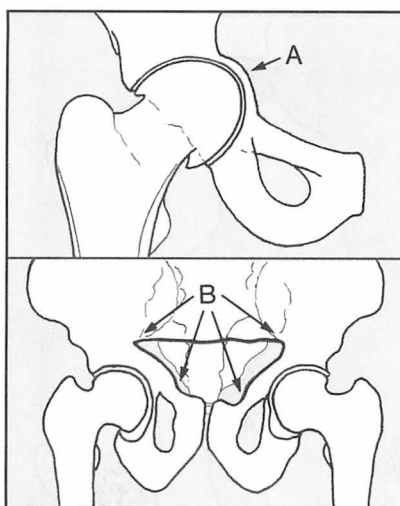


9.80. The neck-shaft angle may be measured from lines drawn through the shaft and along the centre of the neck into the centre of the head.

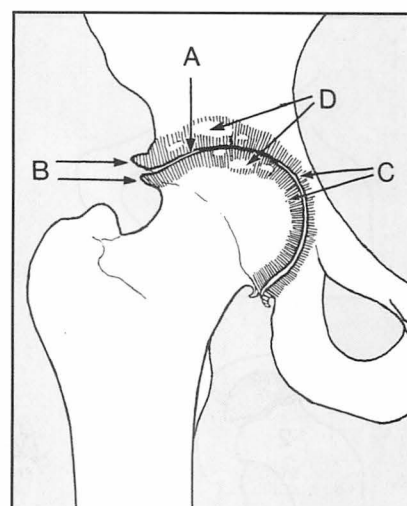
Normal neck-shaft angle in males = 128°.

Normal neck-shaft angle in females = 127°.

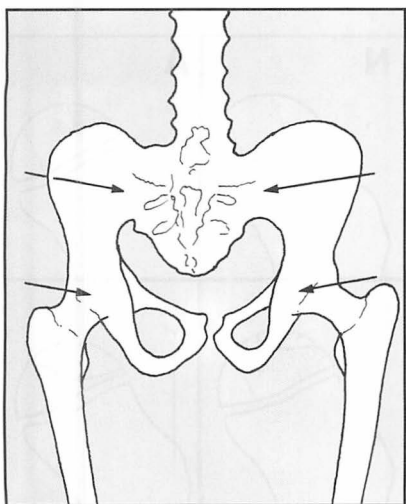
The centre of the head may be easily found with the aid of an orthopaedic rule or similar transparent drawing template inscribed with concentric circles of different radii.



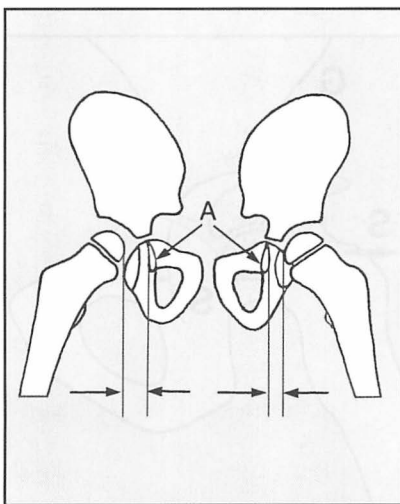
9.81. Pelvic distortion: This may be localized and of the pattern found in protrusio acetabuli (A), which is often hereditary and frequently associated with osteoarthritis; or it may be generalized (B), leading to deformity of the pelvic inlet (triradiate pelvis): this is found in osteomalacia and other diseases accompanied by bone softening, such as rickets and Paget's disease.



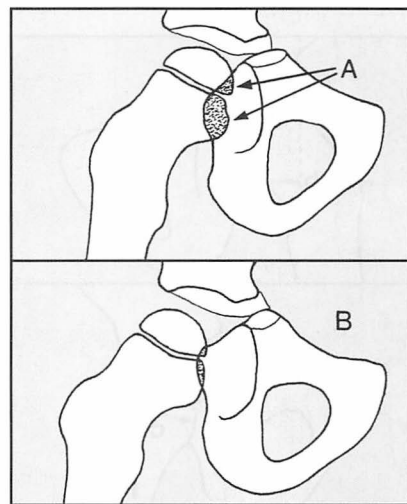
9.82. Osteoarthritis: Note the presence of any of the changes commonly seen in osteoarthritis, such as (A) joint space narrowing, (B) marginal osteophytes, (C) marginal sclerosis, (D) cystic changes in the head of the femur and in the acetabulum.



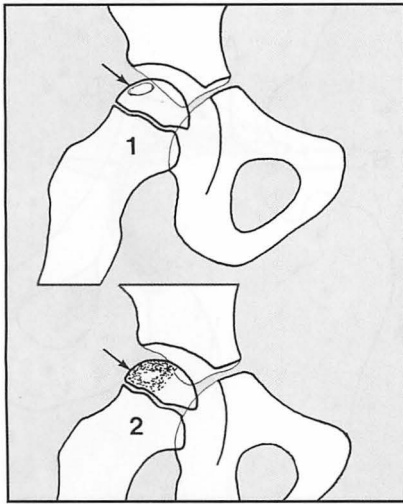
9.83. Complete obliteration of the hip joint (bony ankylosis) is seen in ankylosing spondylitis (where there is invariably involvement of the sacroiliac joints). It is also seen as a late result of tuberculous and other infections, and after surgical fusion.



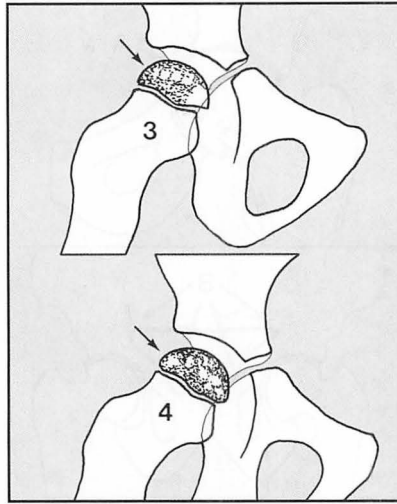
9.84. Perthes' disease (1): The earliest radiographic sign is an increase in joint space. (Note, however, that this is also seen in synovitis of the hip and in infective arthritis). Minor degrees of joint space widening may be detected by measuring the distance between (A) 'the tear drop' and the capital epiphysis on both sides.



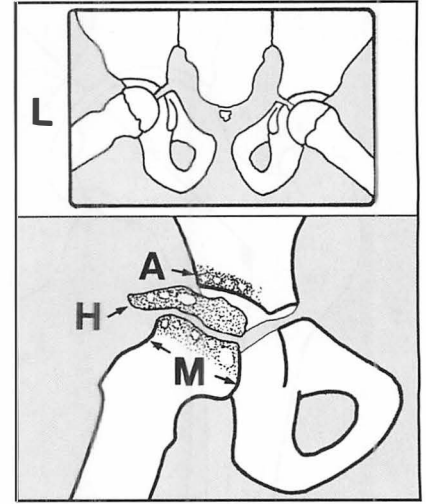
9.85. Perthes' disease (2): If the 'tear drop' (formed by the anterior acetabular floor) is not clear, note (A) the overlap shadows of the head and neck on the acetabulum, comparing one hip with the other. Alteration (B) occurs in Perthes' disease, synovitis and infection.



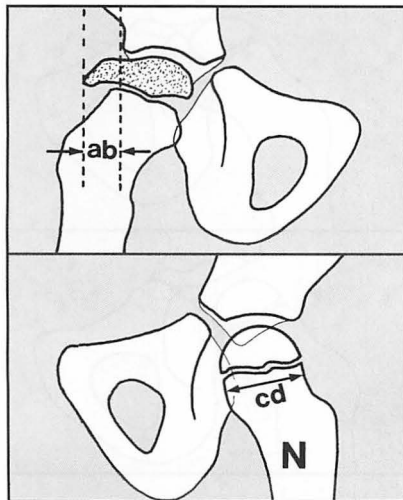
9.86. Perthes' disease (4): Catterall Grading (a): This is the commonest method used to assess the severity of the bone changes when they appear. *Grade 1:* Cyst formation occurs in the anterolateral aspect of the capital epiphysis. Revascularization may be completed without bone collapse, and the prognosis without treatment is good. *Grade 2:* A little more of the head is involved, and bony collapse is inevitable.



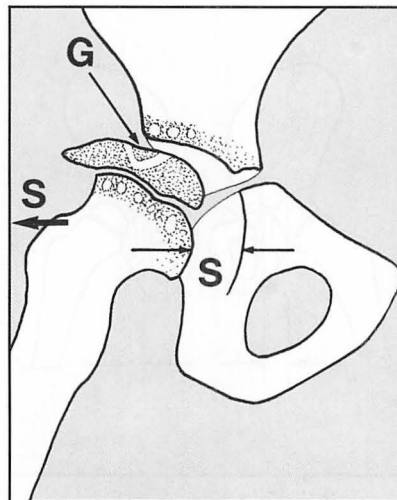
9.87. Perthes' disease (5): Catterall grading (b): *Grade 3:* Most of the head is involved. *Grade 4:* The whole head is affected. Bony collapse is inevitable in grades 3 and 4, and the prognosis is consequently poorer.



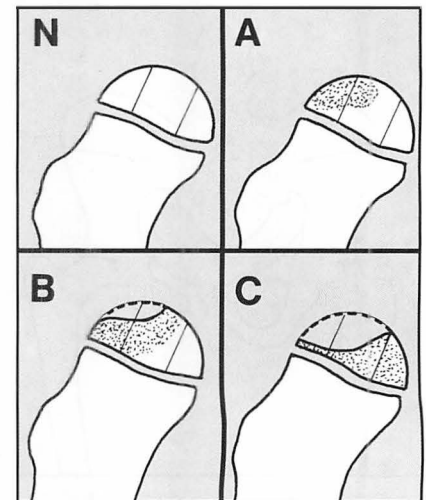
9.88. Perthes' disease (6): The so-called 'frog' lateral (Loewenstein projection, (L)) is routine in assessing these cases. Apart from the cystic changes that appear in the capital epiphysis, the acetabulum may be similarly affected (A); cystic changes may also occur in the metaphysis, which may widen (M). The femoral head may flatten and extrude laterally (H). MRI scanning allows more accurate grading.



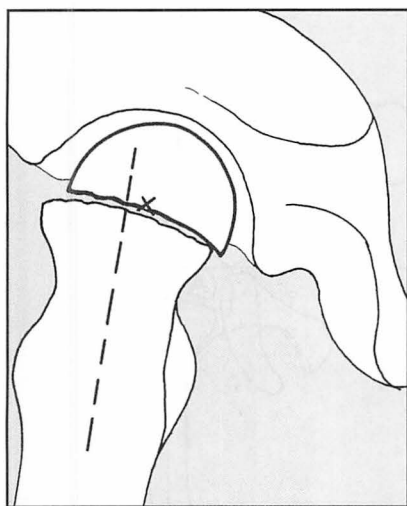
9.89. Perthes' disease (7): Lateral extrusion may be expressed as a percentage of the diameter of the metaphysis on the normal side (N): if $ab/cd \times 100 > 20\%$, then the prognosis is poor. An accurate assessment of the amount of avascular bone may be made by radionuclide bone scanning. Prognosis is mainly dependent on the mass and degree of epiphyseal involvement (assessed, for example, by Catterall grading).



9.90. Perthes' disease (8): Other adverse factors placing the case in the 'head-at-risk' category include (a) presentation above the age of 4, (b) calcification seen lateral to the epiphysis or other evidence of major extrusion, (c) lateral subluxation (S), (d) a positive Gage sign (a sequestrum surrounded by a 'V' of viable epiphysis (G)).

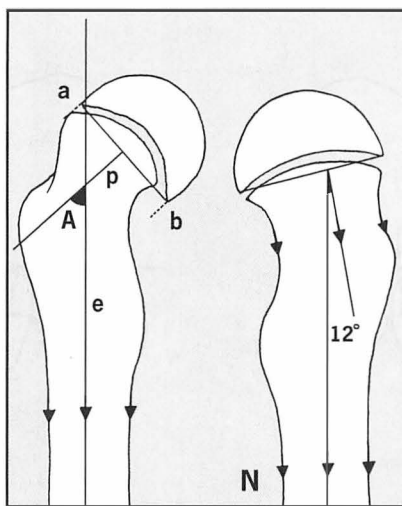


9.91. Perthes' disease (9): Herring lateral pillar classification: Divide the head into three columns during the fragmentation stage; then, if the lateral part is of normal height (Herring A), the prognosis is excellent. If the lateral part is depressed up to 50% (even with the central column involved) (Herring B), the results are generally good under age 9. In Herring C the lateral pillar is less than 50% and all develop permanent deformity.



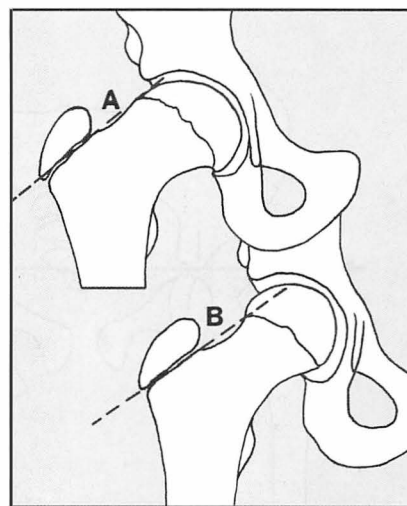
9.92. Slipped femoral epiphysis (1):

The earliest changes are seen in the lateral projection. A line drawn up through the centre of the neck fails to meet the midpoint of the base of the epiphysis. The distance between the centre of the base of the epiphysis (x) compared with the width of the base of the epiphysis may be used to calculate the degree of slip. Less than 1/3 may be classified as grade 2; grade 3 = 1/3 to 1/2; grade 4 = more than 1/2. (Grade 1 is used for pre-slip cases.)



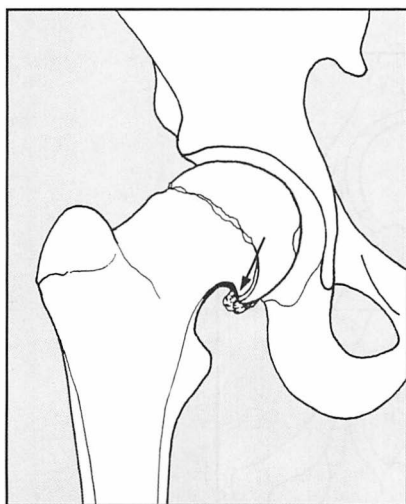
9.93. Slipped femoral epiphysis (2):

Southwick's method of quantifying the severity of any slip: In the frog lateral draw a perpendicular (p) from a line (ab) drawn across the base of the epiphysis. Note the angle (A) between this and a line (e) drawn through the centre of the femoral shaft, and compare the sides. (If the condition is unilateral, subtract 12° to allow for the normal-shaft angle in this projection.) 30° is regarded as mild; 30–60° is moderate, and more than 60° severe.

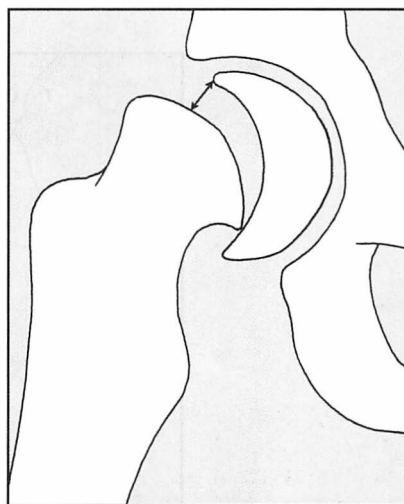


9.94. Slipped femoral epiphysis (3):

Although the earliest radiographic changes are seen in the lateral, greater degrees of slip become detectable in the AP projections. The first sign is that a tangential line drawn on the upper femoral neck fails to strike the epiphysis (A), whereas in a normal well-centred view such a tangent (B) includes part of the epiphysis.

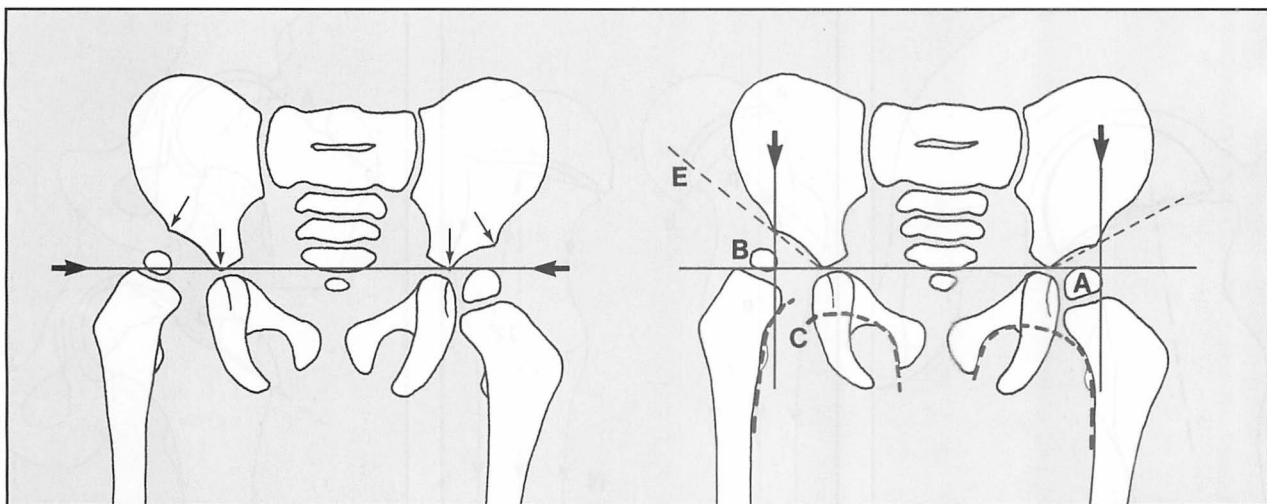


9.95. Slipped femoral epiphysis (4): In the later stages, some weeks after the initial slip (now the so-called 'chronic slip' stage) there is distortion of the inferior part of the femoral neck, with new bone formation ('buttressing').

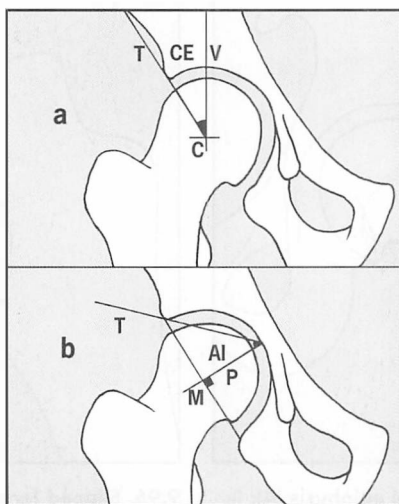


9.96. Slipped femoral epiphysis (5):

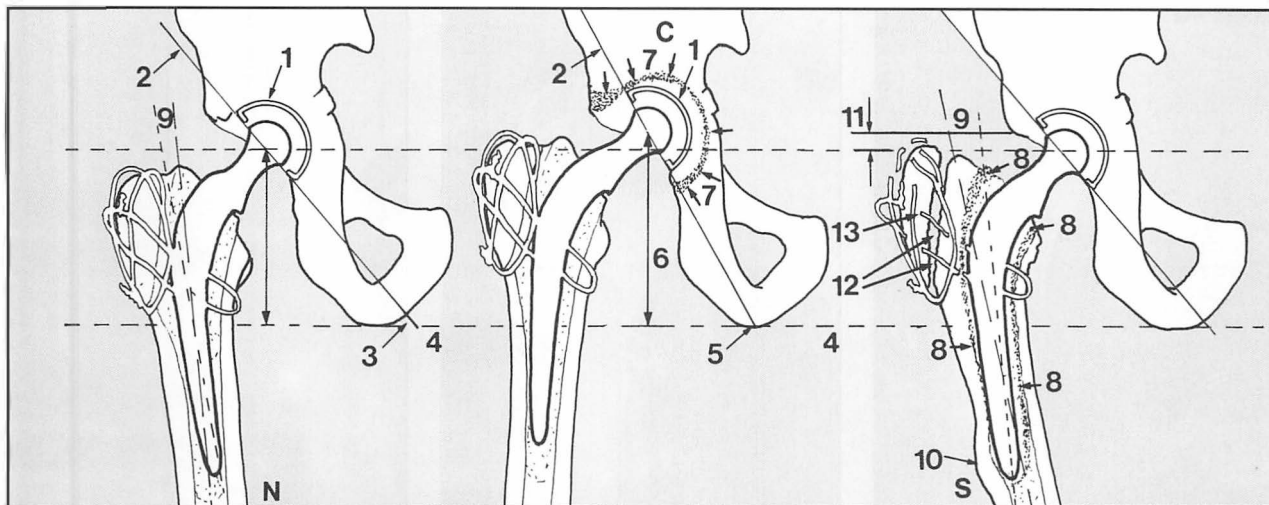
Physeal separation: the frog lateral radiograph is again used. The distance between the anterior lip of epiphysis and the closest point of the metaphysis is measured. In the majority of cases of slipped femoral epiphysis there is in fact no physeal separation. If separation is present, it is seldom detected unless it exceeds 4 mm. Detected separations normally lie in the 4–12 mm range. Separation is a significant finding, as it tends to be associated with a high incidence of avascular necrosis.



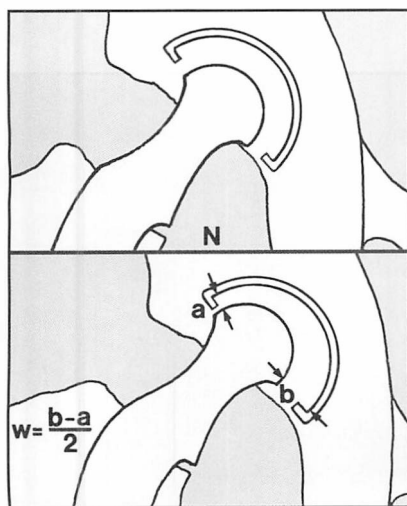
9.97. Radiographs in the child (1): Interpretation of hip radiographs in the older child is dependent on the presence of ossification in the epiphysis of the femoral head. This normally appears between 2 and 8 months, but is often delayed in DDH. The position of the capital epiphysis in relation to the other pelvic elements must be determined. First draw a horizontal line (Hilgenreimer line) across the pelvis. On each side this should touch the downward-pointing apex of the acetabular element of the ilium. Vertical lines (Perkins' lines) should then be drawn from the lateral limits of the acetabula. These lines divide the region of each hip into four areas. The epiphysis of the femoral head should normally lie within the lower and inner quadrant (A), but in DDH the head moves upwards and outwards (as at B). Shenton's line (C) may be disturbed. Dysplasia of the acetabulum alters its slope (E), which decreases with growth (it usually does not exceed 30° at 6 months). There are a number of other measurements of a specialized nature that may be made (and compared with tables detailing average values relating to age and sex) when a more detailed assessment of hip dysplasia is required.



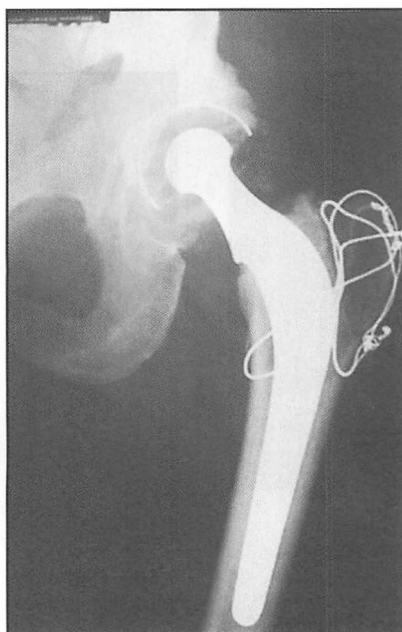
9.98. Radiographs (2): To assess joint development after treatment for DDH the following may be noted (a) the centre-edge angle (CE, of Wiberg); and (b) the acetabular index (AI) angle. (V is a vertical. C the centre of the femoral head, T an acetabular edge tangent, M is the midpoint of a line joining the acetabular margins, P a vertical drawn from it.) Additional information regarding the head, acetabulum and limbus may be obtained by MRI scans or contrast arthrography.



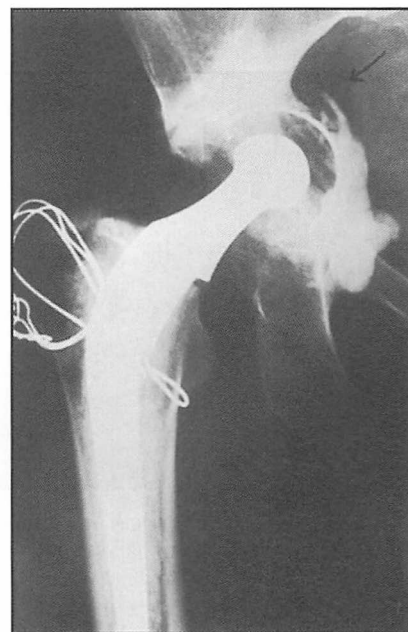9.99. Component loosening after total hip replacement: The cup (C): The wire marker (1) sunk within the radiolucent cup aids the analysis of any radiographic series. The plane (2) of the socket lies at an angle (3) to the plane of the pelvis (4), shown by a line drawn between the ischial tuberosities. This angle may be altered (5) by rotation of the cup if it loosens. The cup may also migrate proximally: look for any disturbance in the relationship between the wire marker and the fixed landmarks of the pelvis. An increase in the distance (6) between the centre of the cup and the ischium may be suggestive of migration, although errors of positioning and tube/film distances make this a little unreliable. Development of a radiolucent zone (7) (between cement and bone) exceeding 1 mm and extending right round the cup is a strong indicator of loosening. (Note that the appearance of a radiolucent line between the cement and a component is diagnostic of loosening.) **The stem (S):** Look for a radiolucent zone of more than 1 mm between cement and bone (8) or between the stem and the cement. Note any change in the angle between the axes of the femur and prosthetic stem (9), or any local bone disturbance (10). Check for sinking of the prosthesis, by noting the distance between the upper edge of the acetabulum and the greater trochanter (11). Non-union of the greater trochanter (12) and wire fracture and fragmentation (13) should also be recorded.



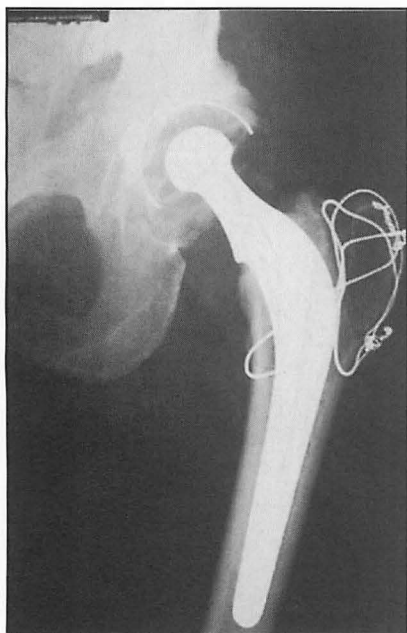
9.100. Component wear: This is posing less of a problem than was originally anticipated by both surgeons and patients, but should be assessed. Wear involves the softer acetabular component; head wear is negligible. To determine wear, measure the gap between the prosthetic head and the wire marker at their upper and lower limits. Half the difference between these is a measure of wear in the wall of the cup, 3 mm or more being an appreciable amount.



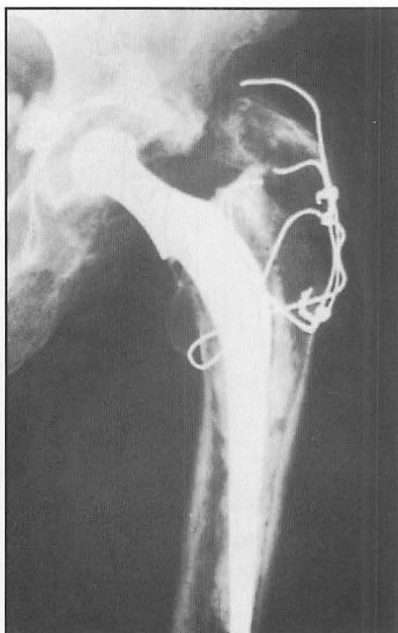9.101. Radiographs: In this (normal) Charnley total hip replacement, the stem of the prosthesis is well placed. The greater trochanter is uniting in good position, and the wires are intact. The head of the femoral component is concentric with the acetabular wire marker.



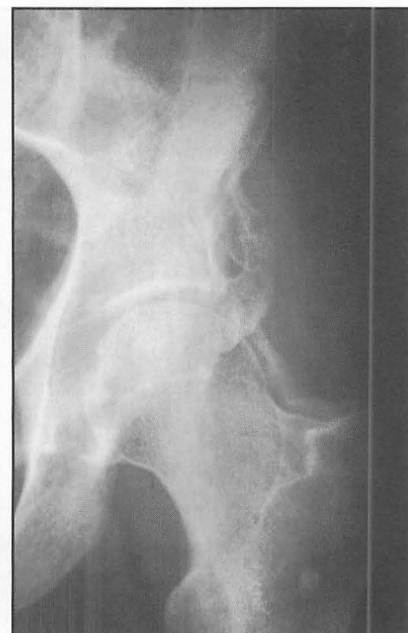9.102. Hip radiographs: examples of pathology (1): After a total hip replacement the floor of the acetabulum has given way and the cup is becoming centrally displaced.



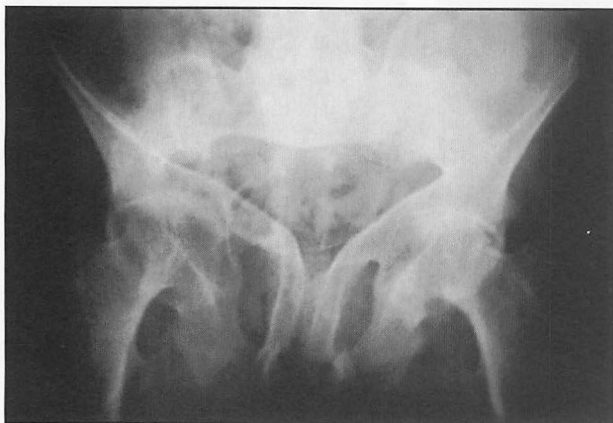
9.103. Pathology (2): After a total hip replacement the prosthetic stem has fractured, with loss of the ability to weightbear. Note the cement, which has extruded into the pelvis during the insertion of the device. There is some evidence of loosening of both the cup and the stem.



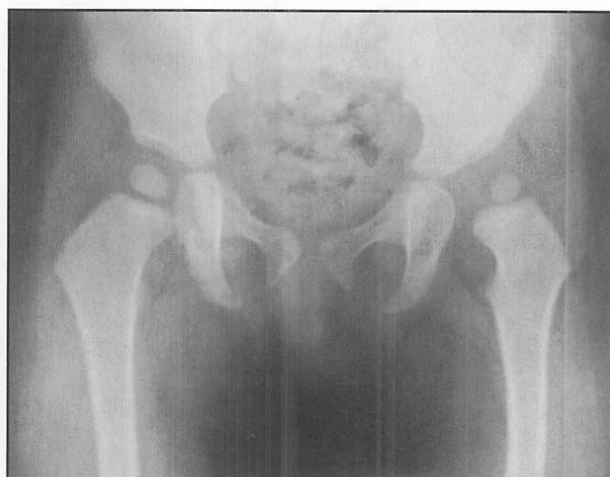9.104. Pathology (3): In this case of total hip replacement the trochanteric wires have broken; the trochanter has displaced proximally and failed to unite. The stem has loosened, and its distal end is in danger of breaching the femoral cortex. Note the extensive translucency at the bone-cement interface.



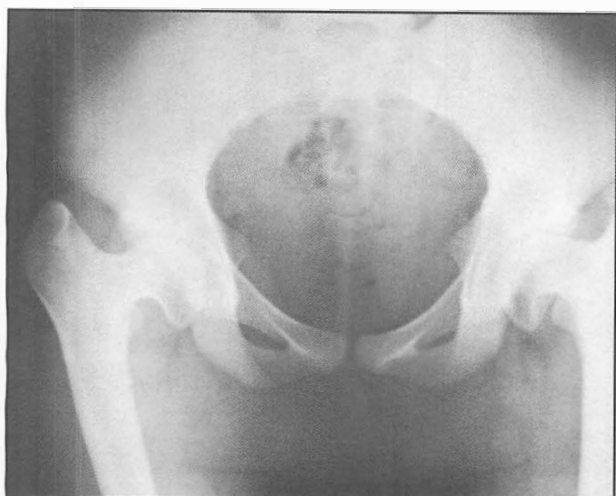9.105. Pathology (4): Following a dislocation of the hip which was successfully reduced, this patient complained of great stiffness in the hip. Note the extensive new bone formation around the joint.
Diagnosis: myositis ossificans.



9.106. Pathology (5): Note the gross distortion of the pelvis.
Diagnosis: triradiate pelvis, in this case secondary to osteomalacia.

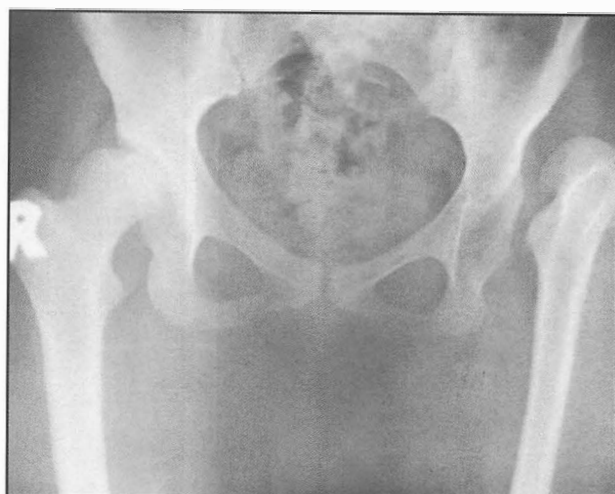

9.107. Pathology (6): In the left hip (right of the illustration) the femoral epiphysis is smaller than on the other side, and the slope of the acetabulum greater. Shenton's line is disrupted. If Perkins' squares are constructed, the epiphysis of the femoral head will be seen to lie in the upper and outer quadrant. (Compare these findings with the other side.) There is some atrophy of the femoral shaft, suggesting a long-standing lesion.
Diagnosis: developmental dislocation of the left hip.



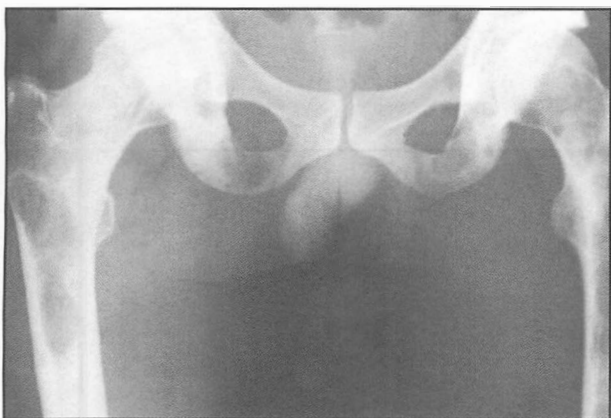9.108. Pathology (7): There is distortion of both femoral heads, which have become buffer shaped, and there is alteration of the neck-shaft angles.

Diagnosis: congenital coxa vara.



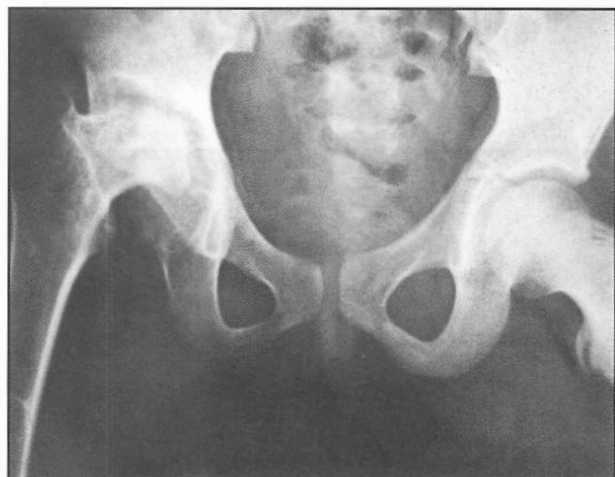9.109. Pathology (8): The left the hip is dislocated and the femoral head atrophic; on the right the femoral head is poorly contained in the acetabulum, and there are early osteoarthritic changes in the joint. Both acetabula are poorly developed, and their slope is markedly increased.

Diagnosis: untreated developmental dislocation of the hip.



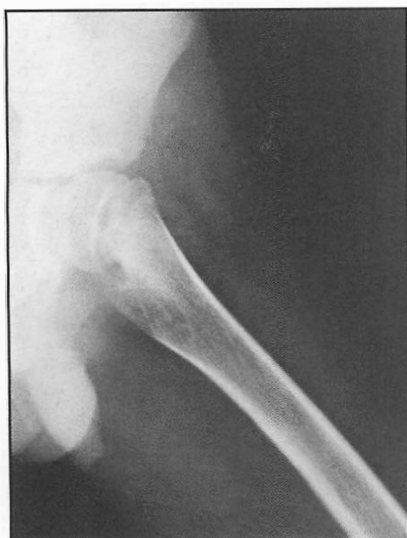9.110. Pathology (9): There are widespread cystic changes in both femora and the pelvis.

Diagnosis: in this case the abnormal appearances are due to hyperparathyroidism.

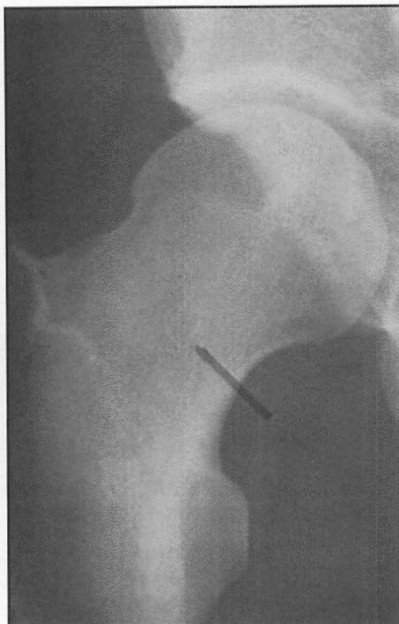


9.111. Pathology (10): This radiograph of the pelvis of an adolescent boy shows gross destruction of the right hip joint, with changes in both the head of the femur and the acetabulum.

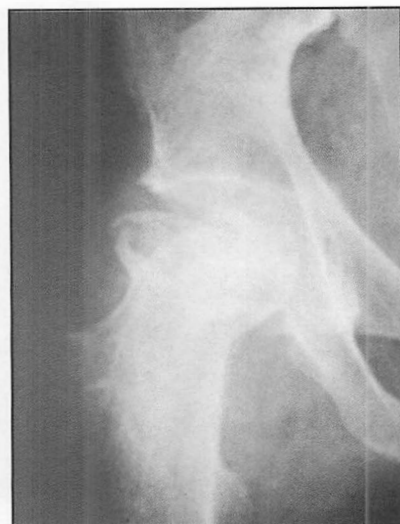Diagnosis: the appearances are typical of an infective arthritis. In this case the organism was the tubercle bacillus.



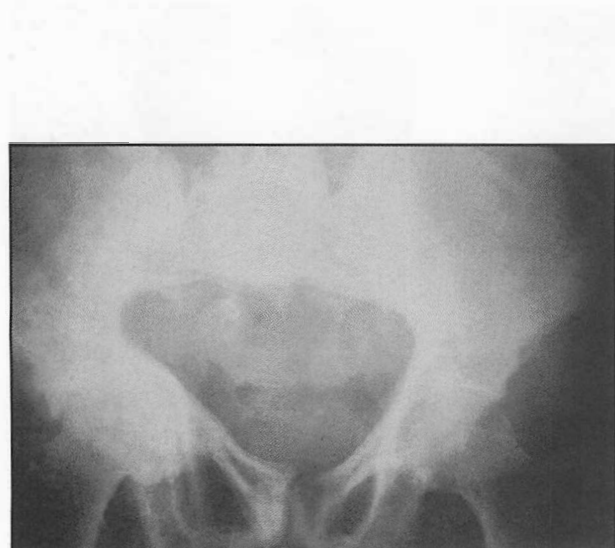
9.112. Pathology (11): This lateral projection of the hip shows displacement of the proximal femoral epiphysis relative to the femoral neck.
Diagnosis: slipped femoral epiphysis.



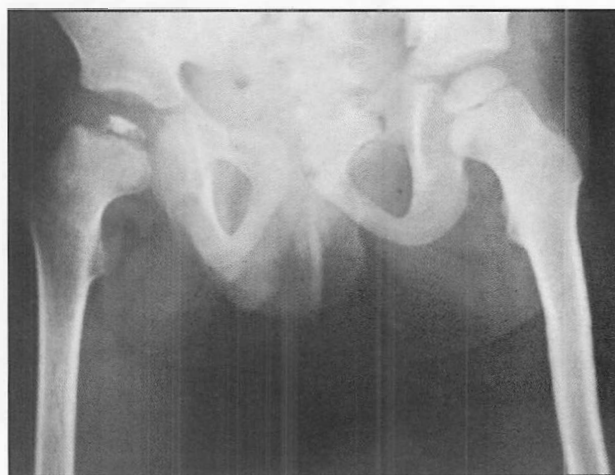9.113. Pathology (12): The pointer marks a ringed area of bone in the femoral neck with a central nidus. This was the source of chronic, niggling bone pain.
Diagnosis: the history and X-ray appearance are typical of osteoid osteoma.



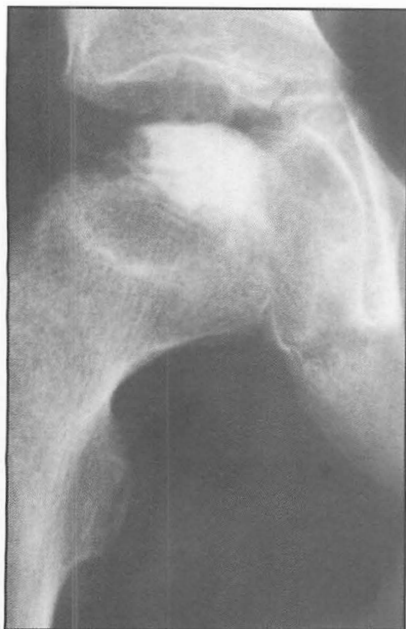9.114. Pathology (13): The complaint is of pain and stiffness of the hip following a hip fracture 2 years previously. The fracture was treated by nailing; the internal fixation device was subsequently removed, and there are some very minor changes only in bone texture to show its previous presence.
Diagnosis: collapse of the femoral head due to avascular necrosis. There are secondary osteoarthritic changes in the hip.



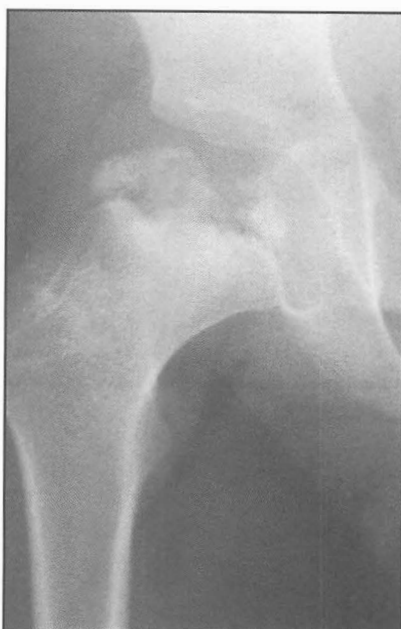9.115. Pathology (14): There is marked disturbance of the bony texture, mainly involving the right hemipelvis. There is a degree of protrusio acetabuli, and there is disturbance of the architecture of the hemipelvis, which is becoming centrally displaced.
Diagnosis: Paget's disease.



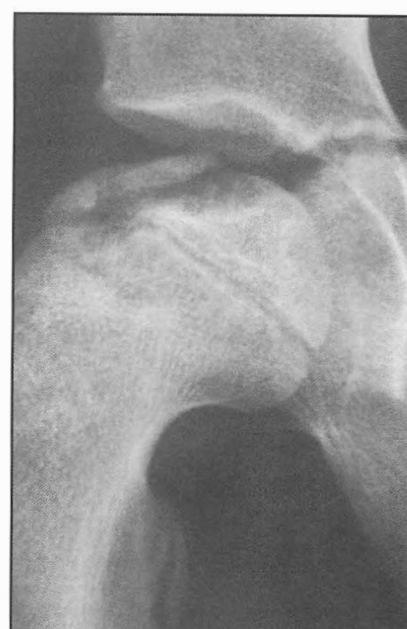9.116. Pathology (15): The epiphysis of the right femoral head is small and of increased density. There is some broadening of the metaphysis, and there are some cystic changes in the roof of the acetabulum.
Diagnosis: Perthes' disease.



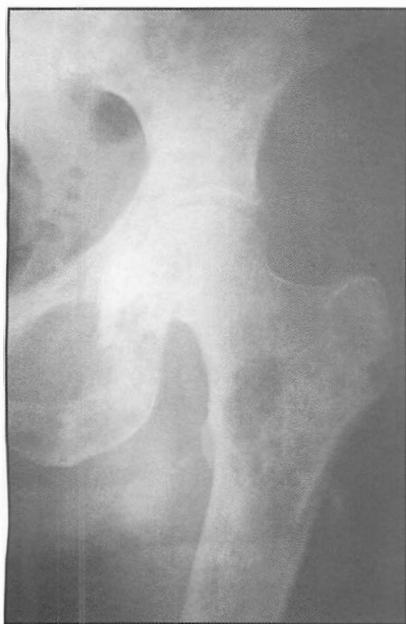
9.117. Pathology (16): There is increased density of the capital epiphysis and some cystic change in the metaphysis, which is showing signs of broadening. There are also some cystic changes in the outer half of the acetabulum. The area of sclerosis along the inferior margin of the cyst is sometimes referred to as the 'sagging rope' sign.
Diagnosis: Perthes' disease.



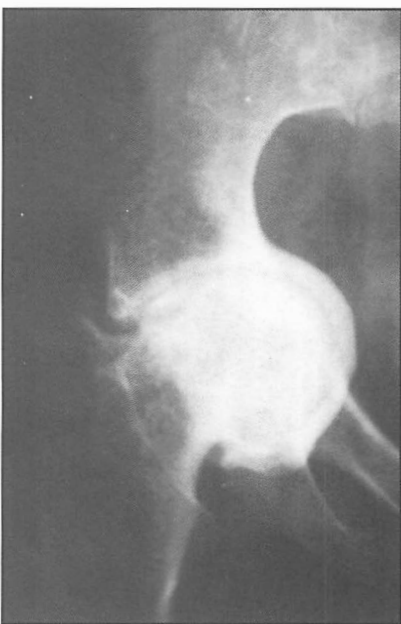9.118. Pathology (17): There is fragmentation of the capital epiphysis, with the presence of Gage's sign.
Diagnosis: Perthes' disease.



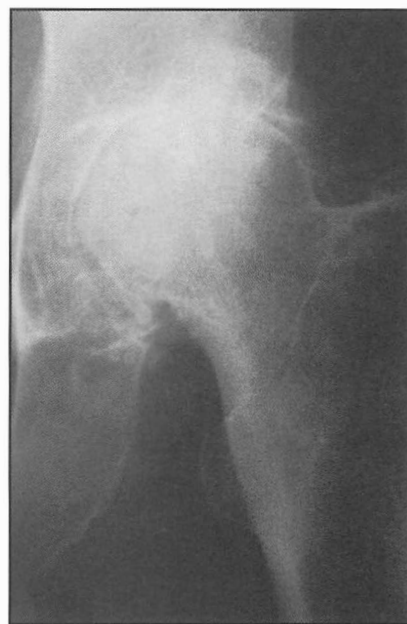9.119. Pathology (18): There is separation and collapse of the lateral part of the epiphysis, with distortion of the epiphyseal plate and cystic changes in the metaphysis, which is broadened. The bone density, which was previously increased, is returning to normal.
Diagnosis: long-established Perthes' disease. This would be described as grade C in the Herring classification of Perthes' disease.



9.120. Pathology (19): There are widespread changes in bone texture in the femur and pelvis, both having a moth-eaten appearance.
Diagnosis: metastatic bone disease.



9.121. Pathology (20): The floor of the acetabulum is projecting into the pelvis. There is narrowing of the joint space, and a minor degree of marginal exostosis formation.
Diagnosis: osteoarthritis with protrusio acetabuli.



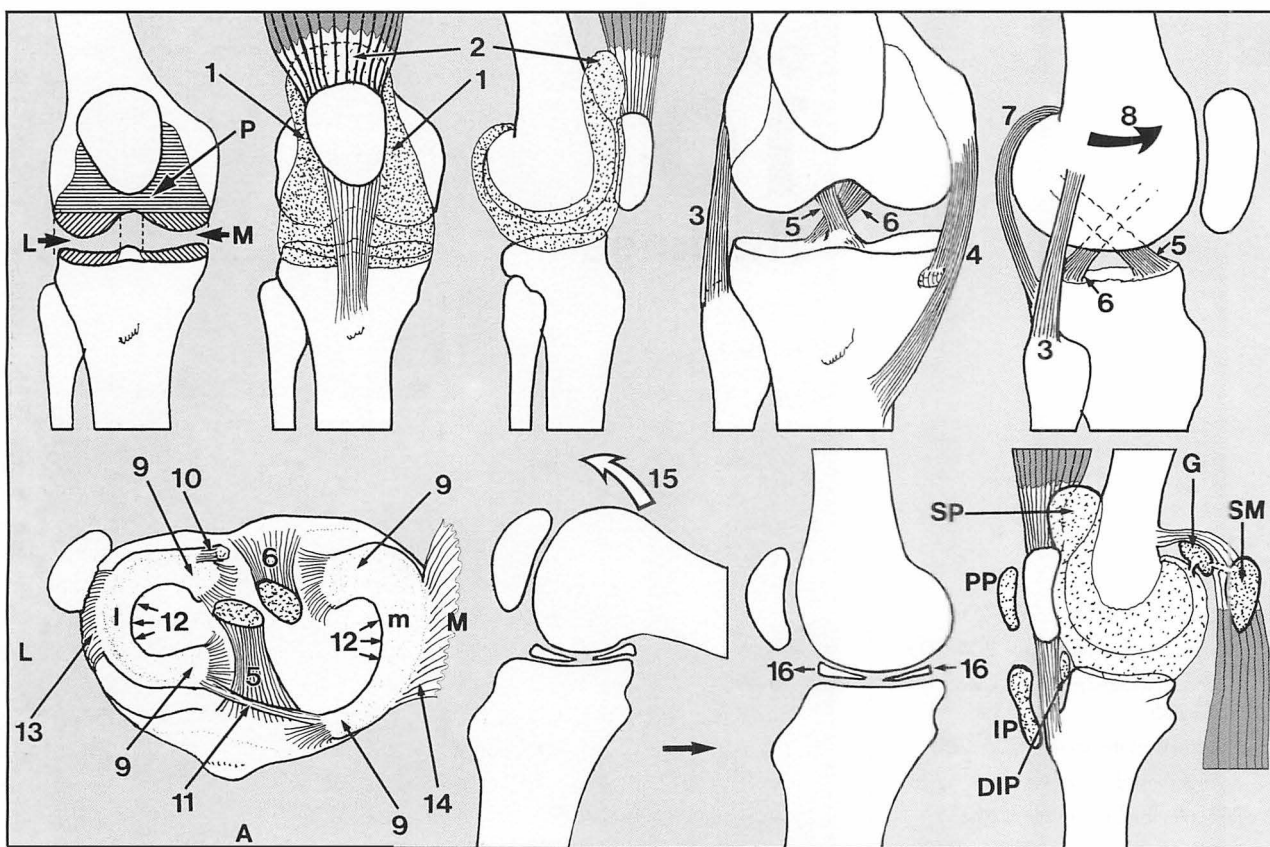
9.122. Pathology (20): There is gross narrowing of the hip joint space.
Diagnosis: osteoarthritis.

CHAPTER

10

The knee

- Anatomical features 202–204
- Causes of knee swelling 204–205
- Extensor mechanism of the knee 205–206
- Ligaments of the knee 206–208
- Rotatory instability of the knee 208
- Patellofemoral instability 209
- Anterior knee pain syndromes 210
- Osteochondritis dissecans, fat pad injuries and loose bodies 211
- Osteoarthritis, rheumatoid arthritis, Reiter's syndrome, ankylosing spondylitis 212
- Disturbances of knee alignment 212–213
- How to diagnose a knee complaint 213–216
- Inspection 217
- Testing the quadriceps and extensor mechanism 218–219
- Diagnosing effusion 219–221
- Tenderness 221–222
- Genu valgum, genu varum and stress instabilities 224–228
- Examining the cruciate ligaments 228–231
- Pivot shift tests 231–232
- Meniscal testing 232–234
- Patellar assessment 234–235
- Radiographs 236–238
- Aspiration of the knee 238–239
- Pathology 239–243



10.A

ANATOMICAL FEATURES

The knee joint (Fig. 10.A) combines three articulations (medial tibiofemoral (M), lateral tibiofemoral (L) and patellofemoral (P)), which share a common synovial sheath; anteriorly, this extends a little to either side (1) of the patella and an appreciable amount proximal to its upper pole (2). This portion, the suprapatellar pouch, lies deep to the quadriceps muscle.

There is little congruency between the articular surfaces of the tibia and femur; as a result, there is a well developed system of ligaments to give the knee stability, and an arrangement of intra-articular menisci to reduce the contact loadings between femur and tibia.

LIGAMENTS

1. *The lateral ligament* (3) extends between the lateral epicondyle and the head of the fibula.
2. *The medial ligament* (4), consisting of superficial and deep parts, is attached above to the medial epicondyle of the femur, and below to the medial surface of the tibia on either side of the semimembranosus groove.
3. *The anterior cruciate ligament* (5) runs between the tibial plateau anteriorly and the lateral femoral condyle posteriorly.
4. *The posterior cruciate ligament* (6) runs between the tibial plateau posteriorly and the medial femoral condyle anteriorly.

Both cruciate ligaments lie within the confines of the intercondylar notch of the femur, thereby avoiding being trapped between the articular surfaces during movement of the joint.

5. *The posterior ligament* (7) is attached to posterior aspects of the femur and the tibia just outside their articular margins.

During the last 10° or so of knee extension the ligaments of the joint are twisted taut as a result of medial rotation (8) of the femur on the tibia; at the start of flexion, this tightening is undone by lateral rotation of the femur, aided by contraction of the popliteus muscle.

MENISCI

In plan view the *medial* (m) and *lateral* (l) menisci are C-shaped; they are triangular in cross-section, and formed from dense avascular fibrous tissue. Their extremities (horns) (9) are attached to the upper surface of the tibia on which they lie; the posterior horn of the lateral meniscus has an additional attachment (10) to the femur, whereas both anterior horns are loosely connected (11). The concave margin (12) of each meniscus is unattached; the convex margin of the lateral meniscus is anchored to the tibia by coronary ligaments (13), whereas the corresponding part of the medial meniscus is attached to the joint capsule (14) and thereby loosely united to both femur and tibia.

During extension of the knee (15) the menisci slide forwards (16) on the tibial plateau and become progressively more compressed, adapting in shape to the altering contours of the particular portions of the femur and tibia between which they come to lie.

Only the peripheral edges of the menisci have an appreciable blood supply, so that meniscal tears that involve the more central portions have a poor potential for healing.

BURSAE

Numerous bursae have been described round the knee, but from the practical point of view only a few are of any real significance.

At the front:

- (a) *The suprapatellar pouch* (SP) or *bursa* is a normal extension of the synovial compartment of the knee; it may become prominent as a result of a joint effusion, but treatment is always directed at the underlying cause rather than this local effect.
- (b) A *prepatellar bursa* (PP) may form between the patella and the overlying skin as a result of repeated local friction, e.g. from kneeling.
- (c) An *infrapatellar bursa* (IP) may form between the skin and the tibial tubercle or patellar ligament, again usually as a result of local friction from kneeling. Bursae forming deep to the patellar ligament (DIP) also occur, but are rather uncommon.

At the back:

Bursal enlargements may be encountered in the popliteal fossa, and these are generally referred to as *Baker's cysts* or enlarged *semimembranosus bursae*. Some are found to communicate with the knee joint (sometimes with a valve-like mechanism), and tend to keep pace in terms of distension with any effusion in the knee.

Others are quite unconnected with the joint. The anatomical explanation is that although the semimembranosus bursa (SM) itself never communicates

with the knee, it is often connected to the bursa (G) under the medial head of gastrocnemius, which does.

SWELLING OF THE KNEE

The knee may become swollen as a result of the accumulation within the joint cavity of excess synovial fluid, blood or pus (synovitis, haemarthrosis, pyarthrosis). Much less commonly, the knee swells beyond the limits of the synovial membrane. This is seen in soft tissue injuries of the knee, when haematoma formation and oedema may be extensive. It is also a feature of fractures, infections and tumours of the distal femur, where confusion may result either from the proximity of the lesion to the joint or because it involves the joint cavity directly. Although primary tumours of the knee are rare, in malignant synovioma there is striking swelling of the joint, and this often extends beyond the limits of the synovial cavity.

SYNOVITIS, EFFUSION

The synovial membrane secretes the synovial fluid of the joint; excess synovial fluid indicates some affection of the membrane. Joint injuries cause synovitis by tearing or stretching the synovial membrane. Infections act directly by eliciting an inflammatory response which causes the synovial membrane to secrete more fluid. The membrane itself becomes thickened and its function disturbed in rheumatoid arthritis and villonodular synovitis; both conditions are usually accompanied by large effusions. In long-standing meniscus lesions and in osteoarthritis of the knee the synovial membrane may not be directly affected, and consequently no effusion may be present in either of these conditions. Minor injuries of the knee which do not materially damage any of the main structural elements are in some cases followed by rather persistent effusions (traumatic synovitis). In spite of these exceptions, the recognition of fluid in the joint is of great importance. Effusion indicates damage to the joint, and the presence of a major lesion must always be eliminated. A tense synovitis may be aspirated to relieve discomfort.

HAEMARTHROSIS

Blood in the knee is seen most commonly following acute injuries where there is tearing of vascular structures. The menisci are avascular, and there may be no haemarthrosis when a meniscus is torn. Bleeding into the joint will take place, however, if the meniscus has been detached at its periphery, or if there is accompanying damage to other structures within the knee (e.g. the cruciate ligaments). In injuries of the medial ligament, a haematoma may track distally without involvement of the joint cavity. Nevertheless, the presence of a haemarthrosis generally indicates a substantial injury to the joint and is a serious finding. Its physical presence alone may give rise to great discomfort and make diagnosis of its underlying cause rather difficult. In view of this a tense, painful haemarthrosis should be aspirated.

PYARTHROSIS

Infections of the knee joint are rather uncommon, and usually bloodborne. Sometimes the joint is involved by direct spread from an osteitis of the

femur or tibia; rarely the joint becomes infected following surgery or penetrating wounds.

In acute pyogenic infections the onset is usually rapid and the knee very painful; swelling is tense, tenderness is widespread, and movement resisted. There is pyrexia and general malaise. Pyogenic infections occurring in patients already suffering from rheumatoid arthritis often have a much slower onset. Although the joint is invariably swollen, other inflammatory changes are often suppressed, especially if the patient is receiving steroids.

Tuberculous infections of the knee, now uncommon in the UK, have a slow onset spread over weeks. The knee appears small and globular, with the associated profound quadriceps wasting contributing to this appearance.

In gonococcal arthritis, great pain and tenderness, often apparently out of proportion to the local swelling and other signs, are the striking features of this condition.

When pus is suspected in a joint, aspiration should always be carried out to empty it and obtain specimens for bacteriological examination. If tuberculosis is suspected, synovial biopsy to obtain specimens for culture and histology is required. All knee infections are treated by splintage and an appropriate antibiotic regimen.

THE EXTENSOR MECHANISM OF THE KNEE

Extension of the knee is produced by the quadriceps muscle acting through the quadriceps ligament, patella, patellar ligament and tibial tubercle. *Weakness of extension* leads to instability, repeated joint trauma and effusion. There is often a vicious circle of pain → quadriceps inhibition → quadriceps wasting → knee instability → ligament stretching and further injury → pain. *Loss of full extension* also leads to instability, as there is failure of the screw-home mechanism which tightens the ligaments of the joint at terminal extension.

Rapid wasting of the quadriceps is seen in all painful and inflammatory conditions of the knee. Weakness of the quadriceps is also sometimes found in lesions of the upper lumbar intervertebral discs, as a sequel to poliomyelitis, in multiple sclerosis and other neurological disorders, and in the myopathies. Difficulty in diagnosis is common when the wasting is the presenting feature of a diabetic neuropathy or secondary to femoral nerve palsy from an iliacus haematoma. Maintenance of good quadriceps tone and breaking the quadriceps vicious circle is an essential part of the treatment of virtually all conditions affecting the knee joint.

Disruption of the extensor mechanism of the knee is seen in a number of conditions. *Fractures of the patella* seldom give difficulty in diagnosis provided the appropriate radiographs are taken. *Ruptures of the quadriceps tendon or patellar ligament* result from sudden, violent contraction of the quadriceps and are seen in the middle-aged when there has been some accompanying degenerative change in the structures involved. *Avulsion of the tibial tuberosity* may also be seen as a result of a sudden muscle contraction. All these acute conditions are generally treated surgically.

There are a number of conditions short of disruption which may affect the patellar ligament and its extremities, with the generic title of jumper's knee. In the *Sinding-Larsen-Johansson syndrome*, seen in children in the 10–14-year age group, there is aching pain in the knee associated with X-ray changes in the distal pole of the patella. *Osgood-Schlatter's disease* (which

is often thought to be due to a partial avulsion of the tuberosity) occurs in the 10–16 age group. There is recurrent pain over the tibial tuberosity, which becomes tender and prominent. Radiographs may show partial detachment or fragmentation of the tuberosity. Pain usually ceases with closure of the epiphysis, and the management is usually conservative. In an older age group (16–30) the patellar ligament itself may become painful and tender. This almost invariably occurs in athletes, and there may be a history of giving-way of the knee. CT scans may show changes in the patellar ligament, which becomes expanded centrally. Exploration and incision of the patellar ligament is usually advised. Rarely, pain and tenderness may occur proximal to the upper pole of the patella in *quadriceps tendinitis*.

THE LIGAMENTS OF THE KNEE

The cruciate, collateral, posterior and capsular ligaments, and the menisci, form an integrated stabilizing system which prevents the tibia from shifting or tilting under the femur in an abnormal fashion. The pathological movements that may occur after ligamentous injury are (a) tilting of the knee into varus or valgus, (b) shifting of the tibia directly forwards or backwards (anterior or posterior translation), and (c) rotation of the tibia under the femur so that the medial or lateral tibial condyle subluxes forwards or backwards.

Ligament injuries are important to detect as they may account for appreciable disability, in the form of incidents of giving-way of the joint, recurrent effusion, lack of confidence in the knee, difficulty in undertaking strenuous or athletic activities, and sometimes trouble in using stairs or walking on uneven ground.

The diagnosis and interpretation of instability in the knee is difficult and somewhat controversial, for the following reasons:

1. Several structures may be damaged simultaneously.
2. Each of the main ligamentous structures around the knee has primary and secondary supportive functions: if a ligament whose primary role in averting a certain abnormal movement is torn, that movement may nevertheless be prevented by other structures which have a secondary supporting function. Later, however, the secondary structures may stretch, giving rise to increasing disability. As a result, the symptoms and clinical signs may be masked during the initial stages, and only become obvious later.
3. A plethora of terms describing these instabilities makes the interpretation of the literature somewhat difficult. The present trend in both examination and management is to analyse and treat the instability; less emphasis is placed on the diagnosis of the precise anatomical disturbance. Nevertheless, the main supportive structures have certain distinctive features which should be noted.

THE MEDIAL LIGAMENT AND CAPSULE

The medial ligament stretches between the femur and the tibia and has both superficial and deep layers. Considerable violence (usually in the form of a valgus strain or a blow on the lateral side of the knee) is required to damage the medial ligament. When the forces are moderately severe a few fibres only may be torn, usually near the upper attachment (sprain of the medial ligament). Then, when the knee is examined clinically, no instability will be demonstrated, but stretching the ligament will cause pain. Minor tears of the medial ligament may be followed eventually by calcification in the

accompanying haematoma, and this may give rise to sharply localized pain at the upper attachment (Pellegrini–Stieda disease).

With greater violence the whole of the deep part of the ligament ruptures, followed in order by the superficial part, the medial capsule, the posterior ligament, the posterior cruciate ligament, and sometimes finally the anterior cruciate ligament. Acute complete tears give rise to serious instability in the knee, which can move or be moved into valgus. They are usually dealt with by immediate surgical repair. Partial tears do well by immobilization for 6 weeks in a pipe-stem plaster. Chronic lesions may be accompanied by tibial condylar subluxation (see later), although there is some doubt as to whether this is indeed possible without there being some additional damage to the anterior cruciate ligament. Surgical treatment may be indicated for such instability. Medial ligament tears may accompany fractures of the lateral tibial table, which will require additional attention.

THE LATERAL LIGAMENT AND CAPSULE

This ligament may be damaged by blows on the medial side of the knee, throwing it into varus. It most frequently tears at its fibular attachment. As in the case of the medial ligament, increasing violence will lead to tearing of the posterior capsular ligament and the cruciates. In addition, the common peroneal nerve may be stretched and sometimes irreversibly damaged. These injuries are usually treated by operative repair and, where applicable, exploration of the common peroneal nerve. Again, any associated fracture of the medial tibial table may require attention. Chronic lesions may be associated with tibial condylar subluxations.

THE ANTERIOR CRUCIATE LIGAMENT

Impaired anterior cruciate ligament function is seen most frequently in association with tears of the medial meniscus. In some cases this is due to progressive stretching and attrition rupture of the ligament. (This may occur if an attempt is made to obtain full extension in a knee blocked by a meniscal fragment.) In others, the anterior cruciate ligament tears at the same time as the meniscus, and in the most severe injuries the medial ligament may also be affected (O'Donoghue's triad).

Isolated ruptures of the anterior cruciate ligament are uncommon and are not usually treated surgically unless accompanied by avulsion of bone at the anterior tibial attachment, or if there is a strongly positive pivot shift test.

When the tear is acute and accompanies a meniscal lesion, the meniscus is preserved if at all possible to reduce the risks of tibial subluxation and secondary osteoarthritic change, although the damage may be such that excision cannot be avoided. After attention to the meniscus, many would then advocate direct repair of the anterior cruciate ligament, supplemented by a ligament reinforcement or a reconstruction procedure (e.g. using part of the patellar ligament and its bony attachments). When an acute anterior cruciate tear is associated with damage to the medial or, less commonly, the lateral collateral ligament, a similar approach may be employed.

Chronic anterior cruciate ligament laxity generally results from old injuries, and may cause problems from acute, chronic or recurrent tibial subluxations. There may be a history of giving-way of the knee, episodic pain and functional impairment. There is often quadriceps wasting and effusion, and secondary osteoarthritis may develop. Intense quadriceps and hamstring muscle building is usually advised as a first measure. In resistant

cases, a ligament reconstruction may be advocated. There is no doubt that these procedures are often initially very successful, but in some the long-term results are disappointing.

THE POSTERIOR CRUCIATE LIGAMENT

Posterior cruciate ligament tears are produced when in a flexed knee the tibia is forcibly pushed backwards (as, for example, in a car accident when the upper part of the shin strikes the dashboard). Most advise immediate surgical repair if the injury is seen at the acute stage, as persisting instability and osteoarthritis are common sequelae in the untreated case.

ROTATORY INSTABILITY IN THE KNEE: TIBIAL CONDYLAR SUBLUXATIONS

In this group of conditions, when the knee is stressed the tibia may sublux forwards or backwards on either the medial or lateral side, giving rise to pain and a feeling of instability in the joint. The main forms are as follows:

1. *The medial tibial condyle subluxes anteriorly* (anteromedial rotatory instability). In the most severe cases this occurs as a result of tears of both the anterior cruciate ligament and the medial structures (medial ligament and capsule). The medial meniscus may also be damaged and contribute to the instability. In the less severe cases there is some controversy regarding which structures may be spared. Clinically, the condition should be suspected on the evidence of the anterior drawer and Lachman tests, and the demonstration of instability on applying a valgus stress to the joint.
2. *The lateral tibial condyle subluxes anteriorly* (anterolateral rotatory instability). In the more severe cases the anterior cruciate ligament and the lateral structures are torn, and there may be an associated lesion of the anterior horn of the lateral meniscus. It may be diagnosed from the results of the anterior drawer and Lachman tests, and by demonstrating instability on applying a varus stress to the knee, although a number of specific tests may afford additional confirmation.
3. *The lateral tibial condyle subluxes posteriorly* (posterolateral rotatory instability). This may follow rupture of the lateral and posterior cruciate ligaments, and be recognized by the presence of instability in the knee on applying varus stress, in combination with eliciting an abnormal posterior drawer test. There are also specific tests for this instability.
4. *Combinations of these lesions* (particularly 1 and 2, and 2 and 3) may be found, especially where there is major ligamentous disruption of the knee.

Where symptoms are demanding, and when a firm diagnosis has been established, the stability of the joint may be restored by an appropriate ligamentous reattachment or reconstruction procedure.

LESIONS OF THE MENISCI

CONGENITAL DISCOID MENISCUS

This abnormality, most frequently involving the lateral meniscus, commonly gives rise to presenting symptoms in childhood. The meniscus has not its usual semilunar form but is D-shaped, with its central edge extending in towards the tibial spines. It may produce a very pronounced clicking from the lateral compartment, a block to extension of the joint, and other derangement signs. It is usually treated by excision.

MENISCUS TEARS IN THE YOUNG ADULT

The commonest cause is a sporting injury, when a twisting strain is applied to the flexed, weightbearing leg. The trapped meniscus commonly splits longitudinally, and its free edge may displace inwards towards the centre of the joint (bucket-handle tear). This prevents full extension (with physiological locking of the joint), and if an attempt is made to straighten the knee a painful elastic resistance is felt ('springy block to full extension'). In the case of the medial meniscus, prolonged loss of full extension may lead to stretching and eventual rupture of the anterior cruciate ligament.

The aim in treating meniscal tears is to correct the mechanical problems that they have created within the joint, while if at all possible preserving as much of each meniscus as is possible; this, it is thought, will reduce the risks of instability and the onset of secondary osteoarthritis. In many cases the torn part of the meniscus (e.g. the handle of a bucket-handle tear) only is excised, but some major meniscal tears may require total meniscectomy. In peripheral detachments and certain other lesions, particularly those near the periphery of the meniscus, repair by direct suture or other measures is sometimes attempted. Many surgical procedures are performed arthroscopically, thereby facilitating early recovery.

DEGENERATIVE MENISCUS LESIONS IN THE MIDDLE-AGED

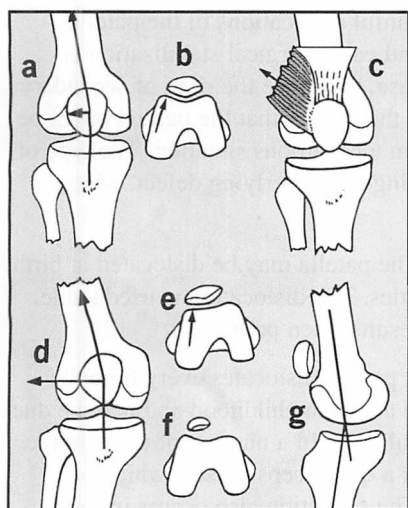
Loss of elasticity in the menisci through degenerative changes associated with the ageing process may give rise to horizontal cleavage tears within the substance of the meniscus; these tears may not be associated with any remembered traumatic incident, and sharply localized tenderness in the joint line is a common feature. In an appreciable number of cases symptoms may resolve without surgery, although this may sometimes be required.

CYSTS OF THE MENISCI

Ganglion-like cysts occur in both menisci, but are much more common in the lateral. Medial meniscus cysts must be carefully distinguished from ganglions arising from the pes anserinus (the insertion of sartorius, gracilis and semitendinosus). In true cysts there is often a history of a blow on the side of the knee over the meniscus. They are tender, and as they restrict the mobility of the menisci they render them more susceptible to tears. They are generally treated by excision, and sometimes simultaneous meniscectomy may be required, especially if there are problems with recurrence. Some workers believe that all meniscal cysts have an associated tear, and prefer to deal with the problem by arthroscopic resection of the tear and simultaneous decompression of the cyst through the substance of the meniscus.

PATELLOFEMORAL INSTABILITY

The patella has always a tendency to lateral dislocation as the tibial tuberosity lies lateral to the dynamic axis of the quadriceps (Fig 10.B); any tightness in the extensor mechanism (e.g. from quadriceps contractions or fibrosis) generates a lateral component of force that tends to displace the patella laterally. Normally, at the beginning of knee flexion the patella engages in the groove separating the two femoral condyles (the trochlea), and this keeps it in place as flexion continues. This system may be disturbed in a number of ways. The side thrusts that tend to cause the patella to sublux



10.B: Some factors relating to patellar instability. Because the quadriceps and the patellar ligament meet at an angle (Q angle) there is a lateral component of force when the quadriceps contracts, and this tends to dislocate the patella laterally (a). This is resisted by the femoral sulcus in which the patella lies, and the prominence of the lateral femoral condyle (b). This mechanism may be interfered with by an abnormal lateral insertion of the quadriceps (c), or an increase in the Q angle (e.g. in knock knee) (d). The lateral femoral condyle may be hypoplastic and the condylar sulcus shallow (e); or the patella itself may be hypoplastic (f). The patella may be highly placed, especially in genu recurvatum (g), so that it fails to engage in the condylar gutter.

laterally may be increased by an abnormal lateral insertion of the quadriceps, tight lateral structures, or by increases in the angle between the axis of the quadriceps and the line of the patellar ligament (e.g. as a result of knock-knee deformity, or by a broad pelvis). The lateral condyle which supports and guides the patella may be deficient, or the patella itself may be small and poorly formed (hypoplasia). If the patella is highly placed (patella alta) it may fail to engage in the condylar groove at the beginning of flexion. (This condition is often associated with genu recurvatum.) Medial to the patella the soft tissues that would normally help prevent an abnormal lateral excursion of the patella may be deficient, sometimes as a result of stretching from previous dislocations.

There are a number of conditions characterized by loss of normal patellar alignment.

Acute traumatic dislocation of the patella This injury occurs most frequently in adolescent females during athletic activity (e.g. playing hockey). There may be a history of a direct blow on the inside of the knee. The patella dislocates laterally and causes a striking deformity, which has often reduced by the time the patient is first seen. If still displaced it is reduced, and a period of fixation in a cylinder plaster is usually advised in all cases. Some advocate exploration, with reefing of the medial structures and release of those on the lateral side.

Recurrent lateral dislocation Further painful dislocations of the patella occur, often with increasing frequency and ease. Surgical stabilization is usually advised in the well established case, to reduce the risks of secondary patellofemoral osteoarthritis and prevent the danger that the patient might be exposed to should the dislocation occur in a hazardous situation. The type of procedure carried out is aimed at correcting the underlying defect, which should be established by investigation.

Congenital dislocation of the patella The patella may be dislocated at birth in association with congenital abnormalities. The dislocation is irreducible. Surgical correction is difficult, and the results often poor.

Habitual dislocation of the patella The patella dislocates every time the knee flexes, and this is pain free. It often arises in childhood and may be due to an abnormal attachment of the iliotibial tract. In a number of cases in the neonatal period it results from fibrosis in a quadriceps muscle which has been used for intramuscular injections. The condition also occurs in joint laxity syndromes. In the established case there is usually a severe associated deficiency of the trochlea. It may be treated by extensive lateral releases, medial reefing, and sometimes transposition of the tibial tubercle.

Permanent dislocation of the patella This is uncommon, and may result from an untreated childhood or adolescent dislocation. The patella is permanently displaced, and the power of the quadriceps and the strength of the knee are greatly reduced.

RETROPATELLAR/ANTERIOR KNEE PAIN SYNDROMES/ CHONDROMALACIA PATELLAE

These are characterized by chronic ill-localized pain at the front of the knee, often made worse by prolonged sitting, or walking on slopes or stairs. It is

commonest in females in the 15–35-year age group, and the pathology is often uncertain. In some there is softening or fibrillation of the articular cartilage lining the patella (chondromalacia patellae), and some of these cases progress to develop clear patellofemoral osteoarthritis.

Those suffering from retropatellar knee pain may be divided into two groups: in one no significant cause can be found, whereas in the other there is evidence of patellar malalignment. In this latter group some of the factors responsible for recurrent dislocation may be found to be present (even although there may be no history of frank dislocation). Although symptoms are often prolonged, they are usually not severe and may be dealt with by restriction of the activities known to aggravate the symptoms, and by physiotherapy. In some cases, where symptoms are particularly severe and unresponsive, and where there is evidence of malalignment, lateral release and patellar debridement procedures are often practised. Where the articular surface of the patella is seriously involved, patellectomy is sometimes advocated.

OSTEOCHONDRITIS DISSECANS

This occurs most frequently in males in the second decade of life, and most commonly involves the medial femoral condyle. Possibly as a result of impingement against the tibial spines or the cruciate ligaments, a segment of bone undergoes avascular necrosis, and a line of demarcation becomes established between this area and the underlying healthy bone. Complete separation may occur so that a loose body is formed. The symptoms are initially of aching pain and recurring effusion, with perhaps locking of the joint if a loose body is present. Good results generally follow conservative treatment with quadriceps exercises and continued weightbearing if the condition is found before epiphyseal closure. If the fragment becomes loose, it should be fixed surgically. If the lesion is long standing, with a fragment smaller than its crater, it should be excised. The cavity may be drilled in an attempt to encourage vascularization of its base. In all cases the damaging effects of a loose body must be prevented.

FAT PAD INJURIES

The infrapatellar fat pads may become tender and swollen and give rise to pain on extension of the knee, especially if they are nipped between the articulating surfaces of femur and tibia. This may occur as a complication of osteoarthritis, but is seen more frequently in young women when the fat pads swell in association with premenstrual fluid retention. Excision of the pads may be required to relieve the symptoms.

LOOSE BODIES

Loose bodies are seen most frequently as a sequel to osteoarthritis or osteochondritis dissecans. Much less commonly, numerous loose bodies are formed by an abnormal synovial membrane in the condition of synovial chondromatosis. Loose bodies are treated by excision, but synovectomy may be required in synovial chondromatosis if massive recurrence is to be avoided.

AFFECTIONS OF THE ARTICULAR SURFACES

OSTEOARTHRITIS (OSTEOARTHROSIS)

The stresses of weightbearing mainly involve the medial compartment of the knee, and it is in this area that primary osteoarthritis usually first occurs. This is an exceedingly common condition, arising without any obvious previous pathology in the joint. Overweight, the degenerative changes accompanying old age, and overwork are common factors. Secondary osteoarthritis may follow ligament and meniscus injuries, recurrent dislocation of the patella, osteochondritis dissecans, joint infections and other previous pathology. It is seen in association with knock-knee and bow-leg deformities, which throw additional mechanical stresses on the joint.

In osteoarthritis the articular cartilage undergoes progressive change, flaking off into the joint and thereby producing the narrowing that is a striking feature of radiographs of this condition. The subarticular bone may become eburnated, and often small marginal osteophytes and cysts are formed. Exposure of bone and free nerve endings gives rise to pain and crepitus on movement. Distortion of the joint surfaces is one cause of progressive loss of movement and fixed flexion deformities. Treatment is generally conservative, by quadriceps exercises, short-wave diathermy, analgesics and weight reduction. Surgery may be considered in severe cases. The procedures available include joint replacement, osteotomy (especially in cases of genu varum and valgum) and arthrodesis.

RHEUMATOID ARTHRITIS

Characteristically the knee is warm to touch, there is effusion, limitation of movements, muscle wasting, synovial thickening, tenderness and pain. Fixed flexion, valgus and (less commonly) varus deformities are quite common. Generally other joints are also involved, although the monoarticular form is occasionally seen. Active cases are often treated by synovectomy in an attempt to avoid or delay the progress of the condition. An acute flare-up of symptoms may be treated by temporary splintage. Either joint replacement, osteotomy or arthrodesis may be considered in well selected cases.

REITER'S SYNDROME

This usually presents as a chronic effusion accompanied by discomfort in the joint. It is often bilateral, with an associated conjunctivitis. There is often a history of urethritis or colitis.

ANKYLOSING SPONDYLITIS

The first symptoms of ankylosing spondylitis are generally in the spine, but occasionally the condition presents at the periphery, with swelling and discomfort in the knee joint. Stiffness of the spine and radiographic changes in the sacroiliac joints are nevertheless almost invariably present.

DISTURBANCES OF ALIGNMENT

GENU VARUM (BOW LEG)

This commonly occurs as a growth abnormality of early childhood, and usually resolves spontaneously. Rarely genu varum is caused by a growth disturbance involving both the tibial epiphysis and the proximal tibial shaft

(tibia vara), and treatment by osteotomy may be required. In adults this deformity most frequently results from osteoarthritis, where there is narrowing of the medial joint compartment. It also occurs in Paget's disease and rickets. It is less common in rheumatoid arthritis unless secondary osteoarthritic changes supervene in that condition.

GENU VALGUM (KNOCK KNEE)

This is seen most often in young children, where it is usually associated with flat foot. Nearly all cases resolve spontaneously by the age of 6. It is also seen in the plump adolescent girl, and it may be a contributory factor in recurrent dislocation of the patella. In adults it most frequently occurs as a result of the bone softening and ligamentous stretching accompanying rheumatoid arthritis. It occurs after uncorrected depressed fractures of the lateral tibial table, and as a sequel to a number of paralytic neurological disorders where there is ligament stretching and altered epiphyseal growth. Selected cases may be treated by corrective osteotomy.

GENU RECURVATUM

Hyperextension at the knee is seen after ruptures of the anterior cruciate ligament and in girls where the growth of the upper tibial epiphysis may be retarded from much pointe work in ballet classes or from the wearing of high-heeled shoes in early adolescence. In the latter cases there is corresponding elevation of the patella (patella alta) contributing to a tendency to recurrent dislocation. More rarely, the deformity is seen in congenital joint laxity, poliomyelitis and Charcot's disease.

BURSITIS

Cystic swelling occurring in the popliteal region in both sexes is usually referred to as enlargement of the semimembranosus bursa. In fact, several of the bursae known to the anatomist may be involved, either singly or together. The swelling sometimes communicates with the knee joint and may fluctuate in size. Rupture may lead to the appearance of bruising on the dorsum of the foot, and this may help to distinguish it from deep venous thrombosis or cellulitis. If there is any doubt about the diagnosis, or if the swelling is persistent and producing symptoms, excision is advised.

Fluctuant bursal swellings may also occur over the patella (prepatellar bursitis or housemaid's knee) or the patellar ligament (infrapatellar bursitis or clergyman's knee). Chronic prepatellar bursitis, with or without local infection, is common in miners, where it is referred to as 'beat knee'; it is also associated with other occupations where prolonged kneeling is unavoidable (e.g. it is common in plumbers and carpet layers). If the swelling is bulky or tense it is aspirated; recurrent swellings, if troublesome, are excised.

HOW TO DIAGNOSE A KNEE COMPLAINT

1. Note the patient's age and sex, bearing in mind the following important distribution of the common knee conditions (Table 10.1).

Age group	Males	Females
0–12	Discoid lateral meniscus	Discoid lateral meniscus
12–18	Osteochondritis dissecans	First incidents of recurrent dislocation of the patella
	Osgood-Schlatter's disease	Osgood-Schlatter's disease
18–30	Longitudinal meniscus tears	Recurrent dislocation of the patella
		Chondromalacia patellae
		Fat pad injury
30–50	Rheumatoid arthritis	Rheumatoid arthritis
40–55	Degenerative meniscus lesion	Degenerative meniscus lesion
45+	Osteoarthritis	Osteoarthritis

Table 10.1

Infections are comparatively uncommon and occur in both sexes in all age groups.

Reiter's syndrome occurs in adults of both sexes; ankylosing spondylitis nearly always occurs in adult males. Both are comparatively rare.

Ligamentous and extensor apparatus injuries occur in both sexes, but are rare in children.

2. Find out if the knee swells. An effusion indicates the presence of pathology, which must be determined. (Note, however, that the absence of effusion does not necessarily eliminate significant pathology.)

3. Try to establish whether there is a mechanical problem (internal derangement) accounting for the patient's symptoms. Do this by:

- (a) *Obtaining a convincing history of an initiating injury.* Note the degree of violence, and its direction. The initial incapacity is important. For example, a footballer is unlikely to be able to finish a game with a freshly torn meniscus. Note whether there was bruising or swelling after the injury, and whether the patient was able to weightbear.
- (b) *Asking if the knee 'gives way'.* 'Giving-way' of the knee on going down stairs or jumping from a height follows cruciate ligament tears, loss of full extension in the knee, and quadriceps wasting. 'Giving-way' on twisting movements or walking on uneven ground follows many meniscus injuries.
- (c) *Asking if the knee 'locks'.* Patients often confuse stiffness and true locking. Ask the patient to show the position the knee is in when and if it locks. *Remember that the knee never locks in full extension.* Locking due to a torn meniscus generally allows the joint to be flexed fully or nearly fully, but the last 10–40° of extension are impossible. Attempts to obtain full extension are accompanied by pain. Ask what produces any locking. With long-standing meniscus lesions a slight rotational force, such as the foot catching on the edge of a carpet, may be quite sufficient. In chronic lesions weightbearing is not an essential factor, locking not infrequently occurring during sleep. If the knee is not locked at the time of the patient's attendance, ask how it became free: unlocking with a click is suggestive of a meniscus lesion. Locking from a loose body may occur at varying positions of flexion. Locking from a dislocating patella may be noted to be accompanied by deformity.

- (d) *Asking about pain.* Find out the circumstances in which it is present and ask the patient if he can localize it by pointing to the site with one finger.

In a high proportion of cases the likely diagnosis will have been established by this stage, requiring only confirmation by clinical examination.

ADDITIONAL INVESTIGATIONS

Occasionally a firm diagnosis cannot be made on the basis of the history and clinical examination alone. The following additional investigations are often helpful.

Suspected internal derangement

- (a) *Arthroscopy* may give much useful information, and in conjunction with the clinical examination will permit a firm, accurate diagnosis to be made in the majority of cases. Incorrect diagnoses are most common in lesions involving the menisci in their posterior thirds. An increasing number of conditions are amenable to arthroscopic surgery, which can often follow diagnostic arthroscopy in the same session.
- (b) *MRI scans* These can be useful in diagnosing lesions of the menisci and ligaments, but it has been suggested that they should only be used if there is diagnostic uncertainty. An accuracy of 90% is claimed. However, there is often an increase in the signal intensity in the region of the posterior third of the medial meniscus (from the myxoid degeneration that may occur in the ageing process, or after previous surgery), and this can lead to false interpretations.
- (c) *Arthrography* may be helpful, although the interpretation of the radiographs is specialized and often difficult.
- (d) *Examination under anaesthesia* If pain prevents full examination (e.g. by preventing flexion) anaesthesia may be helpful. This is frequently followed by arthroscopy.
- (e) *Provocative exercises* These are carried out under the supervision of a trained physiotherapist. They aim to throw considerable stress on the menisci by applying torsional stresses to the weightbearing knee. If the meniscus has been damaged, the exercises are likely to be followed by localized pain, swelling, and sometimes even locking, so that any doubtful meniscus lesion is likely to declare itself.

Suspected acute infections

- (a) Aspiration and culture of the synovial fluid.
- (b) Blood culture.
- (c) Full blood count, including differential white count, and estimation of the sedimentation rate and C-reactive protein.

Suspected tuberculosis of the knee

- (a) Chest radiograph.
- (b) Synovial biopsy, with specimens of synovial membrane being sent for both histological and bacteriological examination. At the same time, synovial fluid specimens are also sent for bacteriology and sensitivities.
- (c) Mantoux test.

Suspected rheumatoid arthritis

- (a) Examination of other joints.
- (b) Estimations of rheumatoid factor.

- (c) Full blood count and sedimentation rate.
- (d) Serum uric acid.

Further investigation of poor mineralization, bone erosions etc.

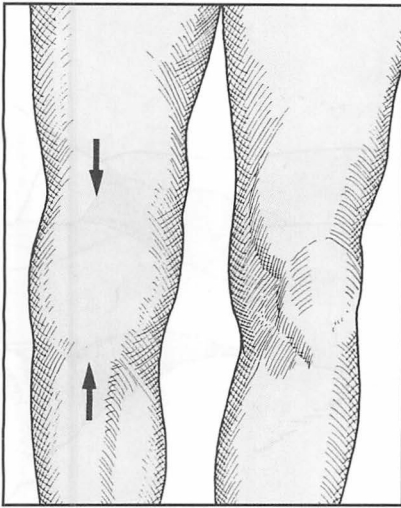
- (a) Estimation of serum calcium, phosphate and alkaline phosphatase.
- (b) Estimation of rheumatoid factor.
- (c) Serum uric acid.
- (d) Full blood count and differential count.
- (e) Skeletal survey and chest radiograph.
- (f) Radioisotope scan.
- (g) Bone biopsy.

Further investigation of chronic effusion, aspirate negative

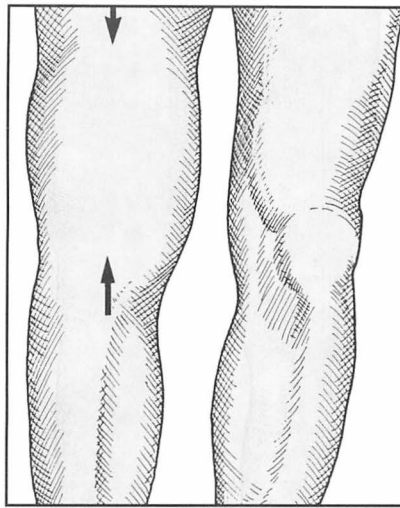
- (a) Tests as for suspected rheumatoid arthritis.
- (b) Brucellosis agglutination tests.
- (c) Radiography of the chest and sacroiliac joints.
- (d) Exploration and synovial biopsy.

Further investigation of severe undiagnosed pain

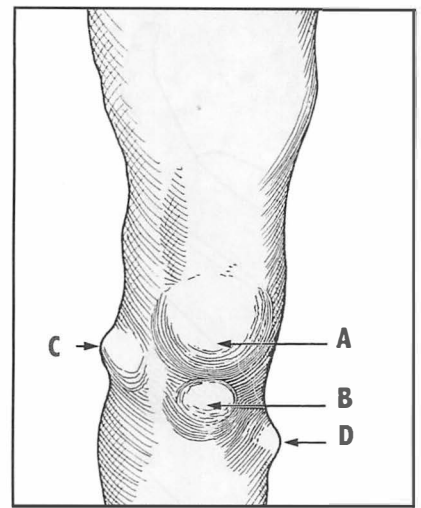
- (a) Radiography of the chest, pelvis and hips.
- (b) Exploration.



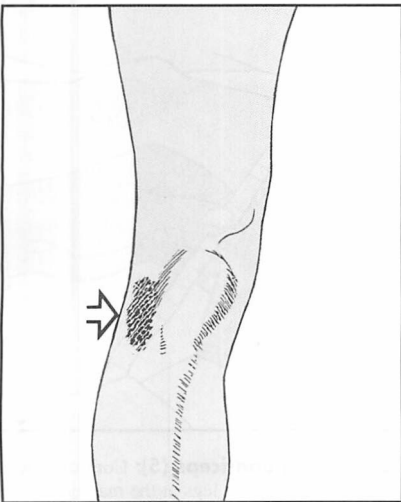
10.1. Swelling (1): Note the presence of swelling confined to the limits of the synovial cavity and suprapatellar pouch, suggesting effusion, haemarthrosis, pyarthrosis or a space-occupying lesion in the joint.



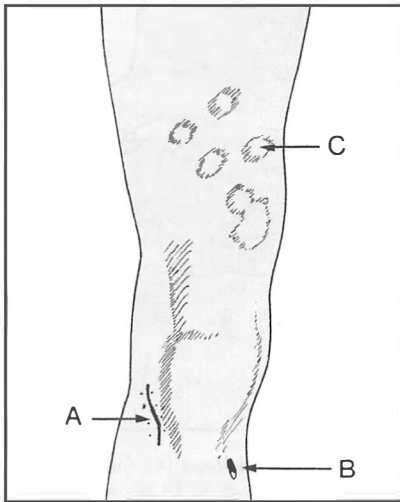
10.2. Swelling (2): Note whether the swelling extends beyond the limits of the joint cavity, suggesting infection (of the joint, femur or tibia), tumour or major injury.



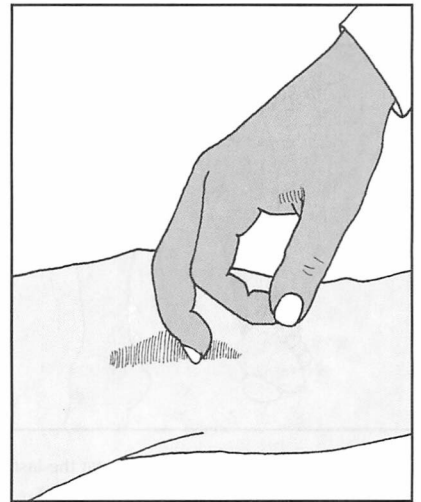
10.3. Lumps: Note presence of localized swellings, e.g. (A) prepatellar bursitis (housemaid's knee), (B) infrapatellar bursitis (clergyman's knee), (C) meniscus cyst (in joint line), (D) diaphyseal aclasis (exostosis, often multiple and sometimes familial). In beat knee (a common affliction in miners) there is chronic anterior bursal enlargement, often with thickening of the overlying skin.



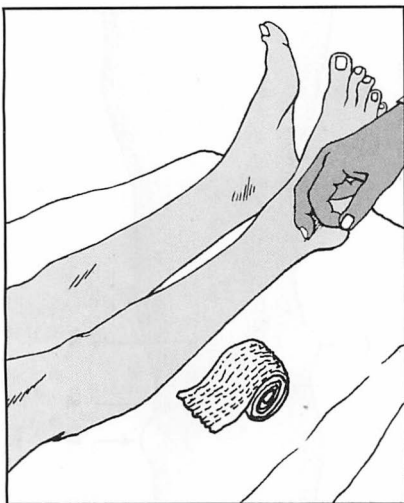
10.4. Discoloration: Note any bruising which suggests trauma to the superficial tissues or knee ligaments. Note that bruising is not usually seen in meniscus injuries. Note any redness suggesting inflammation.



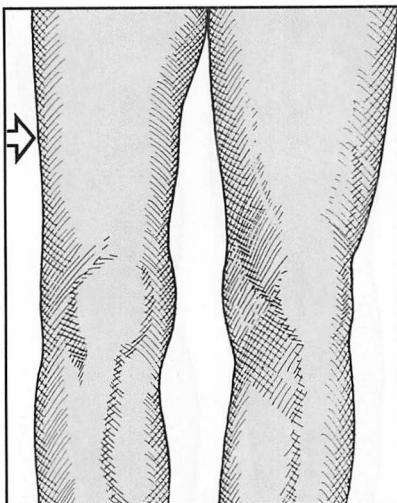
10.5. Skin marks: Note (A) scars due to previous injury or surgery: the relevant history must be obtained. (B) Sinus scars are indicative of previous infections, often of bone, and with the potential for reactivation. (C) Evidence of psoriasis, with the possibility of psoriatic arthritis.



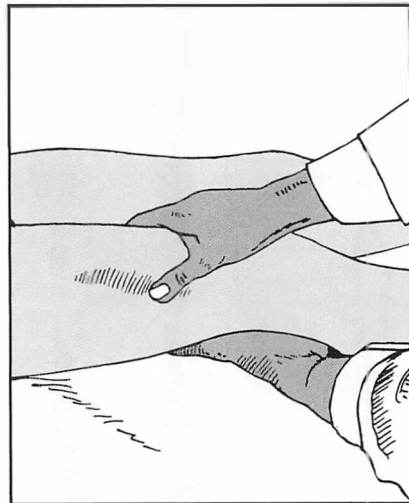
10.6. Temperature (1): Note any increased local heat and its extent, suggesting in particular rheumatoid arthritis or infection. There may also be increased local heat as part of the inflammatory response to injury, and in the presence of rapidly growing tumours. Always compare the two sides.



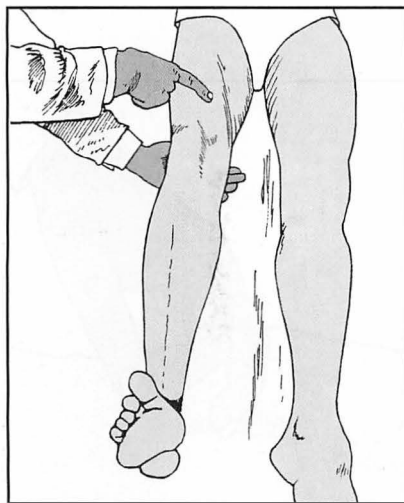
10.7. Temperature (2): A warm knee and cold foot suggest a popliteal artery block. Always make allowance for any warm bandage the patient may have been wearing just prior to the examination, and check the peripheral pulses.



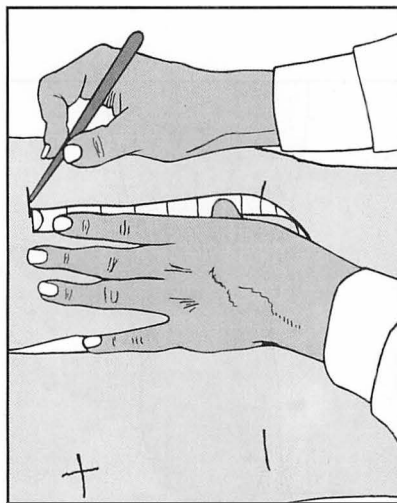
10.8. The quadriceps (1): Inspect the relaxed quadriceps muscle. Slight wasting and loss of bulk are normally apparent on careful inspection.



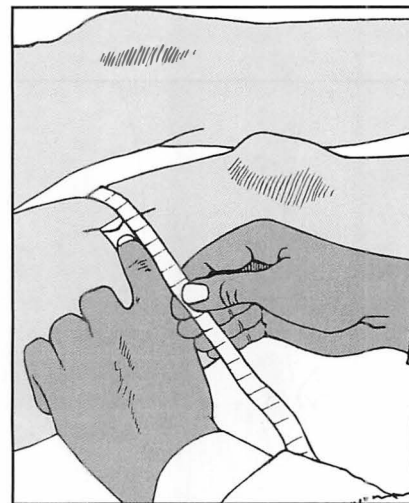
10.9. The quadriceps (2): Examine the contracted quadriceps. Place a hand behind the knee and ask the patient to press the leg against the hand. Feel the muscle tone with your free hand.



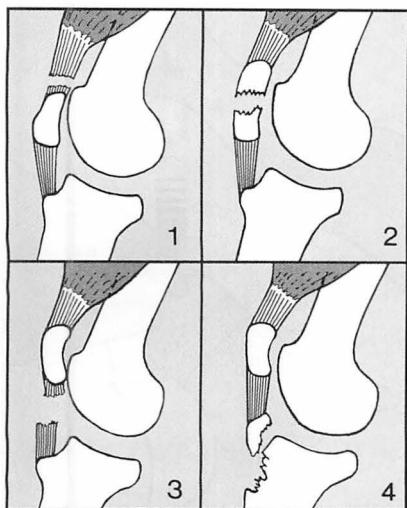
10.10. The quadriceps (3): Repeat the last test, this time asking the patient to dorsiflex the inverted foot. This demonstrates the important vastus medialis portion of the quadriceps, which may be involved in recurrent dislocation of the patella.



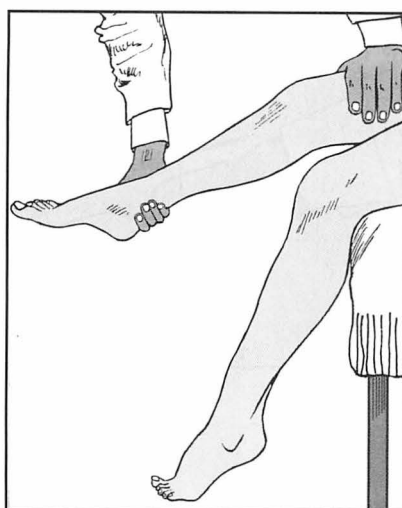10.11. The quadriceps (4): Substantial wasting, especially in the fat leg, may be confirmed by measurement, assuming the other limb is normal. This test, being objective, may be valuable for repeat assessments and in medicolegal cases. Begin by locating the knee joint (see later for details) and marking it with a ballpoint pen. Make a second mark on the skin 18 cm above this. Repeat on the other leg.



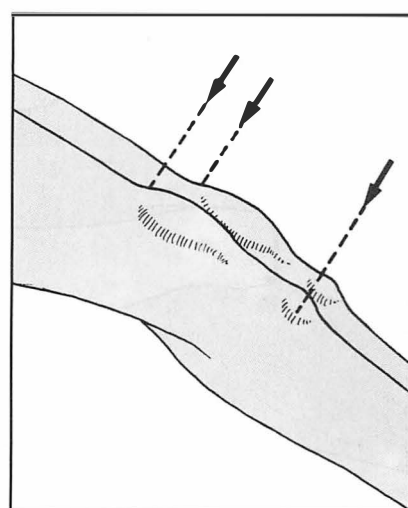
10.12. The quadriceps (5): Compare the circumference of the legs at the marked levels. Wasting of the quadriceps occurs most frequently as the result of disuse, generally from a painful or unstable lesion of the knee, or from infection or rheumatoid arthritis.



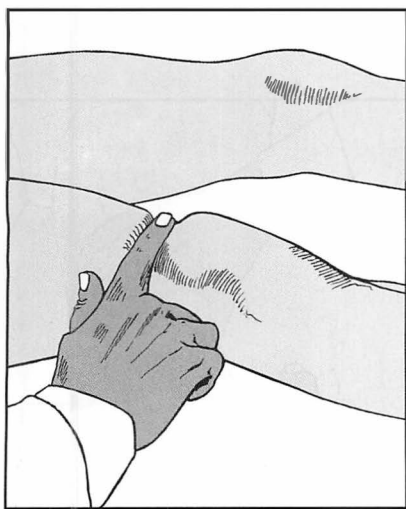
10.13. Extensor apparatus (1): Loss of active extension of the knee (excluding paralytic conditions) follows (1) rupture of the quadriceps tendon, (2) many patellar fractures, (3) rupture of the patellar ligament, (4) avulsion of the tibial tubercle.



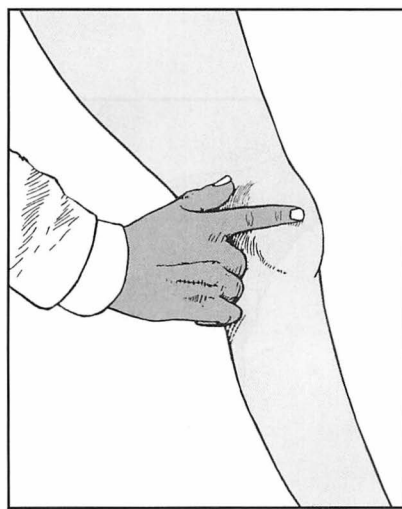
10.14. Extensor apparatus (2): With the patient sitting with his legs over the end of the examination couch, ask him to straighten the leg while you support the ankle with one hand. Feel for quadriceps contraction and look for active extension of the limb.



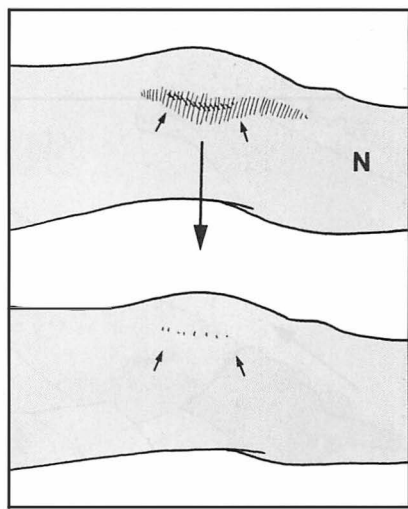
10.15. Extension apparatus (3): Note the position of the patella in relation to the joint line and the tibial tuberosity. If its upper border is high, this suggests that it is proximally displaced and that you should suspect lesions 2, 3 or 4.



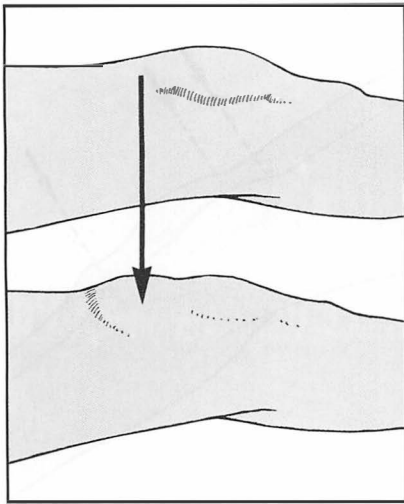
10.16. Extensor apparatus (4): If the patella is normally placed, lay a finger along its upper border. Loss of normal soft tissue resistance is suggestive of a rupture of the quadriceps tendon (1).



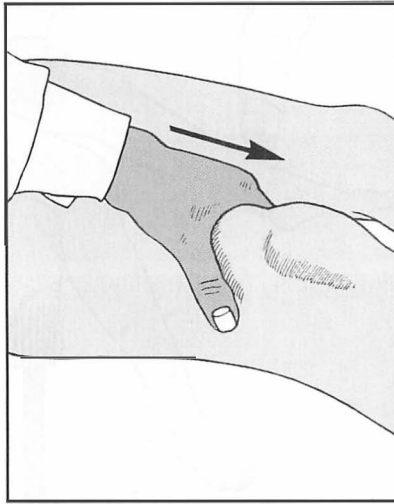
10.17. Extensor apparatus (5): Look for gaps and tenderness at the other levels to help differentiate between lesions 2, 3 and 4. Radiographs of the knee are essential.



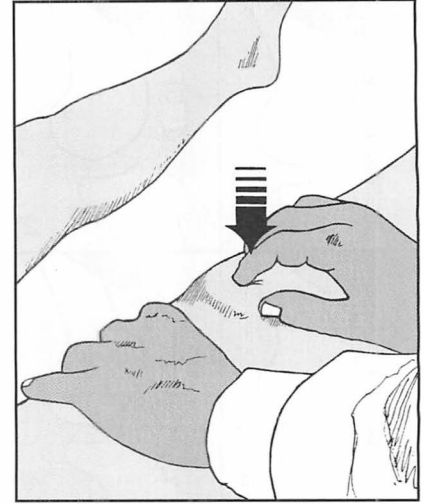
10.18. Effusion (1): Small effusions are detected most easily by inspection. The first signs are bulging at the sides of the patellar ligament and obliteration of the hollows at the medial and lateral edges of the patella.



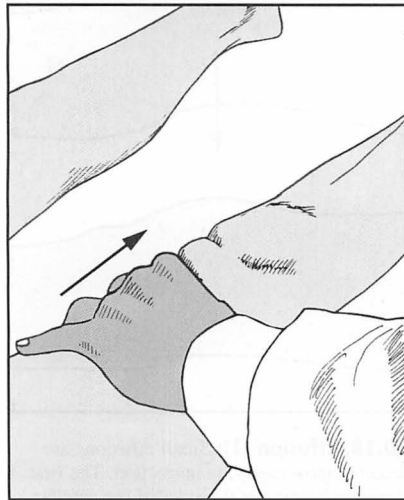
10.19. Effusion (2): With greater effusion into the knee the suprapatellar pouch becomes distended. Effusion indicates synovial irritation from trauma or inflammation.



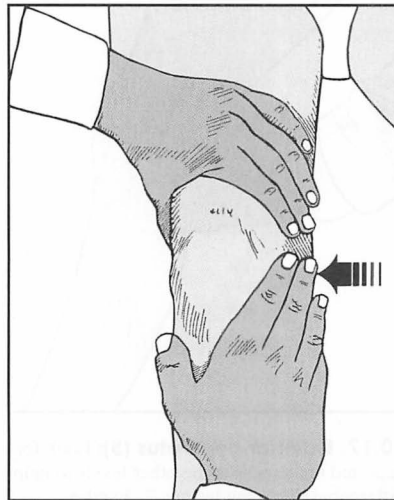
10.20. Effusion (3): Patellar tap test (ballottement test) (1): Squeeze any excess synovial fluid out of the suprapatellar pouch with the index and thumb, slid firmly distally from a point about 15 cm above the knee to the level of the upper border of the patella. This will also 'float' the patella away from the femoral condyles.



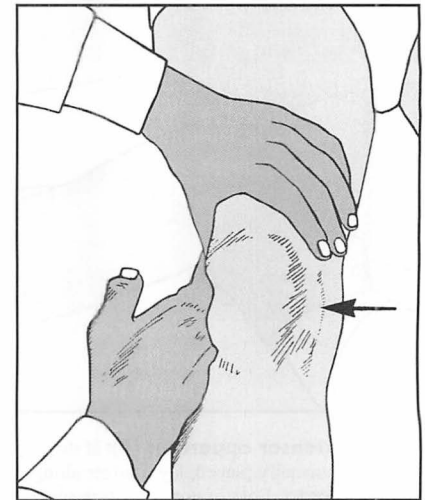
10.21. Effusion (4): Patellar tap test (2): Place the tips of the thumb and three fingers of the free hand squarely on the patella, and jerk it quickly downwards towards the femur. A click as the patella strikes the condyles indicates the presence of effusion. Note that if the patella is not properly steadied as described it will tilt, giving a false negative. Note too that if the effusion is *slight* or *tense*, the tap test will be *negative*.



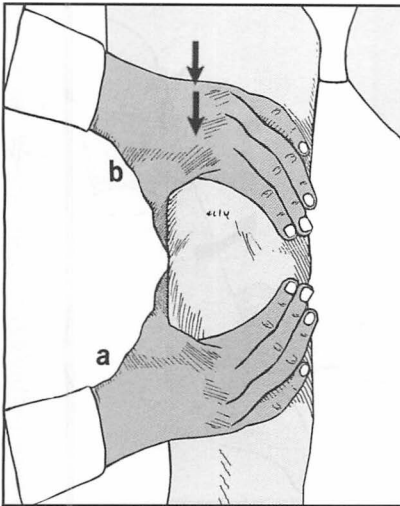
10.22. Effusion (5): Fluid displacement test (1): Small effusions may be detected by this manoeuvre. Evacuate the suprapatellar pouch as in the patellar tap test before.



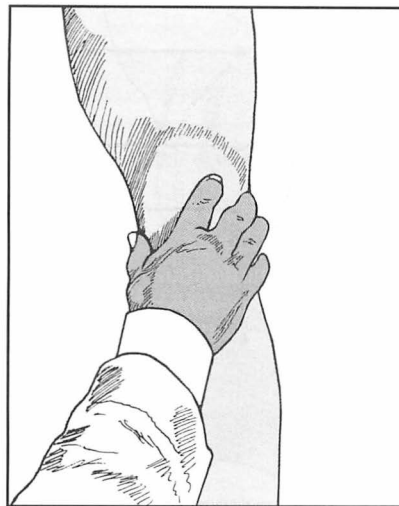10.23. Effusion (6): Fluid displacement test (2): Stroke the medial side of the joint to displace any excess fluid in the main joint cavity to the lateral side of the joint.



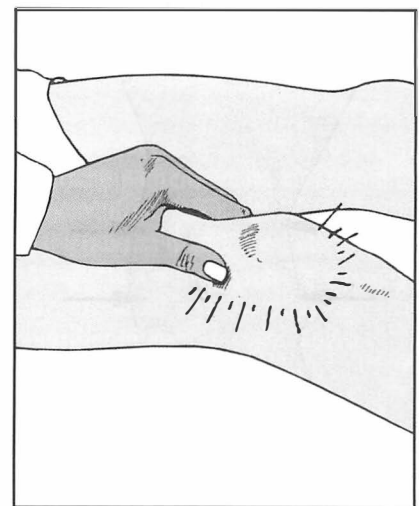
10.24. Effusion (7): Fluid displacement test (3): Now stroke the lateral side of the joint while watching the medial side closely. Any excess fluid present will be seen to move across the joint and distend the medial side. This test will be negative if the effusion is gross and tense.



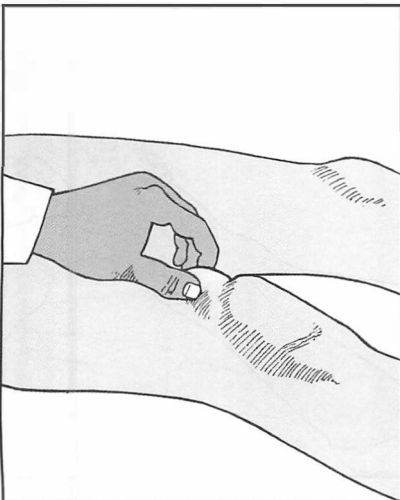
10.25. Effusion (8): Palpable fluid wave test: This can be useful in testing for larger effusions, especially in fat knees. With the thumb on one side of the joint and the fingers on the other (a), compress the knee to empty the hollows at the side of the joint. Now, with the other hand attempt to force fluid from the suprapatellar pouch distally into the knee (b). The force of any fluid being transmitted should be picked up by the compressing hand.



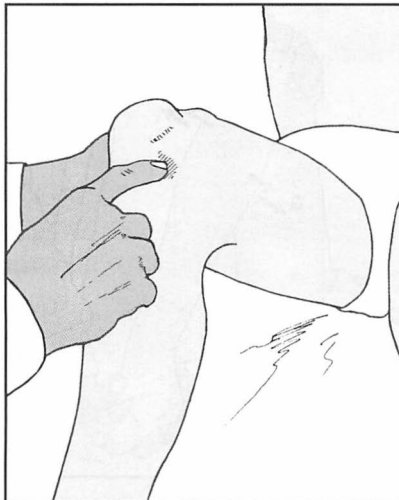
10.26. Haemarthrosis: A haemarthrosis is a sign of major joint pathology, is usually obvious within half an hour of injury, and gives a doughy feel in the suprapatellar region. A tense haemarthrosis should be aspirated to relieve pain and permit a more thorough clinical (and usually) arthroscopic examination.



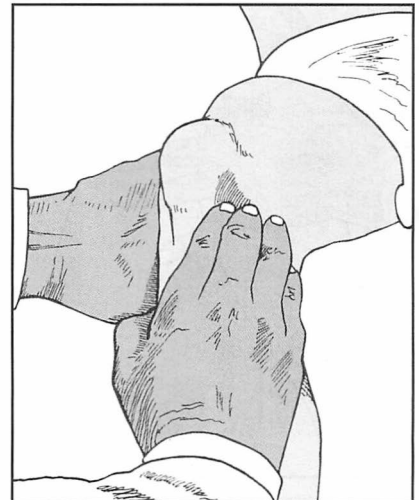
10.27. Pyarthrosis: Tenderness in pyarthrosis is usually widespread. There is generally a severe systemic upset, and quadriceps wasting. If pyarthrosis is suspected, the knee should always be aspirated to relieve painful and destructive joint pressure, and to obtain pus for elucidating the infecting agent and establishing antibiotic sensitivities.



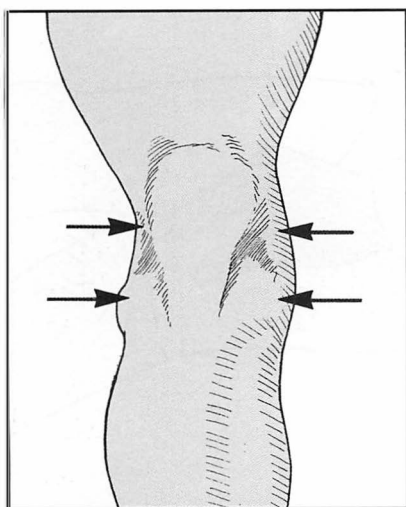
10.28. Synovial membrane: Pick up the skin and the relaxed quadriceps tendon to assess the thickness of the synovial membrane in the suprapatellar pouch. The synovial membrane is thickened in inflammatory conditions, e.g. rheumatoid arthritis, and in villonodular synovitis.



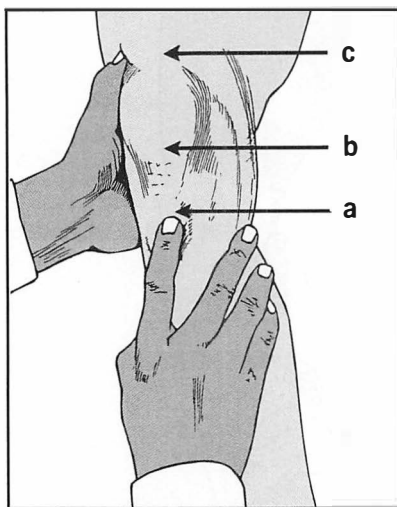
10.29. Tenderness (1): It is first essential to identify the joint line quite clearly. Begin by flexing the knee and looking for the hollows at the sides of the patellar ligament; these lie over the joint line. Then confirm this by feeling with the fingers or thumb for the soft hollow of the joint. When the examining finger is moved proximally it should rise out of the joint hollow on to the femoral condyle; similarly, when moved distally it should ride over the eminence of the tibia.



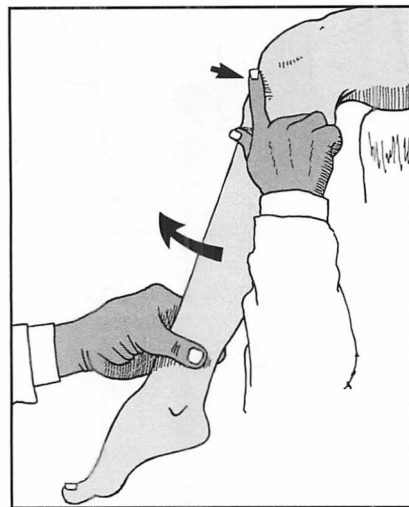
10.30. Tenderness (2): joint line structures: Begin by palpating carefully from in front back along the joint line on each side. Localized tenderness here is commonest in meniscus, collateral ligament and fat pad injuries.



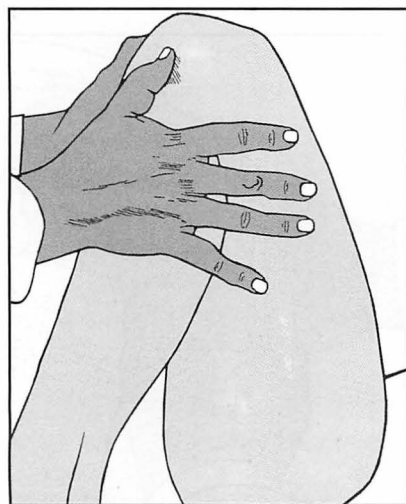
10.31. Tenderness (3): collateral ligaments: Now systematically examine the upper and lower attachments of the collateral ligaments. Associated bruising and oedema are a feature of acute injuries.



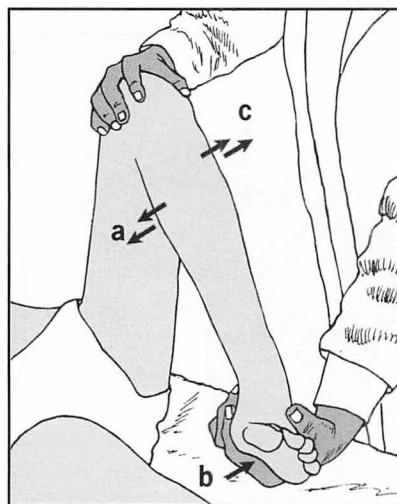
10.32. Tenderness (4): tibial tubercle: In children and adolescents, tenderness is found over the tibial tubercle (a), which may be prominent in Osgood–Schlatter's disease, and after acute avulsion injuries of the patellar ligament and its tibial attachment. Tenderness over the lower pole of the patella (b) and proximal patellar ligament is found in Sinding–Larsen–Johansson disease. Tenderness over the quadriceps tendon (c) is found in quadriceps tendinitis.



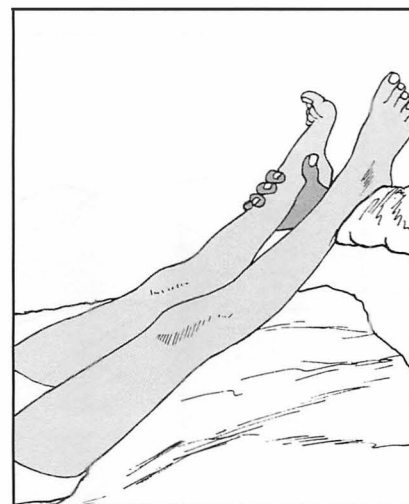10.33. Tenderness (5): Patellar ligament: Where in an athletic patient a problem with the patellar ligament is suspected, look for patellar ligament tenderness while the patient is attempting to extend the leg against resistance. This test is best performed with the leg over the end of the examination couch.



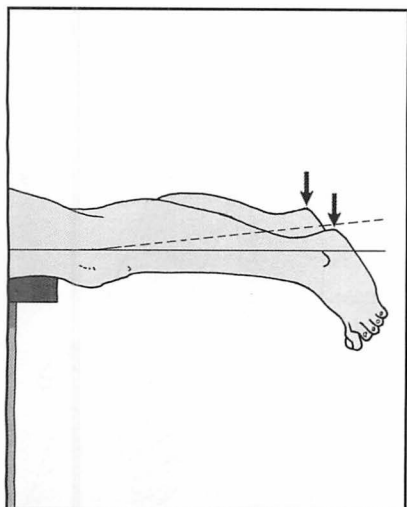
10.34. Tenderness (6): Femoral condyles: suspected osteochondritis dissecans (1): Flex the knee fully and look for tenderness over the femoral condyles. Osteochondritis dissecans most frequently involves the medial femoral condyles, and particular attention should therefore be paid to the medial side.



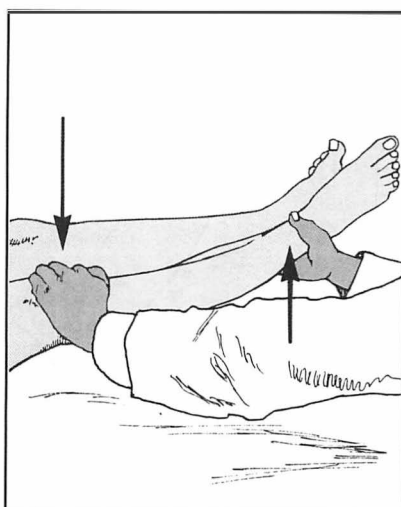
10.35. Suspected osteochondritis dissecans (2): Wilson's test: The aim of the test is to cause pressure between the anterior cruciate ligament and the lateral aspect of the medial femoral condyle. Flex the knee (a) and internally rotate the foot (b). Now extend the knee fully (c). If pain occurs at full extension and is relieved by external rotation of the foot, then the test is positive.



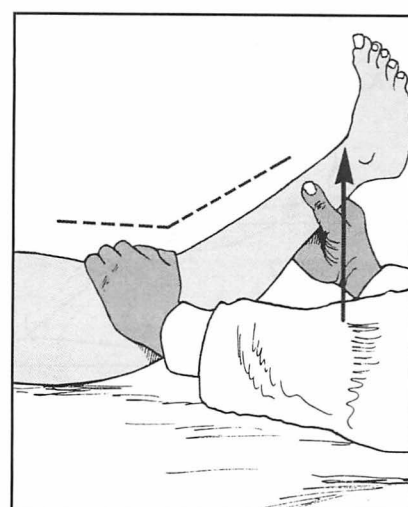
10.36. Movements (1): Extension: First make sure that the knee can be fully extended. If in doubt, lift both legs and sight along the good and affected leg. Full extension is recorded as 0°. Loss of full extension may be recorded as 'The knee lacks X° of extension'.



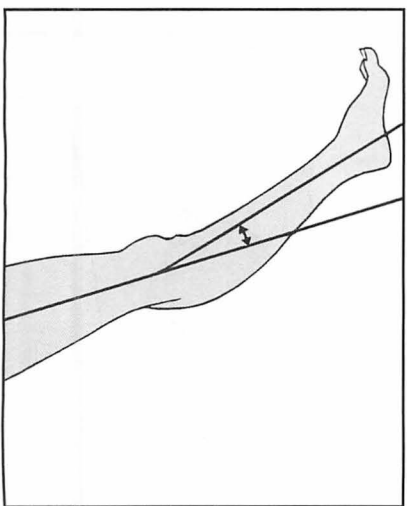
10.37. Movements (2): Extension: If there is still some doubt, examine the patient in the prone position, fully relaxed, and with his legs hanging over the edge of the examination couch. Any loss of extension on one side should be obvious from the position of the heels.



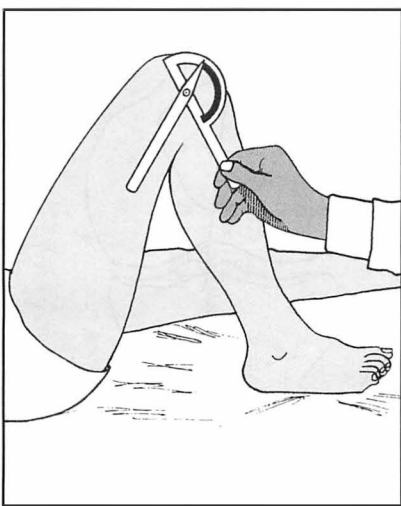10.38. Movements (3): Extension: Try to obtain full extension if this is not obviously present. A springy block to full extension is very suggestive of a bucket-handle meniscus tear. A rigid block to full extension (commonly described as a fixed flexion deformity) is often present in arthritic conditions affecting the knee.



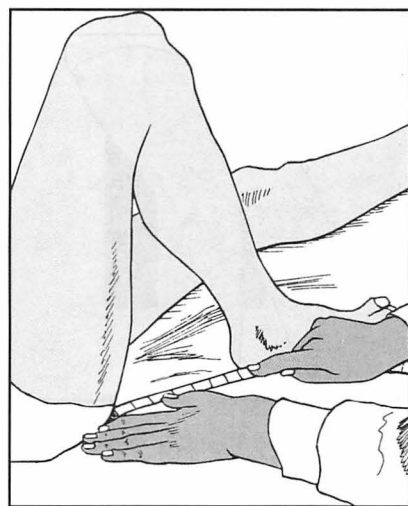10.39. Movements (4): Hyperextension (genu recurvatum): This is present if the knee extends beyond the point when the tibia and femur are in line. Attempt to demonstrate this by lifting the leg while at the same time pressing back on the patella. If severe, look for other signs of joint laxity, particularly in the elbow, wrist and fingers, keeping in mind the rare Ehlers-Danlos syndrome.



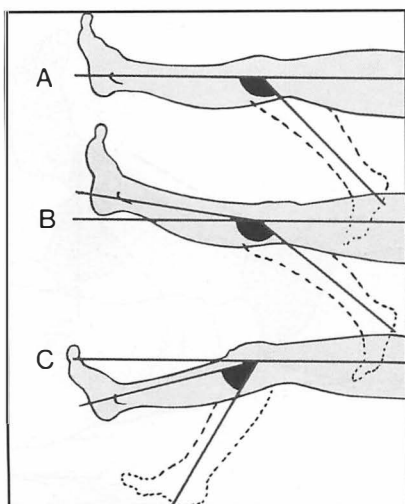
10.40. Movements (5): Hyperextension. if present, is recorded as 'X° hyperextension'. It is seen most frequently in girls, and is often associated with a high patella, chondromalacia patellae, recurrent dislocation of the patella, and sometimes tears of the anterior cruciate, medial ligament, or medial meniscus.




10.41. Movements (6): Flexion (1): Measure the range of flexion in degrees, starting from the zero position of normal full extension. Flexion of 135° and over is regarded as normal, but compare the two sides. There are many causes of loss of flexion, the commonest of which are effusion and arthritic conditions.



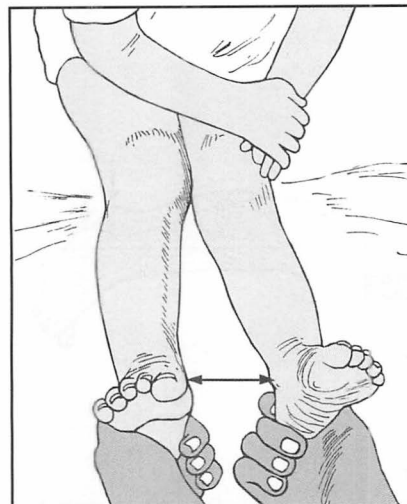
10.42. Movements (7): Flexion (2): Alternatively, measure the heel-to-buttock distance with the leg fully flexed. This can be a very accurate way of detecting small alterations in the range (1 cm = 1.5° approximately) and is useful for checking daily or weekly progress. Note that obviously flexion can never be greater than when the heel contacts the buttock, and that inability to bring the heel to the buttock is not necessarily an indicator of flexion loss (135° is less than this).



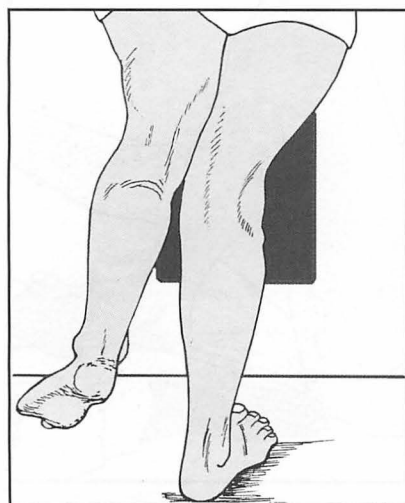
10.43. Movements (8): Recording: The range of movements in the examples illustrated would be recorded as follows: (A) 0–135° (normal range); (B) 5° hyperextension – 140° flexion; (C) 10–60° (or 10° fixed flexion deformity with a further 50° flexion).



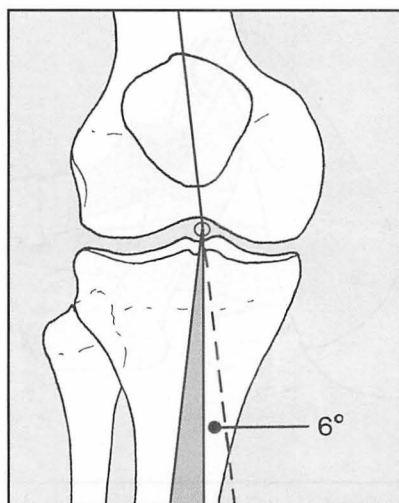
10.44. Genu valgum (knock knee) in children (1): Note whether unilateral or bilateral; the latter is more common. The severity of the deformity is recorded by measuring the intermalleolar gap. Grasp the child by the ankles and rotate the legs until the patellae are vertical.



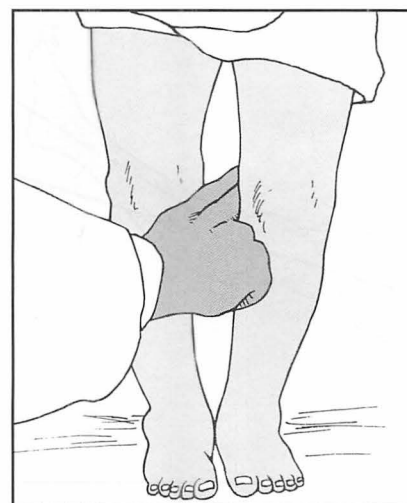
10.45. Genu valgum in children (2): Now bring the legs together to touch *lightly* at the knees, and measure the gap between the malleoli. (Normally the knees *and* malleoli should touch). Serial measurements, often every 6 months, are used to check progress. Note that with growth a static measurement is an angular improvement. In the 10–16-year age group < 8 cm in females and < 4 cm in males is regarded as normal.



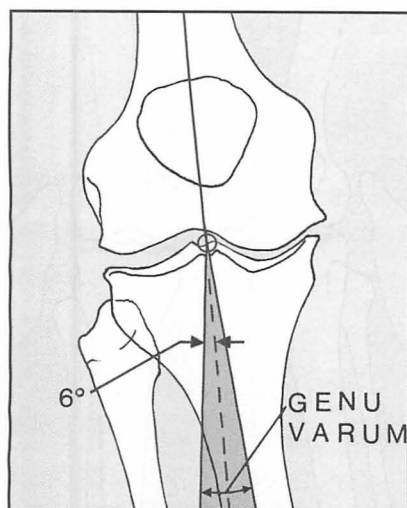
10.46. Genu valgum in adults (1): In adults the deformity is seen most often in association with rheumatoid arthritis. It is also common in teenage girls. It is best measured by X-rays, and the films should be taken with the patient taking all his weight on the affected side.



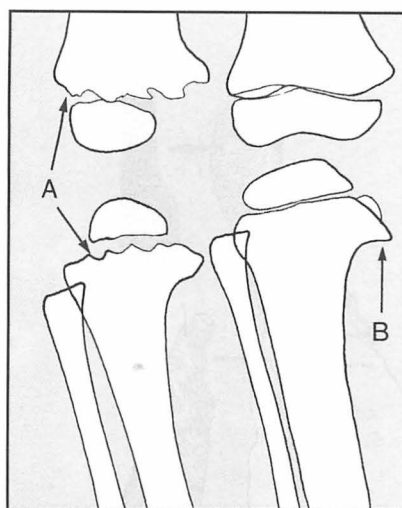
10.47. Genu valgum in adults (2): The degree of valgus may be roughly assessed by measuring the angle formed by the tibial and femoral shafts. Allow for the 'normal' angle, which is approximately 6° in the adult. The shaded area represents genu valgum. (Note that the tibiofemoral angle is virtually the same as the Q angle used in the assessment of patellar instability.)



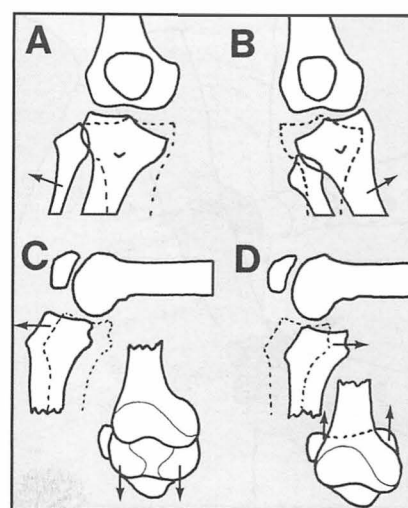
10.48. Genu varum (bow leg) (1): Measure the distance between the knees, using the fingers as a gauge. Ideally the patient should be weightbearing, and it is essential that both patellae should be facing forwards to counter any effect of hip rotation. In the 10–16-year age group, < 4 cm in females and < 5 cm in males is regarded as being within normal limits.



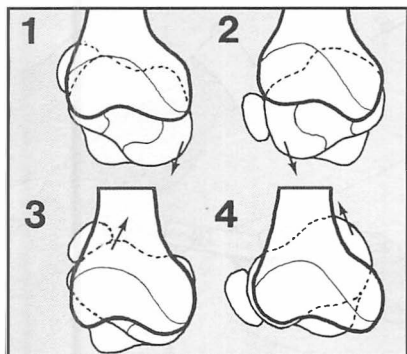
10.49. Genu varum (2): An assessment of the deformity may also be carried out with X-rays, as in genu valgum, with the patient weightbearing during the exposure of the films. The deformity is seen most commonly in osteoarthritis and Paget's disease. It may occur in rheumatoid arthritis, although genu valgum is commoner in that condition.



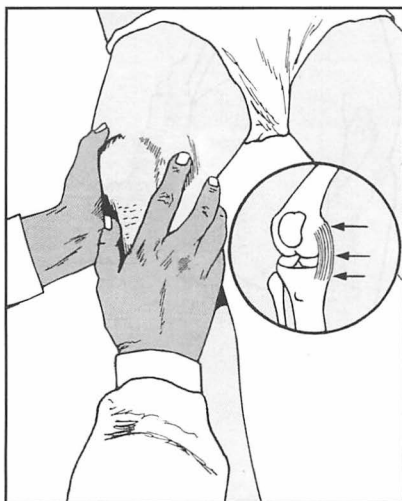
10.50. Genu varum (3): In children, radiography may be helpful. In (A) *rickets*, note the wide and irregular epiphyseal plates. In (B) *tibia vara*, note the sharply downturned medial metaphyseal border. Note that radiological varus is normal till a child is 18 months old.



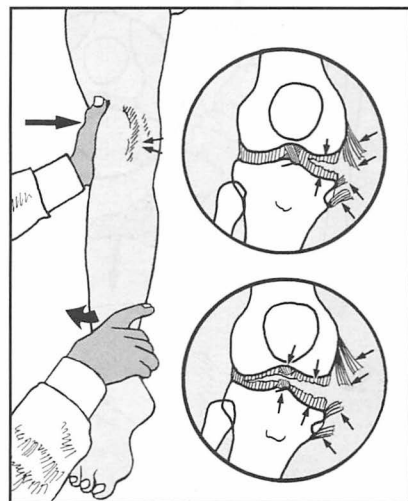
10.51. Instability (1): The following potential deformities may be looked for: (A) *valgus* (when the medial ligament is torn: severe when the posterior cruciate is also damaged); (B) *varus* (when the lateral ligament is torn: severe when the posterior cruciate is also torn); (C) *anterior displacement of the tibia* (anterior cruciate tears: worse if medial and/or lateral structures torn); (D) *posterior displacement of the tibia* (posterior cruciate ligament tears).



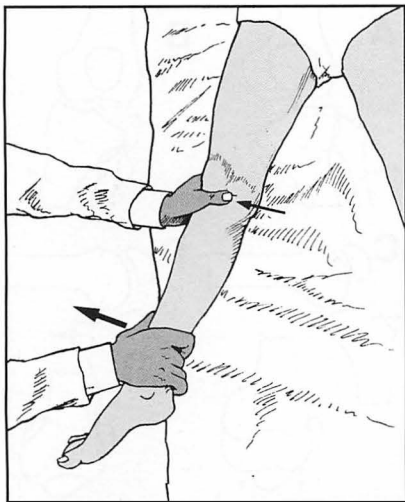
10.52. Instability (2): (E) Rotatory: (1) *The medial tibial condyle subluxes anteriorly* (anteromedial instability): this is usually due to combined tears of the anterior cruciate and medial structures; (2) *the lateral condyle subluxes anteriorly* (anterolateral instability): this is usually due to tears of the anterior cruciate plus the lateral structures; (3) *the lateral tibial condyle subluxes posteriorly* (posterolateral instability) or (4) *the medial tibial condyle subluxes posteriorly* (posteromedial instability). (3) and (4) are due mainly to tears of the posterior cruciate and lateral or medial structures. (5) Combinations of these instabilities.



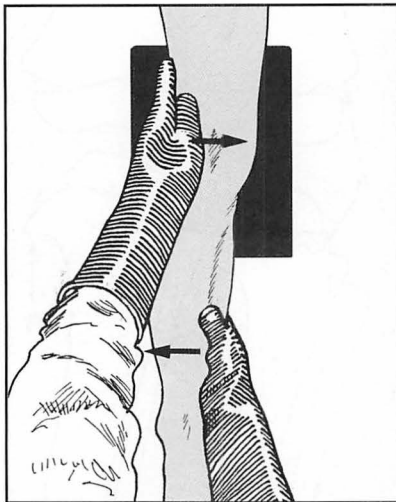
10.53. Valgus stress instability (1): Begin by examining the medial side of the joint, and the medial ligament in particular. *Tenderness* in injuries of the medial ligament is commonest at the upper (femoral) attachment and in the medial joint line. *Bruising* may be present after recent trauma, but haemarthrosis may be absent. (Where the medial ligament has been injured and displays tenderness without laxity it may be classified as a grade 1 injury.)



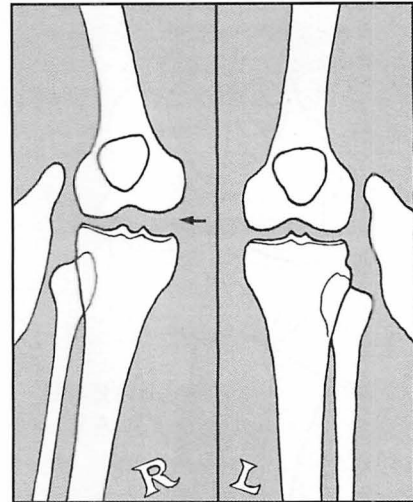
10.54. Valgus stress instability (2): Extend the knee fully. Use one hand as a fulcrum, and with the other attempt to abduct the leg. Look for the joint opening up and the leg going into valgus. On release of the valgus force a confirmatory clunk may be felt. *Moderate valgus* is suggestive of a major medial and posterior ligament rupture (grade 2 injury). *Severe valgus* may indicate additional cruciate (particularly posterior cruciate) rupture (grade 3 injury).



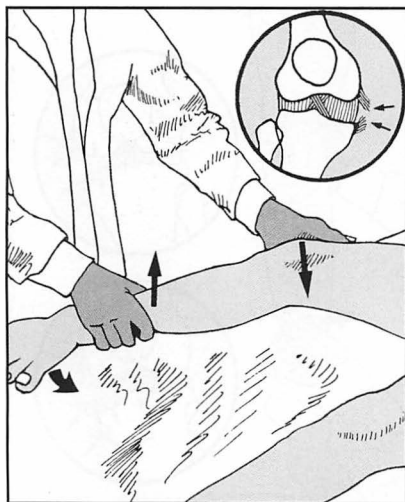
10.55. Valgus stress instability (3): If in doubt, use the heel of the hand as a fulcrum and use the thumb or index, placed in the joint line, to detect any opening up of the joint as it is stressed. If there is still some uncertainty, compare the two sides.



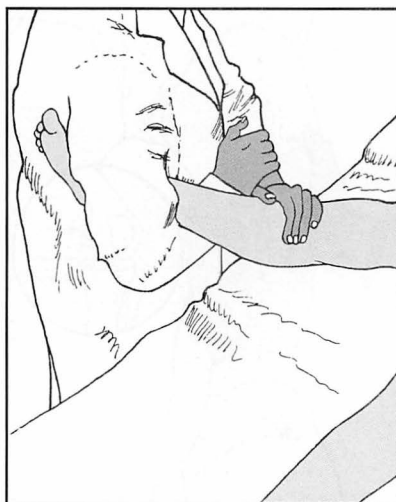10.56. Valgus stress instability (4): stress films (1): If there is still some doubt, then radiographs of both knees should be taken while applying a valgus stress to each joint.



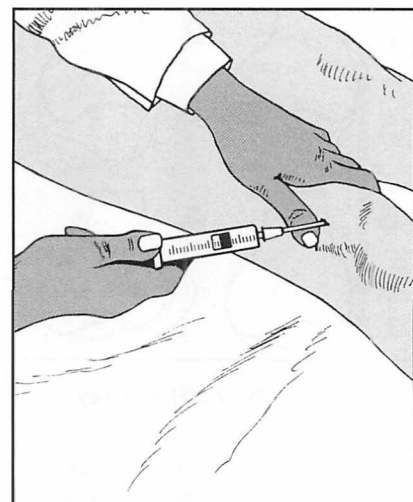
10.57. Valgus stress instability (5): stress films (2): The films of both sides are then compared. Any instability should be obvious.



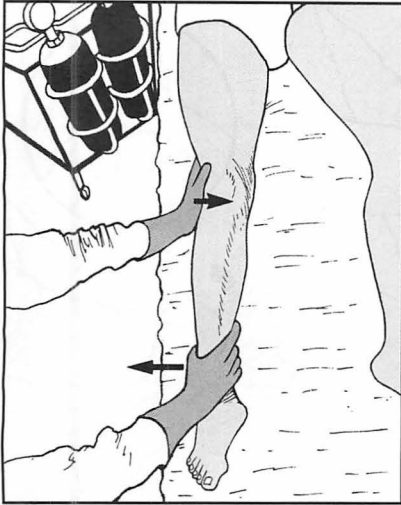
10.58. Valgus stress instability (6): If no instability has been demonstrated with the knee fully extended, repeat the tests with the knee flexed to 20° and the foot internally rotated. Some opening up of the joint is normal, and it is essential to compare the sides. Demonstration of an abnormal amount of valgus suggests less extensive involvement of the medial structures (e.g. partial medial ligament tear, still classified as a grade 2 injury).



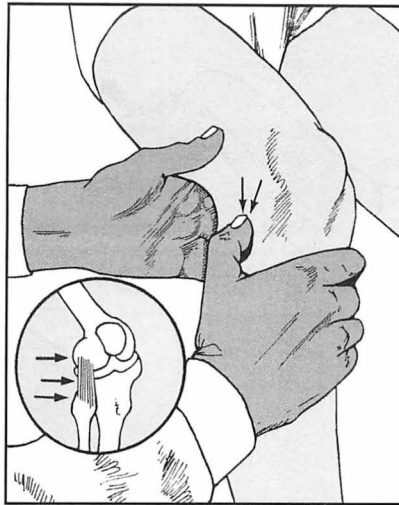
10.59. Valgus stress instability (7): If the knee is very tender and will not permit the pressure of a hand as a fulcrum, attempt to stress the ligament with this crossover arm grip, with one hand placed over the proximal part of the tibia just distal to the knee joint to avoid any local pressure over the joint and its ligaments.



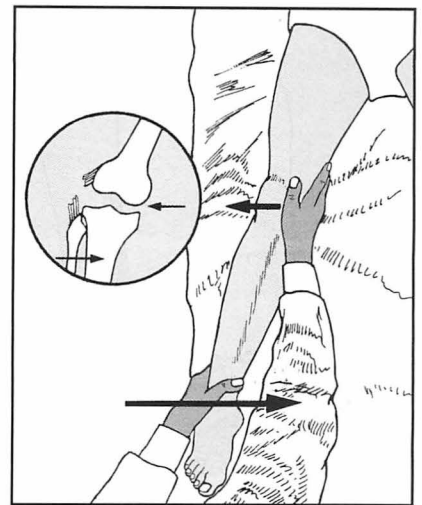
10.60. Valgus stress instability (8): If a haemarthrosis is present (and this is not always the case) preliminary aspiration may allow a more meaningful examination of the joint.



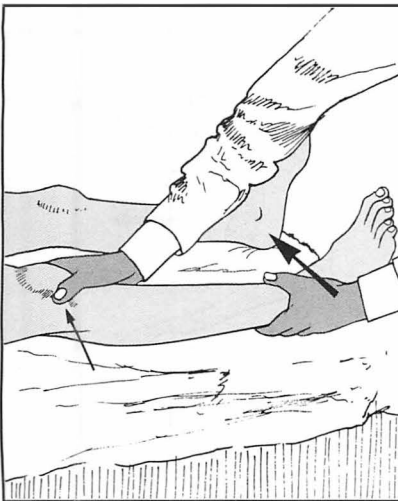10.61. Valgus stress instability (9): If the knee remains too painful to permit examination, the joint should be fully tested under anaesthesia; there should be provision to carry on with a surgical repair should major instability be demonstrated (i.e. where several major structures are involved), or with an arthroscopy.



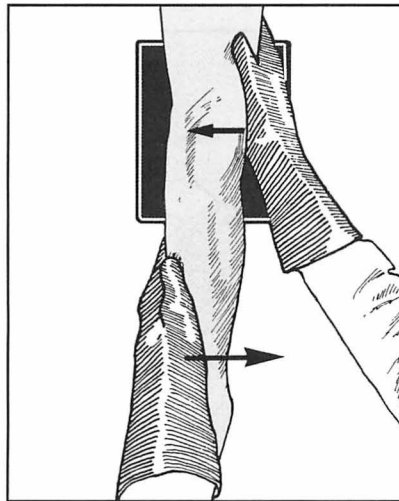
10.62. Varus stress instability (1): Begin by examining the lateral side of the joint. Tenderness is most common over the head of the fibula or in the lateral joint line in acute injuries of the lateral joint complex (lateral ligament and capsule).




10.63. Varus stress instability (2): Attempt to produce a varus deformity by placing one hand on the medial side of the joint and forcing the ankle medially. Carry out the test as in the case of valgus stress instability, first in full extension and then in 30° flexion, and compare one side with the other. Note that when testing the lateral ligament, in the normal knee there is a little more 'give' than with the medial.



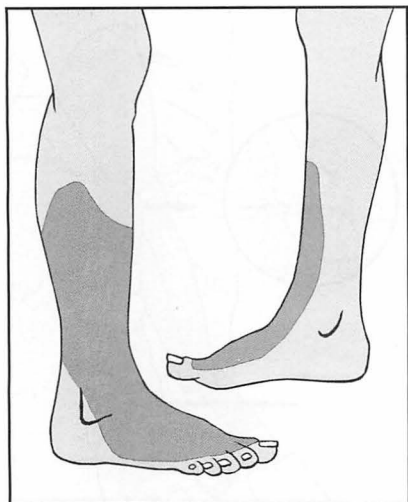
10.64. Varus stress instability (3): Again, for a more sensitive assessment of 'give', the thumb can be placed in the joint line. If there is varus instability in extension as well as flexion, it suggests tearing of the posterior cruciate ligament as well as the lateral ligament complex.



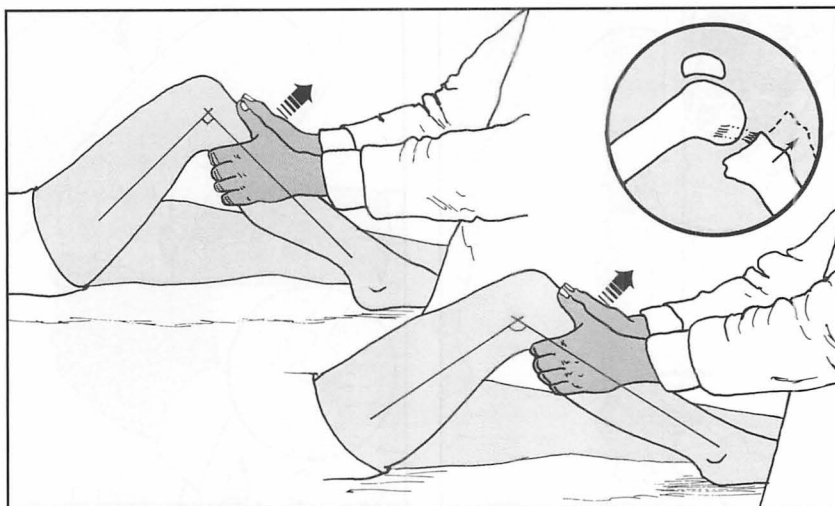
10.65. Varus stress instability (4): As in the case of valgus stress instability stress films may be taken, and if examination is not possible even after aspiration, arrange to examine the knee under general anaesthesia.



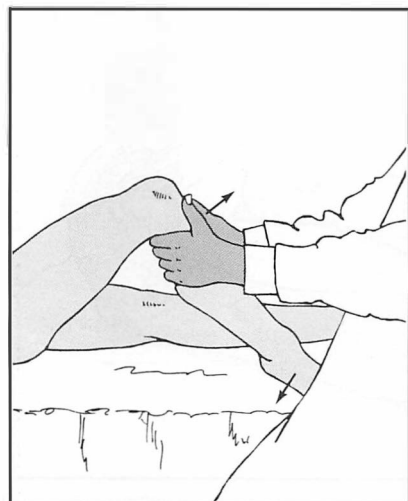
10.66. Varus stress instability (5): Always check that the patient is able to dorsiflex the foot, to ensure that the motor fibres in the common peroneal nerve (lateral popliteal) have escaped damage.



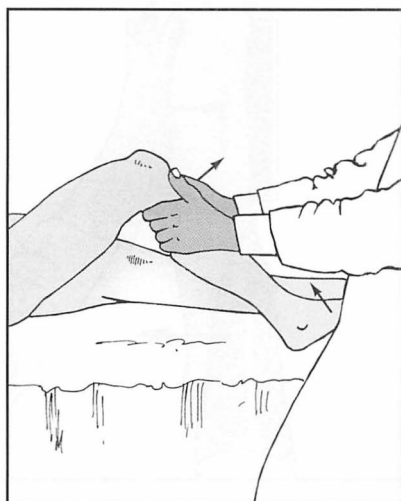
10.67. Varus stress instability (6): In addition, test for sensory disturbance in the distribution of the common peroneal nerve.



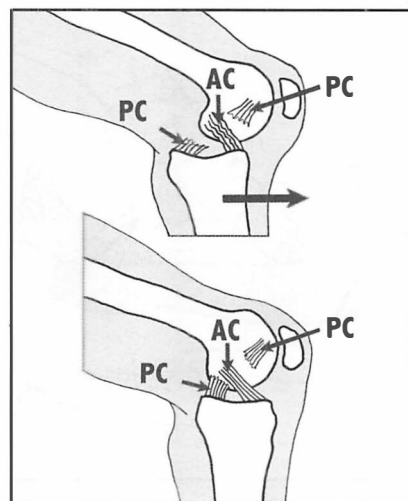
10.68. The anterior drawer test (1): Flex the knee to 90°, with the foot pointing straight forwards, and steady it by sitting close to it. Grasp the leg firmly with the thumbs on the tibial tubercle. Check that the hamstrings are relaxed, and jerk the leg towards you. Repeat with the knee flexed to 70° and compare the sides. Note: significant displacement (i.e. the affected side more than the other) confirms anterior instability of the knee. Note also that in tears the endpoint of the anterior translation is usually softer and less clearly defined than the firm endpoint when the ligament is intact. When the displacement is marked (say 1.5 cm or more) then the anterior cruciate is almost certainly torn, and there is a strong possibility of associated damage to the medial complex (medial ligament and medial capsule) and even the lateral complex. If the displacement is less marked, and one tibial condyle moves further forward than the other, then the diagnosis is less clear: it may suggest an isolated anterior cruciate ligament laxity or a tibial condylar subluxation (rotatory instability).



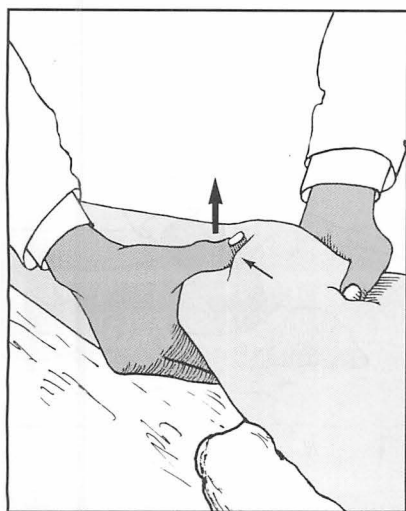
10.69. The anterior drawer test (2): Repeat the test with the foot in 15° of external rotation. Excess excursion of the medial tibial condyle suggests a degree of anteromedial (rotatory) instability, with possible involvement of the medial ligament as well as the anterior cruciate ligament.



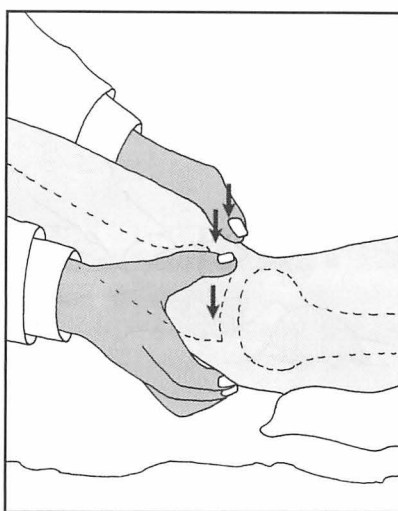
10.70. The anterior drawer test (3): Now turn the foot into 30° of internal rotation and repeat the test. Anterior subluxation of the lateral tibial condyle suggests some anterolateral rotational instability, with possibly damage to the posterior cruciate and the posterior ligament as well as the anterior cruciate ligament.



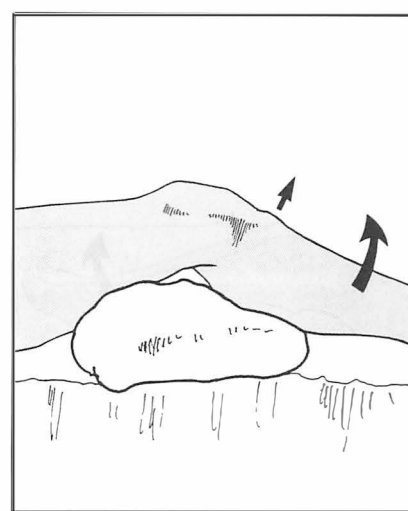
10.71. The anterior drawer test (4): Beware of the following fallacy: a tibia already displaced backwards as a result of a posterior cruciate ligament tear may give a false positive in this test. This also applies to the Lachman tests described in the following frames. Check by inspecting the contours of the knee prior to testing.



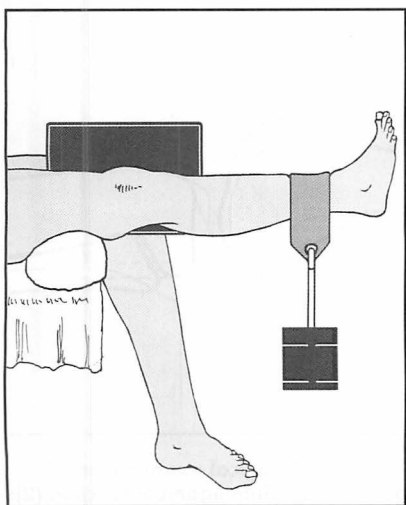
10.72. The Lachman tests (1): The Lachman tests are also used to detect anterior tibial instability. In the *manipulative Lachman test*, the knee should be relaxed and in about 15° flexion. One hand stabilizes the femur while the other tries to lift the tibia forwards. The test is positive if there is anterior tibial movement (detected with the thumb in the joint), with a spongy endpoint. The test is sometimes easier to perform with the patient prone (see next frame).



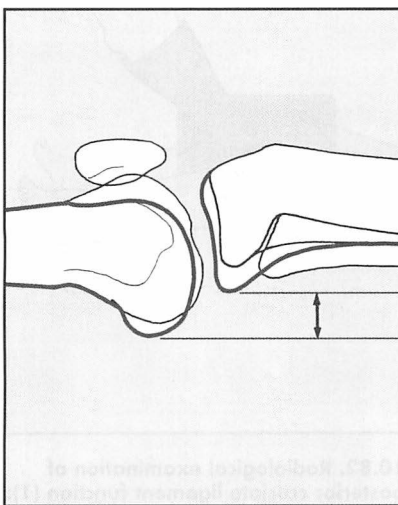
10.73. The Lachman tests (2): The prone test (Feagin and Cooke): This is especially useful where the patient has large thighs which are difficult to grasp. With the patient prone, encircle the tibia with both hands, placing the index fingers and thumbs in the joint line. Flex the knee to 20° and attempt to push the tibia forwards. Anterior translation should be readily detected by the fingers, and the firmness of the endpoint should be noted.



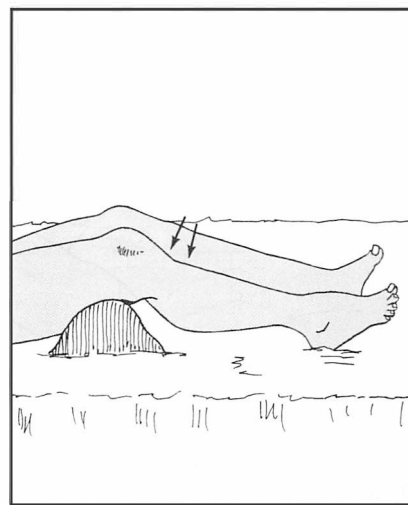
10.74. The Lachman tests (3): In the *active Lachman test* the relaxed knee is supported at 30° and the patient asked to extend it. If the test is positive, there will be anterior subluxation of the lateral tibial plateau as the quadriceps contracts, and posterior subluxation when the muscle relaxes. It is considered that this is best seen from the medial side. Repeat, resisting extension by applying pressure to the ankle.



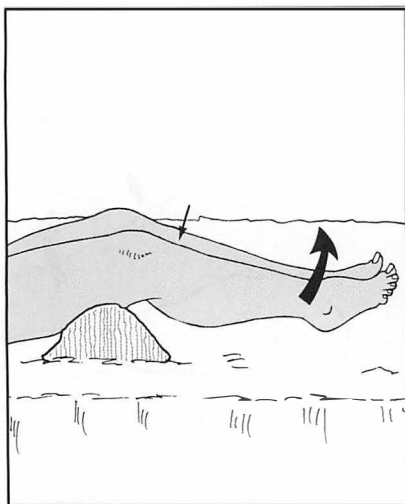
10.75. Radiological analysis of anterior cruciate function (1): Anterior subluxation of the tibia in extension may also be demonstrated with X-rays. The lower thigh is supported by a sandbag, and the leg extended against the resistance of a 7 kg weight. The limb should be in the neutral position, with the patella pointing upwards, and the X-ray film cassette placed between the legs.



10.76. Radiological analysis (2): On the films, draw two lines parallel to the posterior cortex of the tibia, tangential to the medial tibial plateau and the medial femoral condyle. Measure the distance between them. **Normal = 3.5 mm ± 2 mm. Ruptured anterior cruciate = 10.2 mm ± 2.7 mm.** The latter is slightly increased if the medial meniscus is also torn. The diagnostic reliability is high.

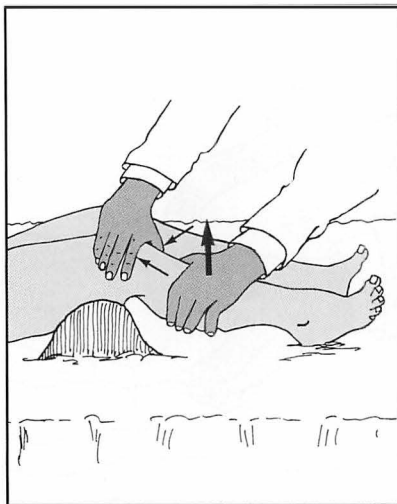


10.77. Posterior tibial instability: testing the posterior cruciate ligament (1): the gravity test: Rupture, detachment or stretching of the posterior cruciate ligament may permit the tibia to sublux backwards, frequently giving rise to a striking deformity of the knee which allows the diagnosis to be made on inspection alone. The knee should be flexed to 20°, with a sandbag under the thigh.



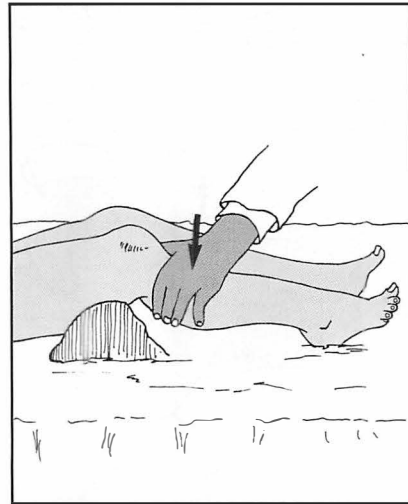
10.78. Posterior cruciate ligament (2):

With the leg still in 20° flexion, ask the patient to lift the heel from the couch while you observe the knee from the lateral side. Any posterior subluxation should normally correct during this extension of the knee, confirming the diagnosis.



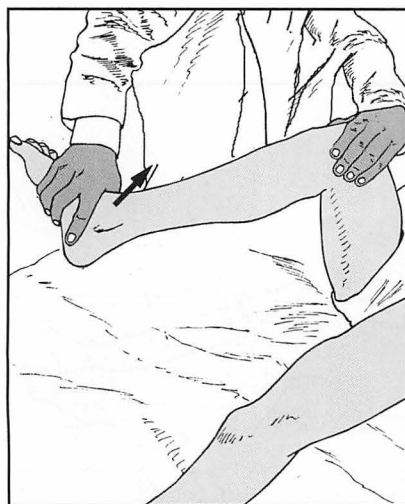
10.79. Posterior cruciate ligament (3):

Place the thumb on one side of the joint line and the index on the other to help you assess any tibial movement. Try to pull the tibia forwards with the other hand. If the posterior cruciate ligament is torn and the tibia subluxed posteriorly, the forward movement as the tibia reduces will be easily felt.



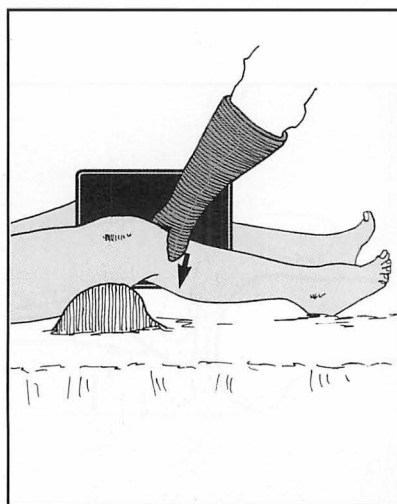
10.80. Posterior cruciate ligament (4):

If the posterior cruciate is lax or torn, but subluxation has not yet occurred (uncommon), then backward pressure on the tibia will normally produce a detectable excessive posterior excursion. Note that a Lachman procedure in the prone position may also be used to detect posterior cruciate laxity.



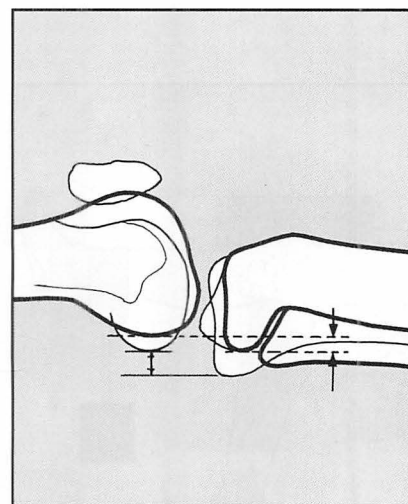
10.81. Posterior cruciate ligament (5):

Dynamic posterior shift test: Flex both the knee and hip to 90°. The latter leads to hamstring tightening, which in the presence of ligament laxity leads to posterior displacement of the tibia. Now extend the knee: this displaces the axis of the pull anteriorly, and the displaced tibia will reduce. This is usually obvious to careful inspection and is indicative of posterior laxity, with or without additional posterolateral laxity.



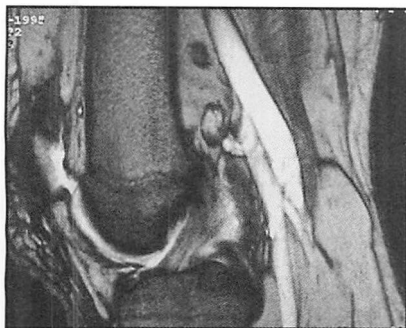
10.82. Radiological examination of posterior cruciate ligament function (1):

A sandbag is placed behind the thigh and the proximal tibia pressed forcibly backwards (with an equivalent force of 25 kg). This is repeated, and after the second preloading cycle, radiographs are taken while the same force is maintained.

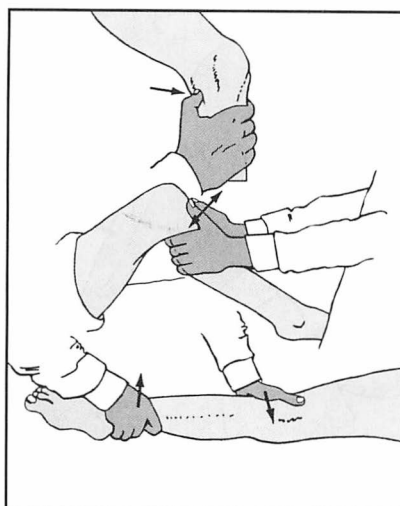


10.83. Radiological examination of posterior cruciate ligament function (2):

The gap between the medial femoral and tibial condyles is measured, along with that between the lateral condyles. A displacement of the order of 8 mm on each side is indicative of an uncomplicated posterior cruciate tear. Excessive movement on the lateral or medial sides indicates posterolateral or posteromedial instability.

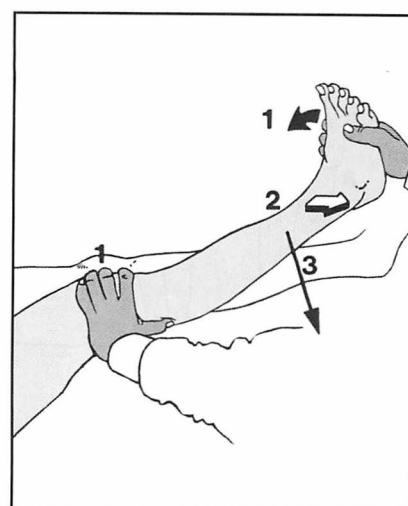


10.84. Visualization of the cruciate ligaments: MRI scans allow an accurate assessment of the state of the cruciate ligaments in 80% of cases. (Note that in terms of accuracy this is inferior to clinical assessment.) (Illus: intact anterior cruciate ligament.) The cruciates may also be inspected by arthroscopy. The ability of the cruciate ligaments to prevent abnormal tibial movements can be assessed mechanically by dynamic testing rigs.



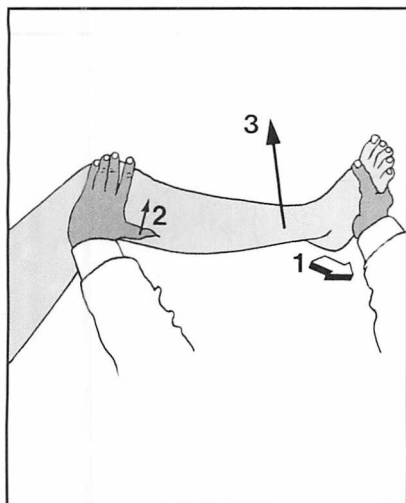
10.85. Assessing tibial subluxations (rotatory or torsional instabilities):

(1) Look for medial or lateral tenderness or oedema. (2) Perform the drawer tests noting variations. (3) Test for laxity on valgus stress (often positive in anterior subluxations of the medial tibial condyle). (4) Test for laxity on varus stress (usually positive when the lateral tibial condyle subluxes forwards or backwards). (5) Carry out the following additional tests.



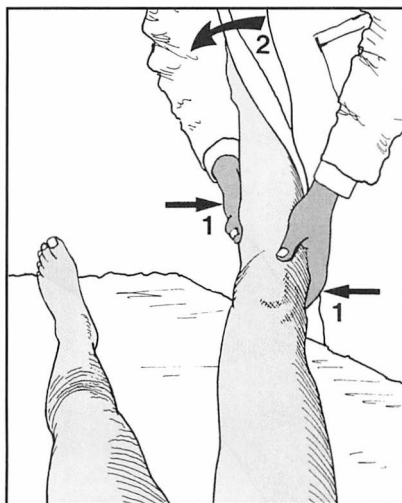
10.86. MacIntosh test for anterior subluxation of the lateral tibial condyle (the pivot shift test):

Fully extend the knee while holding the foot in internal rotation (1). Apply a valgus stress (2). In this position, if instability is present the tibia will be in the subluxed position. Now flex the knee (3): reduction should occur at about 30° with an obvious jerk. A positive test indicates an anterior cruciate abnormality, with or without other pathology.



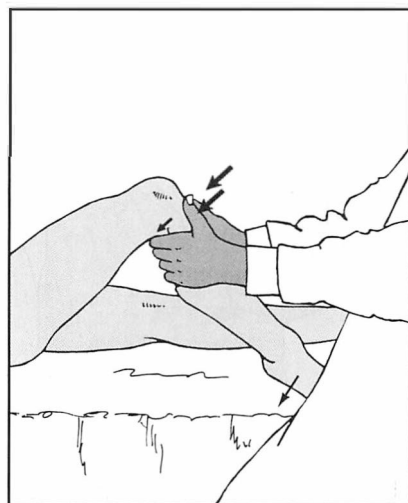
10.87. Losee pivot shift test for anterior subluxation of the lateral tibial condyle:

The patient should be completely relaxed, with no tension in the hamstrings. Apply a valgus force to the knee (1) at the same time pushing the fibular head anteriorly (2). The knee should be partly flexed. Now extend the joint (3). As full extension is reached, a dramatic clunk will occur as the lateral tibial condyle subluxes forwards (if rotatory instability is present). Note: the patient should relate this to the sensations experienced in activity.



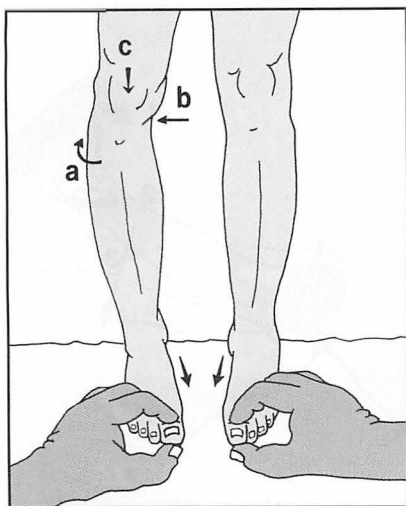
10.88. Modified pivot shift or jerk test for anterior subluxation of the lateral tibial condyle:

Grasp the foot between the arm and the chest, and apply a valgus stress (1); lean over to rotate the foot internally (2). Now flex the knee. If the test is positive, and because the tibia is firmly held, the lateral femoral condyle will appear to jerk anteriorly. Now extend the knee, and as the tibia subluxes the femoral condyle will appear to jerk backwards.



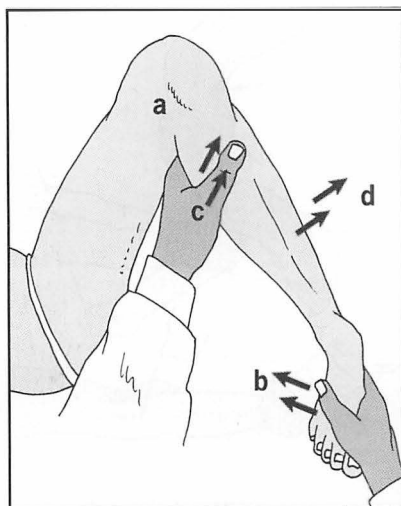
10.89. Posterolateral instability (1):

The posterolateral drawer test: The knee should be flexed to a little less than 90° and the foot placed in external rotation. Apply backward pressure on the tibia. Excessive travel on the lateral side is indicative of posterolateral instability. Posterolateral instability is usually associated with injuries to the posterior cruciate and lateral ligament complex.

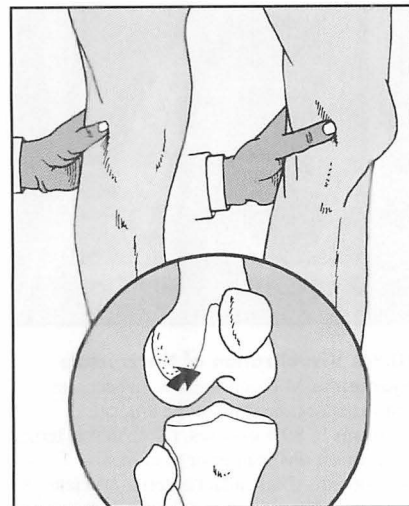


10.90. Posterolateral instability (2): The external rotation recurvatum test:

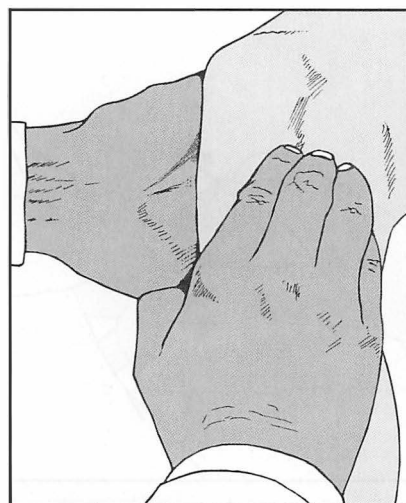
With the patient in the supine position, stand at the end of the examination couch and lift the legs by the great toes. The test is positive if the knee falls into external rotation (a), varus (b) and recurvatum (c).



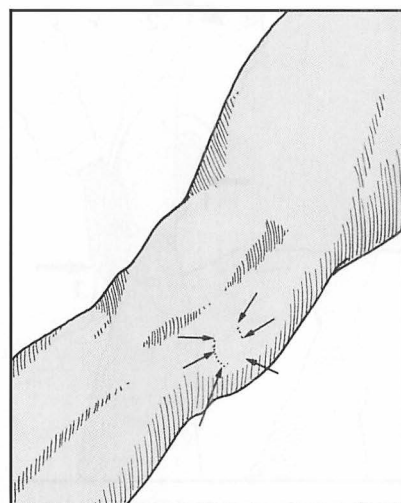10.91. Posterolateral instability (3): Jakob's reversed pivot shift test: Begin by flexing the knee to 90° (a). Now externally rotate the foot (b), apply a valgus stress (c), and extend the knee (d). If the test is positive, the posteriorly subluxed lateral tibial plateau suddenly reduces at about 20° .



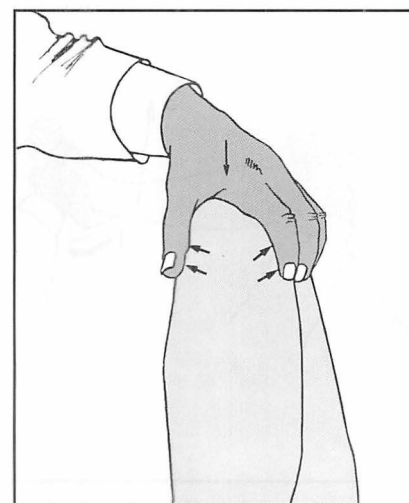
10.92. Posterolateral instability (1): Standing apprehension test: The patient should be taking his weight through the slightly flexed knee. Grasp the knee and with the thumb at the joint line press the anterior part of the lateral femoral condyle medially. The test is positive if movement of the condyle occurs (allowing the tibia to slip posteriorly under it), and if this is accompanied by a feeling of giving way.



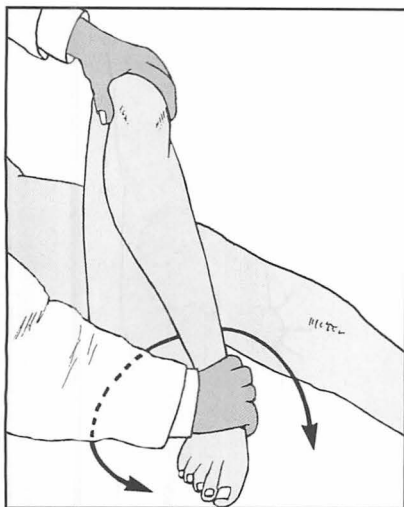
10.93. The menisci (1): Look for tenderness in the joint line and test for a springy block to full extension. These two signs, in association with evidence of quadriceps wasting, are the most consistent and reliable signs of a torn meniscus.



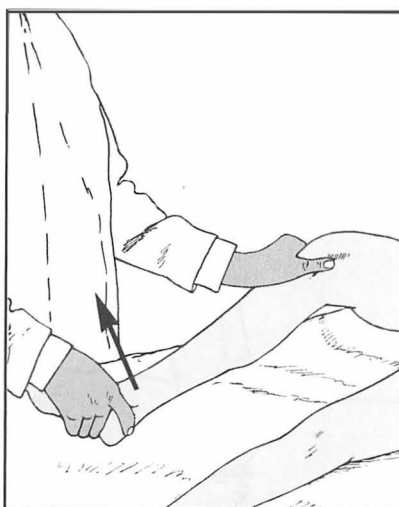
10.94. The menisci (2): In recent injuries, look for telltale oedema in the joint line. Bruising is *not* a feature of meniscal injuries.




10.95. The menisci (3): Posterior lesions (1): Fully flex the knee and place the thumb and index along the joint line. The palm of the hand should rest on the patella. You are now in a position to be able to locate any clicks emanating from the joint.



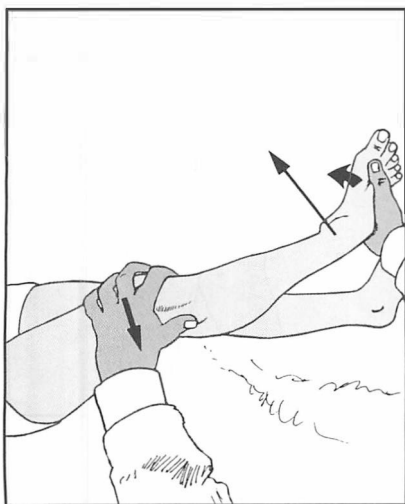
10.96. The menisci (4): Posterior lesions (2): Sweep the heel round in a U-shaped arc, looking and feeling for clicks from the joint accompanied by pain. Watch the patient's face, not the knee, while carrying out this test.



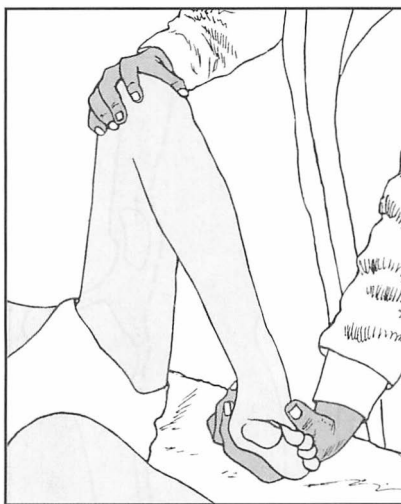10.97. The menisci (5): Anterior lesions: Press the thumb firmly into the joint line at the medial side of the patellar ligament. Now extend the joint. Repeat on the other side of the ligament. A click, accompanied by pain, is often found in anterior meniscus lesions.



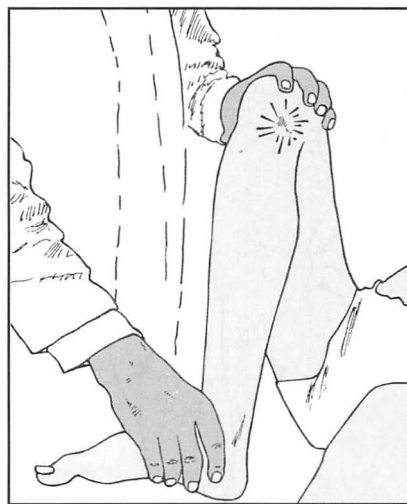10.98. The menisci (6): McMurray manoeuvre for the medial meniscus: Place the thumb and index along the joint line to detect any clicks. *Flex* the leg fully; *externally rotate* the foot, *abduct* the lower leg, and extend the joint smoothly. A click arising in the medial joint line, accompanied by complaint of pain, is indicative of a medial meniscus tear.



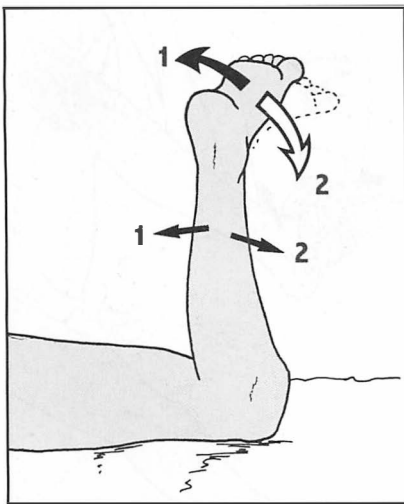
10.99. The menisci (7): McMurray manoeuvre for the lateral meniscus: Repeat the last test with the foot internally rotated and the leg *adducted*. Use the hand to pick up the source of any clicks which are accompanied by pain. A grating sensation may be felt in degenerative lesions of the meniscus.



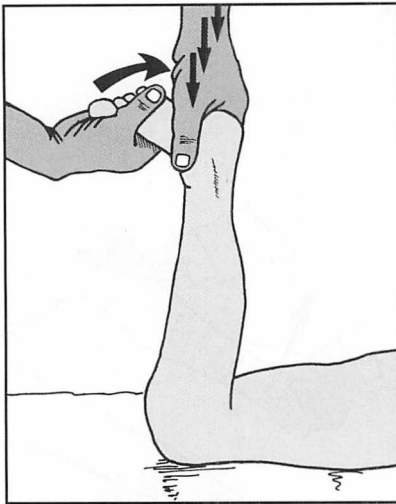
10.100. The menisci (8): If any clicks are detected, the normal limb should be examined to help eliminate symptomless, non-pathological clicks which may be arising from tendons or other soft tissues snapping over bony prominences (e.g. the biceps tendon over the femoral condyle), or from the patella clicking against a femoral condyle.



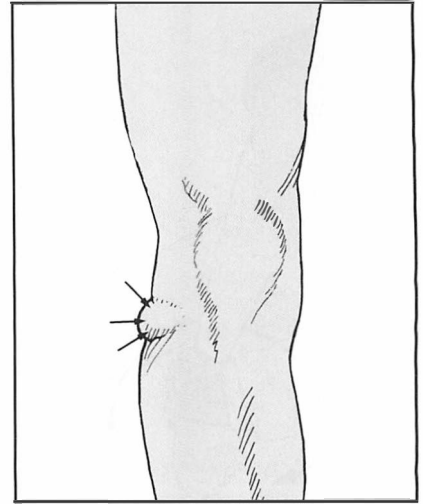
10.101. The menisci (9): If a unilateral painful click is obtained, repeat the test with the sensing finger or thumb removed. The cause of the click, whether from meniscus or tendon, may be visible on close inspection of the joint line.



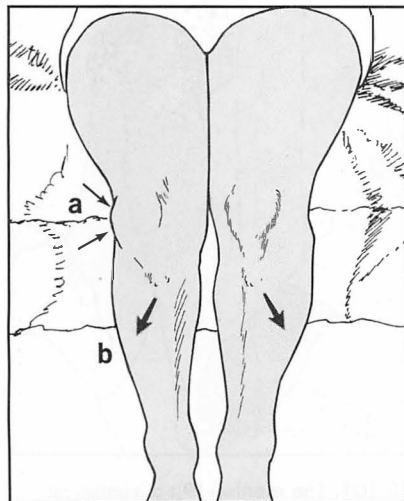
10.102. The menisci (10): Apley's grinding tests (1): In the tests, the suspect meniscus is subjected to compression and shearing stresses; sharp pain is suggestive of a tear. The patient is prone. The examiner grasps the foot, externally rotates it and fully flexes the knee (1). He then internally rotates the foot and extends the knee (2). The sides are compared. This demonstrates any limitation of rotation, or where any pain occurs.



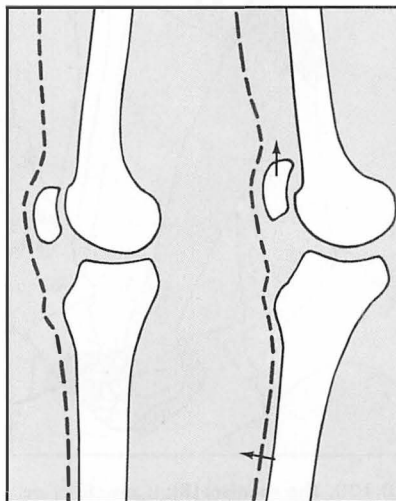
10.103. The menisci (11): Grinding tests (2): Then, while standing on a stool, the examiner throws his weight along the axis of the limb, and externally rotates the foot. Severe sharp pain is indicative of a medial meniscus tear. Repeat in a greater degree of flexion to test the posterior horn. To test the lateral meniscus, repeat the tests with the foot forcibly internally rotated.



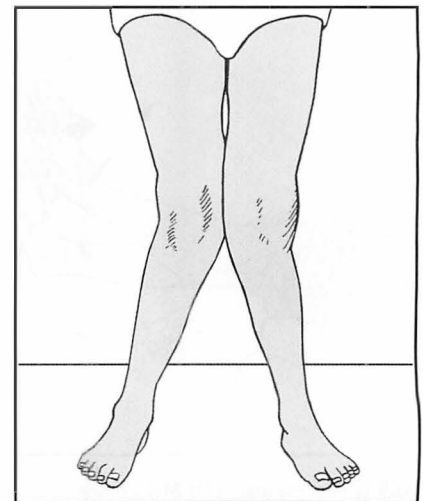
10.104. The menisci (12): Meniscal cysts lie in the joint line, feel firm on palpation, and are tender on deep pressure. Cysts of the menisci may be associated with tears. Lateral meniscus cysts are by far the commonest. Cystic swellings on the medial side are sometimes due to ganglions arising from the pes anserinus (insertion of sartorius, gracilis and semitendinosus).



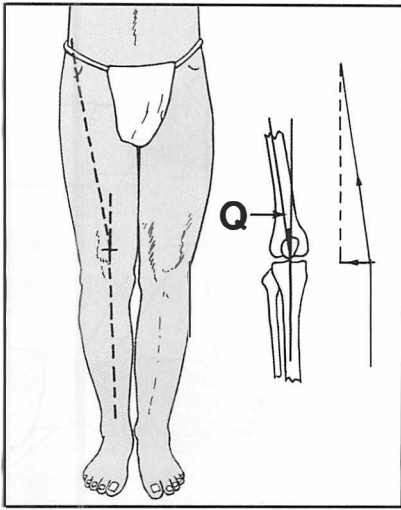
10.105. The patella (1): Examine both knees flexed over the end of the couch. This may show a torsional deformity of the femur or tibia, and a laterally placed patella (a) (which will be predisposed to instability (e.g. recurrent dislocation) or chondromalacia patellae). Now ask the patient to extend the knees (b), and look for any gross disturbance of patellar tracking: it should move smoothly in the patellar groove.



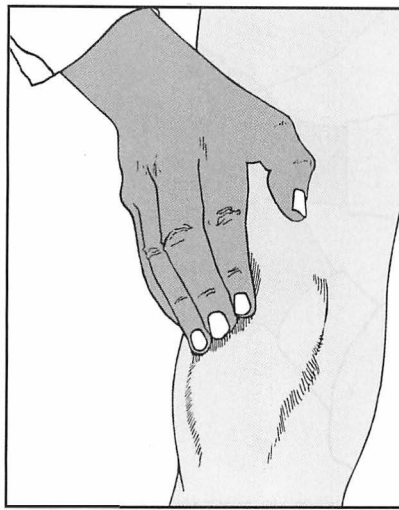
10.106. The patella (2): Look for genu recurvatum and the position of the patella relative to the femoral condyles. A high patella (patella alta) is a predisposing factor in recurrent lateral dislocation of the patella.



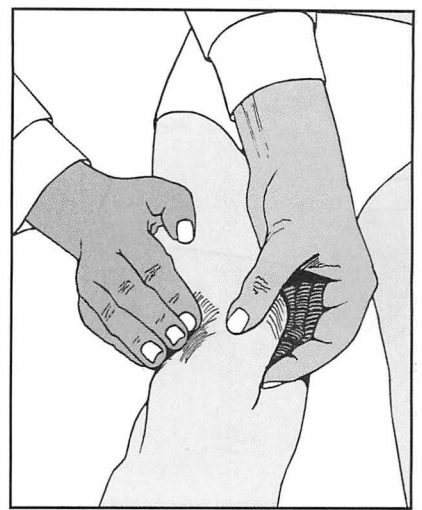
10.107. The patella (3): Is there any knock-knee deformity? Because this leads to an increase in the Q angle (quadriceps angle) it predisposes the knee to recurrent dislocation, anterior knee pain and chondromalacia patellae. The deformity is particularly common in adolescent girls. The intermalleolar distance may be measured, or the Q angle (which is similar to the tibiofemoral angle) may be determined.



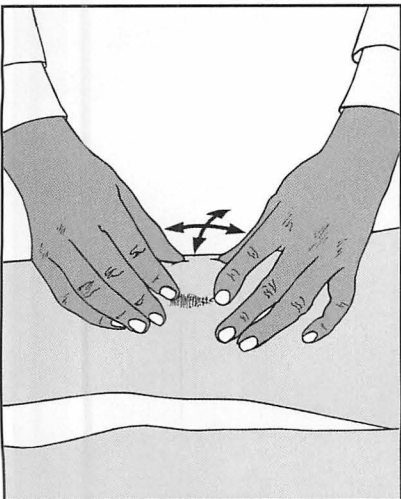
10.108. The patella (4): Finding the Q angle: this is the angle (normally about 6°) between (i) a line joining the anterior superior iliac spine with the centre of the patella, and (ii) the line of the patellar ligament. Ask the patient (who must be standing) to hold the end of a tape measure on his anterior spine while you centre the other over the patella. Then align a goniometer with the tape and the patellar ligament.



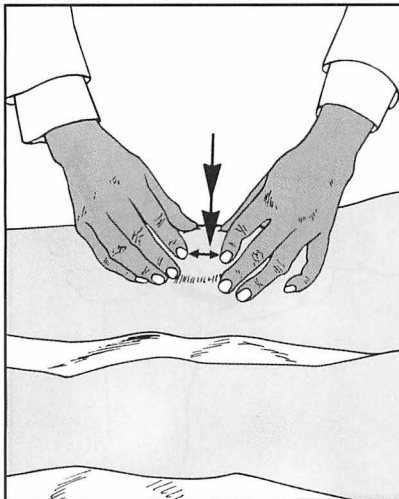
10.109. The patella (5): Look for tenderness over the anterior surface of the patella, and note whether a tender, bipartite ridge is present. Lower pole tenderness occurs in Sinding–Larsen–Johansson disease. (Tenderness may also occur over the patellar ligament, quadriceps tendon and tibial tuberosity in other extensor apparatus traction injuries and variants of ‘jumper’s knee’.)



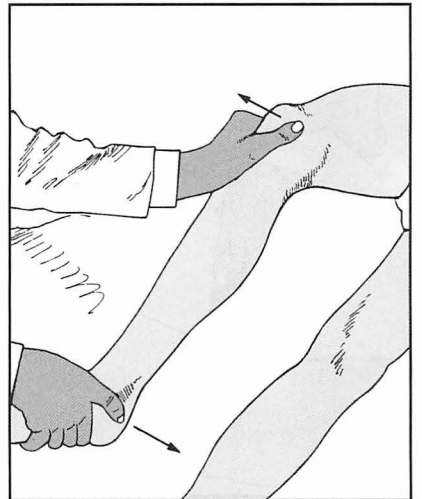
10.110. The patella (6): Displace the patella medially and palpate its articular surface. Tenderness is found when the articular surface is diseased, e.g. in chondromalacia patellae. Repeat the test, displacing the patella laterally. Two-thirds of the articular surface of the patella are normally accessible in this way.



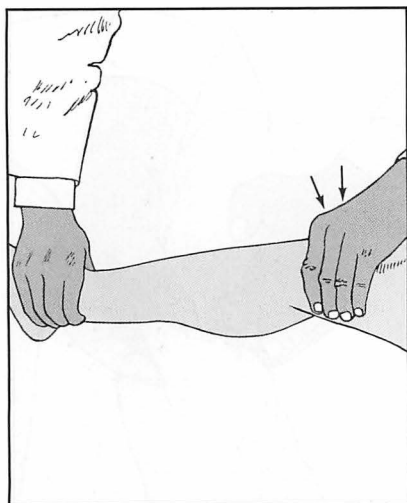
10.111. The patella (7): Test the mobility of the patella by moving it up and down and from side to side. Reduced mobility is found in retropatellar arthritis. The quadriceps must be relaxed for adequate performance of this test. Decreased patellar mobility will obviously impair the performance of the previous test.



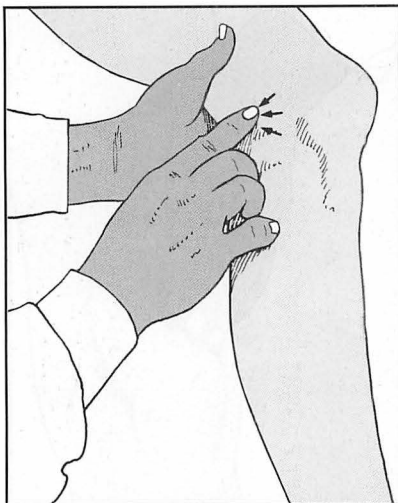
10.112. The patella (8): Move the patella proximally and distally, at the same time pressing it down hard against the femoral condyles. Pain is produced in chondromalacia patellae and retropatellar osteoarthritis.



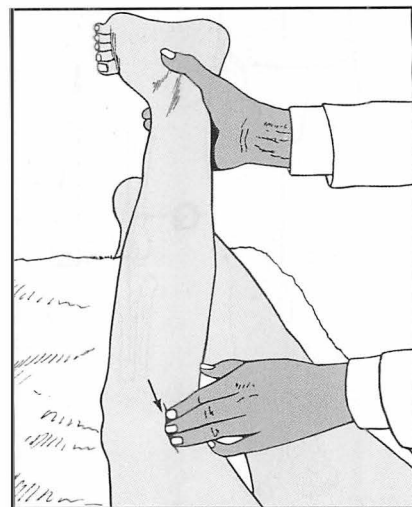
10.113. The patella (9): The apprehension test: Try to displace the patella laterally while flexing the knee from the fully extended position. If there is a tendency to recurrent dislocation, the patient will be apprehensive and try to stop the test, generally by pushing the examiner’s hand away.



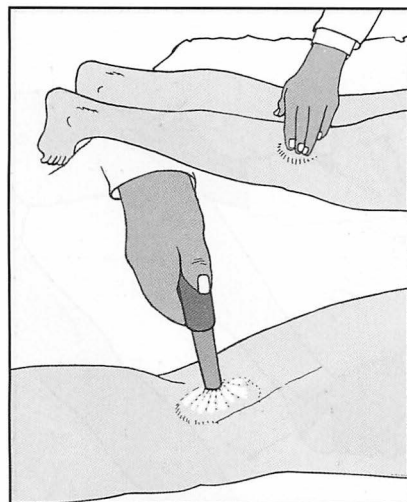10.114. Articular surfaces (1): Place the palm of the hand over the patella, and the thumb and index along the joint line. Flex and extend the joint. The source of crepitus from damaged articular surfaces can then be detected. Compare one side with the other. If in doubt, auscultate the joint. Ignore single patellar clicks.



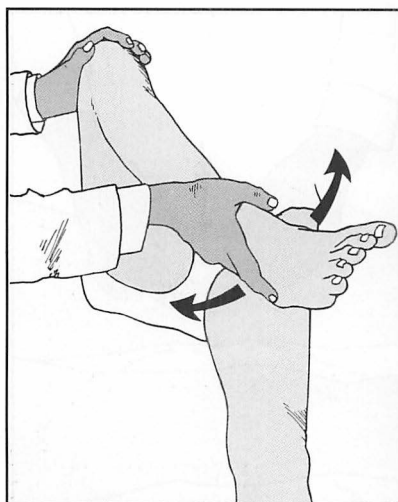
10.115. Articular surfaces (2): Apparent broadening of the joint and palpable exostoses occur commonly in osteoarthritis. (Both sides of the joint are affected in the later stages of tibiofemoral osteoarthritis, but in the early stages of this condition the *medial* side of the joint is often affected first, leading to a bow-leg deformity and frequently laxity of the medial ligament.)



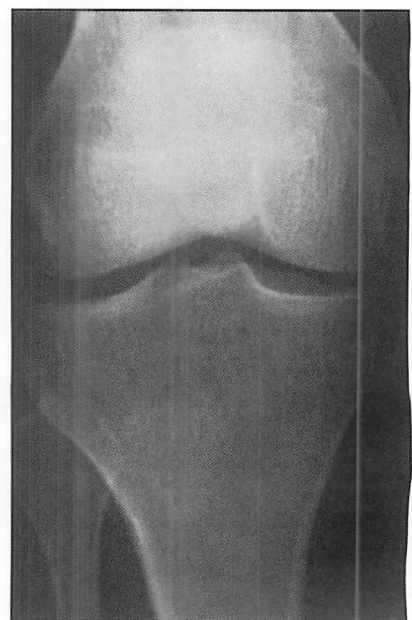
10.116. Popliteal region (1): Nearly all the tests previously described have involved examination of the joint *from the front*. Do not forget to examine the *back* of the joint, by both inspection and palpation. If the knee is flexed the roof of the fossa is relaxed, and deep palpation becomes possible.



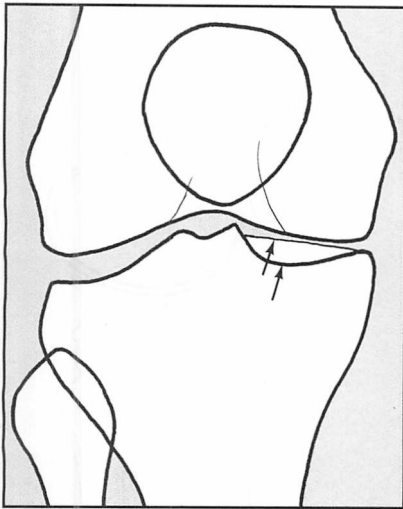
10.117. Popliteal region (2): Semimembranosus bursae become obvious when the knee is extended. Compare the sides. A bursa may be small at the time of examination, and transillumination is worth trying although not always positive. Note that semimembranosus bursae may be secondary to rheumatoid arthritis or other pathology in the joint.



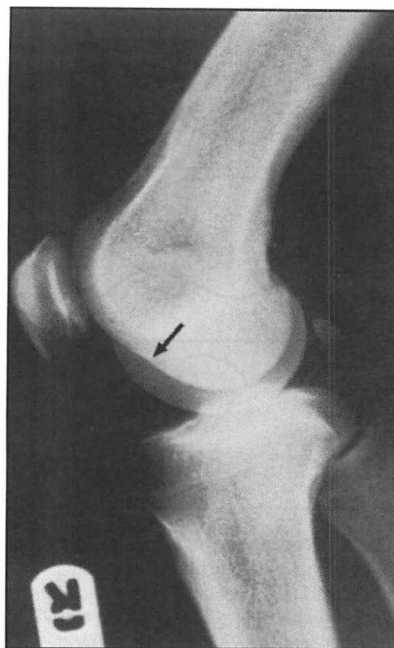10.118. The hip: Always examine the hip, especially in the presence of severe, undiagnosed pain, as hip pain is often referred to the knee joint. The hip may be screened by testing rotation at 90° flexion and noting pain or restriction of movements.



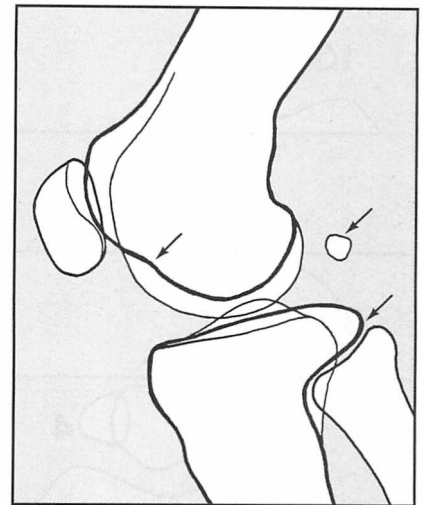
10.119. Radiographs (1): Normal anteroposterior radiograph of the knee.



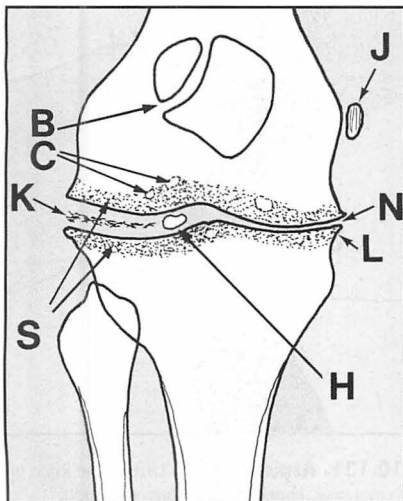
10.120. Radiographs (2): The contours of the femur, tibia and fibula are obvious. The patellar shadow is usually rather faint and difficult to make out. Note on the medial side the two tibial shadows formed by the anterior and posterior rims of the concave medial tibial plateau. (The lateral tibial plateau is convex and has a single shadow.)



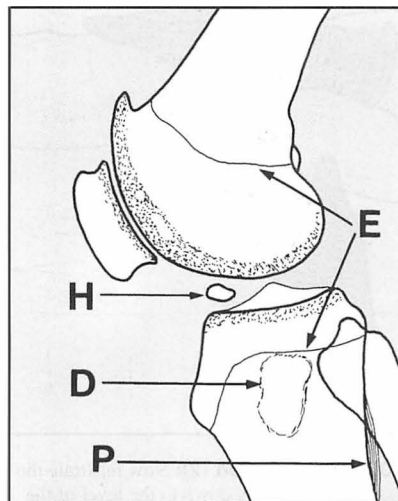
10.121. Radiographs (3): Normal lateral radiograph of the knee. The arrow points to the condylopatellar sulcus, which helps identify the lateral femoral condyle, which is larger and flatter.



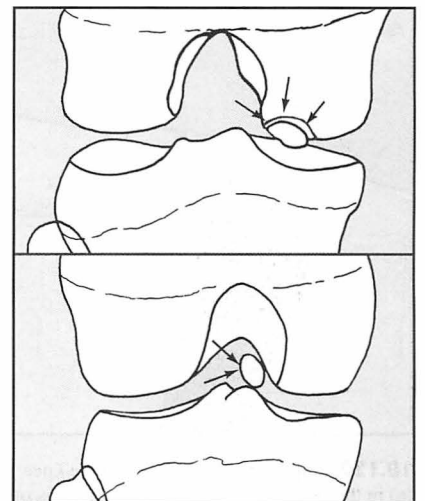
10.122. Radiographs (4): Note here that the *lateral condyles* of the femur and of the tibia are drawn with a heavy line. The *lateral tibial condyle* may often be identified by the fibular articulation. The outline of the *medial tibial condyle* tends to blend with the shadow of the tibial spines. Note the fabella, an inconstant sesamoid bone lying in the lateral head of gastrocnemius: do not mistake it for a loose body.



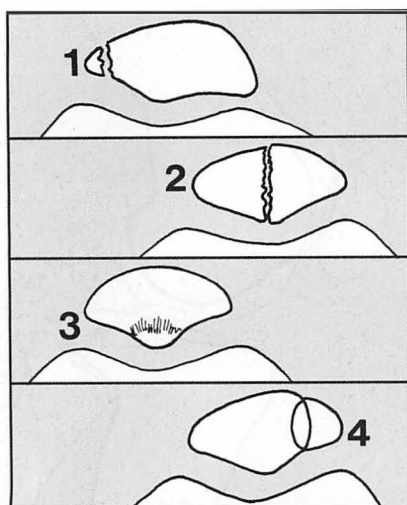
10.123. Radiographs (5): Note any joint space narrowing (indicating cartilage loss) (N), lippling (L), marginal sclerosis (S), cysts (C), loose bodies (H), varus or valgus (these are all common in osteoarthritis). Do not mistake a bipartite patella (B) for fracture: bipartite patella, if present, affects the *outer* quadrant). Note any abnormal calcification, as in Pellegrini-Steida disease (J), calcified meniscus (K), and pseudogout.



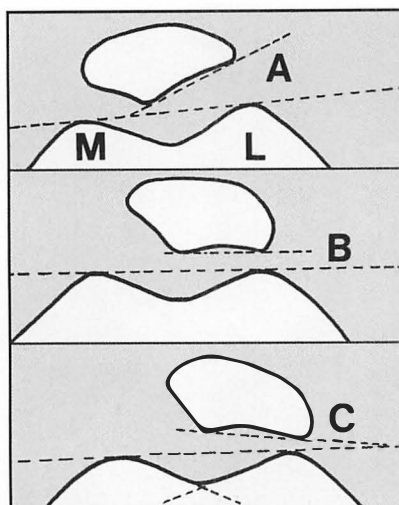
10.124. Radiographs (6): Look for alterations in bone texture (e.g. in Paget's disease, rheumatoid arthritis, osteomalacia, infections). Note any bone defects (D) suggestive of tumour or infection, or areas of periosteal reaction (P), perhaps indicative of tumour or infection. Do not mistake epiphyseal lines (E) for hairline or other fractures.



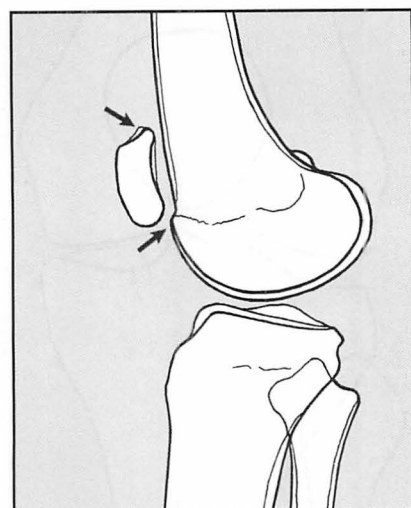
10.125. Radiographs (7): Intercondylar (tunnel) radiographs are often of help in confirming the diagnosis of osteochondritis dissecans, as they show the common sites more clearly, especially in the medial femoral condyle. They are also of value in locating loose bodies.



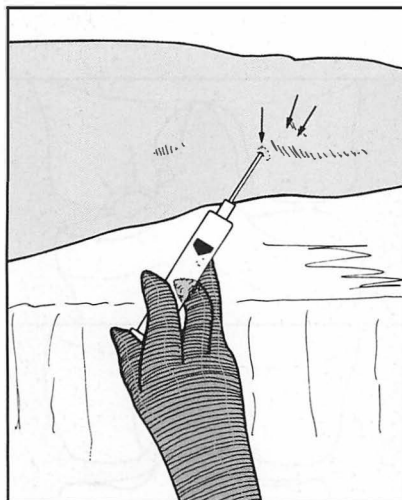
10.126. Radiographs (8): Where the patella is suspect, a tangential (skyline) view should be obtained. This may show (1) a marginal (medial) osteochondral fracture, common in recurrent dislocation of the patella, (2) other fractures, (3) occasionally, evidence of chondromalacia patellae, (4) bipartite patella.



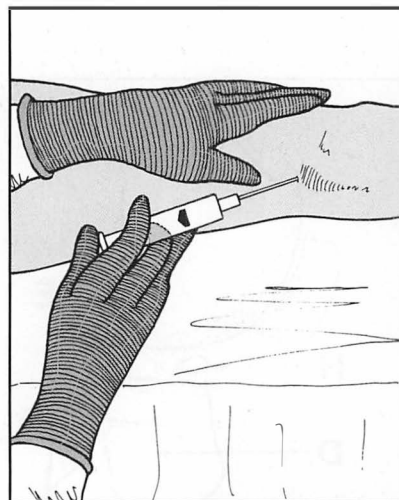
10.127. Radiographs (9): A 20° projection may help in assessing patellar instability. Draw tangents to show the *lateral patellofemoral angle*. This is positive in 97% of normal subjects (A). In those suffering from recurrent dislocation of the patella it is zero in 80% (B), or negative in 20% (C). This angle may also be defined by CT scans. Note also whether the sulcus is shallow ($> 170^\circ$).



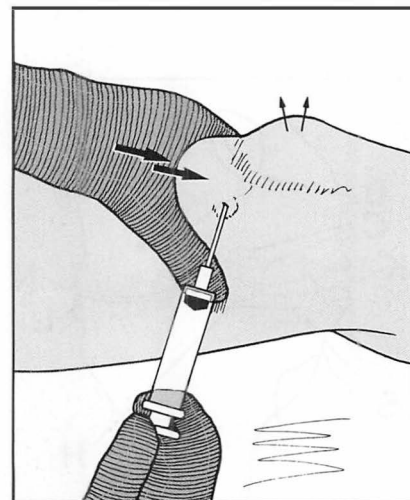
10.128. Radiographs (10): Again, in suspected recurrent dislocation of the patella the lateral projection should be taken with the knee weightbearing and held in full extension. This may confirm the presence of a highly placed and susceptible patella (patella alta).



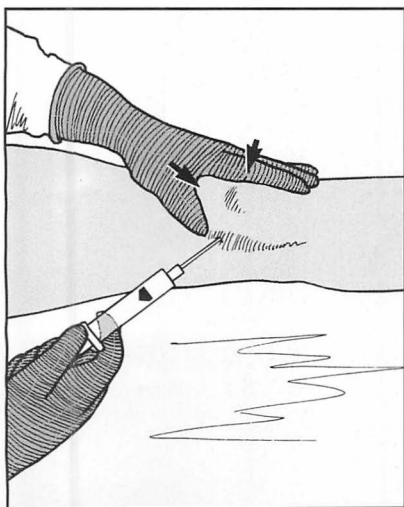
10.129. Aspiration (1): Aspirate the knee (a) in the presence of a tense haemarthrosis or (b) to obtain specimens for bacteriology in suspected infections. Taking full aseptic precautions, begin by raising a skin wheal with local anaesthetic just above and lateral to the patella.



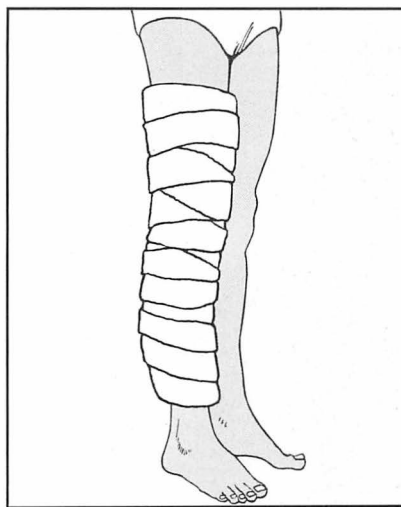
10.130. Aspiration (2): Now infiltrate the tissues more deeply down to the level of the synovial membrane of the suprapatellar pouch.



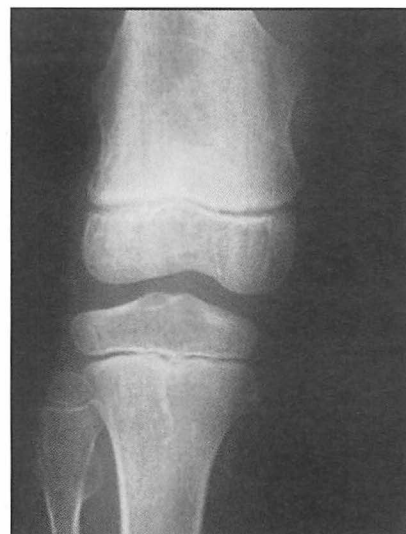10.131. Aspiration (3): Unless the knee is very tense, squeeze fluid from the upper limits of the suprapatellar pouch to float the patella forwards before inserting the aspiration needle.



10.132. Aspiration (4): Squeeze the superior aspect and sides of the joint during the terminal stages of aspiration to empty the joint. After withdrawal of the needle, apply a sterile dressing over the aspiration site.

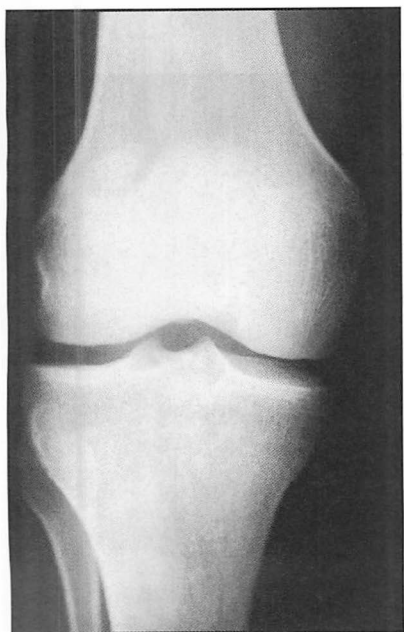


10.133. Aspiration (5): Unless other treatment is contemplated, apply a Jones compression bandage. This consists of several layers (2–4) of wool in the form of wool roll, gamgee or cottonwool sheets, each held in place with firmly (but not tightly) applied calico, domette or crepe bandaging. Alternatively, a double layer of a circularly woven bandage (e.g. Tubigrip) may be used.

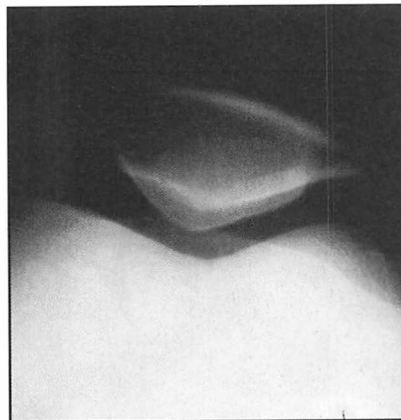


10.134. Examples of pathology (1): The radiographs show both femoral and fibular exostoses affecting the metaphyses of these bones. Clinically corresponding swellings were obvious on inspection and palpation.

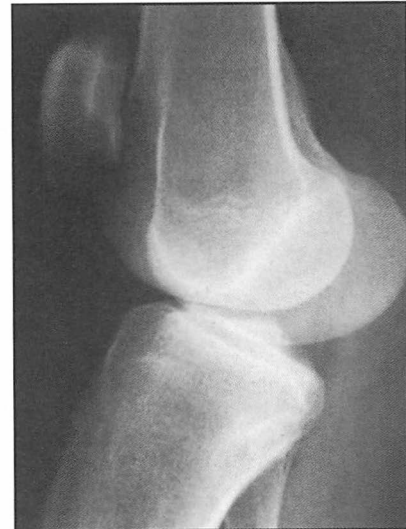
Diagnosis: diaphyseal aclasis (sometimes also referred to as metaphyseal aclasis).



10.135. Pathology (2): The superolateral quadrant of the patella has a separate centre of ossification, and despite not showing clearly on the radiographs the edges were well rounded and not typical of fracture. Clinically there was no local tenderness. **Diagnosis:** bipartite patella. The constancy of the site may often help differentiate it from fracture.

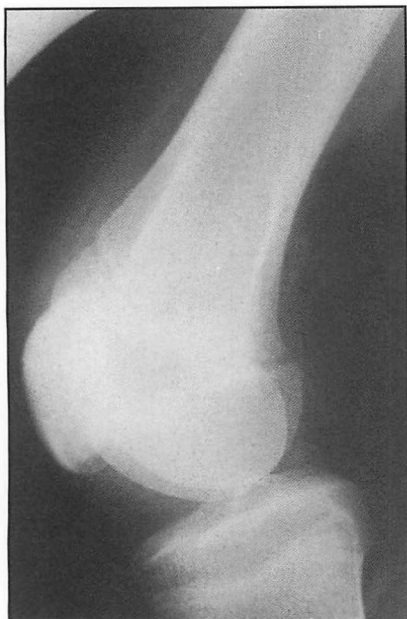

10.136. Pathology (3): Tangential (skyline) projection of the previous case showing the lateral irregularity (to the right of the picture).

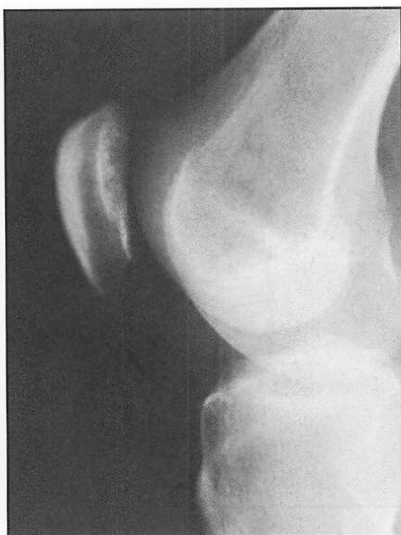


10.137. Pathology (4): This is a weightbearing lateral projection of the knee in an adolescent girl. The patella is in contact with the femur proximal to its articular surface, and the joint is hyperextended.

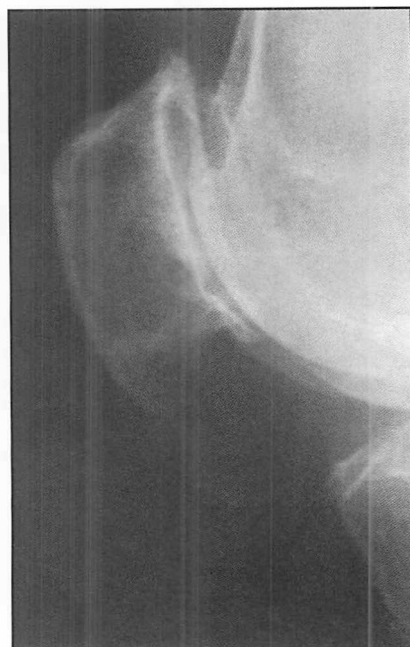Diagnosis: genu recurvatum and patella alta deformities.



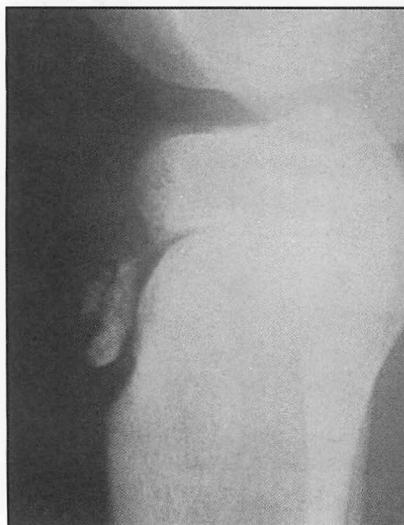10.138 Pathology (5): This radiograph is of an acute injury to the knee in an adolescent girl. Although the shadows of the femur and tibia show that the joint has been correctly positioned for the lateral projection, the patella is superimposed on the femur.
Diagnosis: lateral dislocation of the patella.



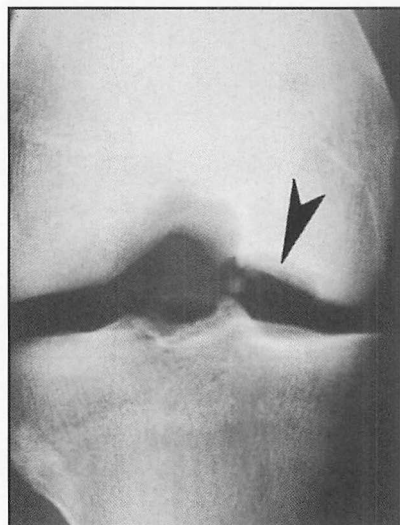
10.139. Pathology (6): There is a well defined irregularity involving the proximal two-thirds of the articular surface of the patella in a young woman.
Diagnosis: this illustrates a marked degree of chondromalacia patellae.



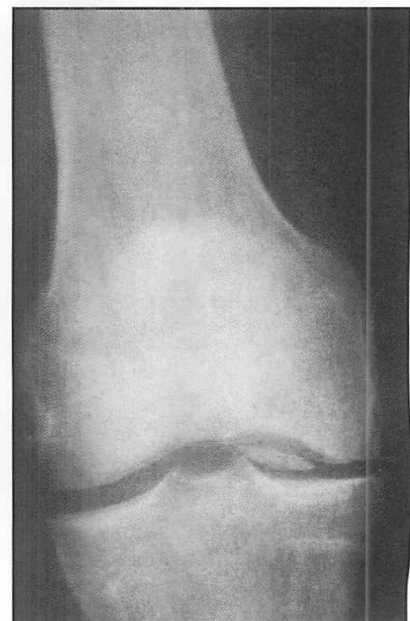
10.140. Pathology (7): This localized view of the knee shows marked narrowing of the joint space between the femur and the patella, with patellar lipping.
Diagnosis: severe retropatellar osteoarthritis.



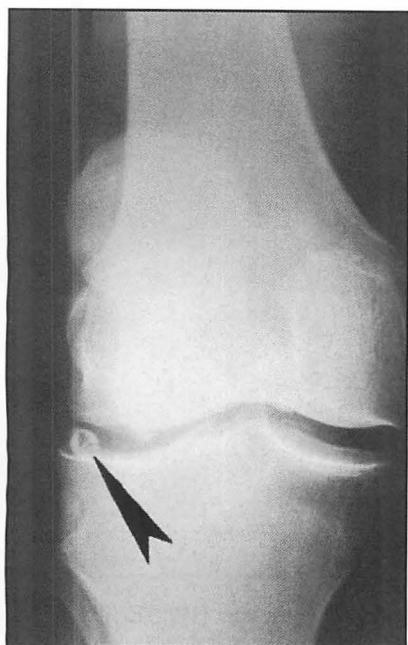
10.141. Pathology (8): Note the separation and fragmentation of the tongue-like downward-projecting proximal tibial epiphysis. This was associated with chronic, localized knee pain.
Diagnosis: Osgood-Schlatter's disease.



10.142. Pathology (9): This radiograph is an anteroposterior view of the knee which has been positioned to show the intercondylar notch (the so-called 'tunnel projection'). Note the punched-out area in the medial femoral condyle, indicated with the arrow.
Diagnosis: osteochondritis dissecans, typically affecting the lateral side of the medial femoral condyle.

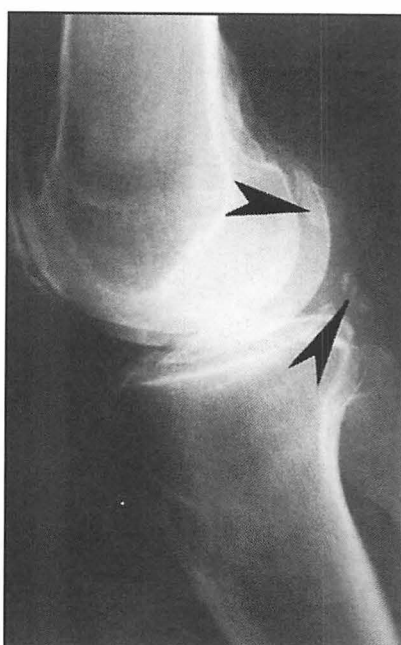


10.143. Pathology (10): These radiographs of a young man (note the degree of epiphyseal fusion) show separation of a large fragment of bone (and articular cartilage) from the medial femoral condyle.
Diagnosis: long-standing osteochondritis dissecans.



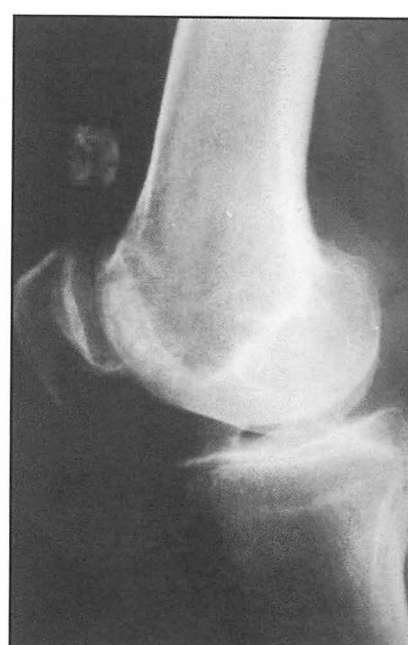10.144. Pathology (11): This is the radiograph of a middle-aged man. The arrow points to a small spherical loose body lying in the lateral compartment of the joint. There is some unilateral joint space narrowing, and irregularity of the articular surface of the lateral femoral condyle.

Diagnosis: osteoarthritis of the knee, with the loose body probably secondary to that process.



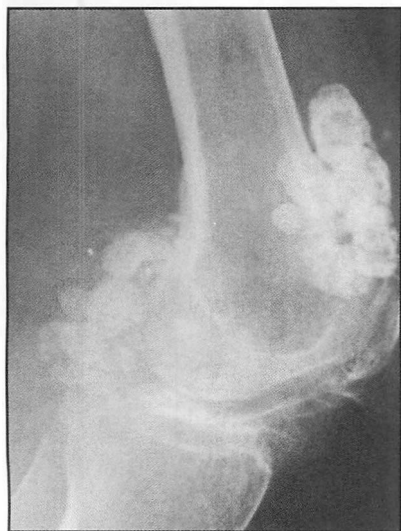
10.145. Pathology (12): The arrows point to three opacities related to the knee.

Diagnosis: the *upper* arrow points to a normal fabella. The *lower* arrow indicates two loose bodies, lying in the posterior part of the joint. These are secondary to osteoarthritis.



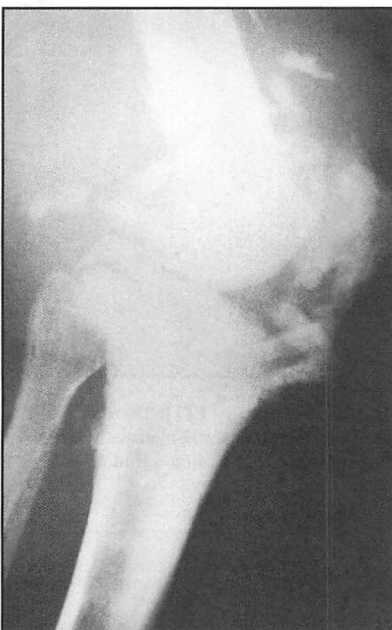10.146. Pathology (13): There are sclerotic changes involving the posterior articular surface of the patella, and to a lesser extent the related condylar surfaces of the femur. There is a little irregularity of the tibial spines, and there is a large opacity lying proximal to the upper pole of the patella.

Diagnosis: osteoarthritis of the knee, with a large loose body in the suprapatellar pouch.



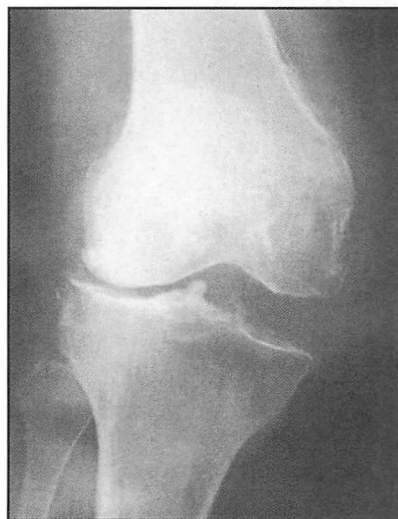
10.147. Pathology (14): There are multiple loose bodies in the knee joint.

Diagnosis: synovial chondromatosis.



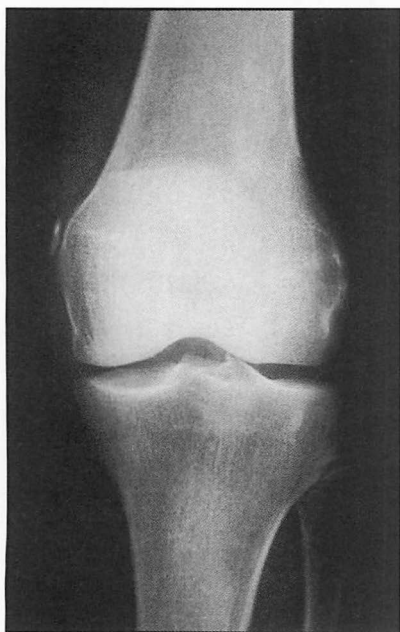
10.148. Pathology (15): There is gross disorganization of the knee, with much new bone formation.

Diagnosis: Charcot's disease.



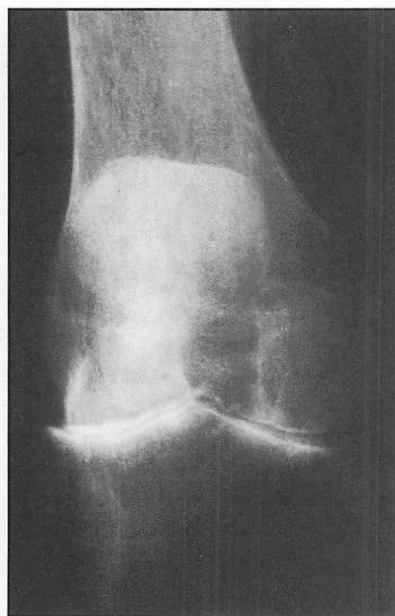
10.149. Pathology (16): This radiograph, taken following acute trauma, shows widening of the medial joint line.

Diagnosis: rupture of the medial ligament of the knee. It is uncommon to see such a degree of deformity without stress being applied to the joint while the films are being exposed. The gross nature of the deformity indicates that the posterior ligament and probably both cruciate ligaments are also torn. There is no evidence of an associated fracture of the lateral tibial plateau.



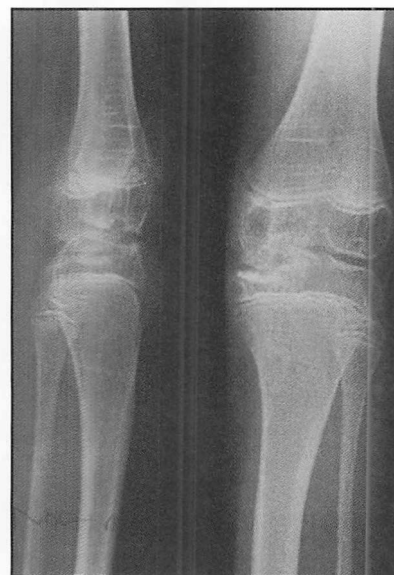10.150. Pathology (17): There is a history of chronic pain on the medial side of the knee, and the radiographs shows calcification in the region of the upper attachment of the medial ligament.

Diagnosis: Pellegrini–Stieda disease.



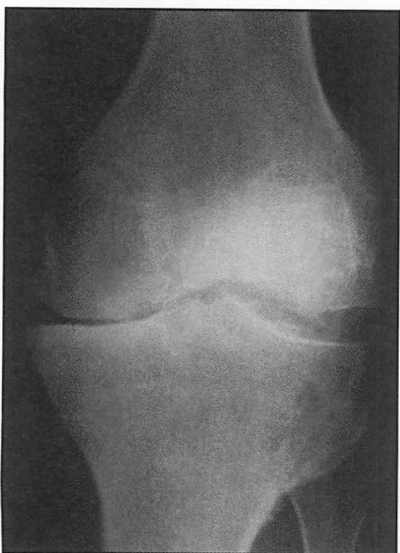
10.151. Pathology (18): There is gross narrowing of the joint space with a degree of osteoporosis.

Diagnosis: rheumatoid arthritis.



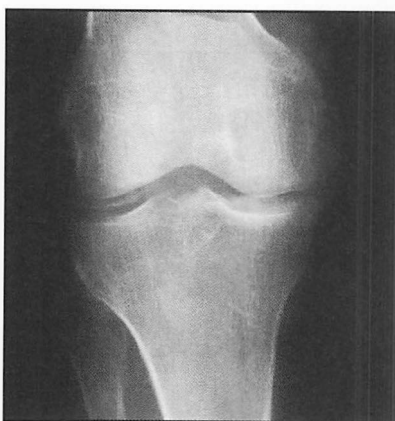10.152. Pathology (19): There is destruction of the medial joint compartment, with some horizontal bone striations (Looser's zones) indicative of repeated incidents of temporary growth arrest.

Diagnosis: chronic joint infection typical of tuberculosis of the knee.



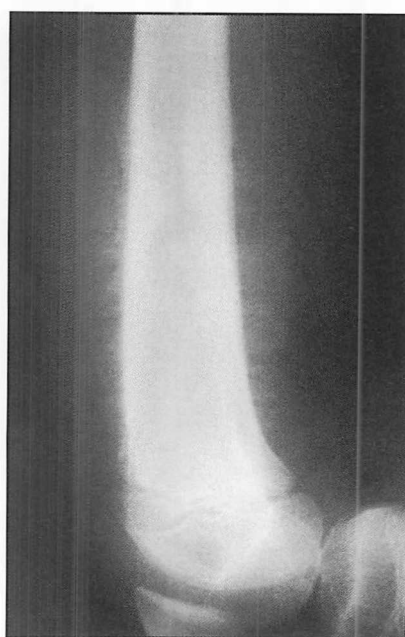10.153. Pathology (20): There is narrowing of the medial joint compartment, with a degree of marginal sclerosis of bone. There is a little residual disturbance of the lateral tibial plateau, where there has been an old fracture.

Diagnosis: osteoarthritis of the knee, probably secondary to an old valgus injury where there has been a tibial plateau fracture (and possibly an associated medial ligament injury).



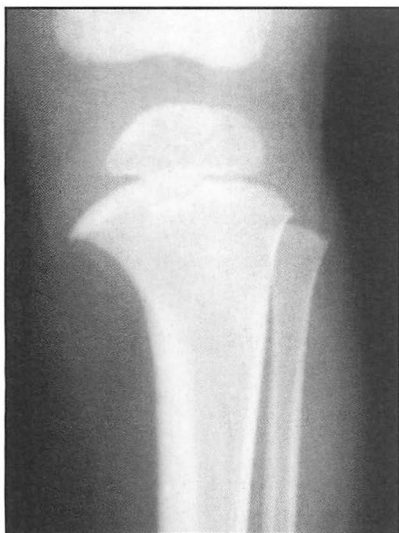10.154. Pathology (21): There is calcification in the lateral meniscus.

Diagnosis: this is a common finding in pseudogout.

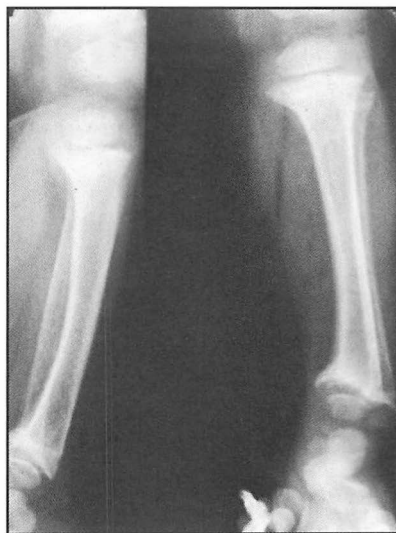

10.155. Pathology (22): There is a fusiform swelling of the femoral shaft encroaching on the knee joint. Note the radial spiculation.

Diagnosis: the appearances are typical of osteogenic sarcoma.



10.156. Pathology (23): The proximal part of the tibial metaphysis on its medial side is beaked, and clinically there was marked bowing of this child's legs.
Diagnosis: tibia vara.



10.157. Pathology (24): Clinically there was a marked bow-leg deformity. The radiographs confirm the tibial bowing and show widening of the metaphyses of the tibia, with characteristic irregularity and cupping.
Diagnosis: rickets associated with vitamin D deficiency.

CHAPTER

11

The tibia

Common causes of pain in the
anterior aspect of the lower
leg 246

Osteitis of the tibia 246

Bone tumours 246

Anterior tibial compartment
syndrome 246

Stress fracture of the tibia 246

Medial tibial syndrome/shin
splints 247

Tabes dorsalis 247

Common causes of pain in the
posterior aspect of the lower
leg 247

Deformities of the tibia 247

Guide to commoner causes of leg
pain 248

Inspection 249

Tibial torsion 249–250

Screening tests for leg pain 250

Radiographs 251

Pathology 252–254

COMMON CAUSES OF PAIN IN THE ANTERIOR ASPECT OF THE LOWER LEG

Note: Knock-knee and bow-leg deformities are included with the knee joint.

OSTEITIS OF THE TIBIA

Osteitis of the tibia occurs predominantly in children, with or without a history of previous trauma or sore throat. Pain is intense, tenderness is acute and initially well localized over the metaphyseal area, and there is inability to weightbear. There is systemic upset with fever and tachycardia, and often (but not always) a polymorph leukocytosis. Admission and investigation with repeated blood cultures is essential. Radiographs of the tibia are initially normal. When this condition is suspected, it is customary to administer a broad-spectrum antibiotic effective against the penicillin-resistant *Staphylococcus*, and in large doses to achieve adequate bone levels, prior to the results of blood culture. Splintage of the affected area is often helpful, and in proven cases antibiotics are administered for 4 weeks. Surgical drainage is seldom necessary and is avoided unless failure of response to antibiotics, profound toxicity and spread of the infection make it essential.

Cellulitis from insect stings, small wounds and abrasions and hair follicle infections may sometimes cause difficulty in diagnosis.

Low-grade osteitis of the tibia (Brodie's abscess) may give rise to chronic upper tibial pain.

BONE TUMOURS

The tibia is a common site for many primary bone tumours, so that radiographic examination of the tibia is essential in any case of undiagnosed leg pain.

ANTERIOR TIBIAL COMPARTMENT SYNDROME

This is a common complication of fractures of the tibial shaft, but may follow a period of intense lower limb activity: hence it is common in athletes. It gives rise to pain in the front of the leg. This is due to oedema and swelling within the confines of the anterior compartment, which lead in turn to ischaemia in the anterior tibial muscles. In severe cases where swelling is progressive there may eventually be muscle necrosis. The leg is diffusely swollen and tender, and the skin has a glossy appearance. Tibialis anterior and extensor hallucis longus are first affected, with weakness and later inability to extend the ankle and great toe. The dorsalis pedis pulse may be absent, and there may be sensory loss in the first web space due to ischaemic changes in the deep peroneal nerve. In high-risk and suspect cases compartment pressure monitoring is advisable. In severe cases immediate surgical decompression of the anterior tibial compartment is essential if muscle necrosis is to be avoided.

STRESS FRACTURE OF THE TIBIA

In this condition the onset of leg pain may be sudden or less acute. There is sharply localized bone tenderness and overlying oedema. Radiographic demonstration of the hairline fracture may be difficult, and with persistent pain repeated examination is essential. A radioisotope bone scan may be helpful in diagnosing a local 'hot spot'. In many cases the diagnosis may not

be firmly established until a small area of telltale callus is showing. The condition is also common in Paget's disease where, of course, there is an easily identifiable radiological abnormality.

MEDIAL TIBIAL SYNDROME/SHIN SPLINTS

In this condition pain on the medial side of the shin in sportsmen may be severe, and there is usually tenderness along the posteromedial border of the lower part of the tibia. In a number of cases the symptoms may arise from stress fractures of the tibia, but in others the pathology is less clear. (Other causes include compartment syndromes, fascial hernias, interosseous membrane tears, periosteal avulsions, tendinitis, muscle sprains and periostitis.) Where symptoms are of a chronic nature, and fracture has been excluded, division of the attachments of the crural fascia may give relief.

TABES DORSALIS

Severe pain in the shins (lightning pains) is common in tabes dorsalis. Usually other criteria are present (e.g. Argyll-Robertson pupils) and serological tests will confirm the diagnosis.

COMMON CAUSES OF PAIN IN THE POSTERIOR ASPECT OF THE LOWER LEG

1. *'Ruptured plantaris tendon'*. Sudden pain in the calf during activity with diffuse tenderness in the upper and outer part of the calf is now regarded as being due to tearing of muscle fibres of soleus or gastrocnemius, rather than injury to the plantaris muscle whose name is attached to the condition. Pain often persists for several months and a period of plaster immobilization is often helpful in giving relief in the acute initial stages.
2. *Thrombophlebitis*. Thrombosis in the superficial veins of the calf with local inflammatory changes is a common cause of recurrent calf pain, and the presence of tenderness and other inflammatory signs along the course of a calf vein make diagnosis easy. Thrombosis in the deep veins is often silent, and its importance in the postoperative situation is well known.
3. *Other causes of posterior leg pain*. Pain in the calf is common in patients suffering from prolapsed intervertebral discs. Claudication pain is a feature of vascular insufficiency and spinal stenosis. Lesions of the foot and ankle that lead to protective muscle spasm on standing and walking frequently give rise to marked calf and leg pain.

DEFORMITIES OF THE TIBIA

Alteration in the normal curvature of the tibia is not uncommon and may be a cause for complaint. The bone may curve convex laterally (tibial bowing), convex anteriorly (tibial kyphosis), or undergo a rotational deformity (tibial torsion). Deformities of these types are particularly likely to occur in infants and young children, when the immature bone may yield under the weight of a relatively heavy child. In the majority of cases no other cause is apparent, and spontaneous correction by the time the child reaches the age of 6 is the rule. Nevertheless, rickets and other osteodystrophies must be excluded and continuous observation is essential.

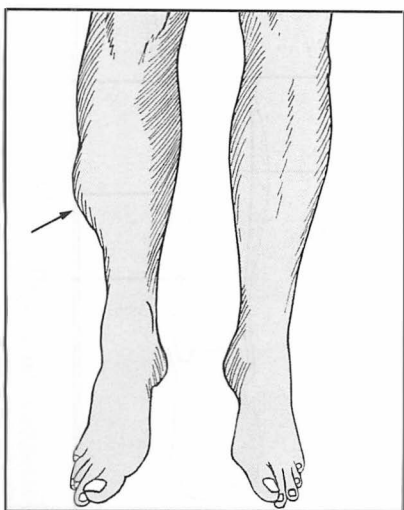
Pseudarthrosis of the tibia is a rare congenital abnormality which leads to progressive tibial kyphosis. The tibia becomes progressively thinner and

undergoes spontaneous fracture, which proceeds to non-union. It is particularly resistant to treatment. The diagnosis is made on the radiographic findings.

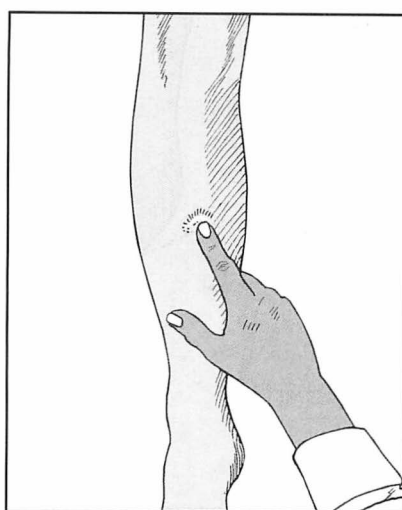
In the adult, deformity of the tibia may be seen following rickets in childhood, malunited fractures, Paget's disease and syphilis.

GUIDE TO COMMONER CAUSES OF LEG PAIN

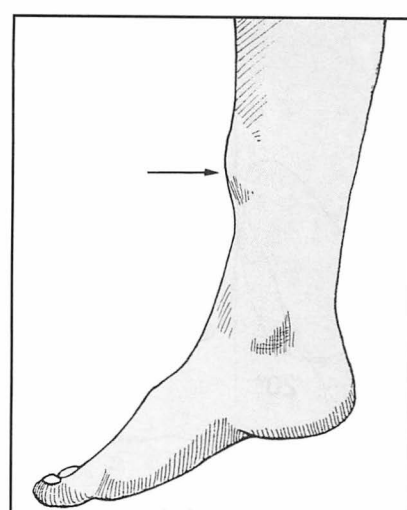
In children	Osteitis or other infections Bone tumour
Adolescents and young adults	Stress fracture tibia Bone tumours (especially osteoid osteoma, osteoclastoma, osteosarcoma) Brodie's abscess Anterior compartment syndromes Paget's disease 'Ruptured plantaris tendon' Painful conditions of the foot Syphilis Bone tumours
Adults	PID and spinal stenosis Vascular insufficiency Paget's disease 'Ruptured plantaris tendon' Painful conditions of the foot Syphilis Bone tumours



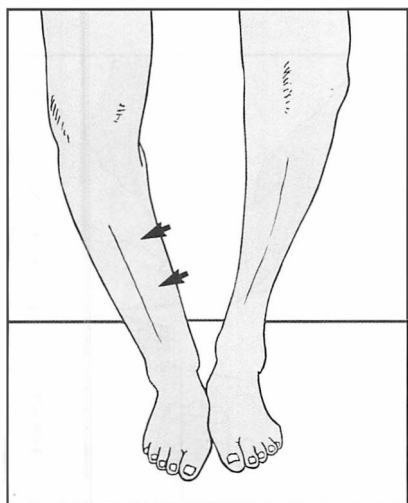
11.1. Inspection (1): Soft tissue swelling: Note the site and extent of any swelling. In the case of oedema, note particularly if bilateral (suggesting a general rather than a local cause). Unilateral leg oedema in women over 40 is a common sign of intrapelvic neoplasm.



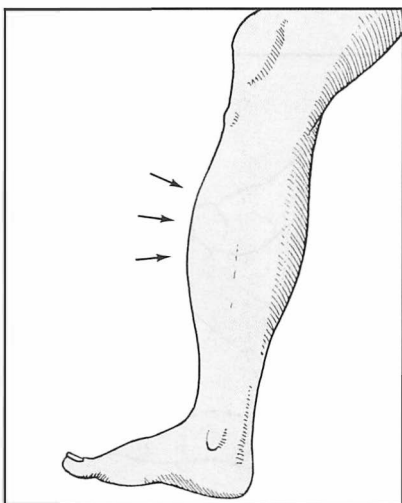
11.2. Inspection (2): Localized oedema: Localized oedema is common over inflammatory lesions and stress fractures.



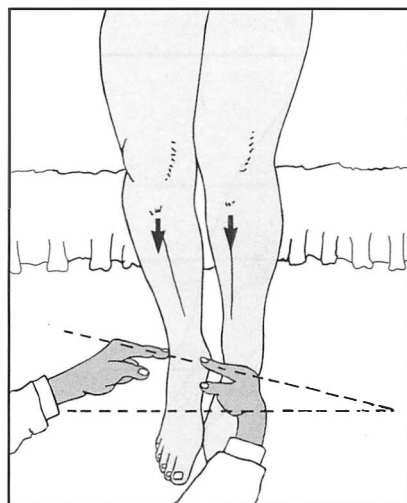
11.3. Inspection (3): Local bone swelling: This is suggestive of neoplasm (e.g. osteoid osteoma) or old fracture. Multiple or single exostoses commonly occur in the tibia in diaphyseal aclasis. Thickening of the ends of the tibia is seen in rickets and in osteoarthritis.



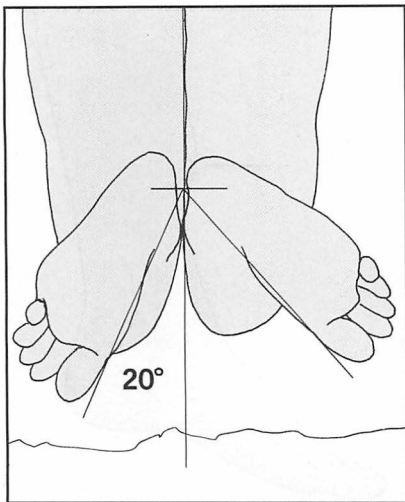
11.4. Inspection (4): General bone thickening: Extensive thickening of bone is characteristic of Paget's disease and long-standing osteitis. In the latter case there are usually other signs, such as scarring or sinuses.



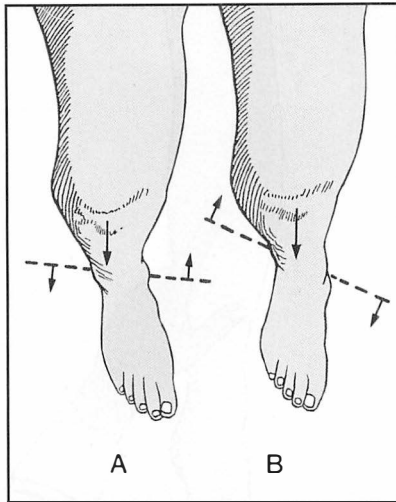
11.5. Inspection (5): Tibial shape: Note any abnormal anterior curvature (tibial kyphosis), possibly secondary to Paget's disease, malunited fracture, syphilis or rickets. Rickets affects the distal half of both tibia and fibula, and there are associated lateral and torsional deformities.



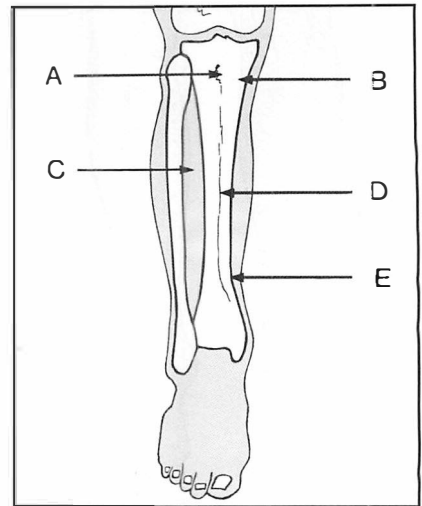
11.6. Tibial torsion (1): Flex the legs over the edge of the examination couch. The tibial tubercles must face directly forwards. Place the index fingers over the malleoli. The medial malleolus normally lies 20° in front of the lateral in the coronal plane).



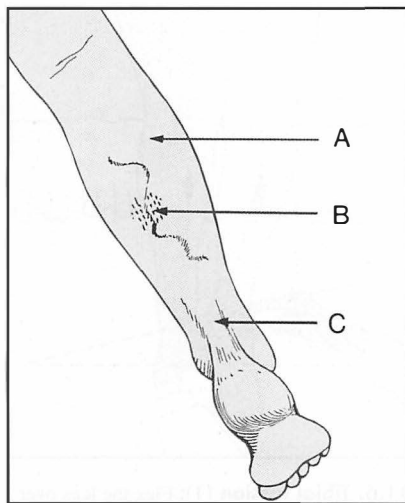
11.7. Tibial torsion (2): Alternatively, examine the patient in the prone position with the knees flexed to 90°. The ankle should be in the neutral position. Note the position of the medial borders of both feet in relation to the midline: this is normally in the region of 20°, but will be greater where there is a lateral tibial torsional deformity (illustrated), and less where there is a medial torsional deformity.



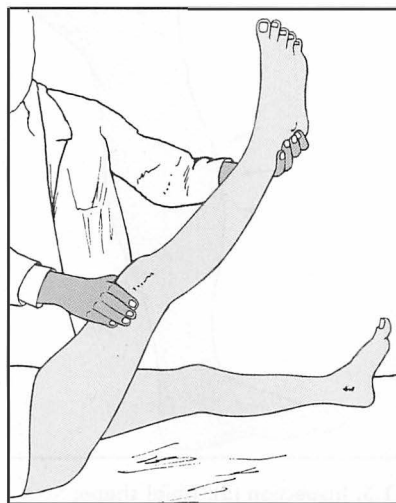
11.8. Tibial torsion (3): (A) *Medial* torsional deformity (a decrease in the angle) is associated with flat foot and intoeing. (B) *Lateral* torsional deformity (an increase in the angle) is seen in pes cavus.



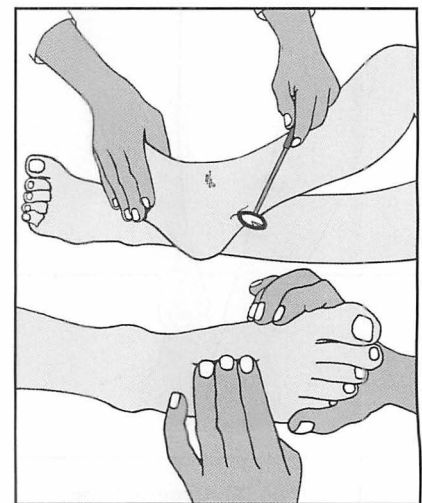
11.9. Tenderness (1): At the front of the leg, tenderness is characteristically sited in the following conditions: (A) Osgood–Schlatter's disease, (B) Brodie's abscess, osteitis, (C) anterior tibial compartment syndrome, (D) stress fracture, (E) shin splints.



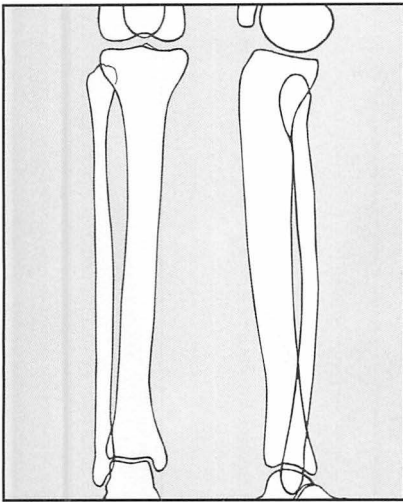
11.10. Tenderness (2): At the back of the leg, tenderness is characteristically situated in the following: (A) 'ruptured plantaris tendon' syndrome, (B) over varicosities in superficial thrombophlebitis, (C) over the tendocalcaneus in partial tears and complete ruptures.



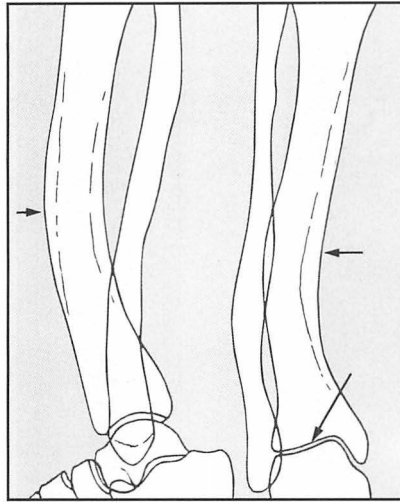
11.11. Screening tests (1): The following tests should be carried out in the investigation of any case of leg pain. The straight leg-raising test should be carried out as a first measure. In many cases pain in the leg below the knee is referred from the spine.



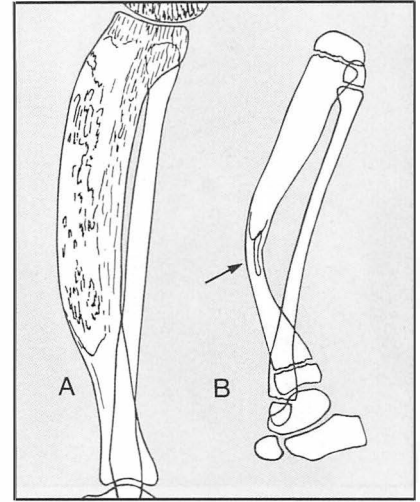
11.12. Screening tests (2): The lower limb reflexes should be elicited, and if indicated, test the pupils for reaction to light and accommodation. Lower leg pain is a common symptom of late syphilis. (3) The peripheral pulses should be sought. Ischaemia is an extremely common cause of leg pain.



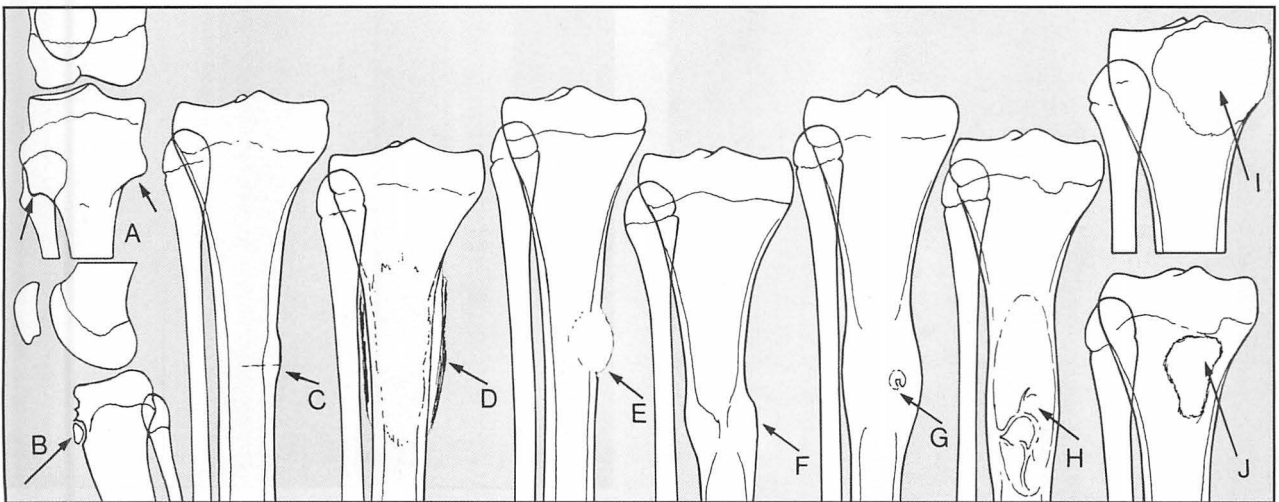
11.13. Radiographs (1): The standard films are an anteroposterior and a lateral which include both ends of the tibia and fibula. For better visualization of a suspect area, localized views are required. CT and MRI scans are often useful, especially in evaluating cystic defects, and radioisotope scans may be helpful in assessing local vascularity.



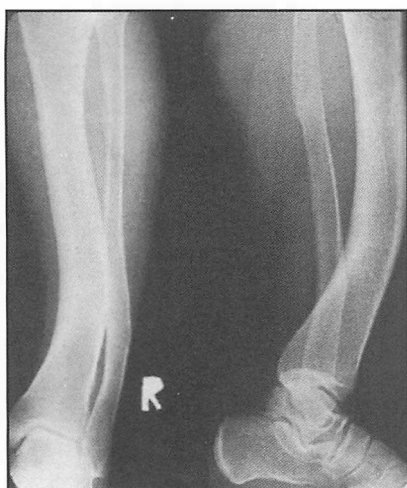11.14. Radiographs (2): Begin by noting the general shape of the bones, their texture and their mineralization. For example, in *rickets* during the phase of bone softening, deformity follows weightbearing. Note angulation of the plane of the ankle (which may theoretically predispose to osteoarthritis).



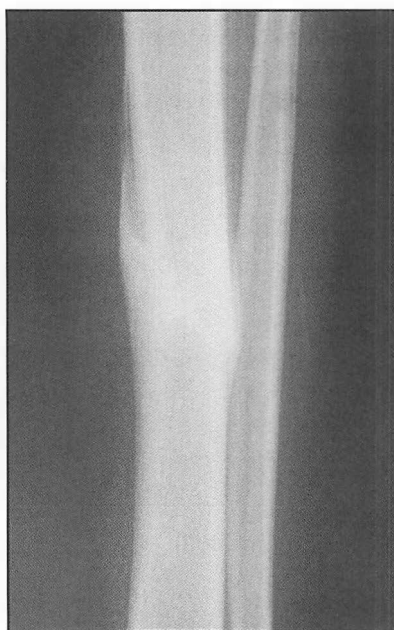11.15. Radiographs (3): Deformity is common in *Paget's disease* (A), where there is disturbance of form and texture, and sometimes sarcomatous change. In *pseudarthrosis of the tibia* (B) there is local thinning and angulation of the bone, which progresses to tibial dissolution, the fibula generally remaining relatively normal.



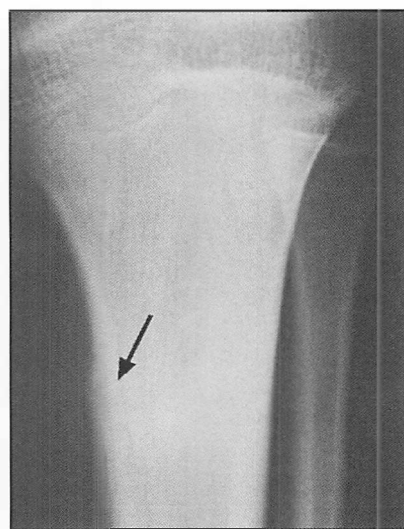
11.16. Radiographs (4): Note any localized deformity such as in (A) diaphyseal aclasis (often several bones are affected); (B) Osgood-Schlatter's disease; (C) localized periosteal reaction in the region of a stress fracture; (D) more extensive subperiosteal new bone formation in the later stages of osteitis, or at the site of a bone tumour. Note (E) cortical bone destruction suggesting a lytic neoplasm or infection. Localized thickening of bone is seen after a healed fracture (F) or again at a tumour site (e.g. in osteoid osteoma, where there is often a central nidus (G)). Examine the cavity and ends of the bone for space-occupying lesions, such as (H) a unicameral bone cyst occurring in the shaft, (I) an osteoclastoma occurring in the epiphysis, and (J) a Brodie's abscess in the metaphysis.



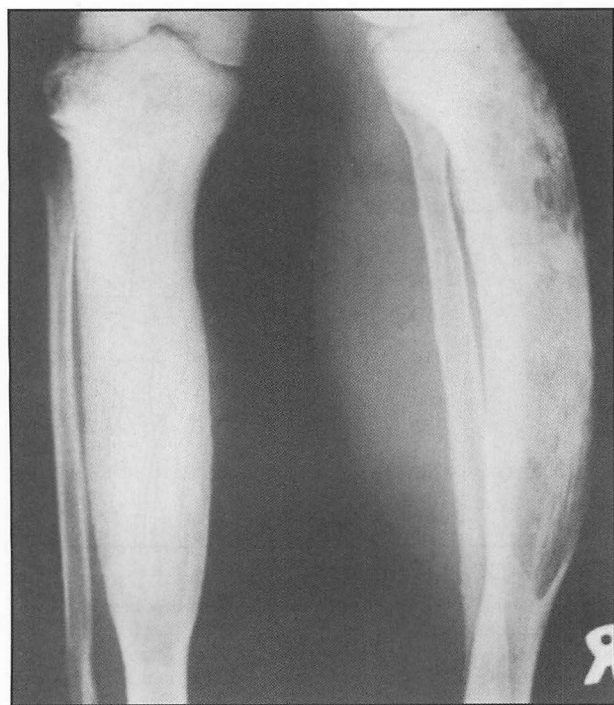11.17. Radiographs of the tibia:
Examples of pathology (1): The radiograph shows curvatures of the tibia and fibula, which are convex both laterally and anteriorly. There is an additional torsional deformity which is not obvious in these films.
Diagnosis: persisting deformity of the tibia following rickets in childhood.



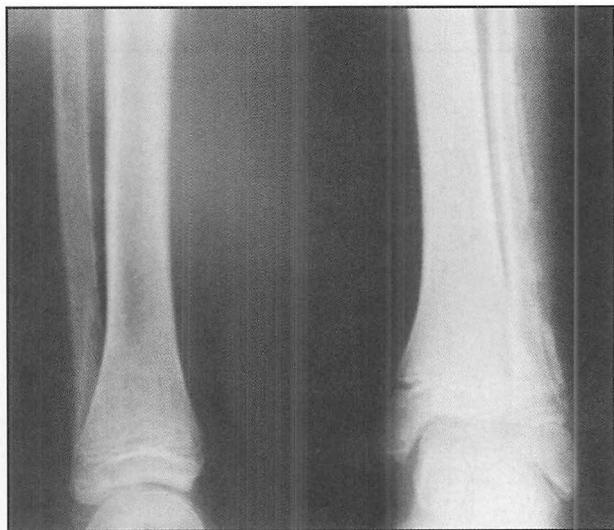11.18. Pathology (2): In the centre of the film the tibia is seen to be locally thickened, and just visible is an area of increased bone density running downwards from left to right.
Diagnosis: old fracture of the midshaft of the tibia.



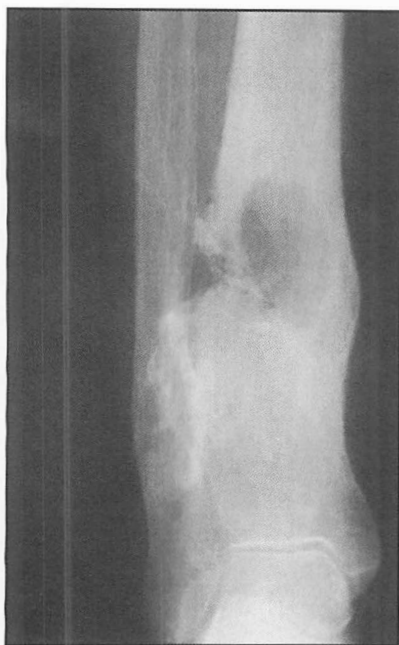11.19. Pathology (3): The arrow points to an area of periosteal reaction with the slight increase in bone density at the same level.
Diagnosis: stress fracture of the tibia.



11.20. Pathology (4): The AP view shows striking alteration in bone texture, with an increase in curvature, convex anteriorly. In both views bone thickening and increased bone density are apparent.
Diagnosis: Paget's disease of the tibia. In this case there was no malignant change.

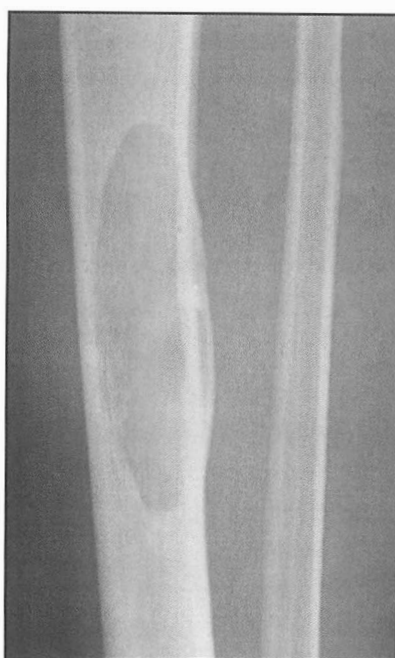

11.21. Pathology (5): In the left fibula (on the right of the picture) there is extensive bone destruction and subperiosteal new bone formation.
Diagnosis: the appearances are characteristic of osteitis some weeks after the onset, which was heralded with fever, malaise, and severe local pain.



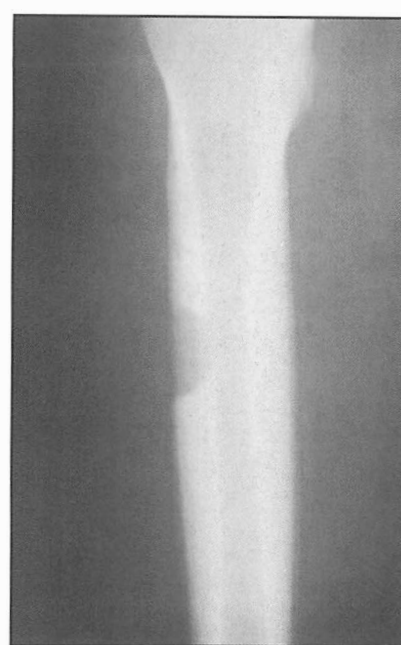
11.22. Pathology (6): There is localized thickening of the tibia, with a large cavity which is open on its lateral aspect.

Diagnosis: Chronic osteitis of the tibia. The cavity in the bone led to a sinus. No sequestra are apparent in the radiograph.



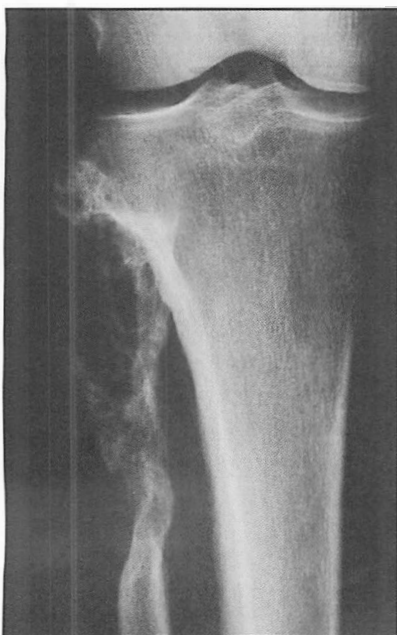
11.23. Pathology (7): There is a large cystic space in the tibia, with well rounded margins.

Diagnosis: unicameral (simple) bone cyst involving the medullary canal of the tibia. Such abnormalities may often be brought to light by a pathological fracture.



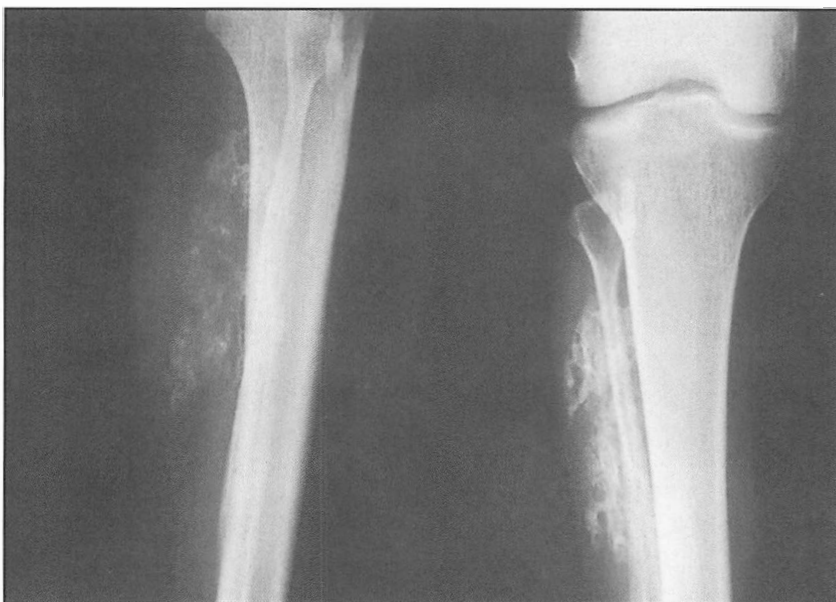11.24. Pathology (8): This radiograph of the femur shows a bony lesion of the shaft with a characteristic punched-out appearance, and secondary thickening of the surrounding bone.

Diagnosis: the appearances are characteristic of a highly malignant Ewing's tumour. Lesions in the tibia are not uncommon and have a similar appearance.



11.25. Pathology (9): There is destruction and gross deformity of the proximal fibula.

Diagnosis: The appearances are typical of osteoclastoma. The tumour in this case was only locally malignant, but was associated with a common peroneal nerve palsy and drop foot.



11.26. Pathology (10): There is an extensive area of new bone formation related to the shaft of the fibula. Although the lesion is more easily seen in the AP projection, its extent is best judged in this case in the lateral. There was a history of local trauma and swelling some weeks before.


Diagnosis: The appearances are typical of myositis ossificans. This was thought to have occurred in a haematoma which had formed on the lateral aspect of the leg following a small crack fracture of the fibula.

CHAPTER

12

The ankle

- Anatomical features 256
- Soft tissue injuries of the ankle 257
- Injuries of the lateral ligament 257
- Inferior tibiofibular ligaments 257
- Medial ligament 257
- Achilles tendon (tendo calcaneus) 258
 - Achilles tendinopathy 258
 - Acute traumatic Achilles tendon rupture 258
 - Insertional tendinitis 258
- Other common conditions seen around the ankle 258
 - Tenosynovitis 258
 - Footballer's ankle 259
 - Osteochondritis of the talus 259
 - Snapping peroneal tendons 259
 - Osteoarthritis 259
 - Rheumatoid arthritis 259
 - Tuberculosis 259
 - Shortening of the Achilles tendon (tendo calcaneus) 259
- Guide to painful conditions around the ankle 260
- Inspection 261
- Tenderness 261
- Lateral ligament 261–262
- Inferior tibiofibular joint 263
- Movements 263–264
- Achilles tendon 264–265
- Tenosynovitis 265–266
- Peroneal tendons and articular surfaces 266–267
- Radiographs 267–268
- Pathology 268–270



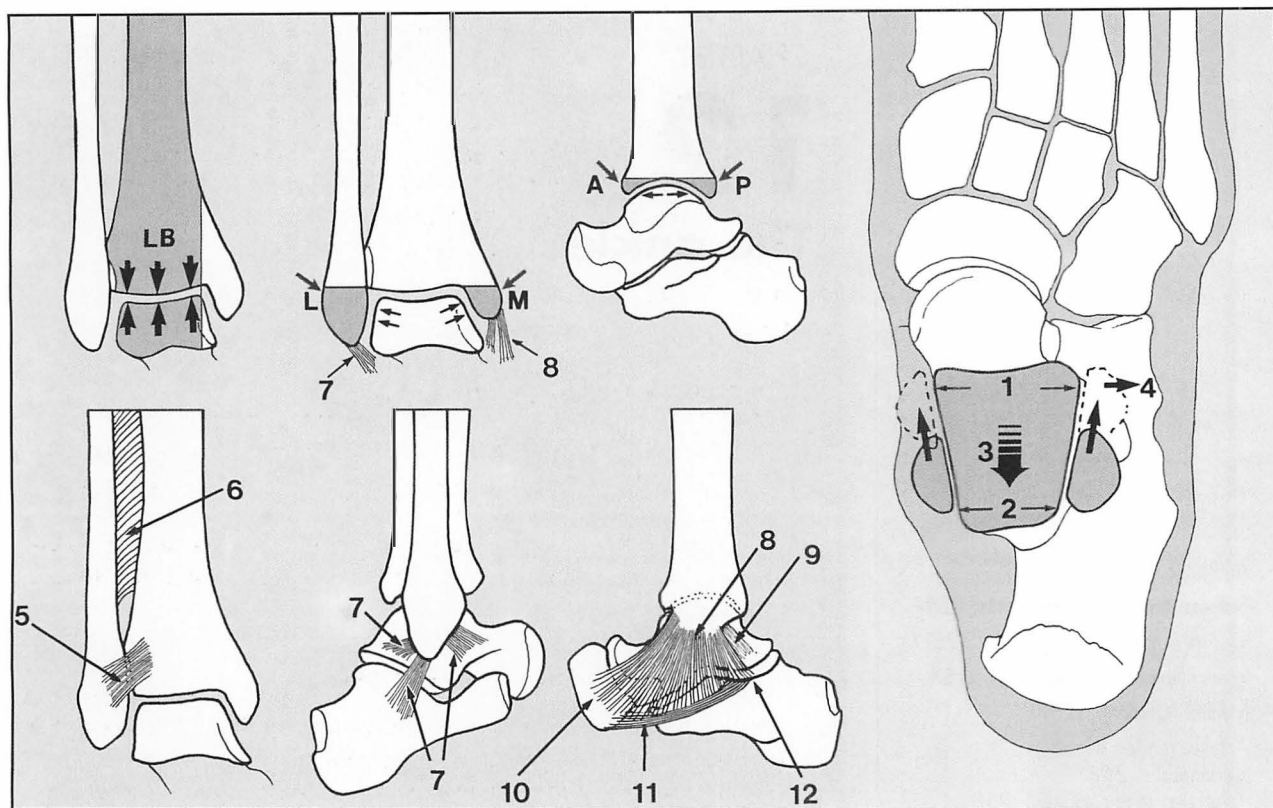


Fig. 12.A

ANATOMICAL FEATURES

The ankle joint is basically a simple hinge joint, normally permitting movement in one plane (dorsiflexion and plantarflexion), but in addition, up to 18° of axial rotation of the talus in the tibial mortise may occur. Load-bearing stresses (LB) are taken by the upper articular surface of the talus and the tibia; the fibula plays no part in this.

Medial displacement (translation) of the talus is prevented by the medial malleolus (M), and *lateral displacement* by the lateral malleolus (L). *Posterior talar shift* is blocked by the downward-projecting curved articular surface of the tibia (P) behind, and the corresponding surface in front (A) prevents *anterior subluxation*. Any of these bony prominences may be fractured, resulting in potential instability.

When viewed from above, the articular surface of the talus may be seen to be wider anteriorly (1) than posteriorly (2). This means that as the ankle is dorsiflexed (3), the talus is gripped more firmly between the malleoli and pushes the fibula laterally (4). When the ankle is plantarflexed there is a greater degree of freedom (and instability) of the talus in the ankle mortise.

The natural congruency of the bony components of the ankle accounts for its inherent stability and this is reinforced by the disposition and strength of the associated ligaments. These include the following:

- (a) The inferior tibiofibular ligaments (anterior and posterior) (5), which bind the tibia to the fibula. They are assisted by the weak interosseous membrane (6).

- (b) The lateral (external) ligament (7) has three parts which arise from the fibula; distally the anterior and posterior fasciculi are attached to the talus, and the central slip is attached to the calcaneus.
- (c) The medial ligament (8), immensely strong, is triangular in shape (hence the alternative term deltoid ligament), and is attached proximally to the medial malleolus. Its deep fibres (9) pass to the medial surface of the talus, and its superficial part is attached to the navicular (10), the spring ligament (11) and the calcaneus (12).

Note that a careful examination of the foot is often also required in the investigation of many ankle complaints.

SOFT TISSUE INJURIES OF THE ANKLE

Soft tissue injuries of the ankle are extremely common and in more severe cases difficult to differentiate from undisplaced fractures. Radiographic examination is essential in all but the most minor lesions, and is also necessary where symptoms are persistent. When fracture has been excluded after a significant injury a diagnosis has still to be made, as this manifestly affects treatment.

INJURIES OF THE LATERAL LIGAMENT

The lateral ligament is damaged through inversion injuries. In an incomplete tear, some fibres only are ruptured (ankle sprain). Treatment is then symptomatic and a full early recovery can be expected. When the ligament is completely torn or detached from the fibula, the talus is free to tilt in the mortice of the tibia and fibula. If the lateral ligament fails to heal, chronic instability of the ankle results. If this injury is diagnosed in the acute stages, it should be treated by prolonged immobilization in a plaster cast or orthosis, or by operative repair. In late-diagnosed cases good results generally follow lateral ligament reconstruction procedures.

In *functional instability of the ankle* the patient complains of frequent sensations of the ankle giving way, and pain, stiffness and swelling related to activity, but no evidence of ligament laxity can be found. It is thought that in many of these cases there is a degree of motor incoordination arising from some disorder of proprioception. Most respond to specialized physiotherapy (using tilt boards and other measures to improve muscular coordination).

INFERIOR TIBIOFIBULAR LIGAMENTS

When the foot is dorsiflexed the distal end of the fibula moves laterally (and proximally) as it is engaged by the wedge-shaped upper articular surface of the talus. This movement is restricted by the inferior tibiofibular ligaments, and to a lesser extent the interosseous membrane. Damage to these structures may lead to lateral displacement of the fibula and lateral drift of the talus (diastasis). In treatment, the talus must be realigned with the tibia and any fibular displacement reduced. This reduction may be held by cross-screwing of the fibula to the tibia, or by plaster fixation.

MEDIAL LIGAMENT

The medial ligament is immensely strong, and if stressed in ankle joint injuries it generally avulses the medial malleolus rather than itself tearing.

Nevertheless, tears do occur, and are seen particularly in conjunction with lateral malleolar fractures. Meticulous reduction of any associated fracture is essential, and this often requires an open procedure. Operative repair of the ligament may be required.

ACHILLES TENDON (TENDO CALCANEUS)

ACHILLES TENDINOPATHY

This generally results from excessive repetitive overload of the tendon to a degree that exceeds its capacity to recover. The preferred term 'tendinopathy' includes a number of conditions which may only be differentiated by direct inspection and histological examination of the tendon or surrounding structures. These include *tendinitis*, where there is a clear inflammatory process involving the tendon; *tendinosis*, where there is collagen degeneration within the tendon; and *paratendinitis*, when there are inflammatory changes in the sheath of the tendon.

The condition is common in athletes, particularly runners and jumpers, but also in footballers, tennis players and ballet dancers. It gives rise to localized pain which is related to lower limb activity. In severe cases of tendinopathy there may be progressive weakness of plantarflexion, accompanied by impaired function and, in some cases, spontaneous rupture of the tendon.

Most cases are treated conservatively by restricting activities, supplemented when required by physiotherapy in the form of tendon stretching exercises, tendon massage, orthotic devices for the shoes, and therapeutic ultrasound. In some resistant case surgical measures such as the removal of fibrotic nodules from within the tendon and the release of tendon adhesions may be required.

ACUTE TRAUMATIC ACHILLES TENDON RUPTURE

Sudden plantarflexion of the foot may rupture the Achilles tendon, especially when it is weakened as a result of tendinosis and the degenerative changes often seen in middle age. Surgical repair may be carried out, although in most cases excellent results may be achieved by conservative management in a plaster cast or an orthosis.

INSERTIONAL TENDINITIS

This condition affects the tendon at its calcaneal insertion in the calcaneus. It tends to occur in middle-aged and overweight patients, and is usually treated conservatively.

OTHER COMMON CONDITIONS SEEN AROUND THE ANKLE

TENOSYNOVITIS

Inflammatory changes in the tendon sheaths behind the malleoli may give rise to pain at the sides of the ankle joint. Tenosynovitis may follow unusual excessive activity or be associated with degenerative changes, flat foot or rheumatoid arthritis. There is puffy swelling in the line of the tendons, with tenderness extending often for several centimetres along their length. Tibialis posterior and peroneus longus are most frequently involved, and stretching of these structures during inversion and eversion of the foot gives rise to pain. Spontaneous rupture is not uncommon. Symptoms generally respond to

immobilization for short periods in a below-knee walking plaster or an orthosis.

FOOTBALLER'S ANKLE

Ill-localized pain in the front of the ankle may follow repeated incidents of forced plantarflexion of the foot which result in tearing of the anterior capsule of the ankle joint. This occurs frequently in footballers, where this form of stress is common. Calcification in the resulting areas of avulsion and haemorrhage leads to the appearance of characteristic exostoses, which show in lateral radiographic projections of the ankle. These may lead to mechanical restriction of dorsiflexion.

OSTEOCHONDritis OF THE TALUS

Although rather uncommon, this condition, which is seen most frequently in adolescents and young men, may give disabling pain in the ankle. It is now generally agreed that the condition starts as an osteochondral fracture. It is the frequent source of complaints of chronic disability following a so-called simple sprain of the ankle. The diagnosis is made on the radiological findings, although the site of the pain and local tenderness over the upper articular surface of the talus may lead one to suspect it. CT and MRI scans are invaluable in doubtful cases. If loose bodies are produced, they must be excised. The treatment of the local lesion follows in principle that of osteochondritis dissecans of the knee.

SNAPPING PERONEAL TENDONS

This is an uncommon cause of ankle pain and is due to tearing of the superior peroneal retinaculum. The patient complains of a clicking sensation in the ankle and is usually able to demonstrate the peroneal tendons riding over the lateral malleolus. The treatment is by surgical reconstruction of the retinaculum.

OSTEOARTHRITIS

Primary osteoarthritis of the ankle is rare. Secondary osteoarthritis is sometimes seen after ankle fractures, avascular necrosis of the talus, or osteochondritis of the talus.

RHEUMATOID ARTHRITIS

Rheumatoid arthritis of the ankle is not uncommon but is seldom seen as a primary manifestation of the disease, so that the diagnosis seldom presents difficulty.

TUBERCULOSIS

Tuberculous infections of the ankle joint are now rare in the UK. When they occur there is swelling of the joint, wasting of the calf, and the usual signs of inflammation. The patient develops a painful limp, and as the joint is comparatively superficial, sinus formation is common at a comparatively early stage.

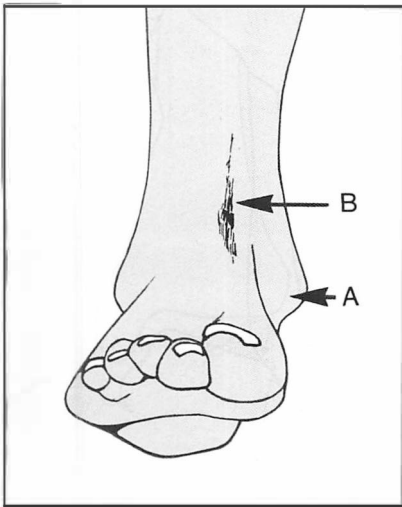
SHORTENING OF THE ACHILLES TENDON (TENDO CALCANEUS)

Shortening of the Achilles tendon results in plantarflexion of the foot and clumsiness of gait as the heel fails to reach the ground. The more severe

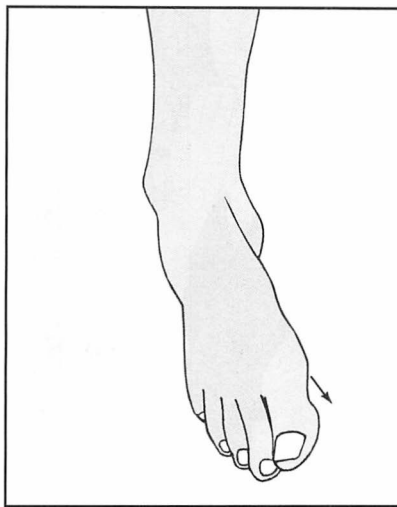
degrees of Achilles tendon shortening are accompanied by a tendency to flat foot. In many cases flexion of the knee, by taking the tension off the gastrocnemius, will permit dorsiflexion of the foot. Shortening of the Achilles tendon may occur as an apparently isolated condition with no obvious predisposing cause, but in a great many cases it is associated with congenital deformities of the foot or neurological disorders, of which subclinical poliomyelitis is one of the most common (for talipes deformities see Foot section). Occasionally it may result from ischaemic contracture of the calf muscles.

GUIDE TO PAINFUL CONDITIONS AROUND THE ANKLE

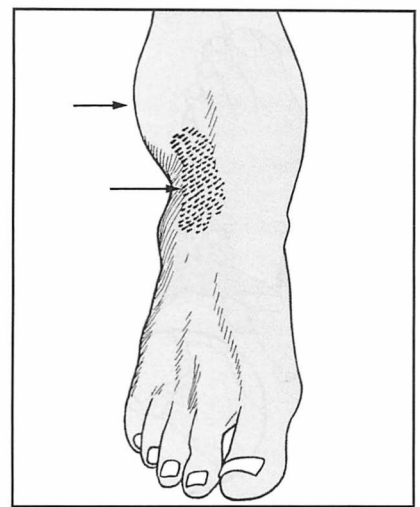
History of recent injury	Sprain of lateral ligament
	Complete tear of lateral ligament
	(Ankle fracture, fracture of the fifth metatarsal base)
	Tibiofibular diastasis
History of past injury	Ruptured Achilles tendon (tendo calcaneus)
No history of injury	Complete tear of lateral ligament
	Secondary osteoarthritis (e.g. previous ankle fracture)
	Osteochondritis tali
	Rheumatoid arthritis
	Primary osteoarthritis
	Footballer's ankle
	Secondary osteoarthritis (e.g. from osteochondritis tali)
	Tenosynovitis
	Achilles tendinopathy
	Snapping peroneal tendons



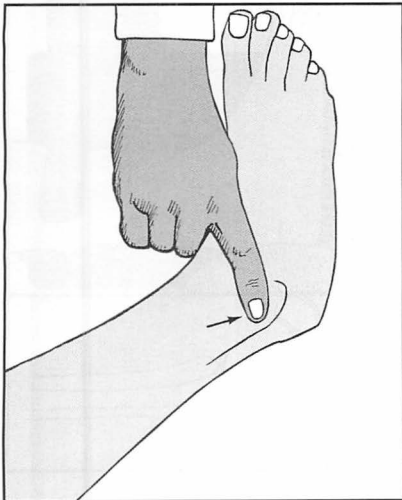
12.1. Inspection (1): Look for (A) deformity of shape, suggesting recent or old fracture; (B) sinus scars, suggesting old infection, particularly tuberculosis.



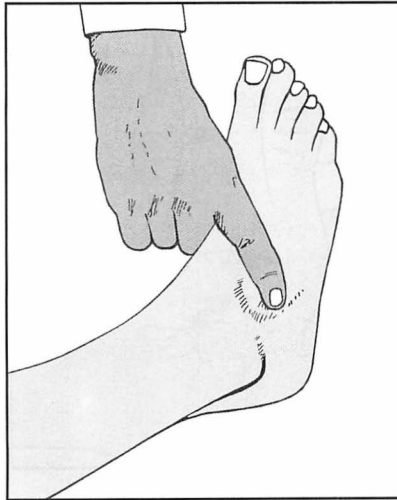
12.2. Inspection (2): Look for deformity of posture (e.g. plantarflexion owing to short tendo calcaneus, talipes deformity, ruptured tendo calcaneus or drop foot).



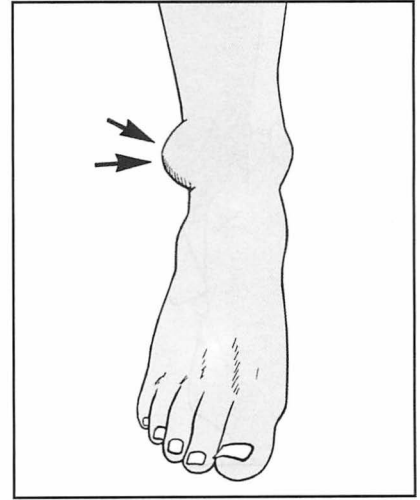
12.3. Inspection (3): Look for bruising, swelling or oedema. If there is any swelling, note whether it is diffuse or localized. Note also whether oedema is bilateral, suggesting a systemic rather than a local cause.



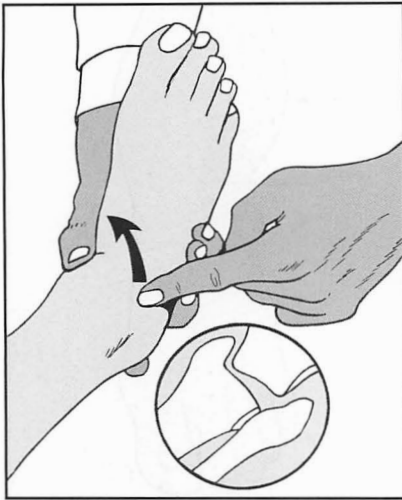12.4. Tenderness (1): When there is tenderness localized over the malleoli following injury, radiographic examination is necessary to exclude fracture.



12.5. Tenderness (2): After inversion sprains, tenderness is often diffuse. Swelling to begin with lies in the line of the fasciculi of the lateral ligament.



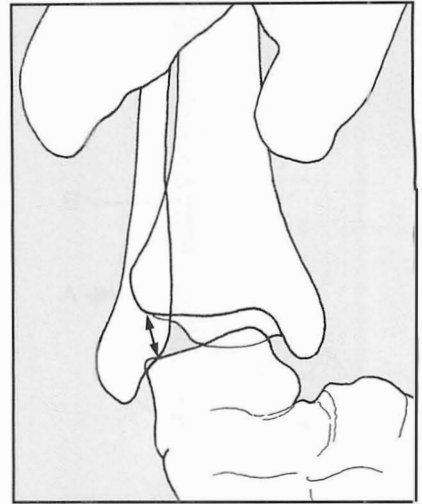
12.6. Lateral ligament (1): Complete lateral ligament tear: Swelling is rapid, and if seen within 2 hours of injury is egg-shaped and placed over the lateral malleolus (McKenzie's sign).



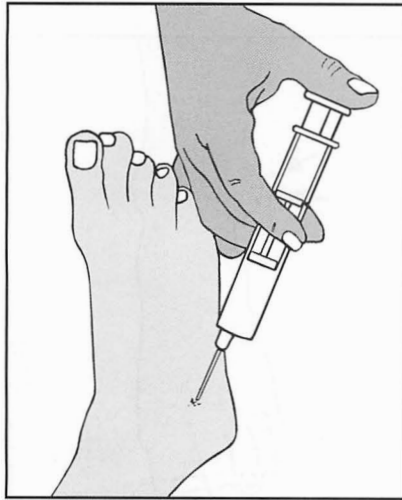
12.7. Lateral ligament (2): Stress testing for complete lateral ligament tears (1): Grasp the heel and forcibly invert the foot, feeling for any opening-up of the lateral side of the ankle between the tibia and the talus.



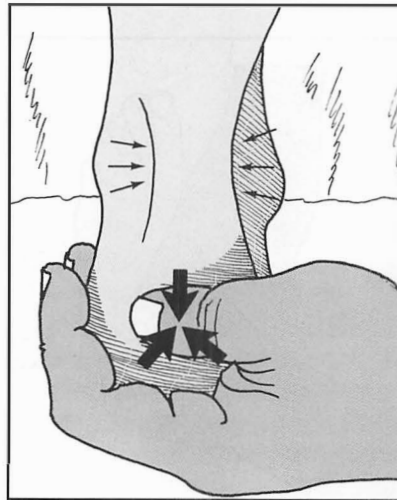
12.8. Lateral ligament (3): Stress testing for complete lateral ligament tears (2): If in doubt, have a radiograph taken while the foot is forcibly inverted.



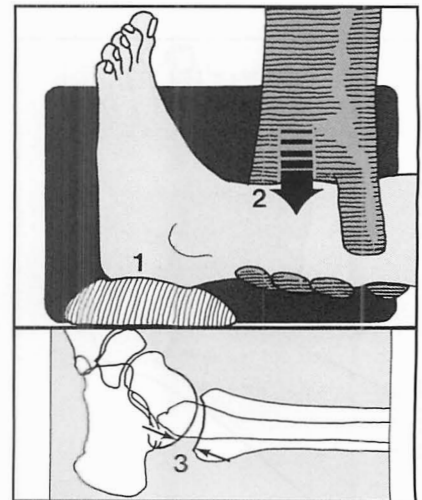
12.9. Lateral ligament (4): Stress testing for complete lateral ligament tears (3): If tilting of the talus in the ankle mortise is demonstrated, repeat the examination on the other side and compare the films.



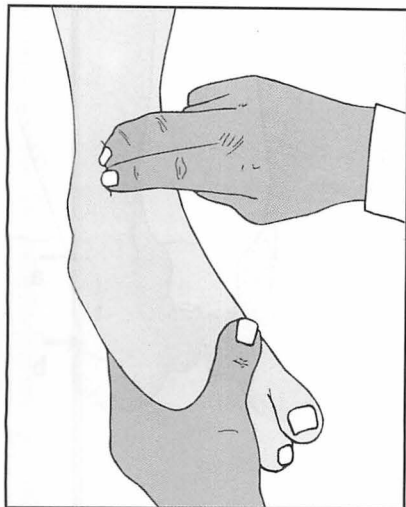
12.10. Lateral ligament (5): Stress testing for complete lateral ligament tears (4): If the injury is fresh and painful, the examination may be more readily permitted after the injection of 15–20 mL of 0.5% lignocaine widely in the region of the lateral ligament.



12.11. Lateral ligament (6): Stress testing of the anterior talofibular component of the lateral ligament (1): Instability may sometimes follow tears of the anterior talofibular portion only of the lateral ligament. With the patient prone, press downwards on the heel, looking for anterior displacement of the talus, which is often accompanied by dimpling of the skin on either side of the tendo calcaneus.

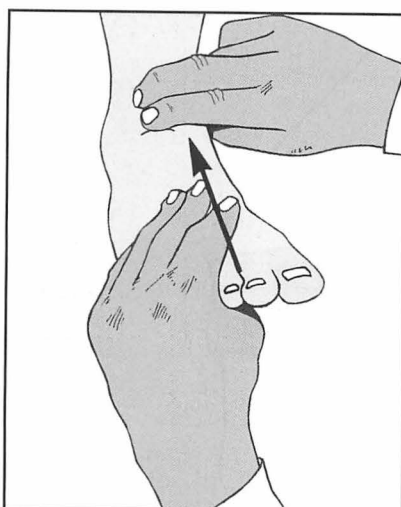


12.12. Lateral ligament (6): Stress testing of the anterior tibiofibular ligament (2): Anterior displacement may be confirmed by radiographs taken in the prone position; alternatively, with the patient supine (and preferably with local anaesthesia), support the heel on a sandbag (1) and press firmly downwards on the tibia (2) for 30 seconds up to exposure. A gap on the radiograph between the talus and tibia of more than 6 mm is regarded as pathological (3).



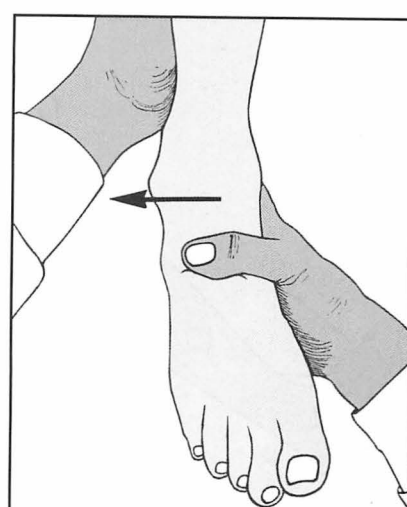
12.13. Inferior tibiofibular ligament

(1): In tears of this ligament (which has anterior and posterior components) tenderness is present over the ligament just above the line of the ankle joint.



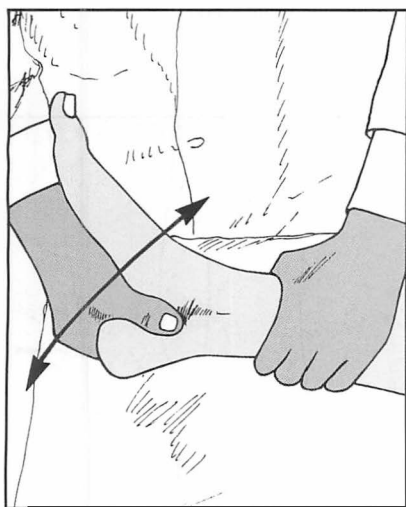
12.14. Inferior tibiofibular ligament

(2): In tears of the inferior tibiofibular ligament pain is produced by dorsiflexion of the foot, which displaces the fibula laterally.

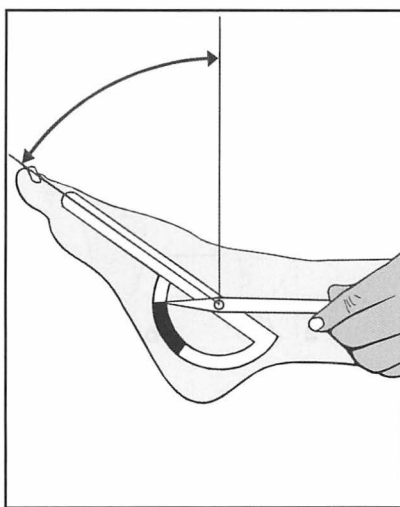


12.15. Inferior tibiofibular ligament

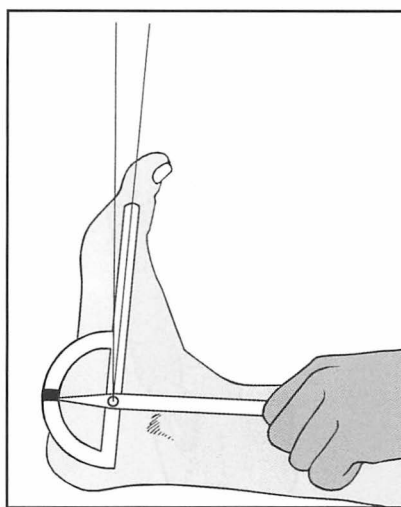
(3): Grasp the heel and try to move the talus directly laterally in the ankle mortise. Lateral displacement indicates a tear of the ligament.



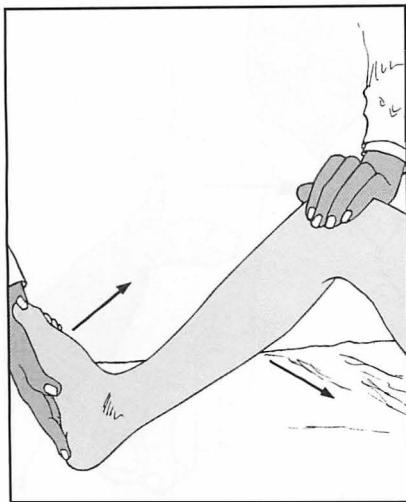
12.16. Ankle joint movements (1): First confirm that the ankle is mobile, and that any apparent movement is not arising in the midtarsal or more distal joints. Firmly grasp the foot proximal to the midtarsal joint; try to produce dorsiflexion and plantarflexion.



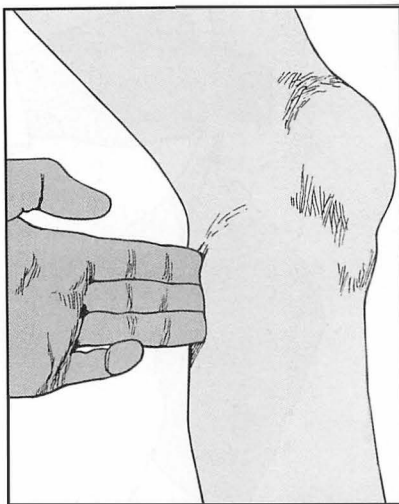
12.17. Ankle joint movements (2): Measure plantarflexion from the zero position. This reference lies at right-angles to the line of the leg.
Normal range = 55°.



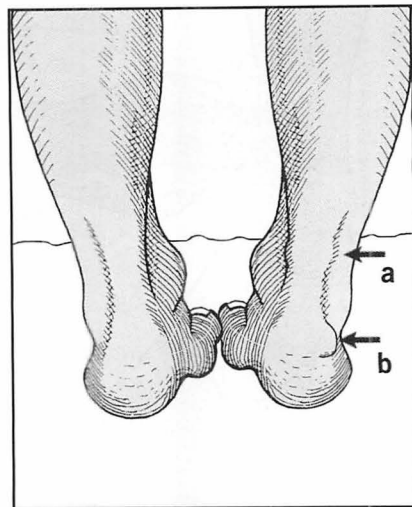
12.18. Ankle joint movements (3): Measure the range of dorsiflexion. Always compare the sides.
Normal range = 15°.



12.19. Ankle joint movements (4): If dorsiflexion is restricted, bend the knee. If this restores a normal range, the Achilles tendon is tight. If it makes no difference, joint pathology (such as osteoarthritis, rheumatoid arthritis or infection) is the likely cause.

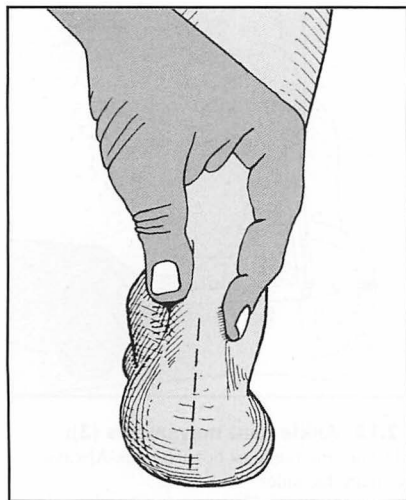


12.20. Ankle joint movements (5): If there is loss of active dorsiflexion (drop foot) a full neurological examination is required. The commonest causes are stroke, old poliomyelitis, prolapsed lumbar intervertebral discs, and local lesions of the common peroneal (lateral popliteal) nerve.



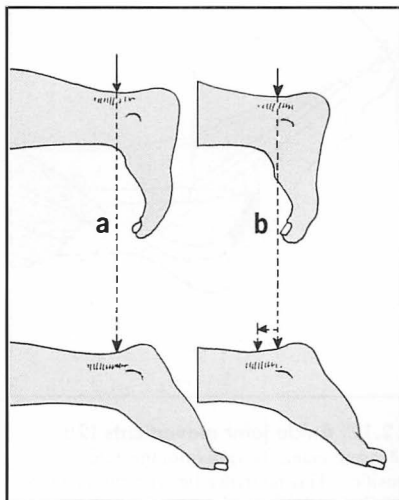
12.21. Tendo calcaneus (Achilles tendon): Suspected tendinopathy (1):

The patient should be prone, with the feet over the edge of the couch. Inspect and compare the sides. Note any local (a) or diffuse swelling, redness of the skin, or the presence of a Haglund deformity (b): this is an exostosis affecting the posteromedial aspect of the heel on its lateral aspect. It is commonly associated with an Achilles insertional tendinitis, although it does not directly involve the tendon.



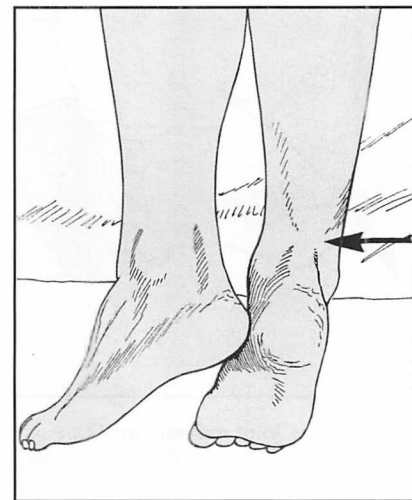
12.22. Suspected tendinopathy (2):

Now look for tenderness, which in the case of a tendinopathy is normally situated 3–5 cm proximal to the tendon insertion. Check for any increase in local heat. Palpate the tendon, noting any localized or fusiform swelling, and any nodularity. Gently squeeze the tendon (illus.); marked pain is a feature of tendinosis with an associated paratendinitis.



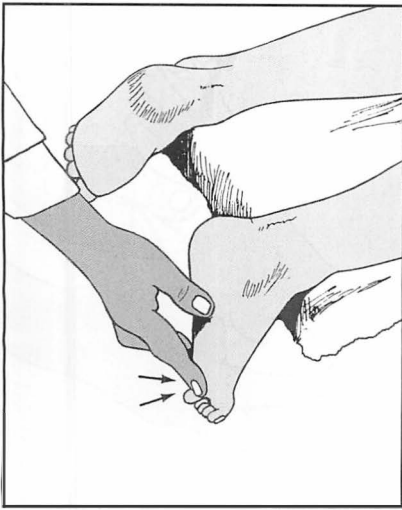12.23. Suspected tendinopathy (3):

If tenderness is found, note whether the site of maximum tenderness changes with dorsiflexion and plantarflexion of the foot. If the pain is secondary to paratendinitis the site of maximum tenderness will remain fixed (a). If it is due to tendinosis alone, it will move with the tendon (b). Note also any weakness of plantarflexion.

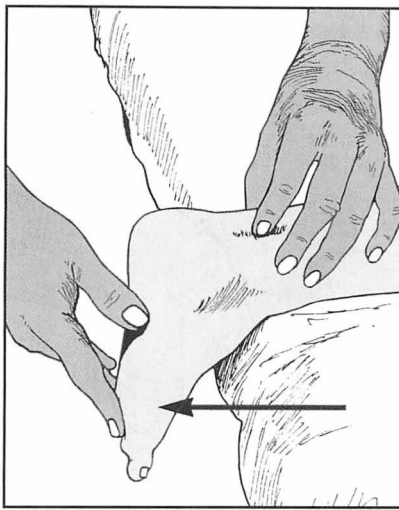

12.24. Suspected tendon rupture (1):

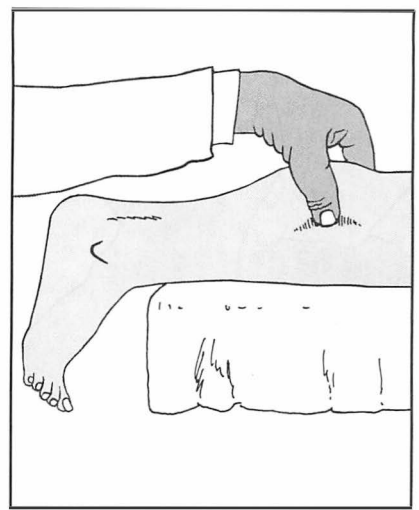
Again the patient should be examined with the feet over the end of the couch. Defects in the contour of the tendon may be obvious.



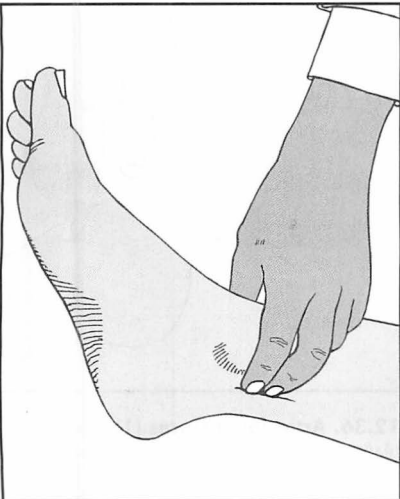
12.25. Tendo calcaneus (2): Test the power of plantarflexion by asking the patient to press the foot against your hand. Compare one side with the other, and note the shape of each contracting calf and the prominence of each tendon.



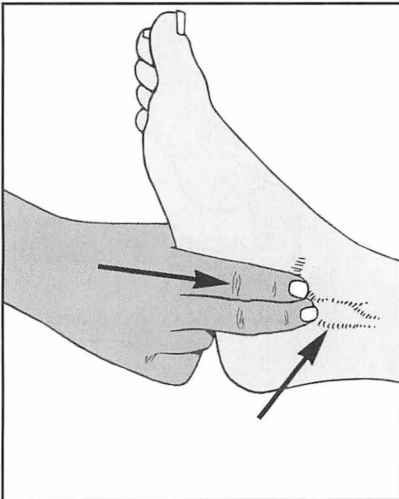
12.26. Tendo calcaneus (3): Palpate the tendon while the patient continues resisted plantarflexion. Compare the sides. Any gap in the tendon (ruptured tendo calcaneus) should be obvious. The integrity of the tendon may also be tested by inserting a needle vertically into the middle of the calf. Normally the needle should tilt when the ankle is passively dorsiflexed and plantarflexed.



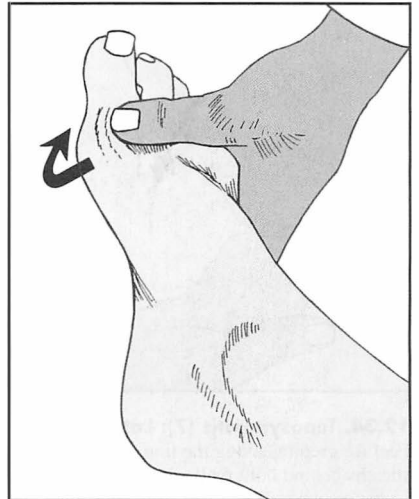
12.27. Tendo calcaneus (4): Thomson test: Normally when the calf is squeezed the foot moves as the ankle plantarflexes. Loss of this movement is pathognomonic of an acute rupture of the tendo calcaneus.



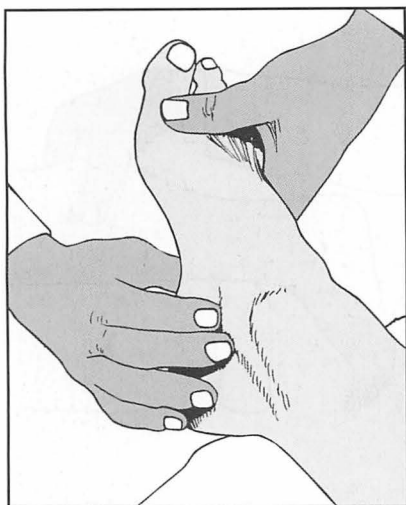
12.28. Tenosynovitis (1): Medial (1): Look for tenderness along the line of the long flexor tendons. Tenderness is usually diffuse and linear in pattern. Note the site and extent of any local thickening.



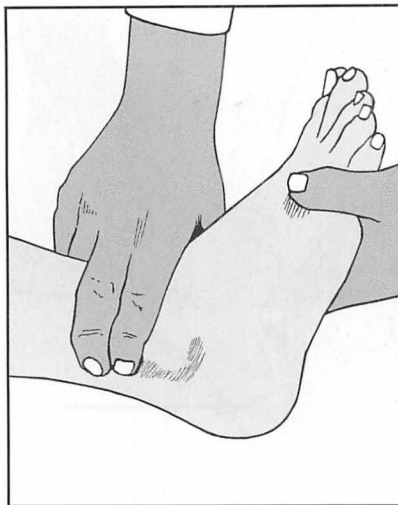
12.29. Tenosynovitis (2): Medial (2): Look for synovitis in relation to the flexor tendons. There may be obvious swelling. Demonstrate the presence of any excess synovial fluid by milking the tendon sheaths in a proximal direction.



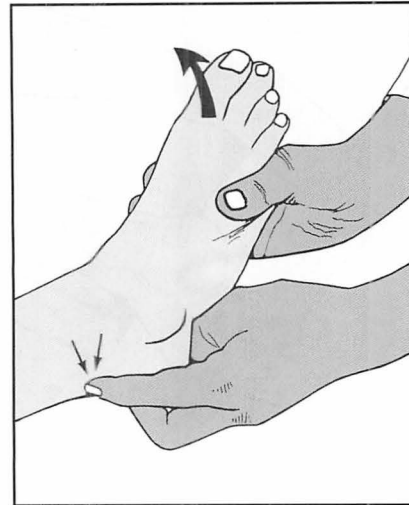
12.30. Tenosynovitis (3): Medial (3): Plantarflex and evert the foot. This may produce pain where tenosynovitis involves the tendon of tibialis posterior.


12.31. Tenosynovitis (4): Medial (4):

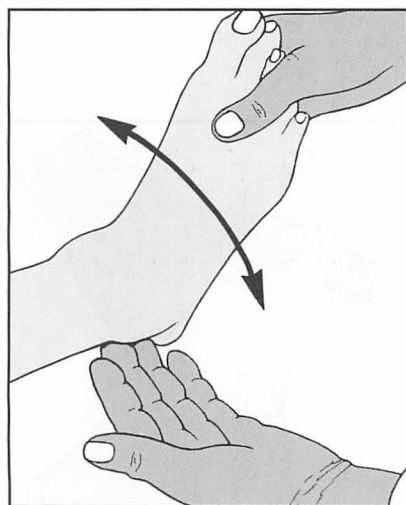
With the foot held in the plantarflexed and everted position, look for tenderness or gaps in the line of the tendon of tibialis posterior. Spontaneous rupture is seen most frequently in association with flat foot and rheumatoid arthritis.


12.32. Tenosynovitis (5): Lateral (1):

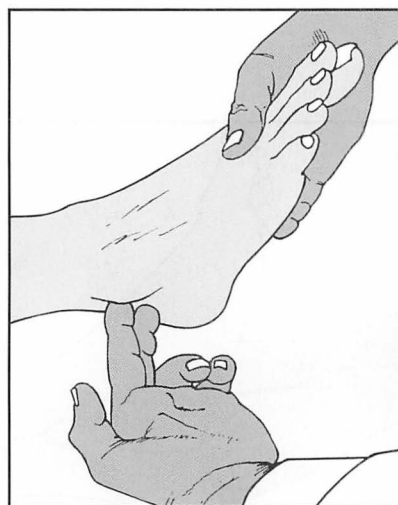Examine the peroneal tendons for tenderness and the presence of excess synovial fluid in their sheaths.


12.33. Tenosynovitis (6): Lateral (2):

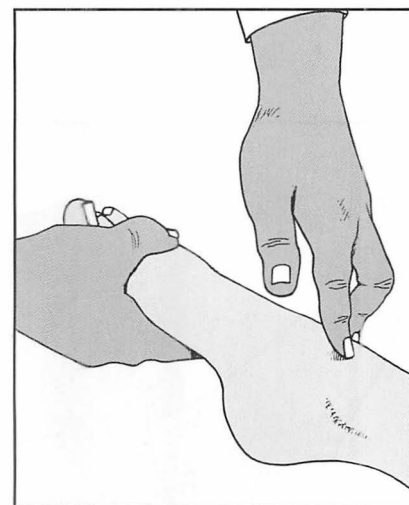
Force the foot into plantarflexion and inversion. This will give rise to pain and increased tenderness along the line of the peroneal tendons if tenosynovitis of the peroneal tendons is present.


12.34. Tenosynovitis (7): Lateral (3):

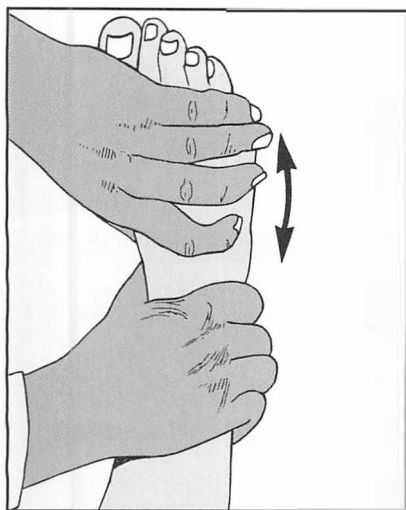
Feel for crepitus along the line of the tendon sheaths behind both malleoli as the foot is swung backwards and forwards between inversion and eversion. Confirm by auscultation.



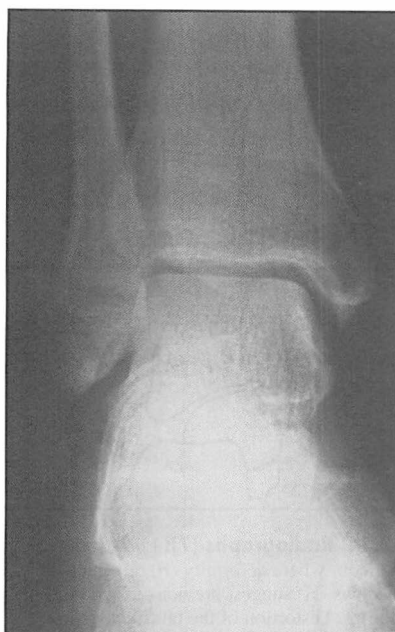12.35. Peroneal tendons: Lightly palpate the peroneal tendons with the fingers; look and feel for displacement of the tendons as the patient everts the foot against light resistance. Displacement occurs in the condition known as 'snapping peroneal tendons'.



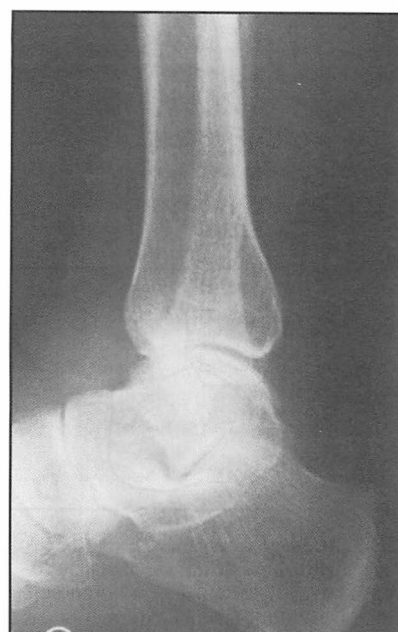
12.36. Articular surfaces (1): Forcibly plantarflex the foot to allow palpation of the anterior part of the superior articular surface of the talus. Tenderness occurs in arthritic conditions, and in osteochondritis of the talus. A tender exostosis may be palpable in cases of footballer's ankle.



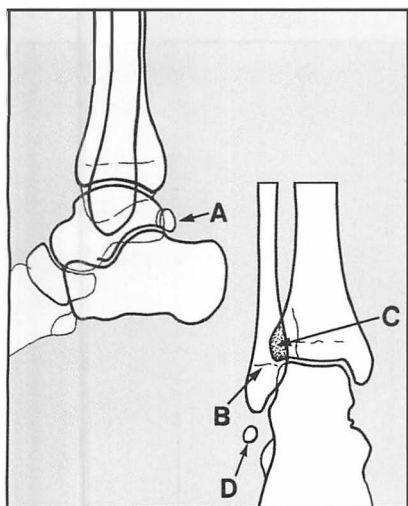
12.37. Articular surfaces (2): Place a hand across the front of the ankle and passively dorsiflex and plantarflex the foot. Crepitus, which may be confirmed by auscultation, suggests articular surface damage.



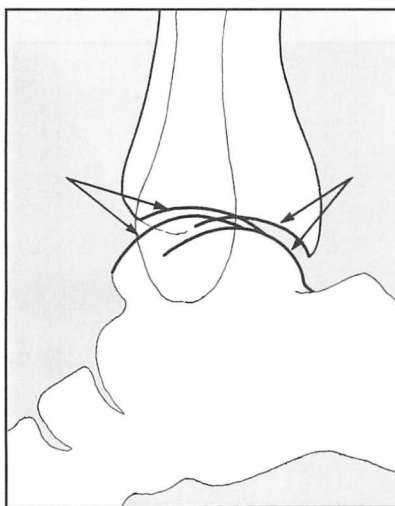
12.38. Radiographs (1): Normal anteroposterior radiograph of the ankle.



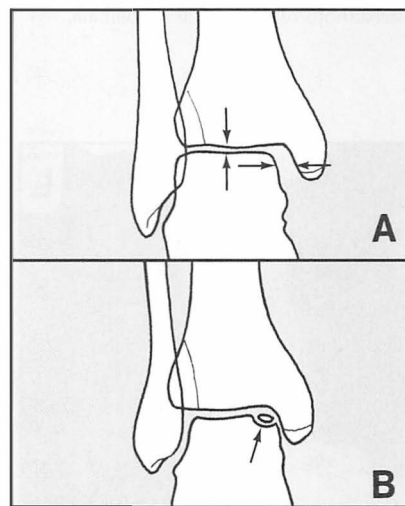
12.39. Radiographs (2): Normal lateral radiograph of the ankle.



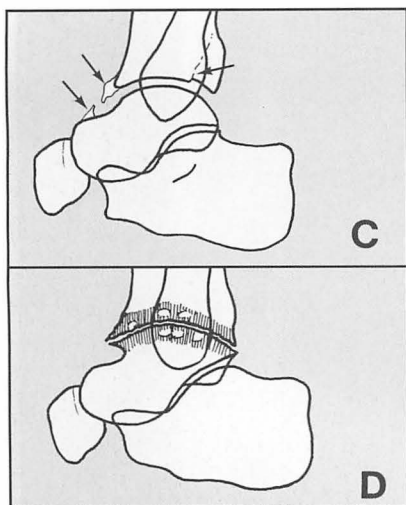
12.40. Radiographs (3): In the standard AP and lateral projections do not mistake (A) the common os trigonum accessory bone and (B) the epiphyseal line of the fibula for fractures. The amount of tibiofibular overlap (C) is dependent on positioning and any diastasis. The os fibulare (D) is thought to represent an avulsion of the anterior talofibular ligament, and may be associated with instability.



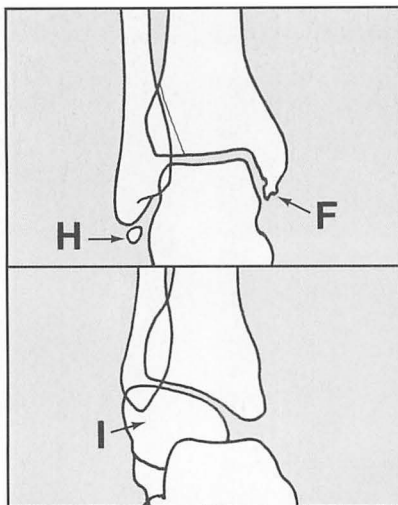
12.41. Radiographs (4): The articular margins of tibia and talus should appear as two congruent circular arcs. If there is some difficulty in positioning that cannot be improved upon, four arcs will be seen. Two pairs should be congruent, as shown. If not, there is a subluxation.



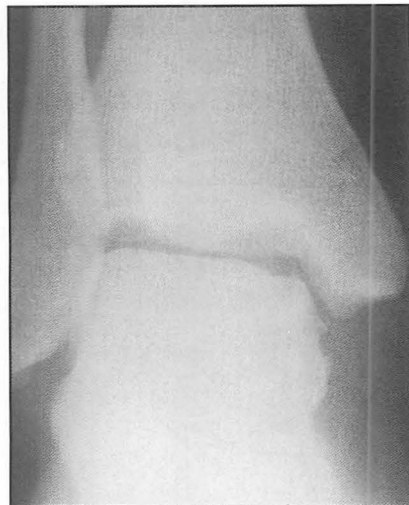
12.42. Radiographs (5): Note any widening of the gap (A) between talus and medial malleolus: this is suggestive of diastasis (compare its size with the one between the upper surface of talus and the tibia: they should normally be equal). (B) Note the presence of any defects in the articular surface of the talus, suggestive of osteochondritis tali. CT and MRI scans may help in the doubtful case.



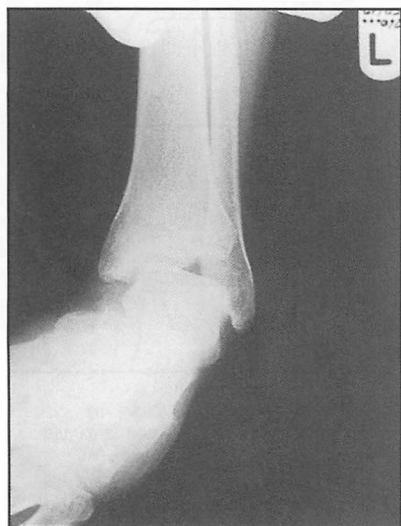
12.43. Radiographs (6): (C) Note any irregularity in the joint surfaces that may suggest previous fracture, e.g. of the posterior malleolus; note any anterior exostoses of the tibia (and/or the talus), which are a feature of footballer's ankle. (D) Examine the articular margins for exostoses, joint space narrowing and cystic change, which are common features of osteoarthritis. If these are present, look for a possible cause (such as osteochondritis dissecans), as primary osteoarthritis of the ankle is uncommon.



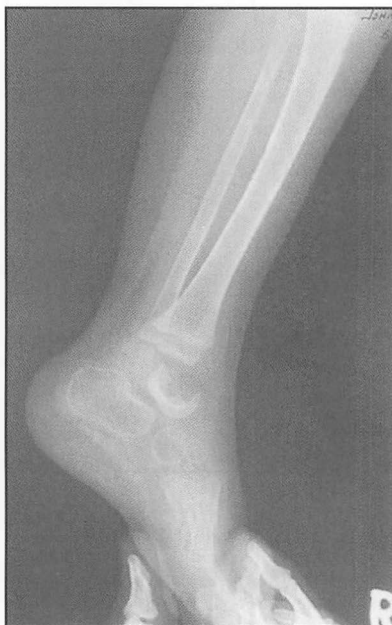12.44. Radiographs (7): Look at the malleoli, where deformity (F) or rounded shadows (H) suggest previous avulsion injuries. Distortion of the talus occurs in association with talipes deformities (I) and after injuries which have resulted in avascular necrosis, and where there may be increases in bone density.



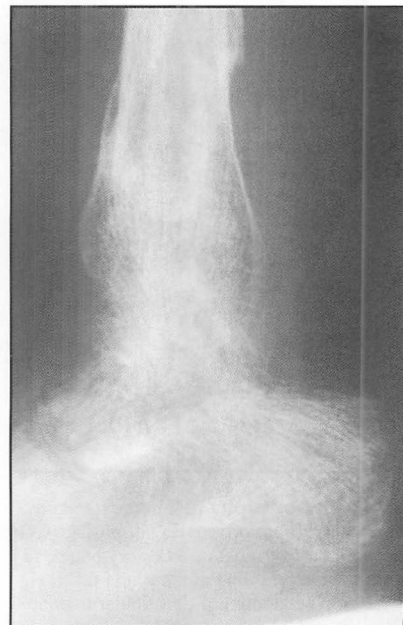
12.45. Radiographs of the ankle: Examples of pathology (1): The upper articular surface of the talus is distorted on its medial side.
Diagnosis: the appearances are typical of osteochondritis dissecans. More complete assessment of the defect may be obtained by a CT or MRI scan.



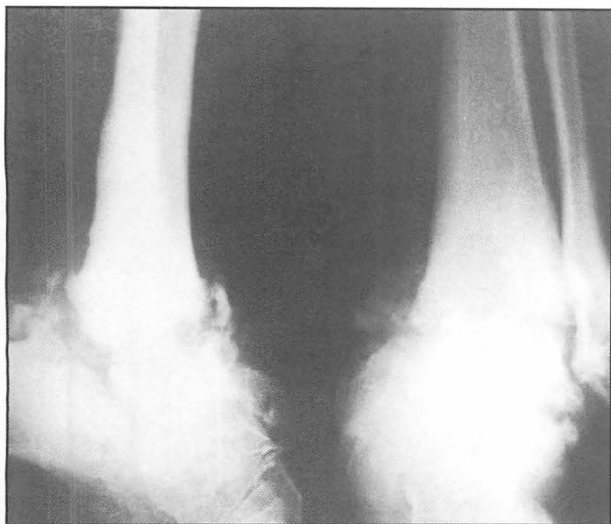12.46. Pathology (2): This inversion film shows tilting of the talus in the ankle mortice. There was no tilting elicited in comparison films of the other side.
Diagnosis: unilateral complete tear of the lateral ligament.



12.47. Pathology (3): There is a large defect in the talus, which also shows increased density inferiorly.
Diagnosis: tuberculosis of the ankle with gross involvement of the talus.

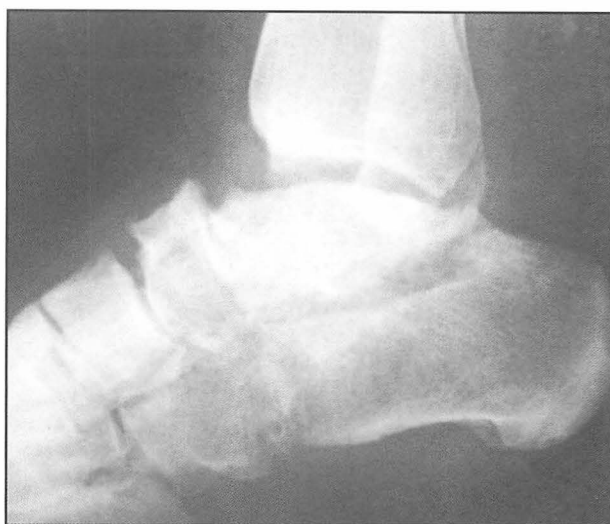

12.48. Pathology (4): There is gross decalcification of the ankle following a minor fracture in the foot. The ankle was stiff and painful, and there was marked swelling of the foot and leg below the knee.
Diagnosis: Sudeck's atrophy (post-traumatic osteodystrophy, complex regional pain syndrome).



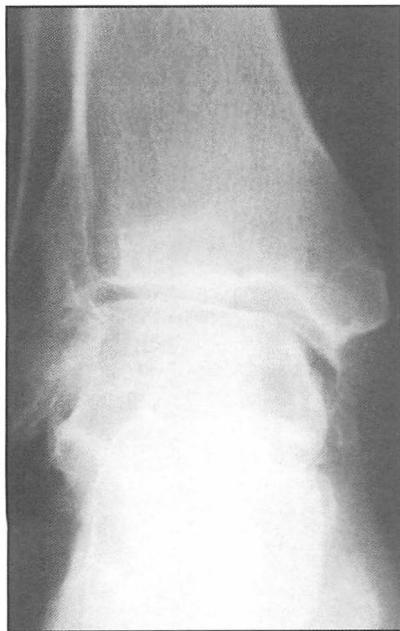12.49. Pathology (4): The radiographs show gross disorganization of the ankle.

Diagnosis: Neuropathic ankle joint (Charcot's disease). In this case the pathology was syphilitic in origin.



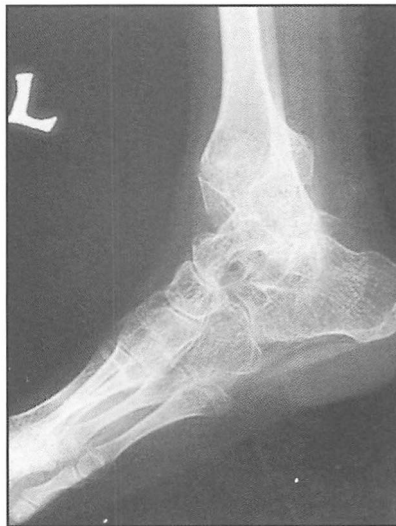12.50. Pathology (5): The talus is grossly misshapen and its upper articular surface flattened; clinically this was associated with pain, swelling and stiffness of the ankle and foot. There was a history of a severe injury to the ankle and foot a year previously.

Diagnosis: compression failure of the talus from avascular necrosis, with secondary osteoarthritic change. This occurred as a sequel to a dislocation of the talus, in spite of a good reduction.



12.51. Pathology (6): There is narrowing of the joint space and the rounding of the upper articular surface of the talus (known as a so-called 'ball and socket' ankle joint).

Diagnosis: osteoarthritis of the ankle. This was secondary to fracture, although all traces of this in the AP projection have disappeared.



12.52. Pathology (7): The bones of the ankle and foot show evidence of disuse osteoporosis, having a ground-glass appearance outlined with narrow, dense cortical margins. The ankle joint space is absent, and there is bony continuity between the talus and the tibia.

Diagnosis: bony ankylosis of the ankle following a chronic joint infection (TB).

CHAPTER

13

The foot

Anatomical features 272

Conditions commencing or seen first
in childhood 275

Talipes equinovarus 275

Talipes calcaneus 276

Skew foot 276

Intoeing 276

Flat foot 276

Pes covus 276

Kohler's disease 277

Sever's disease 277

Conditions affecting the adolescent
foot 277

Hallux valgus 277

Peroneal (spastic) flat foot 278

Exostoses 278

Conditions affecting the adult
foot 278

Hallux rigidus 278

Adult flat foot 279

Splay foot 279

Anterior metatarsalgia 279

Morch fracture 280

Freiberg's disease 280

Plantar (digital) neuroma (Morton's
metatarsalgia) 280

Verruca pedis (plantar wart) 280

Plantar fasciitis 280

Mallet toe, hammer toe, claw toe,
curly toe 280

The nail of the great toe 281

Rheumatoid arthritis 281

Gout 281

Tarsal tunnel syndrome 281

Diagnosis of foot complaints 281

The mature foot: summary of
the key stages in examination
(13–18) 285

Inspection 286–289

Foot posture 289–292

Circulation 292–293

Tenderness 293–296

Plantar neuroma 294–295


Tarsal tunnel syndrome 295–296

Movements 297–299

Footprints and shoes 299–300

Radiographs 300–304

Pathology 304–306



ANATOMICAL FEATURES

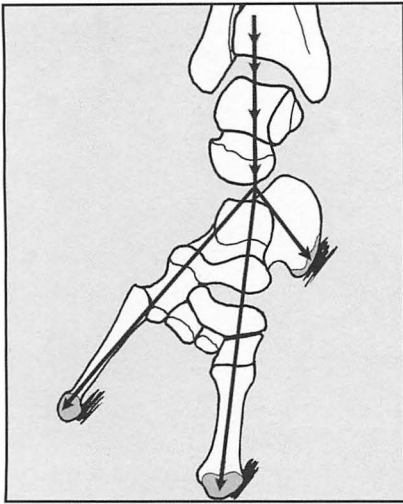


Fig. 13.A. Tripod action of the foot: To maintain perfect ground contact each foot acts as a tripod, with the legs of the tripod being represented by the calcaneus and the heads of the first and fifth metatarsals. To maintain balance, the centre of gravity (in front of S2) must fall within the area covered by one or both feet, and to facilitate this each foot must be capable of movement in two planes.

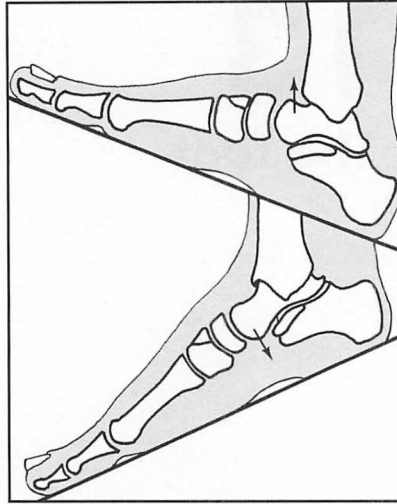


Fig. 13.B. Planes of movement (1): In the *x-axis* nearly all of the movement occurs in the *ankle*, and this allows balance to be maintained when going up and down slopes. (Some very slight movement in the same plane occurs in the midtarsal and tarsometatarsal joints, and minimally in the subtalar joint.)

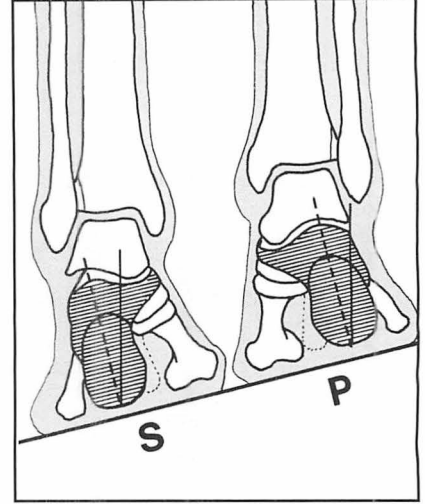


Fig. 13.C. Planes of movement (2): In the *z-axis* supination (S) occurs when the soles of the feet are turned inwards to face one another; pronation (P) involves movement in the opposite direction. This allows the feet to adapt to a surface sloping at right-angles to the direction of travel. The major part of this movement involves the subtalar joint (but the midtarsal and tarsometatarsal joints are also involved).

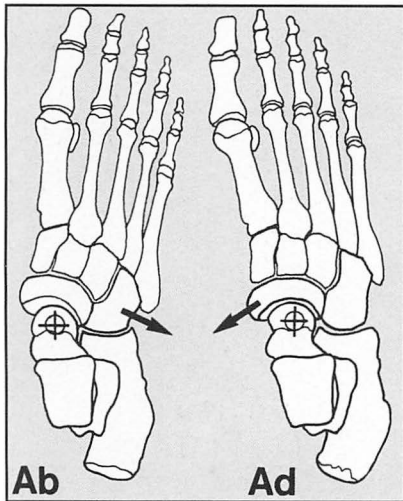


Fig. 13.D. Planes of movement (3): In the *y-axis*, at right-angles to the others, a very limited range of abduction and adduction of the forefoot may occur. Most of this occurs in the midtarsal joint, but some takes place in the tarsometatarsal joints and in the ankle. This is of relatively little importance, although a fixed metatarsus adductus is a well known, self-limiting deformity, generally of childhood.

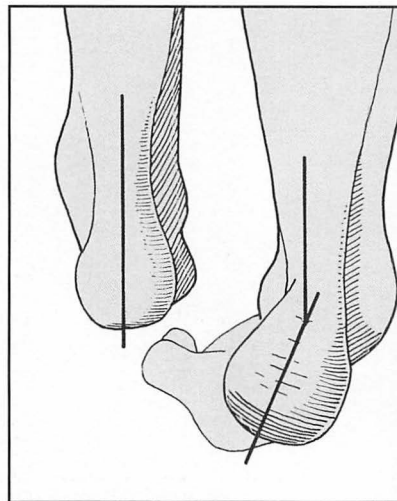


Fig. 13.E. Inversion: Inversion of the heel occurs when the calcaneus tilts into *varus*. This movement occurs in the subtalar joint. As the heel tilts, it carries the rest of the foot with it (the foot is directly connected to the calcaneus through the calcaneocuboid joint), and this results in supination of the foot. (*Valgus* tilting of the heel (eversion) results in *pronation* of the foot.)

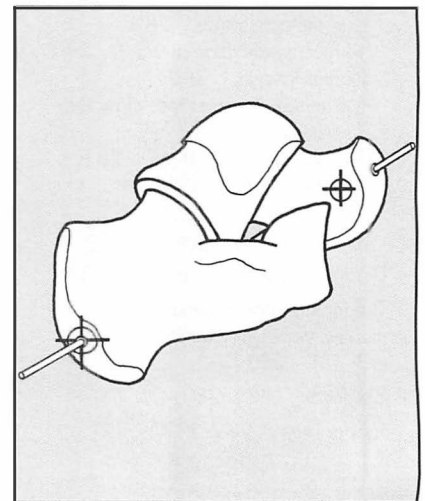


Fig. 13.F. Subtalar movements (1): Movements in the subtalar joint, which involves two pairs of articular surfaces, are highly complex, the only joints they resemble being those between the radius and ulna. There is, however, a relatively fixed axis of movement which passes through the centre of the head of the talus in front, and through the posterolateral tubercle of the calcaneus behind.

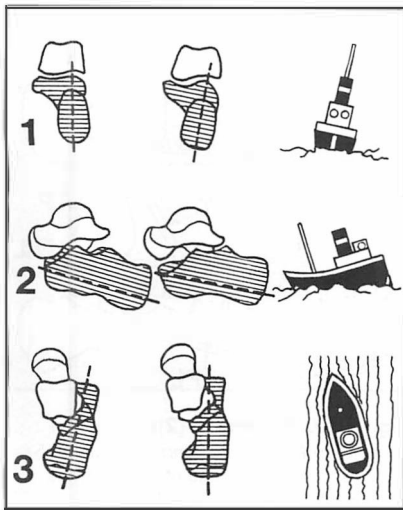


Fig. 13.G. Subtalar movements (2): The complex pattern of calcaneal movements that occurs in inversion are sometimes compared with the three-plane movements of ships or aircraft: the calcaneus rolls (1), pitches (2) and yaws (turns) (3) under the talus.

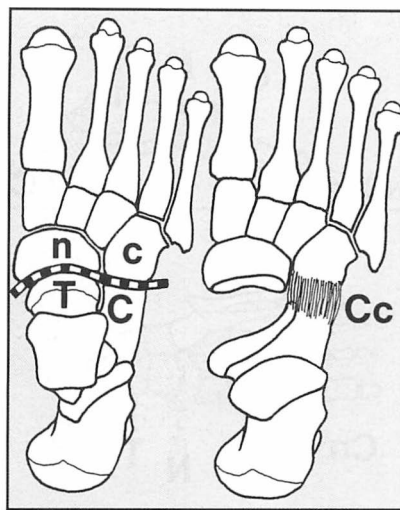


Fig. 13.H. The midtarsal joint (1): This links the hindfoot with the midfoot. It is formed by the head of the talus (T) and the navicular (n) on the medial side, and on the lateral by the calcaneus (C) and the cuboid (c). The latter joint (Cc), which permits only a limited range of movements, ensures that when the heel moves the rest of the foot follows.

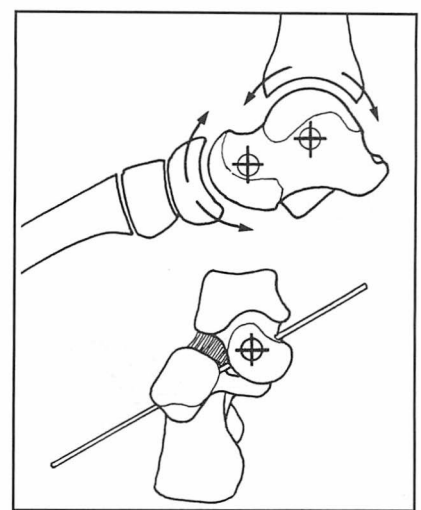


Fig. 13.I. The midtarsal joint (2): The joint has in effect two axes of movement. First, it acts as a hinge, allowing slight dorsiflexion and plantarflexion (like the ankle). The axis of this hinge passes through the centre of the head of the talus, so that this movement is coordinated with subtalar movement (which passes through the same point). The plane of this axis is tilted at 45° relative to the horizontal.

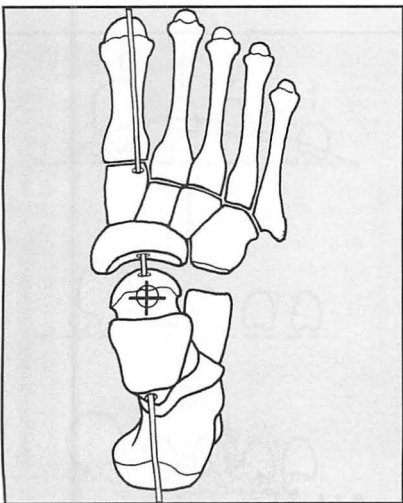


Fig. 13.J. The midtarsal joint (3): In addition to movements in (roughly) the x-axis, a limited amount of pronation and supination (z-axis) is possible; the navicular slides and rotates round the head of the talus, and the cuboid slides on the calcaneus. This axis of rotation also passes through the centre of the head of the talus.

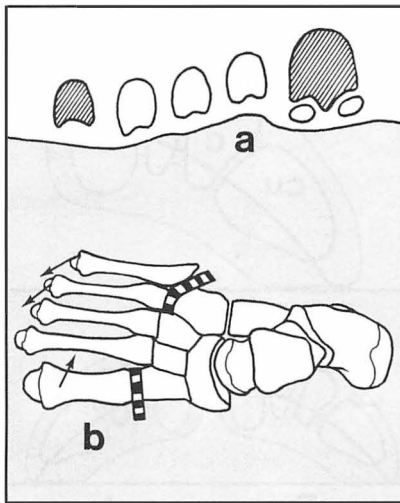


Fig. 13.K. Tarsometatarsal movements: (a) Whereas the heads of the first and fifth metatarsals form the anterior limbs of each foot tripod, the other metatarsal heads can adapt to any irregularity in the surface of the ground. Elevation and depression of the first metatarsal head and of the others (particularly the fourth and fifth (b)) can contribute an appreciable amount to overall supination of the foot (e.g. first tarsometatarsal movement amounts to 15°).

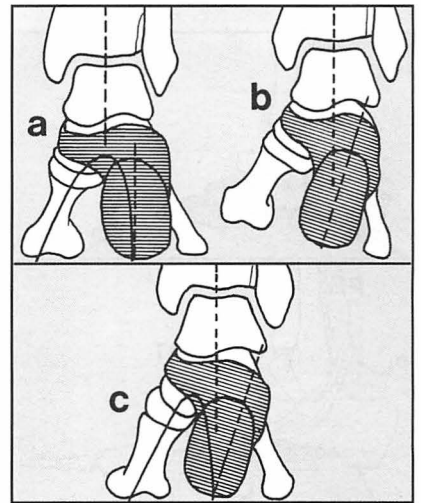


Fig. 13.L. Heel posture (1): Normally, in the weightbearing foot the axis of the heel is in alignment with the tibia (a). If the heel posture is abnormal and tilts into varus, then under normal circumstances the foot would supinate and the first metatarsal head would not contact the ground (b). To correct this, the foot distal to the subtalar joint must pronate, and this leads to accentuation of the medial longitudinal arch (c).

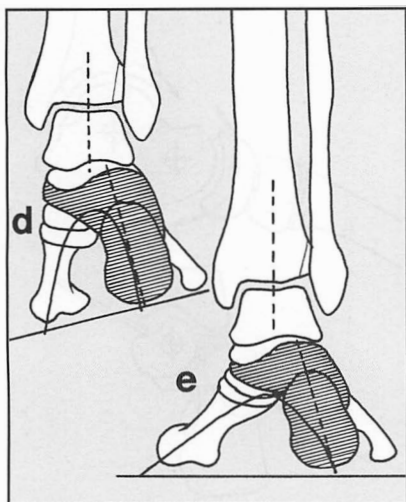


Fig. 13.M. Heel posture (2): If, on the other hand, the heel posture is one of valgus (d), then to allow all the metatarsal heads to contact level ground the foot distal to the subtalar joint must supinate, leading to flattening of the medial arch (e). The important practical points to note are that *valgus heels are associated with flat foot, and varus heel with pes cavus*

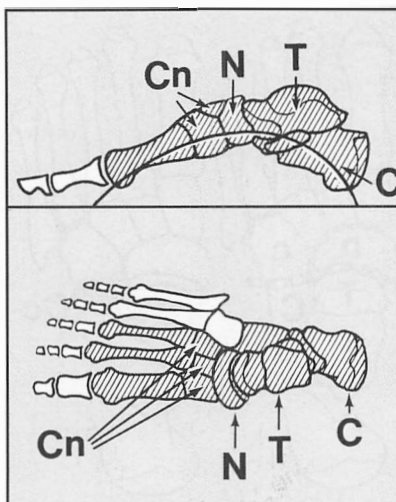


Fig. 13.N. The arches (1): These are well known features of the foot. The medial longitudinal arch is the most important, and the one *primarily* affected in pes planus and pes cavus. It is formed by the calcaneus (C), talus (T), navicular (N), cuneiforms (Cn) and medial three metatarsals. Flattening of the arch is common and is assessed clinically, although weightbearing lateral radiographs may be helpful.

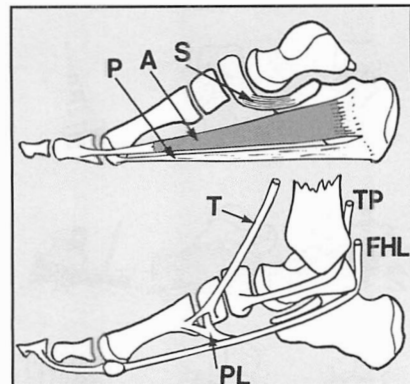


Fig. 13.O. The arches (2): The medial arch is supported by the spring ligament (S), which shoulders the head of the talus; the plantar fascia (P), which acts as a tie; abductor hallucis (A) and flexor digitorum brevis, which act as spring ties; tibialis anterior (T), which lifts the centre of the arch (and, with peroneus longus (PL), forms a stirrup-like support for it); tibialis posterior (TP) which adducts the midtarsal joint and reinforces the action of the spring ligament; and flexor hallucis longus (FHL), which acts as a long spring tie and helps support the head of the talus.

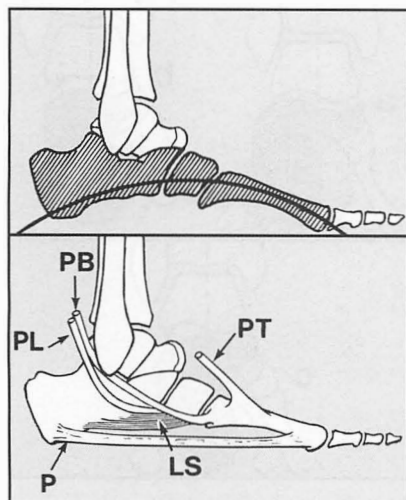


Fig. 13.P. The arches (4): The lateral longitudinal arch is formed by the calcaneus, cuboid and fourth and fifth metatarsals; it is very shallow, and generally flattens out on weightbearing. It is supported by the long and short plantar ligaments (LS), the plantar fascia (P), flexor digitorum brevis, flexor and abductor digiti minimi (not shown), peroneus tertius (PT), peroneus brevis (PB) and peroneus longus (PL).

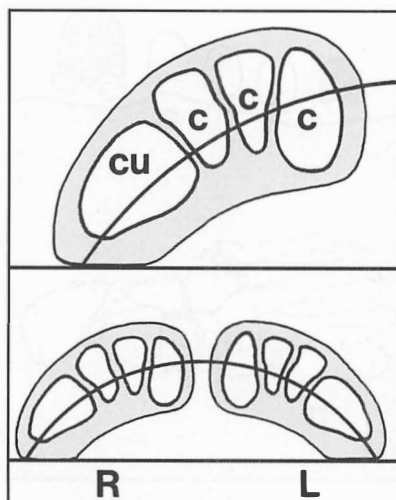


Fig. 13.Q. The arches (5): The transverse arch is formed by the cuneiforms (c) and cuboid (cu). It stretches across the sole in the coronal plane. It is in fact a half arch: the whole arch is completed by the other foot. It is of no particular clinical significance, as its presence and size are precisely related to those of the medial longitudinal arch. The shape of the cuneiforms (likened to the voussoirs of stone arches) helps maintain the arch.

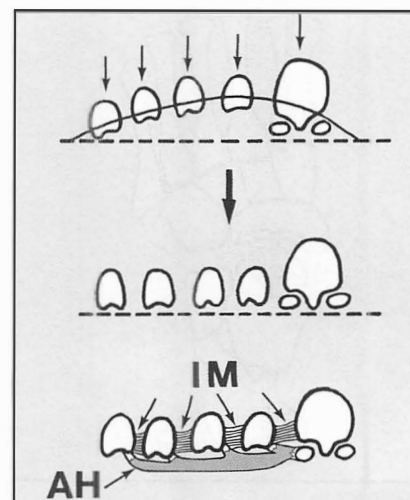


Fig. 13.R. The arches (6): The anterior arch lies in the coronal plane: its bony components comprise the metatarsal heads. It is not a feature of the weightbearing foot, as under load the metatarsal heads flatten out. The metatarsal heads are prevented from spreading out (splaying) by the intermetatarsal ligaments (IM) and the intrinsic muscles, especially the transverse head of adductor hallucis (AH).

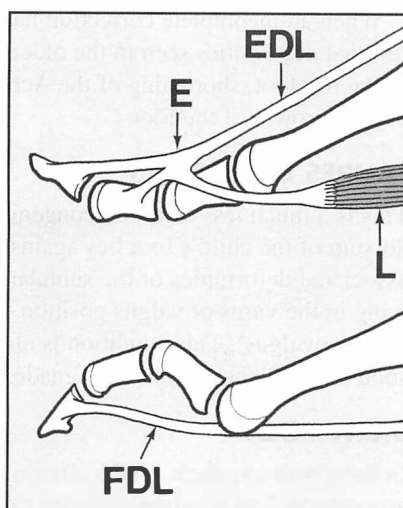


Fig. 13.S. The toes (1): Extensor digitorum longus (EDL) extends the MP and both IP joints of each toe. The interosseous and lumbrical muscles (L), through their attachment to the extensor expansions (E), extend the toes at the proximal and distal interphalangeal joints, and flex the MP joints; if they become weak or fail, the unchecked pull of flexor digitorum longus (FDL) results in clawing of the toes.

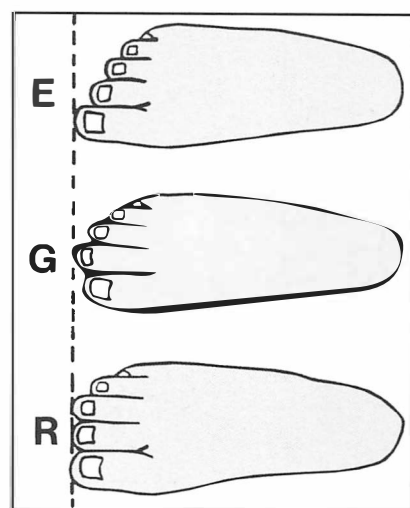


Fig. 13.T. The toes (2): The relative length of the toes is subject to variations, many of which are regarded as normal. The commonest arrangement is the *Egyptian foot* (E), when the great toe is longest and the succeeding toes progressively shorter. In the so-called *Greek foot* (G), the second is the longest. In the *rectangular or intermediate foot* (R), the great and second toes (and often the third) are equal in length.

CONDITIONS COMMENCING OR SEEN FIRST IN CHILDHOOD

TALIPES EQUINOVARUS

This is the commonest of the major congenital abnormalities affecting the foot, and all newly born children should be examined to exclude this condition. It is commoner in boys than girls, and the aetiology is uncertain. The deformity is a complex one: characteristically there is a varus deformity of the heel and adduction of the forefoot, accompanied by some degree of plantarflexion and supination. MRI scans are regarded of being of value in determining talonavicular alignment and as a guide to treatment. Initially this is in the form of corrective stretching of the foot and splintage, and must be started immediately if a good result is to be achieved. In some cases, especially when there is a delay in starting treatment or where there is a failure to respond, simple measures may not be enough. More radical treatments include (a) serial corrective plasters; (b) surgery to release contracted soft tissues (e.g. lengthening of the Achilles tendon and division of the plantar fascia at the heel); procedures that stretch soft tissues and influence bone growth, especially those using the Ilizarov method (this involves the insertion of wires through bony elements in the leg and foot, connecting them with a frame, and repeatedly adjusting their spacing and orientation).

In untreated cases the primary anomaly affecting the soft tissues is followed by alteration in tarsal bone growth. In such cases, wedge excision of bone and fusion of the midtarsal and subtalar joints may be required to obtain a plantigrade foot (Dunn's arthrodesis, triple fusion).

When an incomplete correction has been obtained, the commonest residual deformities seen in the older child and adult are persistent adduction of the forefoot, shortening of the Achilles tendon, and some stunting in overall growth of the foot.

TALIPES CALCANEUS

This is a much less common congenital abnormality of the foot, in which the dorsum of the child's foot lies against the shin. There are frequently associated deformities of the subtalar and midtarsal joints, with the heel lying in the varus or valgus position (talipes calcaneovarus, talipes calcaneovalgus). This condition is also treated by stretching and splintage as soon as the diagnosis has been made.

SKEW FOOT

In this condition there is adduction of the metatarsals (metatarsus adductus) accompanied by a valgus deformity of the hindfoot. It may be seen as a residual deformity in cases of club foot where treatment has not been followed by complete resolution, or it may occur on its own. Many cases resolve spontaneously, but in some it persists, leading to callosities and foot pain. Treatment is usually by conservative measures, but surgery may be required in resistant cases.

INTOEING

After walking has commenced, parents may seek advice because the child is walking with the feet turned inwards (intoeing, hen-toed gait). The feet may be internally rotated to such an extent that the child is constantly tripping and falling. Sometimes this may be due to torsional deformity of the tibiae (which must always be excluded), but more often it is the result of a postural deformity of the hips (internal rotation) or excessive anteversion of the femoral neck. The condition generally corrects spontaneously by the age of 6. Continued observation is advised until correction occurs, but active treatment is seldom required.

FLAT FOOT

The arches of the foot do not start to form until a child starts walking, and they are not fully formed until about the age of 10; *the young child's foot is normally flat*. Nothing is known to speed up the process of arch formation: orthopaedic shoes, heel cups and plastic moulded insoles have all been shown to be valueless. Failure of establishment of the arches is quite rare, but if this occurs it can lead to awkwardness of gait, rapid, uneven wear and distortion of the shoes, but seldom pain or other symptoms if joint mobility is preserved. Persistent flat foot may be associated with valgus deformities of the heel, knock knees, torsional deformities of the tibiae, and shortening of the Achilles tendon. Rarely it may result from an abnormal talus (*vertical* talus) or neuromuscular disorders of the limb (e.g. poliomyelitis, muscular dystrophies). In the older child, gross deformities with a clear organic basis may require surgery, the nature of which is dependent on the pathology (e.g. calcaneal osteotomy for severe valgus heels).

PES CAVUS

Abnormally high longitudinal arches are produced by muscle imbalance, which disturbs the forces controlling the formation and maintenance of the

arches. In many cases there is a varus deformity of the heel and a first metatarsal drop (an increase in the angle between the first metatarsal and the tarsus). Two distinct groups are seen: those in which subtalar mobility is maintained, and those in which subtalar movements are decreased or absent. A neurological abnormality should always be sought, and sometimes this may be obvious (e.g. spastic diplegia or old poliomyelitis). Many cases are associated with spina bifida occulta, which may be confirmed by clinical and radiological examination. Rarely fibrosis of the muscles of the posterior compartment of the leg from ischaemia may be the cause. In the more severe cases there is weakness of the intrinsic muscles of the foot, with clawing of the toes; the abnormal distribution of weight in the foot leads to excessive callus formation under the metatarsal heads and the heel.

When the deformity is marked, surgery is indicated to relieve symptoms and lessen the chances of ultimate skin breakdown under the metatarsal heads. Where there is a varus deformity of the heel, correction of this defect alone may give good results; in some cases a wedge osteotomy of the distal tarsus or metatarsal bases is required to flatten the highly curved arch and improve the weight distribution in the foot. Where clawing of the toes is the most striking finding, proximal interphalangeal joint fusions of the toes or transplanting the flexor into the extensor tendons may be helpful.

KOHLER'S DISEASE

This is an osteochondritis of the navicular occurring in children between the ages of 3 and 10. Pain of a mild character is centred over the medial side of the foot. Symptoms settle spontaneously over a few months and are not influenced by treatment.

SEVER'S DISEASE

Chronic pain in the heel in children in the 6–12-year age group generally arises from the calcaneal epiphysis, which radiologically often shows increased density and fragmentation. The condition is usually referred to as Sever's disease which, although originally considered to be an osteochondritis, is now believed to be due to a traction injury of the Achilles tendon insertion. Symptoms settle spontaneously without treatment.

CONDITIONS AFFECTING THE ADOLESCENT FOOT

HALLUX VALGUS

In adolescence, and particularly in girls, where there is competition between the rapidly growing foot, tight stockings and often small, high-heeled, unsuitable shoes, valgus deformity of the great toe first appears. In some cases a hereditary short and varus first metatarsal may contribute to the problem. As the deformity progresses, the drifting proximal phalanx of the great toe uncovers the metatarsal head, which presses against the shoe and leads to the formation of a protective bursa (bunion), often associated with recurrent episodes of inflammation (bursitis). The great toe may pronate, and further lateral drift results in crowding of the other toes; the great toe may pass over the second toe or, more commonly, the second toe may ride over it. The second toe may press against the toe cap of the shoe, where there is little room for it, and develop painful calluses. Later it may dislocate at the metatarsophalangeal joint. The sesamoid bones under the first metatarsal head may sublux laterally, leading to sharply localized pain under the first

metatarsophalangeal joint. In the late stages of the condition, arthritic changes may develop in the metatarsophalangeal joint. More commonly, there is associated disturbance of the mechanics of the forefoot, leading to anterior metatarsalgia.

A number of surgical procedures are available to correct hallux valgus deformity. The most popular are (a) fusion of the metatarsophalangeal joint in a corrected position; (b) Keller's arthroplasty (excision of the prominent part of the metatarsal head and removal of the basal portion of the proximal phalanx); (c) osteotomy of the first metatarsal neck (Mitchell operation); and (d) in early cases, simple excision of the prominent part of the metatarsal head may give relief. Silicone replacement of the metatarsophalangeal joint is no longer advocated, as it has been found that a troublesome silicone granuloma almost invariably develops in the region within 4 years of surgery.

PERONEAL (SPASTIC) FLAT FOOT

In adolescents (boys in particular), painful flat foot may be found in association with apparent spasm of the peroneal muscles. The foot is held in a fixed, everted position. Inversion of the foot is not permitted, and there is often marked disturbance of gait. The condition is frequently associated with ossification in a congenital cartilaginous bar bridging the calcaneus and navicular (tarsal coalition). This anomaly may be demonstrated radiologically. Surgery in the form of excision of the bar is now the normal treatment for this condition.

EXOSTOSES

Apart from the exposure and prominence of the medial side of the first metatarsal head commonly seen in association with hallux valgus (and referred to as a first metatarsal head exostosis), several exostoses may give rise to trouble in adolescence:

1. *Calcaneal exostosis* Prominence of the calcaneus above and to the sides of the Achilles tendon insertion may cause problems with friction against the counter of the shoe (blisters, calluses, difficulty in shoe fitting). Where the exostosis is restricted to the lateral side it is known as a Haglund deformity.
2. *Cuneiform exostosis* An exostosis formed on the dorsum of the foot by arthritic lipping at the margins of the joint between the first metatarsal and medial cuneiform may cause similar difficulties.
3. *Fifth metatarsal head* Prominence of the fifth metatarsal head (bunionette or tailor's bunion) may occur and is often associated with a varus deformity of the fifth toe (quinti varus).

All the above conditions are treated by local excision of the prominence.

4. *Fifth metatarsal base* The base of the fifth metatarsal is sometimes enlarged and unduly prominent, especially in the narrow foot; it *may* sometimes cause pressure against the shoe, but surgical treatment is seldom required.

CONDITIONS AFFECTING THE ADULT FOOT

HALLUX RIGIDUS

Primary osteoarthritis of the metatarsophalangeal (MP) joint of the great toe often commences in adolescence and gives rise ultimately to pain and

stiffness in this joint. It is commoner in males, and is not associated with hallux valgus. Sometimes the toe is held in a flexed position (hallux flexus), and the proximal phalanx and metatarsal head are thickened following joint narrowing and circumferential exostosis formation. Treatment is usually by fusion or Keller's arthroplasty.

ADULT FLAT FOOT

Gradual flattening of the medial longitudinal arch (incipient flat foot) may occur in those who spend much of the day on their feet. This is often associated with an increase in body weight and the degenerative changes of ageing in the supporting structures of the arch. When these changes are rapid, they give rise to pain ('medial foot strain'). Secondary (tarsal) arthritic changes may also give rise to pain in long-standing flat foot, and are associated with loss of movement in the foot (rigid flat foot). Nevertheless, in two-thirds of cases of flat foot mobility is preserved in the ankle, subtalar and other foot joints (flexible or mobile flat foot), and there is no cause for clinical concern or significant potential for disability. (Ballet dancers and many professional footballers have grotesquely flat feet which do not interfere with their activities.)

In the early stages incipient flat foot may be helped by weight reduction, physiotherapy and arch supports. In the later stages, surgical shoes with moulded insoles may be the most helpful measure.

SPLAY FOOT

Widening of the foot at the level of the metatarsal heads is known as splay foot. This may occur as a variation in the normal pattern of foot growth, causing no difficulty apart from that of obtaining suitable footwear. Splay foot may also be seen in association with metatarsus primus varus, hallux valgus and pes cavus.

ANTERIOR METATARSALGIA

In anterior metatarsalgia there is complaint of pain under the metatarsal heads. The condition is particularly common in middle-aged women and is also often associated with some splaying of the forefoot. Symptoms may be triggered by periods of excessive standing or an increase in weight, and there is often a concurrent flattening of the medial longitudinal arch. Weakness of the intrinsic muscles is usually present, so that there is a tendency to clawing of the toes; hyperextension of the toes at the MP joints leads to exposure of the plantar surfaces of the metatarsal heads, which give high spots of pressure against the underlying skin. In turn this produces pain and callus formation in the sole. This pathological process is by far the commonest cause of forefoot pain, but in every case March fracture, Freiberg's disease, plantar digital neuroma and verruca pedis should be excluded.

The majority of cases of anterior metatarsalgia respond to skilled chiropodial measures, which may include trimming of calluses and the provision of supports: these distribute the weightbearing loads more evenly under the metatarsal heads. Where there is much splaying of the forefoot and associated toe deformities, surgical shoes may be required. Where there is a marked hallux valgus deformity an MP joint fusion may improve the mechanics of the forefoot, with relief of pain.

MARCH FRACTURE

This occurs in young adults and involves the second or, less commonly, the third or fourth metatarsals. The fracture usually follows a period of unaccustomed activity (there is no history of injury) and pain settles after 5–6 weeks when the fracture unites.

FREIBERG'S DISEASE

This is an osteochondritis of the second metatarsal head associated with palpable deformity and pain. Pain may persist for 1–2 years, and in severe cases excision of the metatarsal head may become necessary. Excellent results have also been claimed for a dorsiflexion osteotomy of the metatarsal neck.

PLANTAR (DIGITAL) NEUROMA (MORTON'S METATARSALGIA)

A neuroma situated on one of the plantar digital nerves just prior to its bifurcation at one of the toe clefts may give rise to piercing pain in the foot. It most commonly affects the plantar nerve running between the third and fourth metatarsal heads to the third web space, but any of the digital nerves may be affected. It most commonly occurs in women, particularly in the 25–45-year age group, and is often treated by excision of the affected nerve. Division of the intermetatarsal ligaments in the affected space without excising the nerve is said to give comparable results.

VERRUCA PEDIS (PLANTAR WART)

Verrucae, thought to be viral in origin, are common in the metatarsal region, the great toe and the heel. They must be differentiated from calluses, and are most frequently treated by the careful application of caustic preparations such as salicylic acid, acetic acid and carbon dioxide snow.

PLANTAR FASCIITIS

Pain in the heel is a common complaint in the middle-aged and may be due to tearing of the calcaneal attachment of the plantar fascia following degenerative changes in its structure. Treatment is by the use of Sorbo rubber pads in the heel of the shoe, physiotherapy in the form of ultrasound, or by the local infiltration of hydrocortisone.

MALLET TOE, HAMMER TOE, CLAW TOE, CURLY TOE

In a *mallet* toe there is a fixed flexion deformity of the distal interphalangeal joint of the toe; in a *hammer* toe there is a fixed flexion deformity of the proximal interphalangeal joint of a toe: the distal IP and MP joints are extended; in a *claw* toe both interphalangeal joints are flexed and the MP joint extended; and in a *curly* toe all three joints are flexed. In all these conditions corns may develop where the deformed toe presses against the footwear. Treatment may be conservative, by local chiropodial measures, or surgical, by means of interphalangeal joint fusions or, occasionally, in the case of mallet toe, by amputation. Simultaneous correction of an accompanying hallux valgus deformity may be required if a straightened second hammer toe is prevented from lying correctly because of the position of the hallux. Multiple clawed toes seen in association with pes cavus may be treated by IP joint fusions and flexor/extensor tendon transfers.

THE NAIL OF THE GREAT TOE

Ingrowing of the great toenail gives rise to pain and a tendency to recurrent infection at the nailfold. If infection is not a problem, skilled chiropody treatment (e.g. by nail training using a prosthetic device) is usually successful.

Where infection is marked, avulsion of the nail to permit drainage and healing is often required. In chronic cases, ablation of the nailbed (e.g. by phenolization) may give a permanent cure.

Gross thickening and deformity of the nail (onychogryphosis) may also be treated by ablation of the nailbed or by regular chiropody.

Subungual exostosis, often a source of great pain, is treated by surgical removal of the exostosis.

Deformities of the nails may result from mycelial infections and are very resistant to treatment.

Irregularity of nail growth is a common feature of psoriasis and is usually associated with skin lesions elsewhere. There may be an accompanying psoriatic arthritis.

RHEUMATOID ARTHRITIS

The foot is commonly involved in rheumatoid arthritis and the deformities are often multiple and severe. They frequently include pes planus, splay foot, hallux valgus, clawing of the toes, and subluxation of the toes at the MP joints. Anterior metatarsalgia is often marked. Sometimes a single deformity, such as a hammer toe, may be the main source of the patient's symptoms and may be amenable to a simple local surgical procedure. Where there are many deformities, the prescription of surgical shoes with moulded insoles may be the best treatment. Where there is gross crippling deformity, Fowler's operation, which is an arthroplasty of all the metatarsophalangeal joints combined with a plastic reconstruction of the metatarsal weightbearing pad, is often helpful in older patients; the best results may be obtained when the procedure is combined with fusion of the first MP joint.

GOUT

Gout classically affects the MP joint of the great toe, but in severe cases the other MP joints and even the tarsal joints are involved in the arthritic process. The treatment is mainly medical, but surgical footwear may be required.

TARSAL TUNNEL SYNDROME

The posterior tibial nerve may become compressed as it passes beneath the flexor retinaculum into the sole of the foot, giving rise to paraesthesia and burning pain in the sole of the foot and in the toes. The condition is uncommon, but is relieved by division of the flexor retinaculum. The superficial peroneal nerve may also be compressed as it runs under the extensor retinaculum on the dorsum of the foot, giving paraesthesia in the area of its distribution.

DIAGNOSIS OF FOOT COMPLAINTS

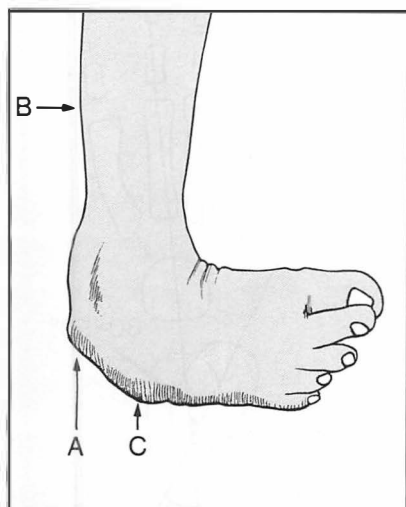
The following table lists the most common disorders and relates them to the age groups in which they have the highest incidence.

Table 13.1

	Heel pain	Pain on dorsal and medial side of foot	Great toe pain	Forefoot pain
Children	Sever's disease	Köhler's disease	Tight shoes and stockings, Ingrowing toe nail	Verruca pedis
Adolescents	Calcaneal exostosis; Bursitis	Cuneiform exostosis; Peroneal flat foot	Early hallux rigidus; Bunion Hallux valgus, nail problems	March fracture; Freiberg's disease Pes cavus; Verruca pedis
Adults	Plantar fasciitis	Flat foot Osteoarthritis Rheumatoid arthritis	Hallux valgus and bunion Hallux rigidus Gout, nail problems	Anterior metatarsalgia; Plantar neuroma Pes cavus Rheumatoid arthritis; Gout; Verruca pedis; Tarsal tunnel syndrome


Table 13.2

	Factors in flat foot	Factors in pes cavus
Infants	'Normal foot' Vertical talus	In all age groups, this is due to muscle imbalance often from a neurological disorder, e.g. spastic diplegia, poliomyelitis, Friedreich's ataxia, peroneal muscle atrophy, spina bifida (usually occulta). Many cases are associated with varus heels
Children	Knock knees Valgus heels Neurological disturbance Torsional deformities of the tibia	
Adolescents	Continuation of childhood factors Peroneal flat foot	
Adults	Continuation of childhood factors Overweight, excessive standing Degenerative processes	

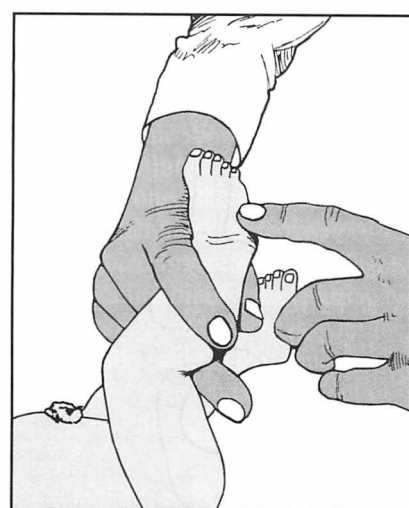


13.1. Clubfoot (1): *Talipes equinovarus*:

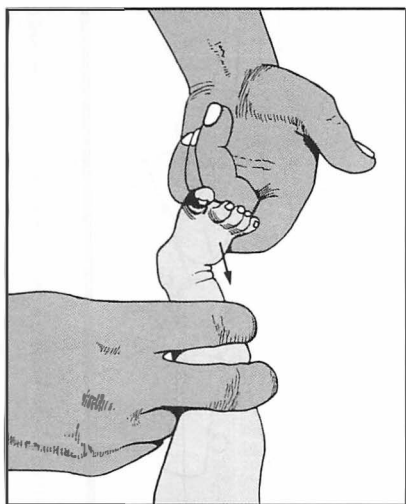
In the untreated case there is (A) persisting varus of the heel, (B) atrophy of the calf muscles, (C) callus where the child walks on the lateral border of the foot. It is commoner in males, may be bilateral, and may be associated with other anomalies.



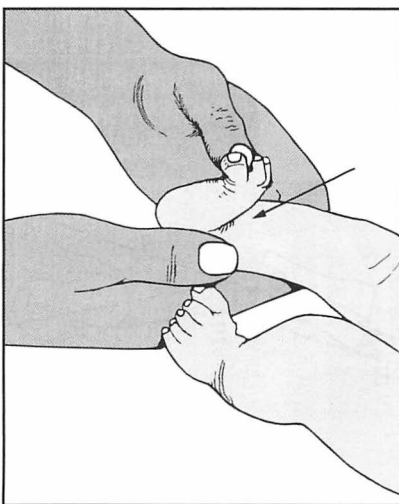
13.2. Club foot (2): The newborn child often holds the foot in plantarflexion and inversion, giving a false impression of deformity. First observe the child as it kicks to see if this position is maintained.



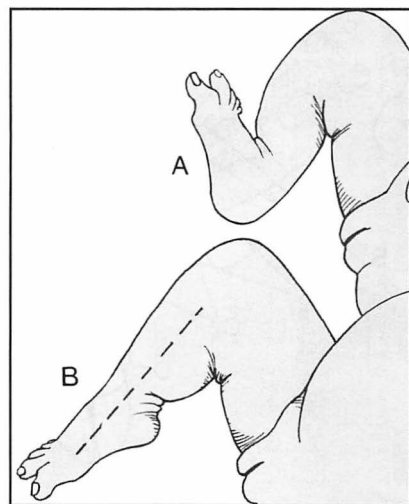
13.3. Club foot (3): If the child maintains the foot in the inverted position, support the leg and lightly scratch the side of the foot.



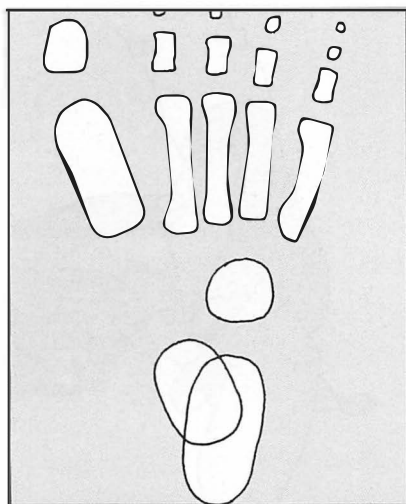
13.4. Club foot (4): In the normal foot the child will respond by dorsiflexion of the foot, eversion, and fanning of the toes. This reaction does not take place if the child has a talipes deformity.



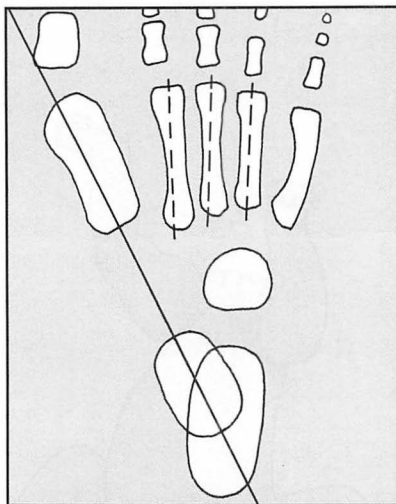
13.5. Club foot (5): If the child does not respond in a normal fashion, gently dorsiflex the foot. In the normal child, the foot can be brought either into contact with the tibia or very close to it.



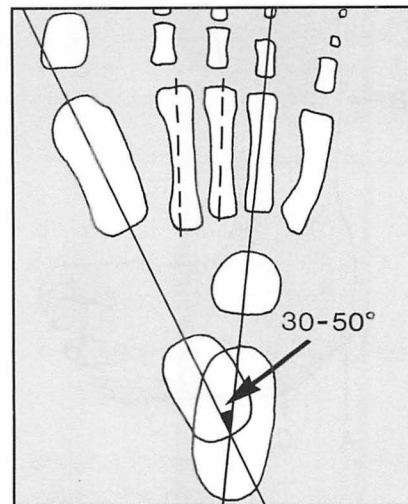
13.6. Club foot (6): (A) Note that in the less common talipes calcaneus deformity, the foot is held in a position of dorsiflexion. (B) Note that in the normal infant the foot can be plantarflexed to such a degree that the foot and tibia are in line.



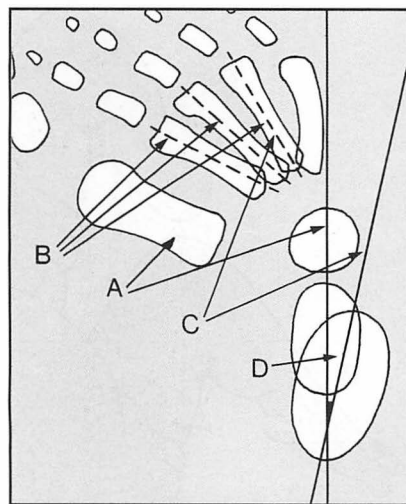
13.7. Radiographs: Anteroposterior view (1): Interpretation is difficult owing to the incompleteness of ossification. Centres for the talus, calcaneus, metatarsals, phalanges, and often the cuboid are present at birth. Begin by drawing a line through the long axis of the talus.



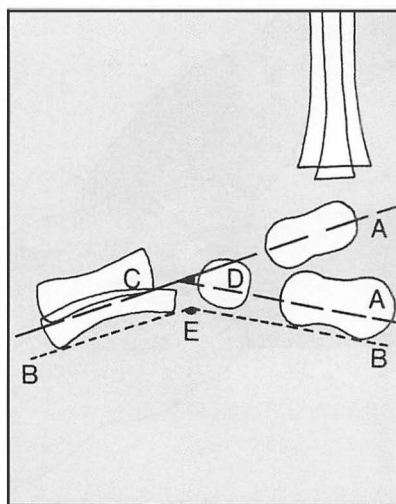
13.8. Radiographs: Anteroposterior view (2): This line normally passes through the first metatarsal, or lies along its medial edge. Note also that the axes of the middle three metatarsals are roughly parallel. Now draw a second line through the long axis of the calcaneus.



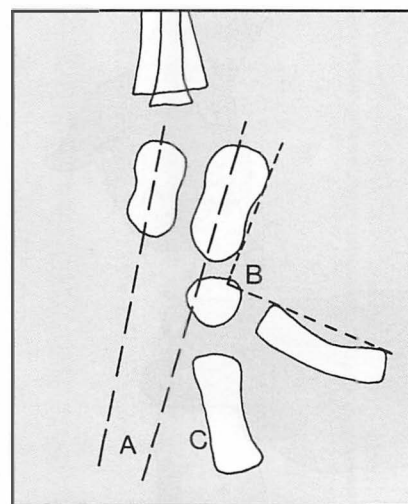
13.9. Radiographs: anteroposterior view (3): Note (A) the axial line of the calcaneus passes through or close to the fourth metatarsal. (B) The axes of the talus and calcaneus subtend an angle of 30-50°.



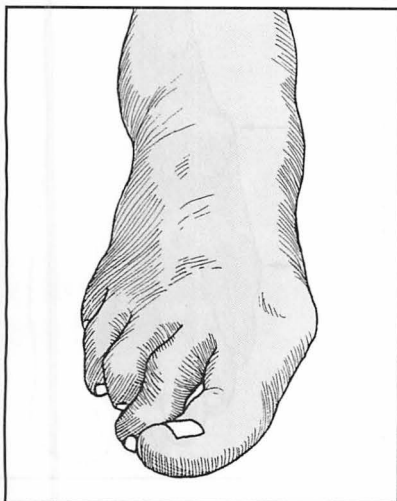13.10. Radiographs: Anteroposterior view (4): In club foot, the previously described relations are altered owing to forefoot adduction. Note (A) the talar axis does not cut the first metatarsal; (B) the middle three metatarsal axes are not parallel; (C) the calcaneal axis does not strike the fourth metatarsal; (D) the angle between the talus and calcaneus is reduced.



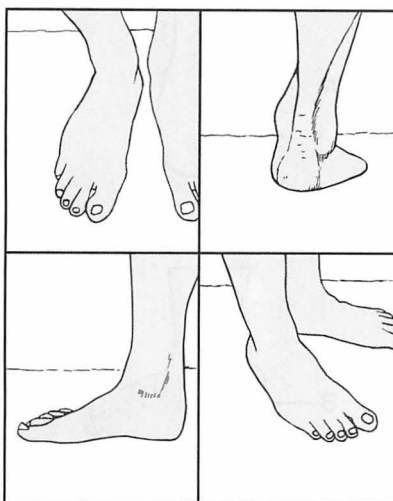
13.11. Radiographs: Lateral (1): Draw (A) axes through talus and calcaneus, and (B) tangents to the calcaneus and fifth metatarsal. Note that in the normal foot at birth that the talar axis passes below the first metatarsal (C); the interaxial angle (D) is 25-50°; the angle between the tangents (E) is 150-175°.



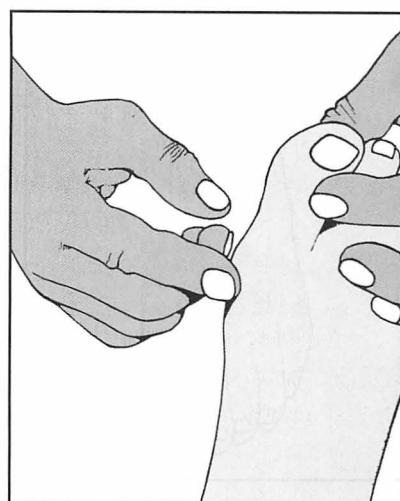
13.12. Radiographs: Lateral (2): In club foot, note (A) the talar and calcaneal axes are nearly parallel; (B) the angle of the tangents is less obtuse; (C) the talar axis does not pass below the first metatarsal. Geometric analysis of the type discussed on this page may be of help in the doubtful case and in assessing progress, and MRI scans are of particular value in determining talonavicular alignment.



13.13. Appearance: Note the shape of the foot, and the presence of any obvious deformities, abnormal callus formation etc.

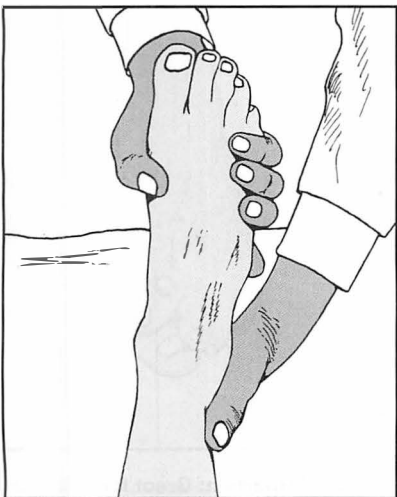

13.14. Weightbearing posture: Examine the weightbearing foot from above, from behind and from the sides.

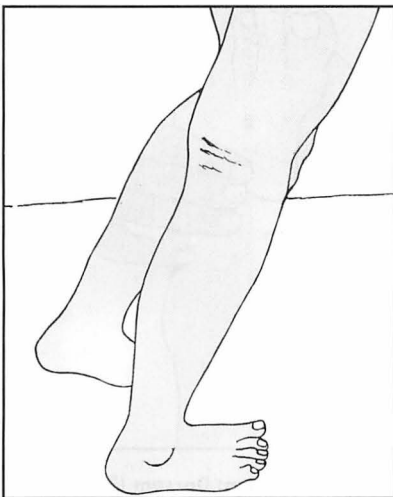


13.15. Palpation: Look for tenderness. Note any joint crepitus. Note any increase or decrease in skin temperature.

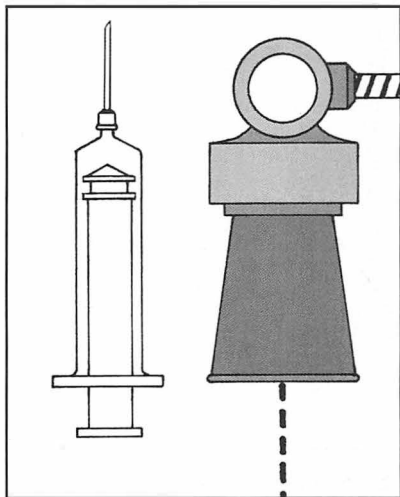
THE MATURE FOOT: SUMMARY OF THE KEY STAGES IN EXAMINATION (13-18)



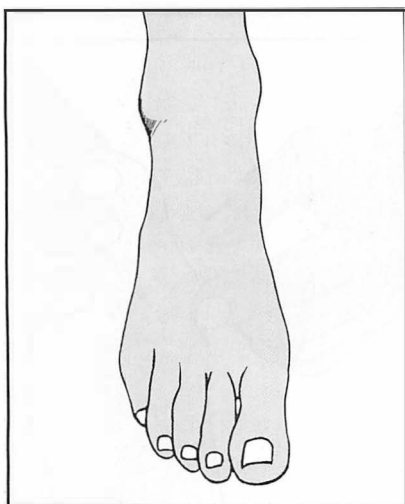
13.16. Movements: Examine the mobility of the toes, foot and ankle.



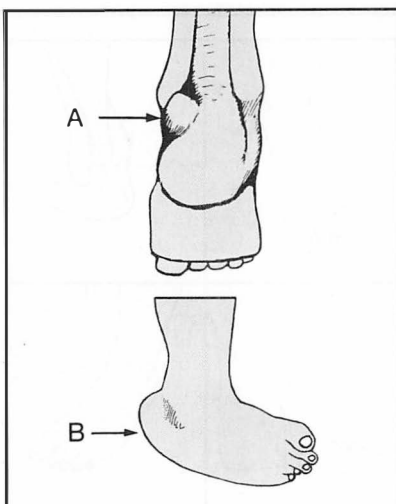
13.17. Gait: Examine the gait, with and without shoes. If indicated, screen the ankles, knees, hips and spine; examine the circulation, and carry out a neurological examination. Note the footprint and examine the shoes.



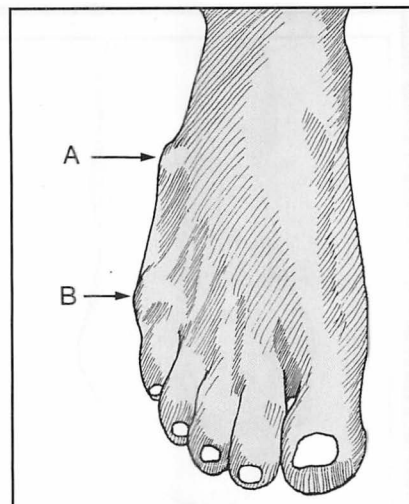
13.18. Investigations: Study the results of special investigations, e.g. radiographs, serum uric acid, sedimentation rate, rheumatoid factor etc.



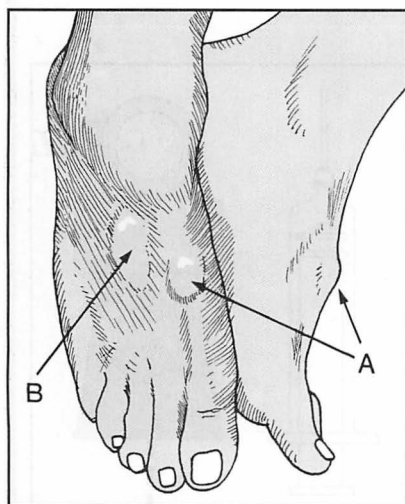
13.19. Inspection: General: Note whether the foot is normally proportioned. If not, look at the hands and assess the rest of the skeleton. In Marfan's syndrome, for example, the feet are long and thin (arachnodactyly, spider bones).



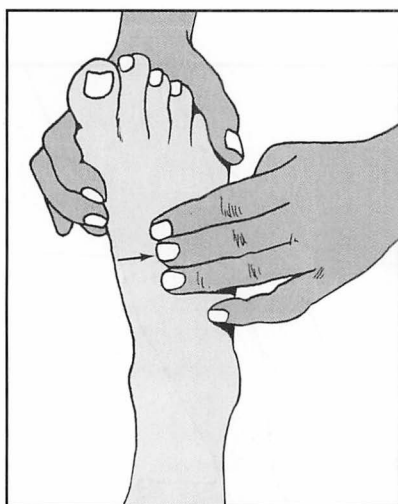
13.20. Inspection: Heel: Is there (A) a calcaneal prominence ('calcaneal exostosis') with overlying callus or bursitis? (Note that where the exostosis is primarily lateral it is known as a Haglund deformity.) Is there deformity of the heel, suggesting old fracture or (B) talipes deformity?



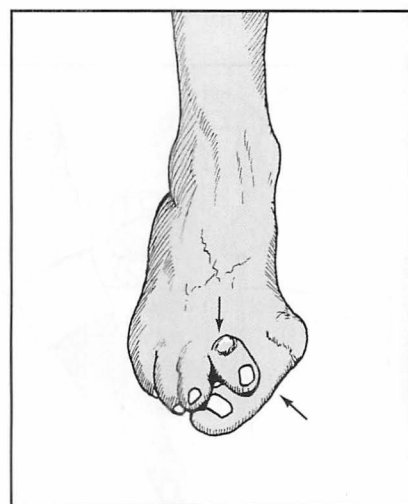13.21. Inspection: Dorsum (1): Is there (A) prominence of the fifth metatarsal base? (B) an 'exostosis' from prominence of the fifth metatarsal head? (The latter is sometimes known as a bunionette or tailor's exostosis.) Both can be a source of local pressure symptoms.



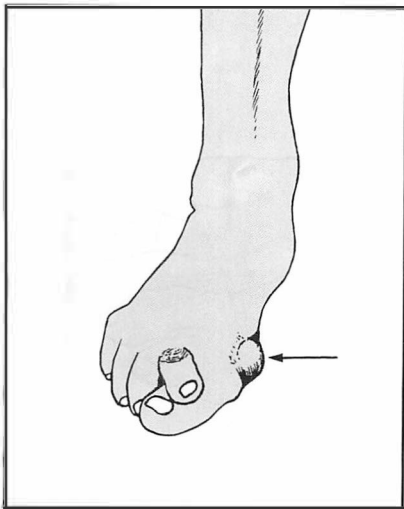
13.22. Inspection: Dorsum (2): Is there (A) a cuneiform exostosis? (B) a dorsal ganglion?



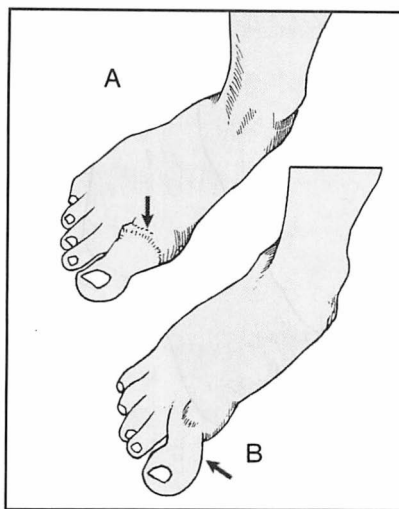
13.23. Inspection: Dorsum (3): Note the general state of the skin and nails. If there is any evidence of ischaemia, a full cardiovascular examination is required. In all cases, the presence of the dorsalis pedis pulse should be sought routinely.



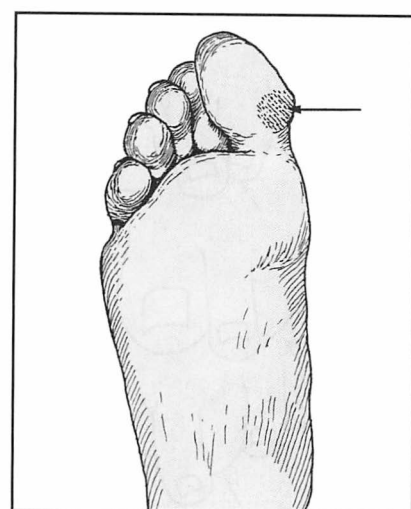
13.24. Inspection: Great toe (1): Note any hallux valgus deformity. If the deformity is severe, the great toe may under- or override the second, and it may pronate. The second toe may sublux at the MP joint. Always reassess any valgus deformity of the great toe with the foot weightbearing.



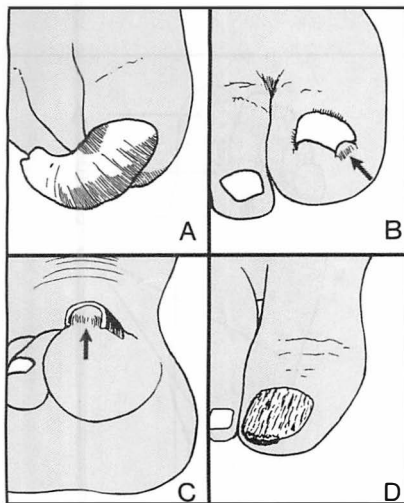
13.25. Inspection: Great toe (2): Note the presence of any bursa over the MP joint (bunion) and whether active inflammatory changes are present (from friction or infection). Discoloration of the joint with acute tenderness is suggestive of gout.



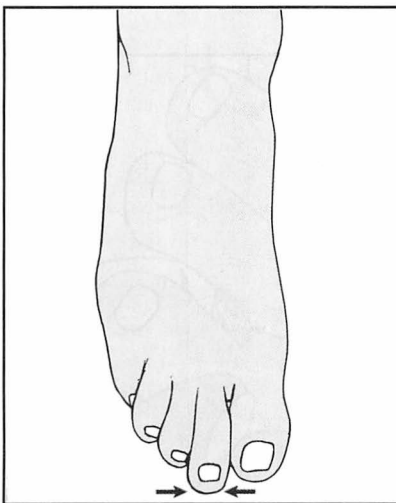
13.26. Inspection: Great toe (3): Note whether (A) the great toe is thickened at the MP joint, suggesting hallux rigidus (osteoarthritis of the first metatarsophalangeal joint), or (B) held in a flexed position (hallux flexus), again generally due to osteoarthritis.



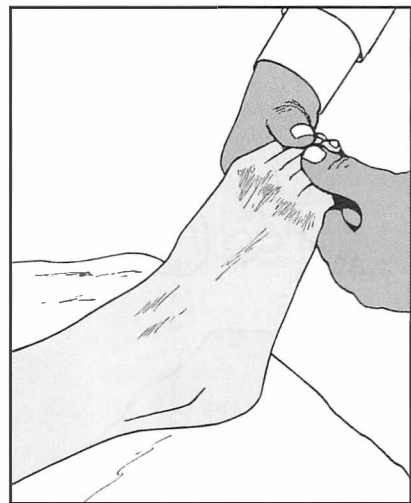13.27. Inspection: Great toe (4): Note the presence of excess callus under the great toe. This finding is highly suggestive of hallux rigidus.



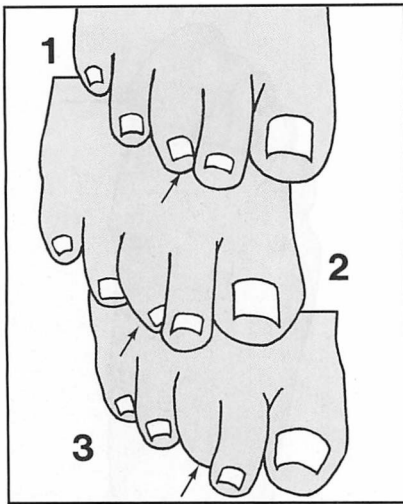
13.28. Inspection: Great toenail: Note whether the great toenail is (A) deformed (onychogryphosis), (B) ingrowing, possibly with accompanying inflammation, (C) elevated (suggesting subungual exostosis), (D) uneven in texture and growth (suggesting fungal infection or psoriasis).



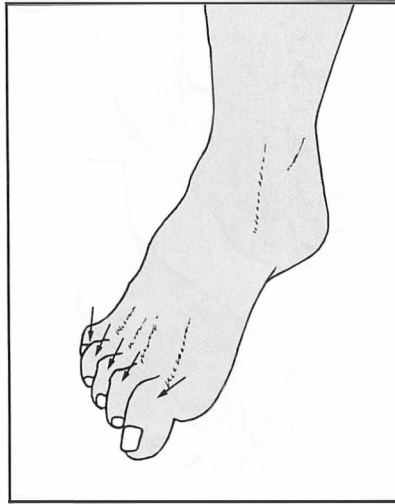
13.29. Inspection: Toes (1): Note the relative lengths of the toes. A second toe longer than the first may occasionally become clawed or throw additional stresses on its MP joint; it may be associated with Freiberg's disease.



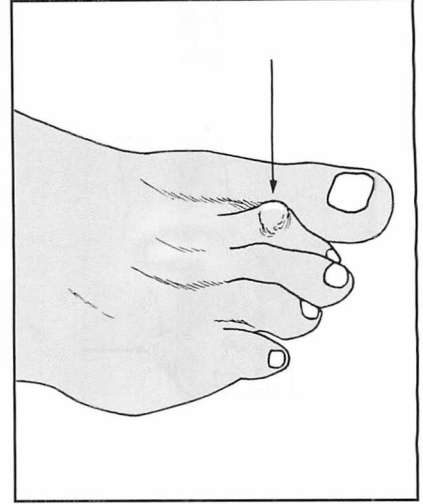
13.30. Inspection: Toes (2): Flex the toes and note the relative lengths of the metatarsals. Abnormally short first or fifth metatarsals are a potential cause of forefoot imbalance and pain. When both are short, there is often painful callus under the second metatarsal.



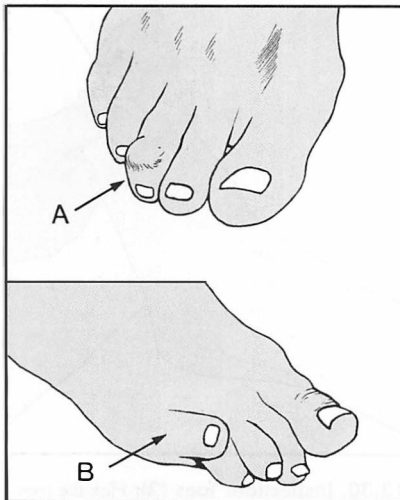
13.31. Inspection: Toes (3): Curly toe: In this deformity a degree of fixed flexion develops in both IP joints and the MP joint. It is generally caused by interosseous muscle weakness. In *grade 1* the toe is mildly flexed, with or without some adduction; in *grade 2* there is a degree of under- or over-riding; and in *grade 3* the nail is not visible from the dorsum.



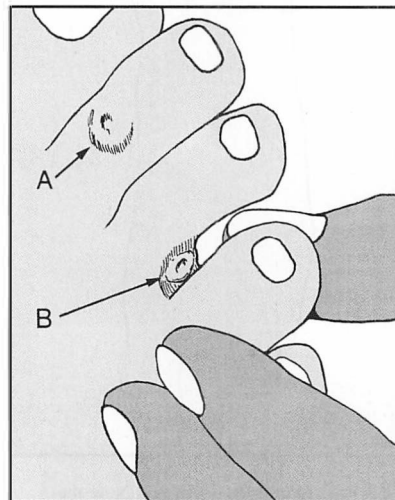
13.32. Inspection: Toes (4): Claw toes: The toes are said to be clawed when they are extended at the metatarsophalangeal joints and flexed at the interphalangeal joints. If all the toes are involved, this suggests that there may be an associated pes cavus or some other cause of intrinsic muscle insufficiency (the lumbricals and interossei flex the MP joints and extend the IP joints).



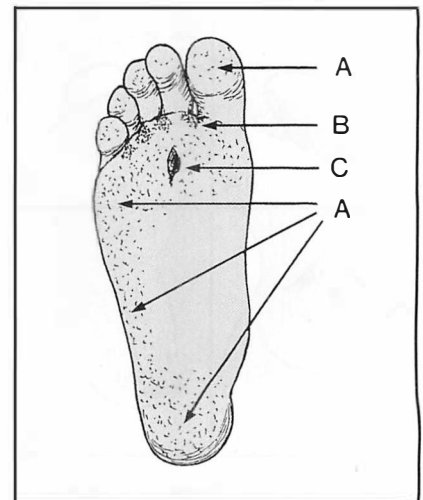
13.33. Inspection: Toes (5): Is there a *hammer toe* deformity, where the toe is flexed at the proximal interphalangeal joint and extended at the MP and distal IP joint? The second toe is most commonly affected, often owing to an associated hallux valgus deformity. There is usually callus over the prominent interphalangeal joint as a result of pressure against the shoe.



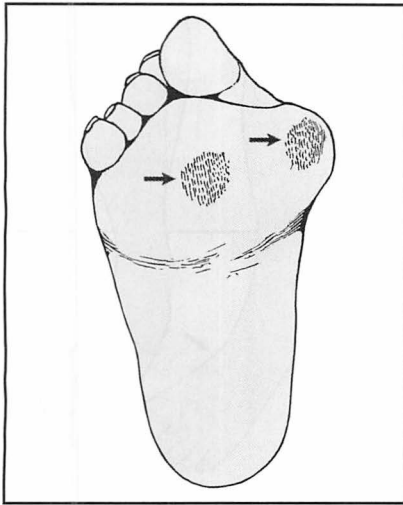
13.34. Inspection: Toes (6): Note the presence of (A) a *mallet toe* deformity (flexion deformity of the distal interphalangeal joint). There is usually callus under the tip of the toe or deformity of the nail. Note (B) an overlapping fifth toe or *quinti varus* deformity (often congenital).



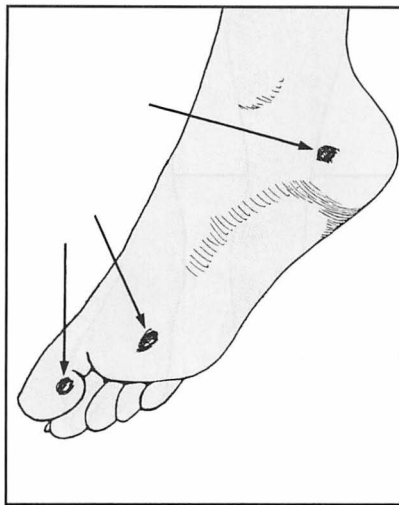
13.35. Inspection: Toes (7): Note the presence of (A) *hard corns*. These are areas of hyperkeratosis that occur over bony prominences, and are generally caused by pressure against the shoes. (B) *Soft corns* are macerated hyperkeratotic lesions occurring between the toes and are not associated with pressure or friction.



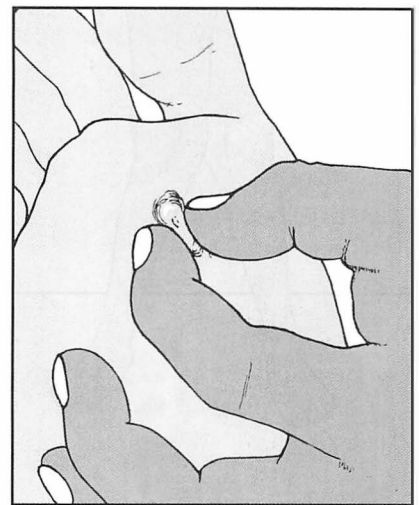
13.36. Inspection: Sole (1): Note (A) Hyperhidrosis. (B) Evidence of fungal infection or athlete's foot. (C) Ulceration of sole, suggesting pes cavus or neurological disturbance (trophic ulceration).



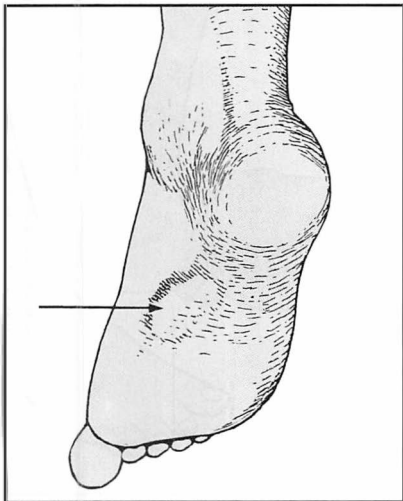
13.37. Inspection: Sole (2): Note the presence of callus, indicating an uneven or restricted area of weightbearing. Be careful to distinguish between abnormal, local thickening, and diffuse, moderate thickening at the heel and under the metatarsal heads (which is normal).



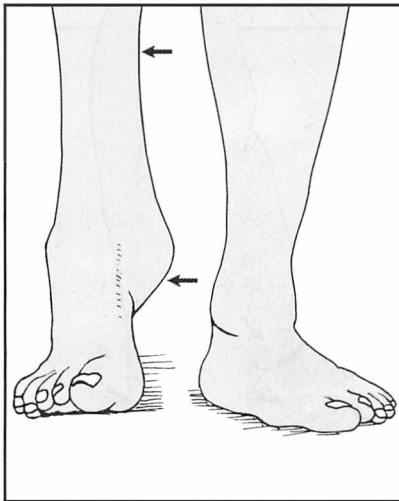
13.38. Inspection: Sole (3): Note the presence of a verruca (plantar wart). Note the three classic sites: at the heel, under the great toe, and in the forefoot in the region of the metatarsal heads. In the sole they are situated between the metatarsal heads: unlike calluses, they *do not occur in pressure areas*.



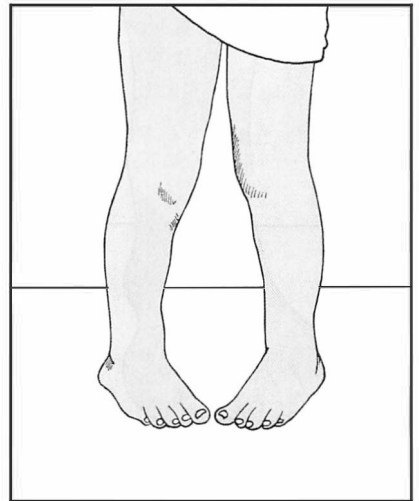
13.39. Inspection: Sole (4): Verruca, ctd. A verruca is exquisitely sensitive to *side to side* pressure. Calluses are much less sensitive, and only to *direct* pressure. If there is any remaining doubt a magnifying lens may be used to confirm the central papillomatous structure of the verruca.



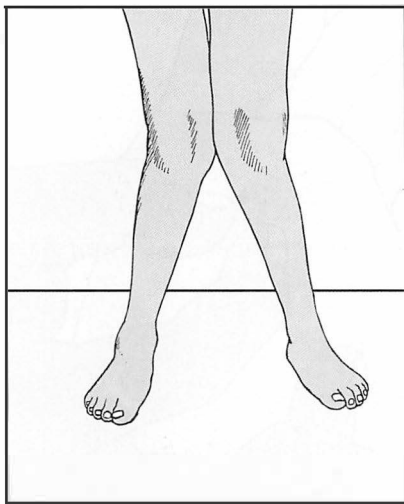
13.40. Inspection: Sole (5): Note any localized fibrous tissue masses in the sole typical of Dupuytren's contracture of the feet. These tissue thickenings arise from the plantar fascia, and are attached to the skin. Always inspect the hands, as both upper and lower limbs are often involved together in this process.



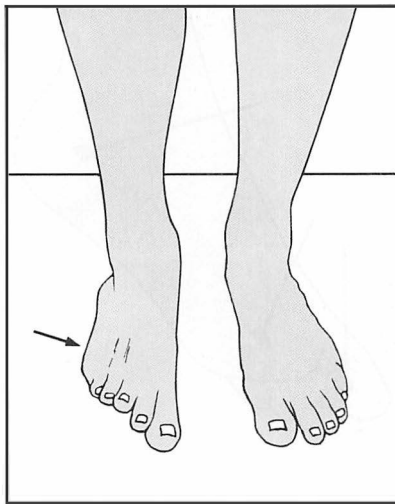
13.41. Posture (1): Examine the patient standing. Are both the heel and forefoot squarely on the floor (plantigrade foot)? If the heel does not touch the ground, examine for shortening of the leg or shortening of the tendocalcaneus.



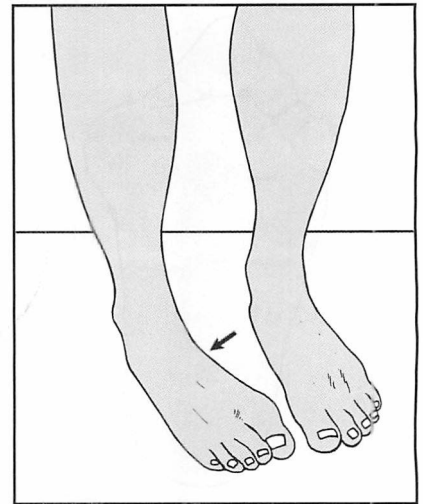
13.42. Posture (2): Intoing: If this deformity is present, examine for (A) torsional deformity of the tibia, (B) increased internal rotation of the hips, or (C) adduction of the forefoot. Most cases of intoeing in children resolve spontaneously by age 6.



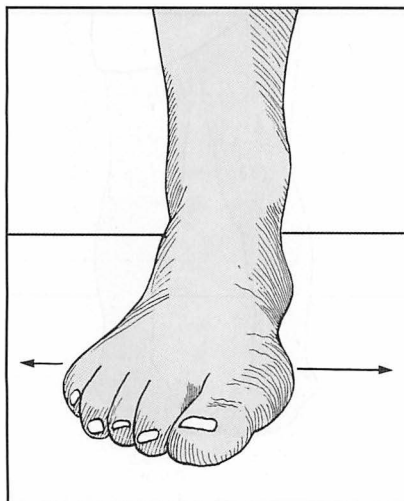
13.43. Posture (3): Genu valgum: Note the presence of genu valgum, which is frequently associated with valgus flat foot. Genu valgum in turn is most commonly seen as a result of a growth disturbance about the knee, or as a complication of rheumatoid arthritis.



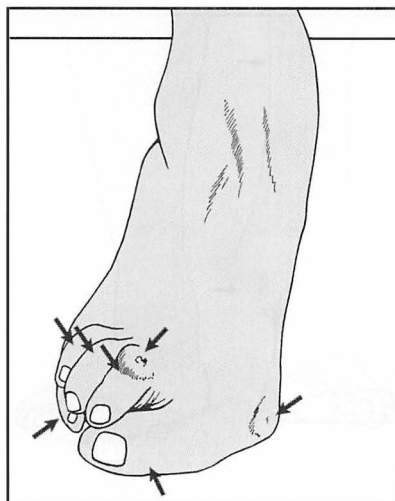
13.44 Posture (4): Eversion: If the foot is everted this suggests (A) peroneal spastic flat foot, (B) a painful lesion on the lateral side of the foot, (C) if less marked, pes planus.



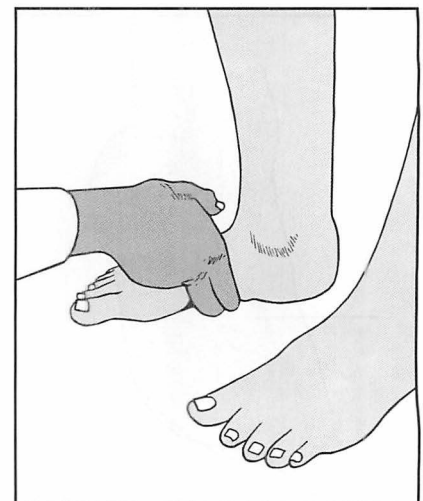
13.45. Posture (5): Inversion: If the foot is inverted this suggests (A) muscle imbalance from stroke or other neurological disorder, (B) hallux flexus or rigidus, (C) pes cavus, (D) residual talipes deformity, (E) a painful condition of the forefoot.



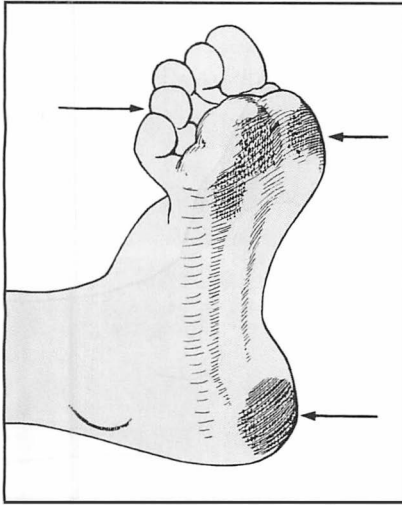
13.46. Posture (6): Splaying: Note whether there is any broadening of the forefoot. This is often the result of intrinsic muscle weakness, and may be associated with pes cavus, callus under the metatarsal heads, hallux valgus, anterior metatarsalgia, and trouble with shoe fitting.



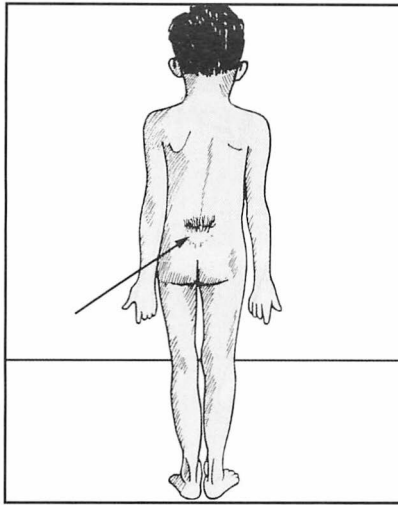
13.47. Posture (7): The toes: Reassess the toes for curling, clawing, mallet toe and hammer toe. Reassess the great toe, particularly for the degree of hallux valgus, overriding of adjacent toe(s), and torsion.



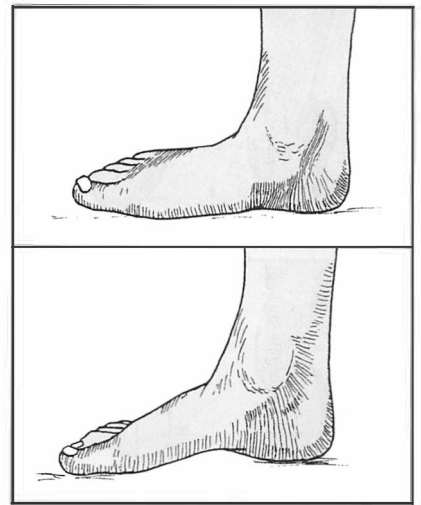
13.48. Posture (8): Medial arch (1): With the patient weightbearing, look at the medial longitudinal arch and try to assess its height. Try to slip the fingers under the navicular. In pes cavus, the fingers may penetrate a distance of 2 cm or more from a vertical line dropped from the medial edge of the foot.



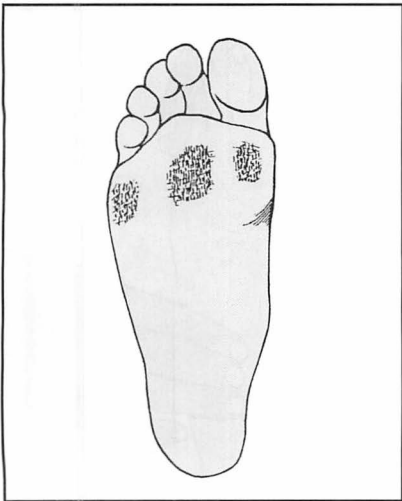
13.49. Posture (9): Medial arch (2): If the arch appears high and accentuated, this suggests a degree of pes cavus. Look for confirmatory clawing of the toes, callus or ulceration under the metatarsal heads, and alteration of the footprint.



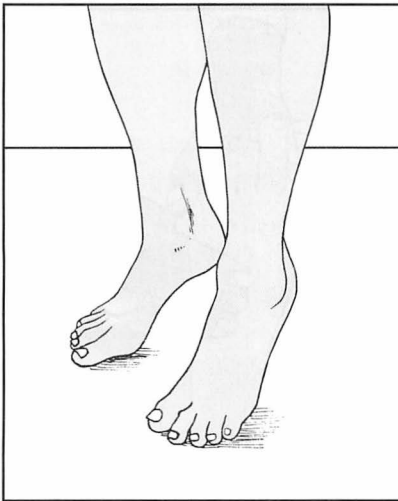
13.50. Posture (10): Medial arch (3): If pes cavus is present, carry out a full neurological examination. Look at the lumbar spine for dimpling of the skin, a hairy patch, or pigmentation suggesting spina bifida or neurofibromatosis. Radiological examination of the lumbar spine is desirable.



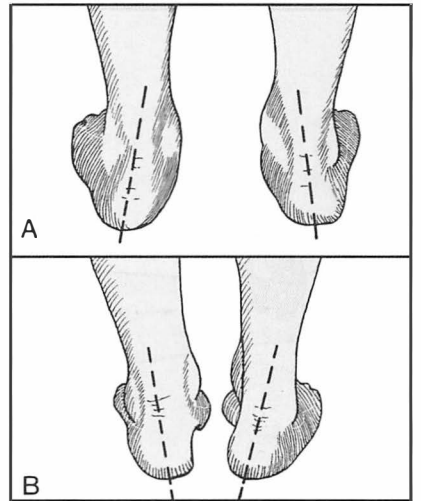
13.51. Posture (11): Medial arch (4): In *pes planus*, the medial arch is obliterated. The navicular is often prominent, and the fingers cannot be inserted under it. Ask the patient to attempt to arch the foot. In mobile flat foot the arch can often be restored voluntarily. Note that in children the arches are slow to become established. Examine the Achilles tendon, shortening of which can cause flat foot.



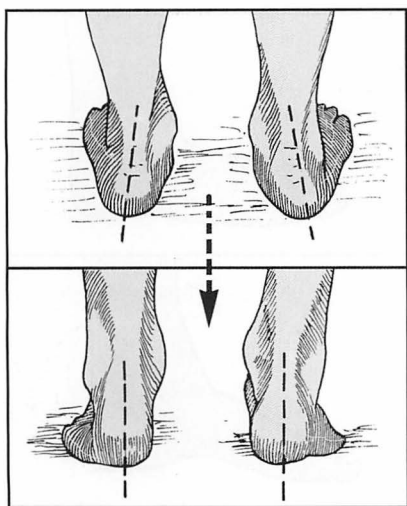
13.52. Posture (12): Medial arch (5): If pes planus is suspected, re-examine the sole for confirmatory evidence of callus under the metatarsal heads, and an increase in the area of the sole involved in weightbearing (i.e. extension of the narrow lateral strip). The footprint will be abnormal in these circumstances. Note also the presence of any knock-knee deformity.



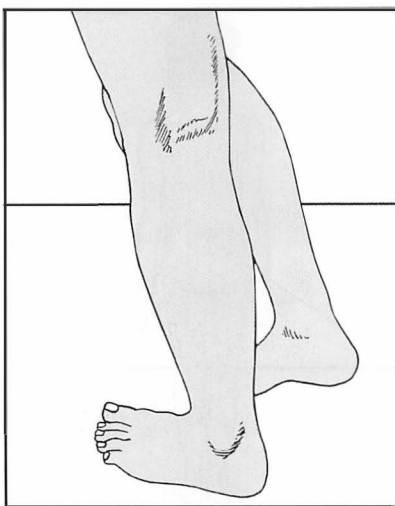
13.53. Posture (13): Medial arch (6): In pes planus, assess the mobility of the foot first by asking the patient to stand on the toes, while at the same time examining the alteration in the shape of the foot by sight and feel. Later in the examination carefully note the range of inversion and eversion. Note that although 23% of adults have flat feet, symptoms are not usually present unless there is associated stiffness.



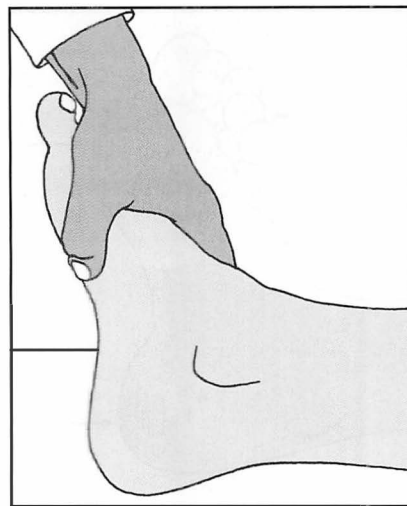
13.54. Posture (14): Heels (1): Look at the foot from behind, paying particular attention to the slope of the heels. Note (A) valgus heels are associated with pes planus, (B) varus heels are associated with pes cavus.



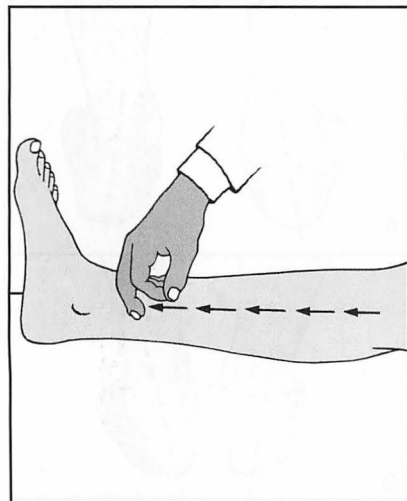
13.55. Posture (15); Heel (2): Again ask the patient to stand on the toes, observing the heels. If the heel posture corrects, this indicates a mobile subtalar joint. Persisting deformity suggesting loss of movement, which may be due to arthritic changes, tarsal coalition, loss of spring ligament or tibialis posterior function, or shortening of the tendocalcaneus.



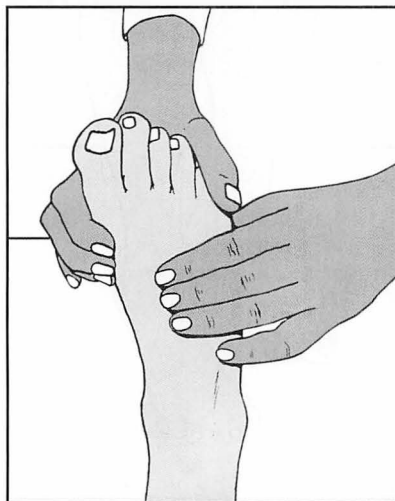
13.56. Gait: Watch the patient walking, first barefooted and then in shoes, to assess the gait. Examine from behind, from in front, and from the sides. A child should also be made to run. A reluctant child can usually be coaxed to walk holding its mother's hand. Highly technical methods of gait analysis using force plates, computer and videoanalysis etc. are available in some centres.



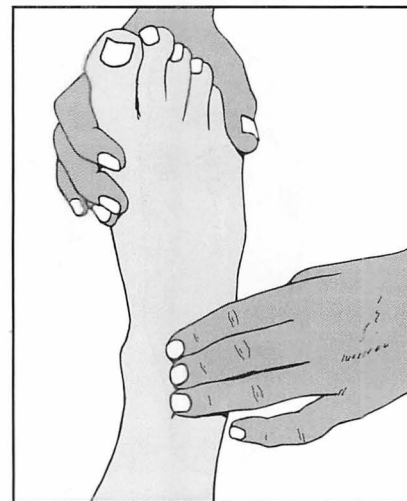
13.57. Skin temperature: Grasp the foot and assess the skin temperature, comparing one side with the other. Take into account the effects of local bandaging and the ambient temperature. A warm foot is particularly suggestive of rheumatoid arthritis or gout.



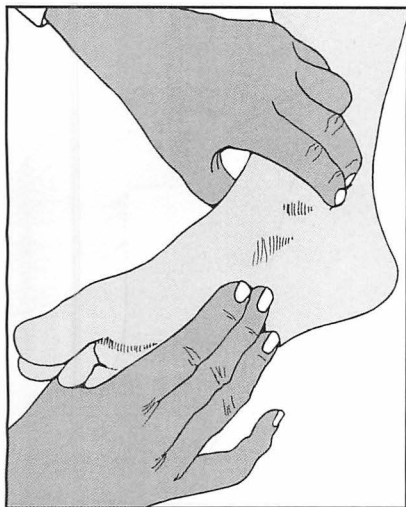
13.58. Circulation (1): If the foot is cold, note the skin temperature gradient along the length of the limb. You should have already observed any trophic changes or discoloration of the skin suggestive of ischaemia.



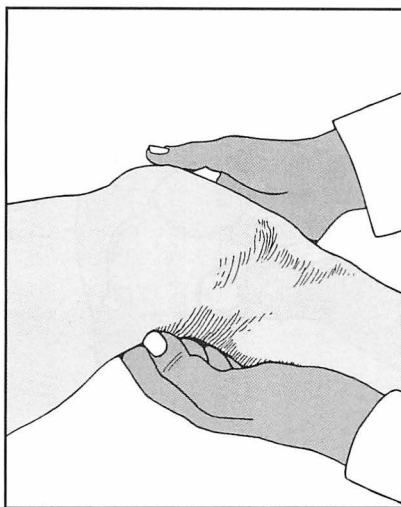
13.59. Circulation (2): Attempt to palpate the dorsalis pedis artery. The vessel lies just lateral to the tendon of extensor hallucis longus and its pulsation should be felt by compressing it against the middle cuneiform. A good pulse generally excludes any significant degree of ischaemia.



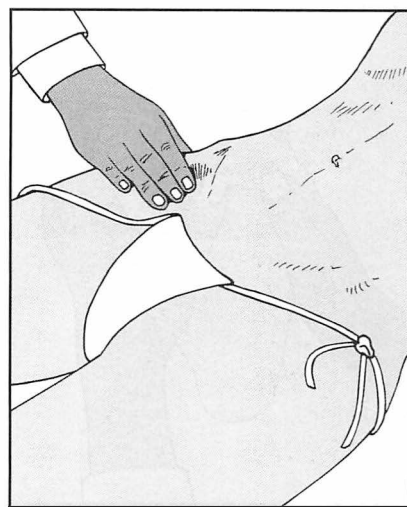
13.60. Circulation (3): Now try to feel the anterior tibial pulse near that midline of the ankle, just above the joint line where the vessel crosses the distal end of the tibia.



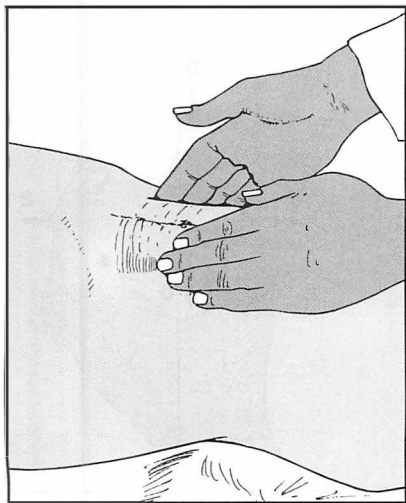
13.61. Circulation (4): The posterior tibial artery is often difficult to find, and it is helpful to invert the foot while palpating behind the medial malleolus.



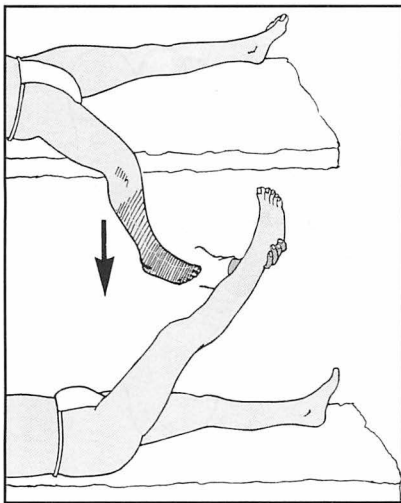
13.62. Circulation (5): Next seek the popliteal artery. When the patient is supine it can only be felt by applying strong pressure in an anterior direction, with the knee flexed to force the vessel against the femoral condyles. Alternatively, it may be sought with the patient prone.



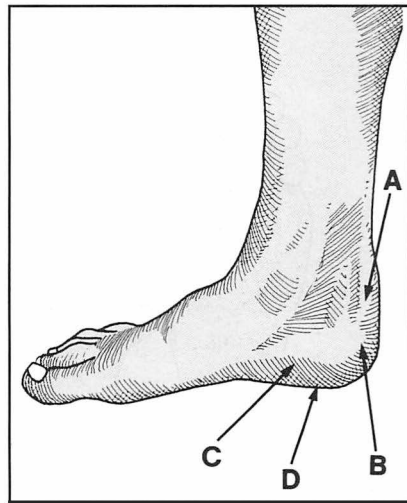
13.63. Circulation (6): The femoral pulse may be felt a little to the medial side of the midpoint of the groin, when the artery can be compressed against the superior pubic ramus.



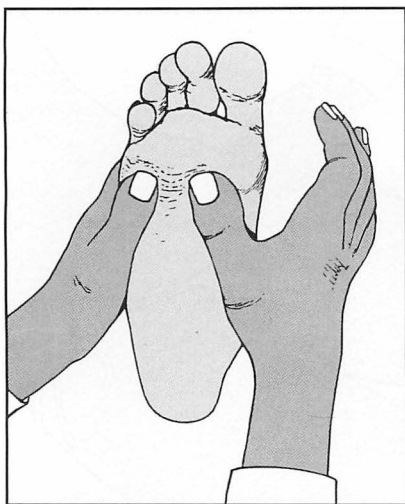
13.64. Circulation (7): Examine the abdomen, palpating the abdominal aorta. Note the presence of pulsation as it is compressed against the lumbar spine, and note any evidence of aneurysmal dilatation.



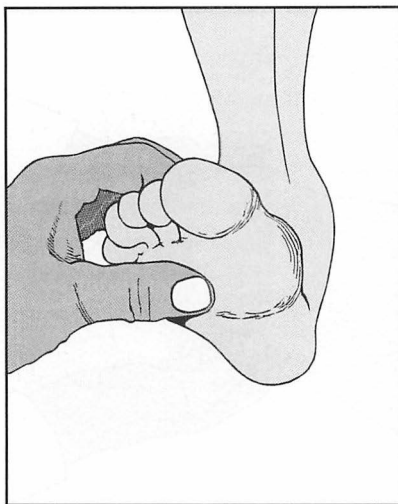
13.65. Circulation (8): Note any cyanosis of the foot when dependent and any blanching on elevation, suggestive of marked arterial insufficiency.



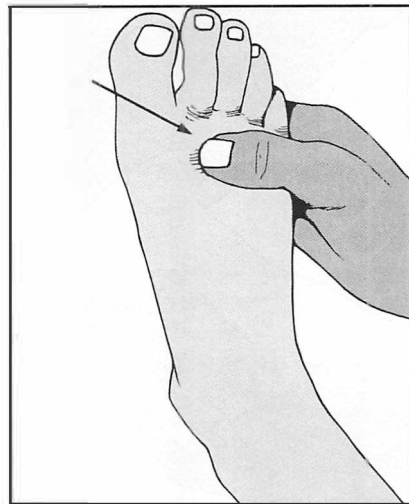
13.66. Tenderness (1): Heel: Tenderness round the heel is present in (A) Sever's disease; (B) superior calcaneal exostosis and tendo calcaneus bursitis; (C) plantar fasciitis and inferior calcaneal exostosis; (D) pes cavus.



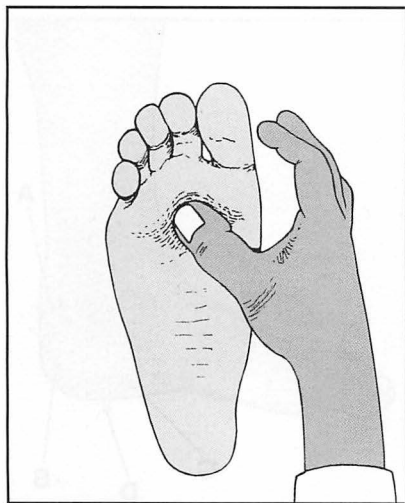
13.67. Tenderness (2): Forefoot (1): Diffuse tenderness under all the metatarsal heads is common in anterior metatarsalgia, pes cavus and pes planus, gout and rheumatoid arthritis.



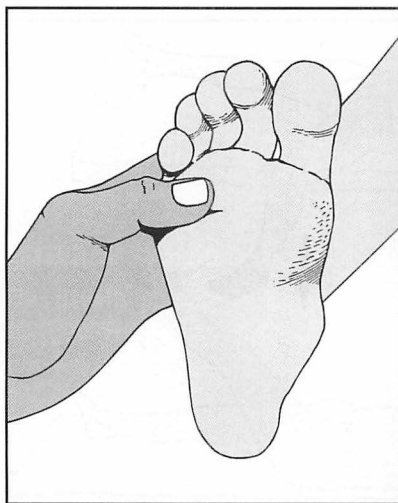
13.68. Tenderness (3): Forefoot (2): Tenderness *under* the second metatarsal head and *over* the second metatarsophalangeal joint is found when the second toe subluxes as a sequel to hallux valgus or rheumatoid arthritis.



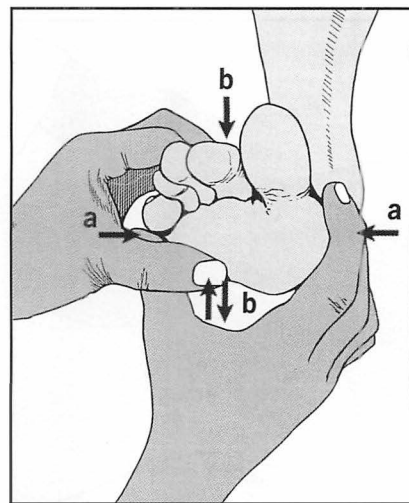
13.69. Tenderness (4): Forefoot (3): Puffy, localized swelling on the dorsum of the foot, palpable thickening of the second metatarsophalangeal joint, pain on plantarflexion of the toe, and joint tenderness are diagnostic of *Freiberg's disease*.



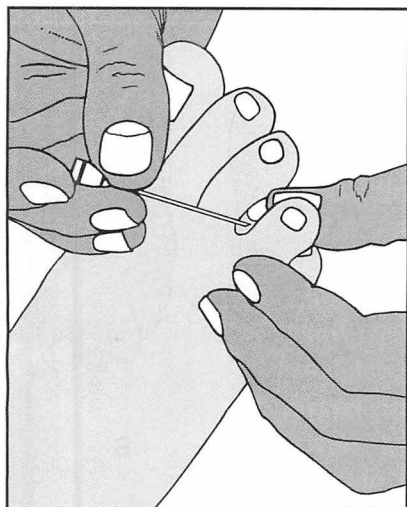
13.70. Tenderness (5): Forefoot (4): Tenderness on both plantar and dorsal surfaces of the second or third metatarsal necks or shafts occurs in march fracture.



13.71. Tenderness (6): Forefoot (5): Suspected plantar neuroma (Morton's metatarsalgia) (1): Sharply defined tenderness between the metatarsal heads (most commonly between the third and fourth) is found in plantar digital neuroma.

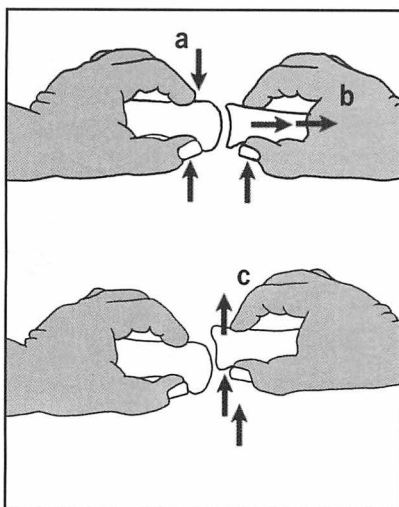


13.72. Suspected plantar neuroma (2): Compress the metatarsal heads (a) and note whether this reproduces the patient's symptoms of pain and possibly paraesthesia (Mulder's sign). Repeat while simultaneously pressing in a coordinated fashion from the sole towards the dorsal surface and back with the other hand (b). This may result in a painful click, which some consider to be associated with a mobile neuroma.



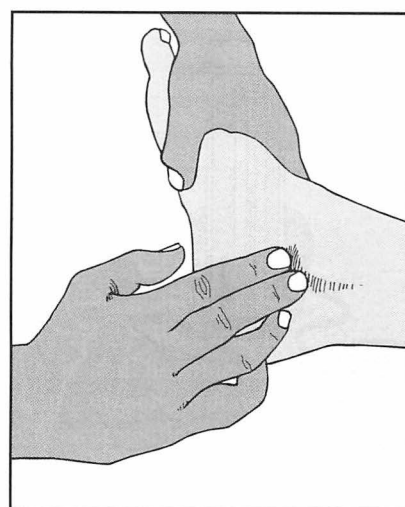
13.73. Suspected plantar neuroma (3):

Sometimes the patient complains of paraesthesia in the toes, and sensory impairment should be sought on both sides of the web space involved.



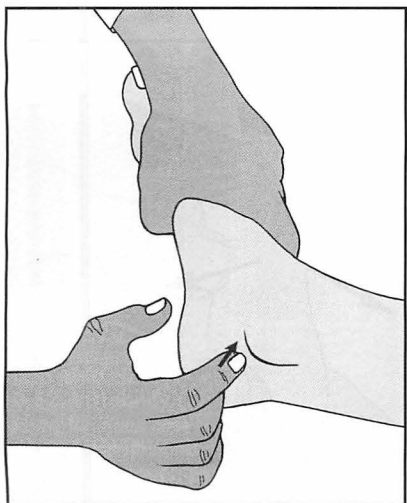
13.74. Suspected plantar neuroma (4):

The symptoms and findings from MP joint instability in a toe may be confused with Morton's metatarsalgia, so always perform the drawer test. To do so, grip the metatarsal at the suspect level with one hand (a) and with the other, while applying traction to the toe (b), attempt to displace it dorsally (c). Pain and excessive translation are diagnostic of instability.



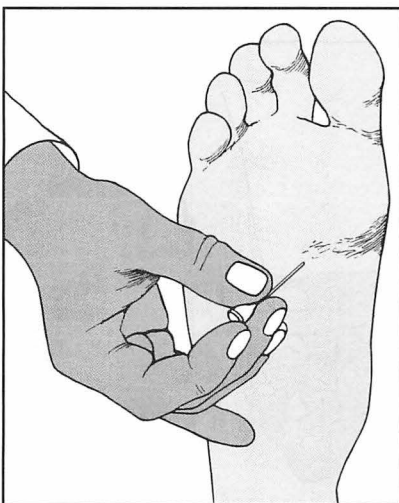
13.75. Tenderness (7): Tarsal tunnel syndrome (1):

Tenderness may occur over the posterior tibial nerve in the tarsal tunnel syndrome, where the presenting symptoms are usually of local pain and paraesthesia in the foot. Note that tenderness at the same site may occur in problems affecting the tibialis posterior tendon (which may be visualized by inverting the foot against resistance).



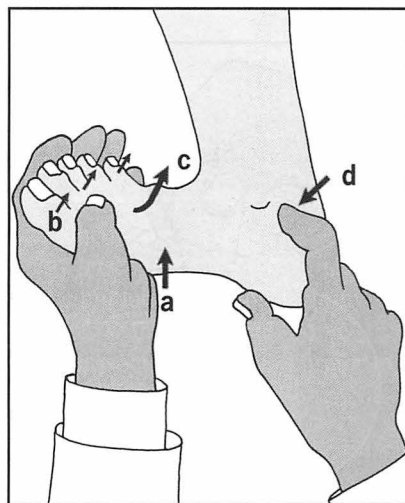
13.76. Tarsal tunnel syndrome (2):

Tinel's sign: In the tarsal tunnel syndrome, tapping over the posterior tibial nerve may give rise to paraesthesia in the sole of the foot.



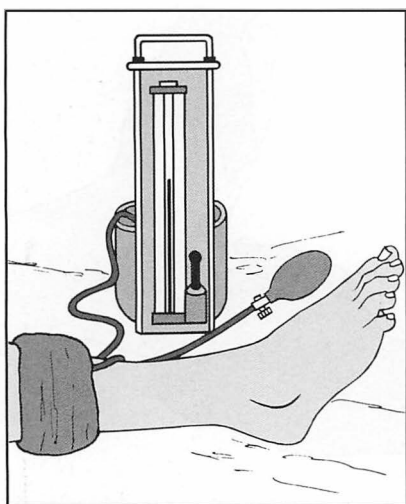
13.77. Tarsal tunnel syndrome (3):

Test sensation over the whole of the sole of the foot and the toes in the area of supply of the medial and lateral plantar nerves (the two terminal divisions of the posterior tibial nerve). Compare the feet. Sensory loss is in fact rather uncommon in tarsal tunnel syndrome.

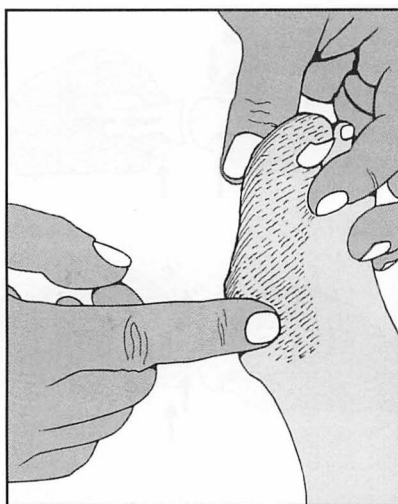


13.78. Tarsal tunnel syndrome (4): The dorsiflexion-eversion test (Kinoshita et al.):

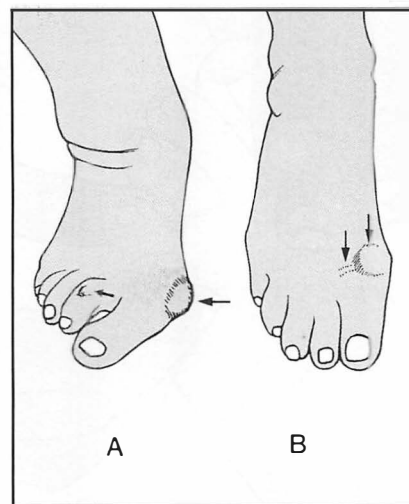
Maximally dorsiflex the ankle (a) and the MP joints of all the toes (b); firmly evert the foot (c) and hold this position. In a positive case the patient's symptoms will be reproduced, sometimes after only a few seconds. Look also for increased local tenderness (d) accompanying the manoeuvre.



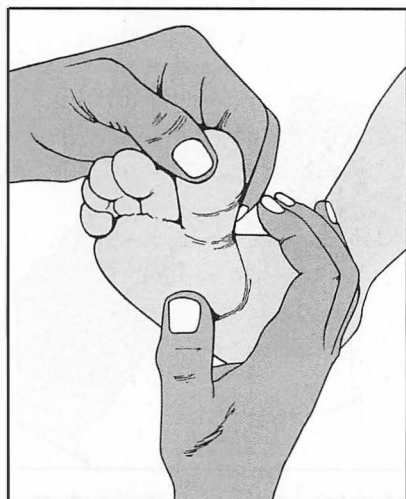
13.79. Tarsal tunnel syndrome (4): The tourniquet test: In doubtful cases, apply a tourniquet to the calf and inflate to just above the systolic blood pressure. If this brings on the patient's symptoms in 1–2 minutes, the diagnosis is confirmed. Pain and paraesthesia on the *dorsum* of the foot may be encountered in the much rarer *superficial peroneal nerve compression syndrome*.



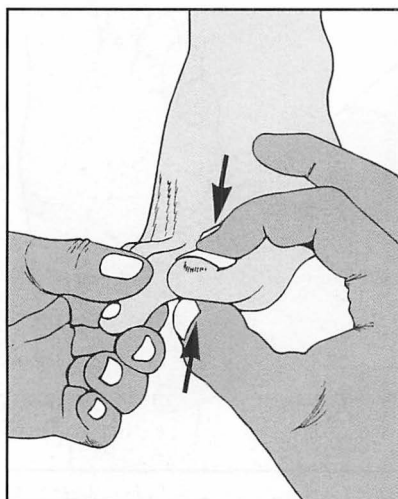
13.80. Tenderness (8): Great toe (1): In *gout*, tenderness is often most acute but is diffusely spread round the whole metatarsophalangeal joint and often the entire toe. There is often a reddish-blue discoloration of the skin round the toe.



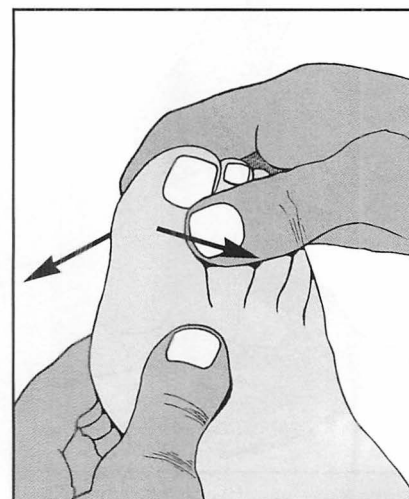
13.81. Tenderness (9): Great toe (2): (A) In *hallux valgus* tenderness is often absent, or confined to the bunion or over painful corns on adjacent toes. (B) In *hallux rigidus* there is usually tenderness over the exostoses that arise on the metatarsal head and proximal phalanx, often on the dorsal surface of the joint as well as the lateral side, where protective bursae may form.



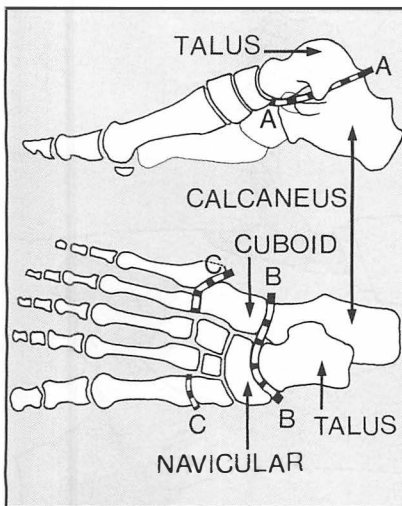
13.82. Tenderness (10): In *sesamoiditis* there is tenderness over the sesamoid bones, which are situated under the first metatarsal head, although they may sublux laterally to a marked degree, especially in cases of gross *hallux valgus*. Pain is produced if the toe is dorsiflexed while pressure is maintained on the sesamoid bones.



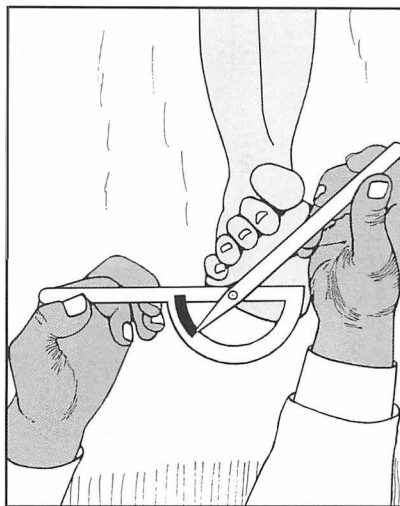
13.83. Tenderness (11): Great toenail: In *subungual exostosis* pain is produced by squeezing the toe in the vertical plane. In *ingrowing toenail* pain is produced by side-to-side pressure.



13.84. Crepitus: Move the great toe in an up and down direction while palpating the metatarsophalangeal joint. Repeat with the interphalangeal joint. Crepitus, indicating osteoarthritic change, is constant in the metatarsophalangeal joint in *hallux rigidus*. Interphalangeal joint crepitus is considered a contraindication for MP joint fusion.

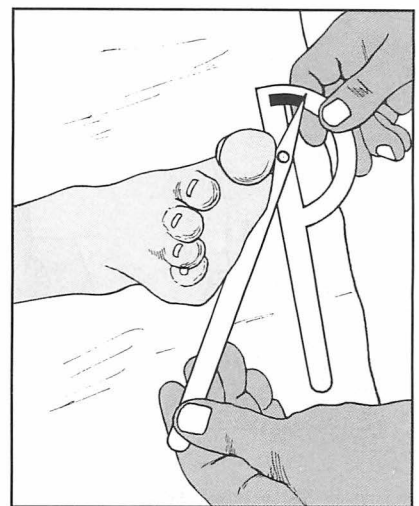


3.85 Movements (1): In assessing foot movements, remember that the total range of supination and pronation in the foot is made up of movements that occur in the subtalar joint (A–A), the midtarsal joint (B–B), and the tarsometatarsal joints (C–C). In the latter, the main movements occur in the joints at the bases of the first, fourth and fifth metatarsals.



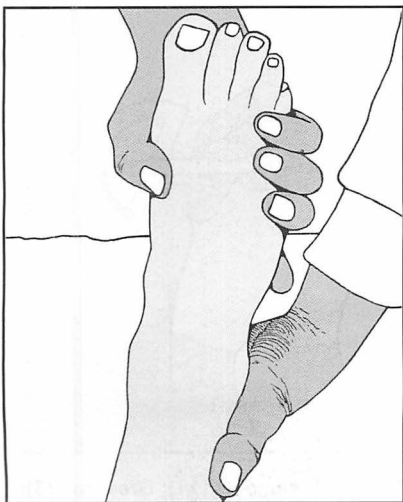
13.86. Movements (2): Supination: Ask the patient to turn the soles of the feet towards one another. The patellae should be vertical. The resulting angle may be measured. If the legs are squarely placed on the couch, its end may be used as a guide.

Normal range = 35° approximately. Note that this is a summation of movements occurring at the three levels previously described.

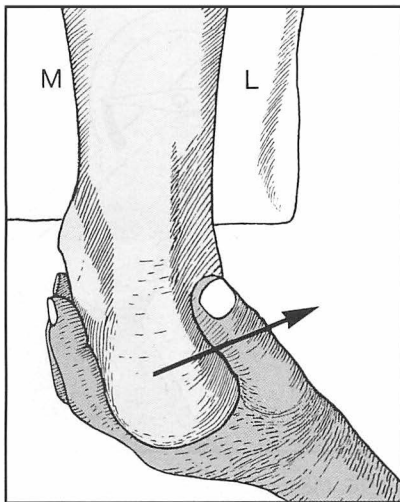


13.87. Movements (3): Pronation: Ask the patient to turn the feet outwards. The range of movement may be measured in a similar fashion.

Normal range = 20° approximately.

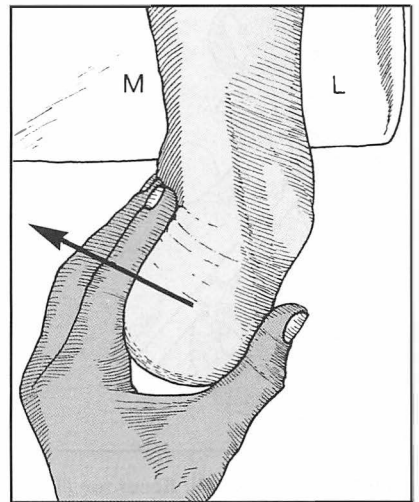


13.88. Movements (4): If supination and pronation are restricted, fix the heel with one hand and with the other assist the patient to repeat these movements. No further reduction in the range indicates a stiff subtalar joint. The presence of some movement shows that the midtarsal and tarsometatarsal joints preserve some mobility.



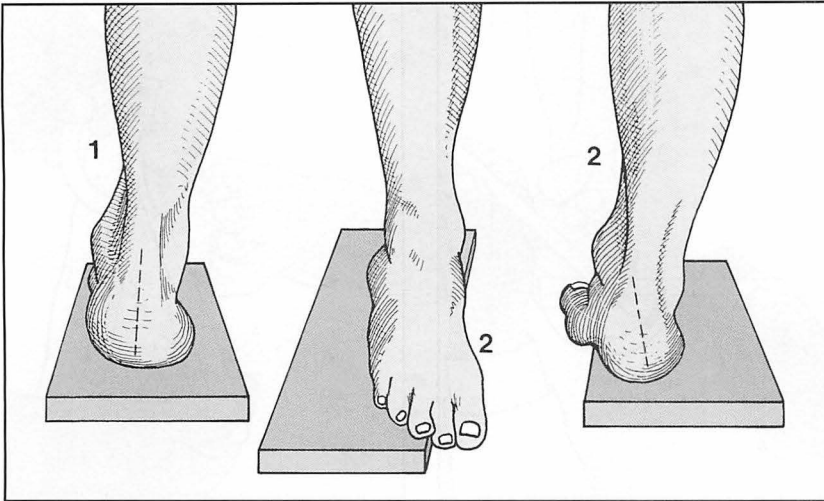
13.89. Movements (5): Turn the patient face down with the feet over the edge of the examination couch. Evert the heel and note the presence of movement in the subtalar joint by the position of the heel.

Normal range of eversion of the heel = 10° approximately.

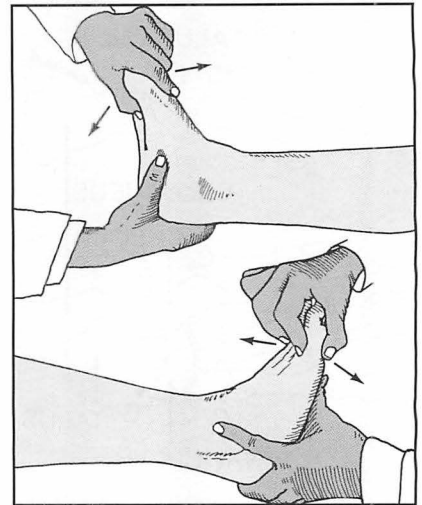


13.90. Movements (6): Repeat, forcing the heel into inversion.

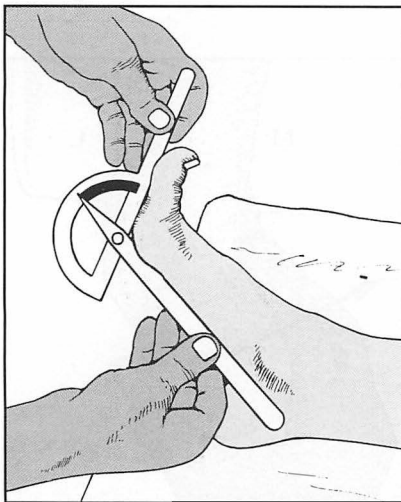
Normal range of inversion of the heel = 20° approximately. Loss of movement indicates a stiff subtalar joint (e.g. old calcaneal fracture, rheumatoid or osteoarthritis, spastic flat foot).



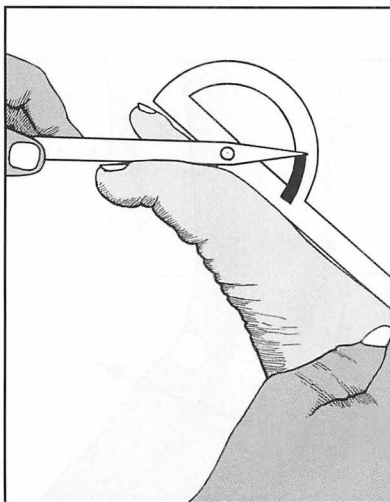
13.91. Movements (7): In idiopathic pes cavus, and pes cavus secondary to neuromuscular disease, the subtalar joint is generally mobile; in pes cavus secondary to congenital talipes equinovarus the subtalar joint is often stiff. As a further guide to the differentiation of these cases, mark the axis of the heel with a skin pencil and note its position with the patient standing on a 2 cm block of wood, first squarely (1), and then with the forefoot over the medial edge (2). A change in the axis (3) indicates a mobile subtalar joint.



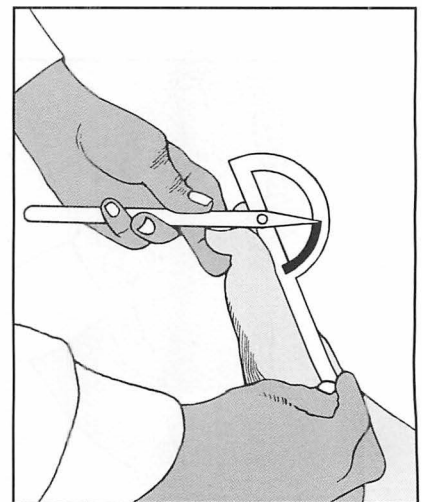
13.92. Movements (8): Test for mobility in the first, fourth and fifth tarsometatarsal joints by steadying the heel with one hand and attempting to move the metatarsal heads individually in a dorsal and plantar direction.



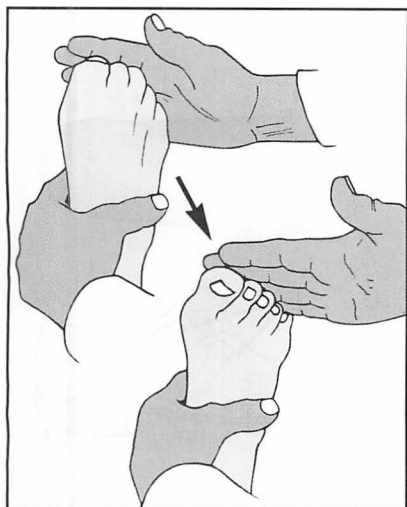
13.93. Movements (9): Great toe (1): Note the range of extension in the great toe at the metatarsophalangeal joint.
Normal range = 65°



13.94. Movements (10): Great toe (2): Note the range of flexion at the metatarsophalangeal joint.
Normal range = 40°.
Metatarsophalangeal movements are severely restricted and painful in hallux rigidus. There is often little impairment in hallux valgus unless secondary arthritic changes are quite severe.

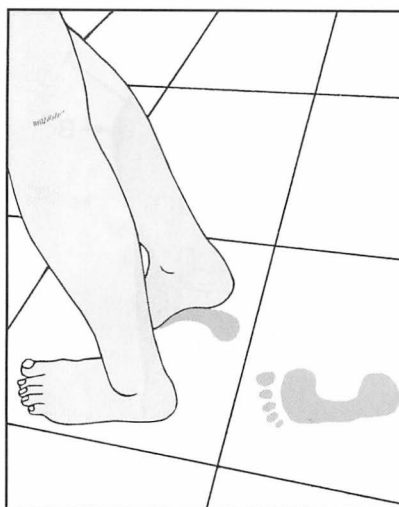

13.95. Movements (11): Great toe (3): Note the range in the interphalangeal joint.
Normal flexion = 60°.
Extension = 0°.
Restriction is common after fractures of the terminal phalanx, and is generally regarded as being a contraindication to metacarpophalangeal joint fusion.



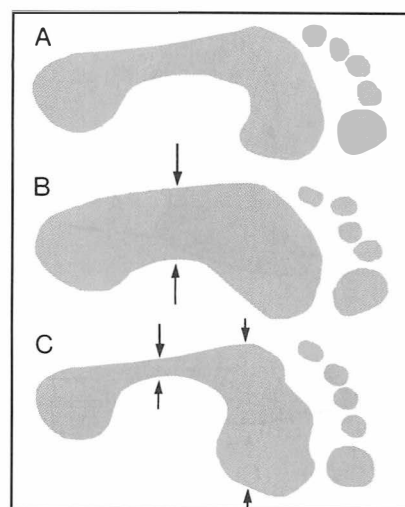
13.96. Movements (12): Lesser toes:

Overall mobility may be roughly assessed by alternately curling and straightening the toes. Accurate measurement of individual ranges is seldom needed. Restriction is often seen in gout, rheumatoid arthritis, Sudeck's atrophy, and ischaemic conditions of the foot and leg.



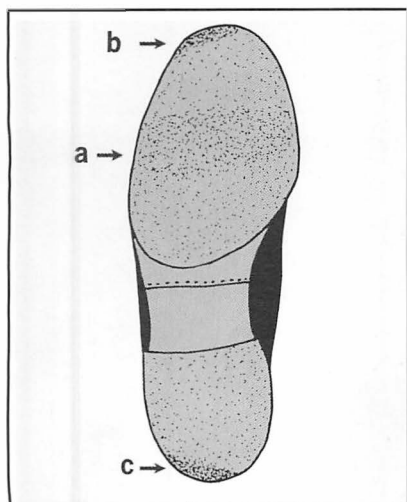
13.97. Footprint (1):

It is sometimes helpful to see the pattern of weight distribution in the foot: note the imprint of the sweaty foot on a vinyl floor, or (A) apply olive oil to the sole and dust the imprint with talc; (B) use ink on paper (or fix on an X-ray plate and develop it). Various specialized technical methods are available. A pedoscope may also be used for this purpose.

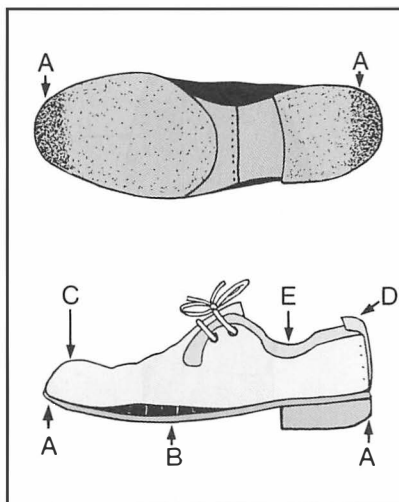


13.98. Footprint (2): Typical patterns:

(A) Normal foot. (B) Pes planus. Note the increase in area of the central part of sole taking part in weightbearing. (C) Pes cavus. Note the decrease in area of contact in the midsole and the splaying of the anterior part of the foot. In extreme cases the lateral weightbearing strip may disappear.

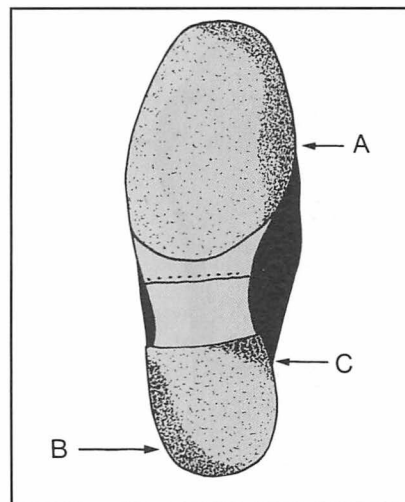


13.99. Shoes (1): The patient's only complaint may be shoe wear. Inspection is expected and may be helpful. In the normal sole wear is fairly even, being maximal across the tread (a) and at the tip (to the lateral side) (b). At the back of the heel (c), maximum wear is also to the lateral side.



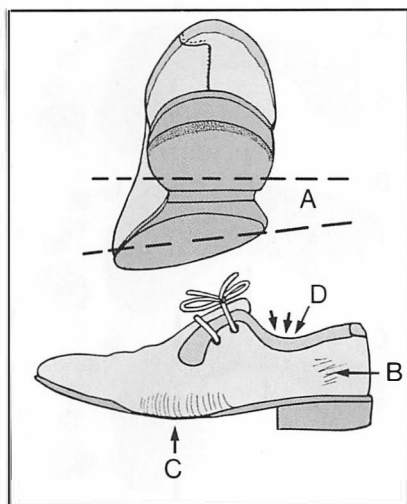
13.100. Shoes (2): The too-short shoe:

Note (A) the excessive wear at the toe and heel. (B) A gap may appear above sole. (C) The toe cap may bulge, and the inside of shoe may be marked by the toes. (D) The heel may give at the seam. There may be blistering of the heel, and excessive sock wear. (E) A gap may appear between the quarter and the ankle.

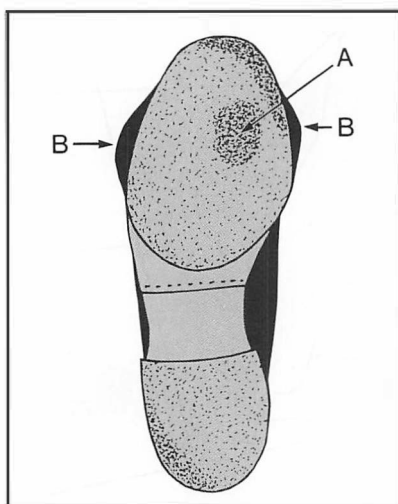


13.101. Shoes (3): Pes planus (1):

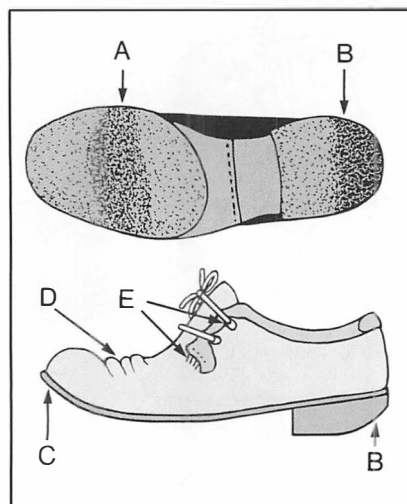
Note (A) wear on the medial side of the sole extending to the tip; (B) wear on the outer side of heel; (C) in severe cases, wear on the diagonal corner of heel.



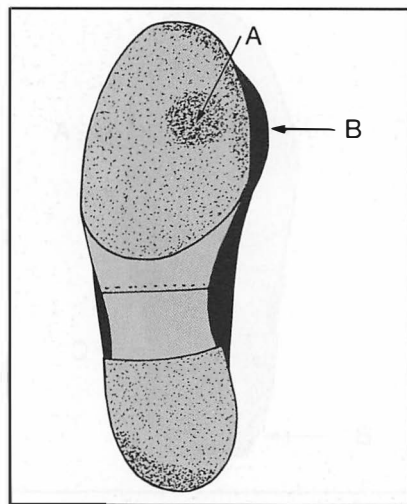
13.102. Shoes (4): Pes planus (2): Note (A) the shoe may be twisted when viewed from behind (i.e. the heel and sole are on different planes); (B) scuff marks on medial side; (C) the upper bulges over the sole on the medial side. The quarter bulges away from the foot (D).



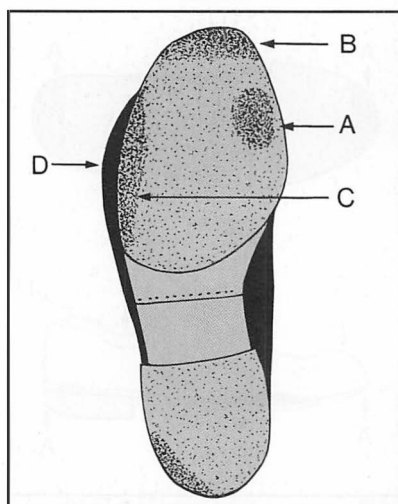
13.103. Shoes (5): Splay foot: Note (A) excess wear in the region of the first or second metatarsal heads. (B) The upper bulges over the sole anteriorly.



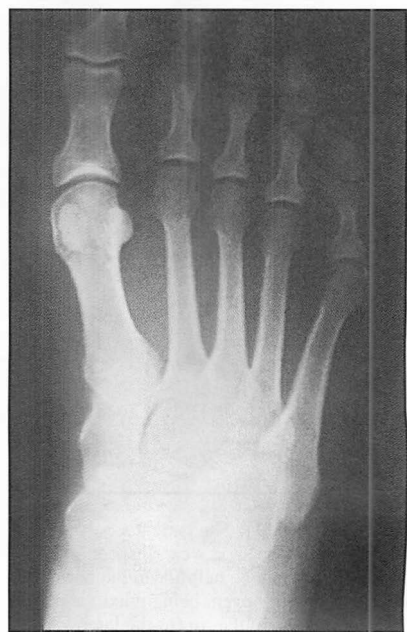13.104. Shoes (6): Pes cavus: Note (A) excessive wear under the metatarsal head region; (B) excessive wear at the back of the heel; (C) raising of toe; (D) creases; (E) giving way of laces.



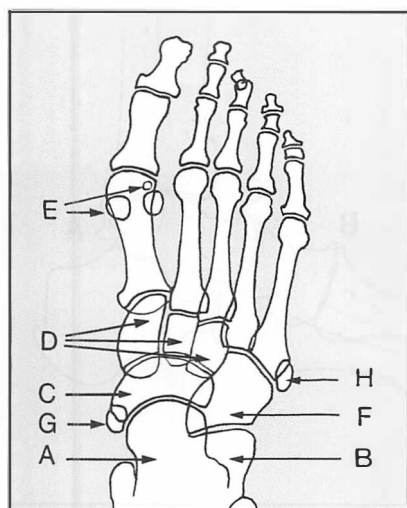
13.105. Shoes (7): Hallux valgus: There is often (A) excess wear as in splay foot under the area of the first and second metatarsal heads; (B) bulging of the upper to accommodate the prominent first metatarsal head.



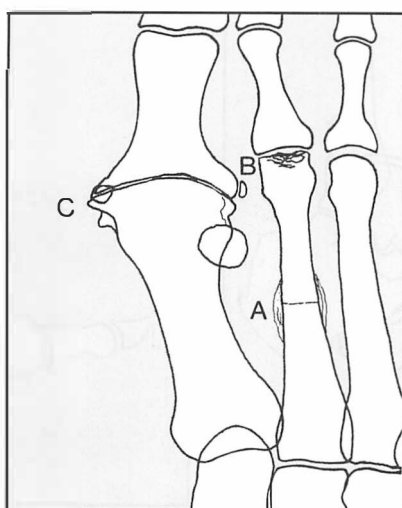
13.106. Shoes (8): Hallux rigidus: Note (A) excessive wear under the first metatarsal head and (B) at the tip of the sole; (C) excess wear on the lateral side (through walking on the side of the foot); (D) lateral overhang. In addition, the toe of the shoe may be upturned.



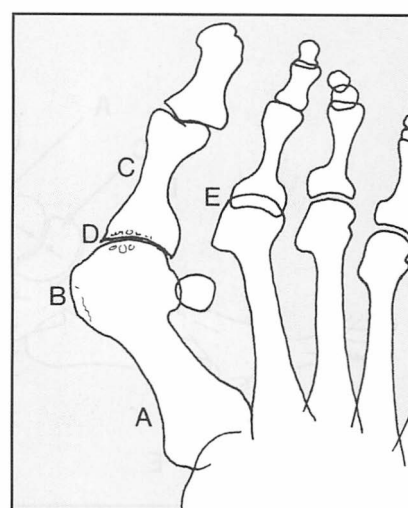
13.107. Radiographs (1): Normal anteroposterior radiograph of the foot.



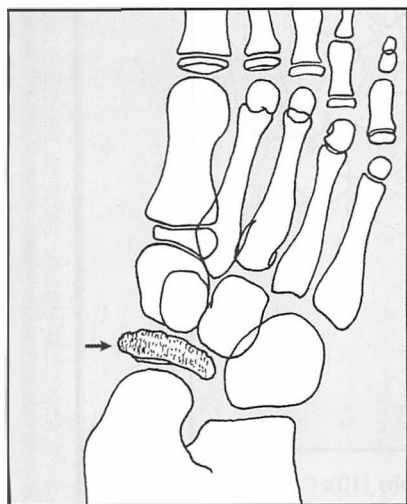
13.108. Radiographs (2): An AP view is routine, along with either a lateral or an oblique. Note (A) talus; (B) calcaneus; (C) navicular; (D) cuneiforms; (E) sesamoids (often bi- or tripartite); (F) cuboid. Inconstant accessory bones may be mistaken for fracture or loose bodies, e.g. (G) os tibiale externum; (H) os Vesalianum.



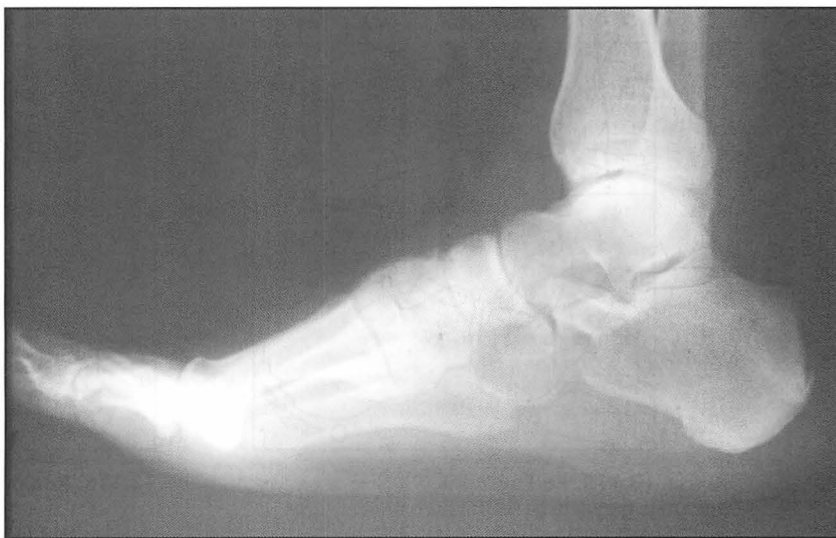13.109. Radiographs (3): In the AP view, note the bone texture and typical anomalies, such as (A) march fracture (periosteal reaction occurs in the healing stages); (B) Freiberg's disease affecting the second metatarsal head; (C) osteoarthritic changes with exostosis formation (hallux rigidus).



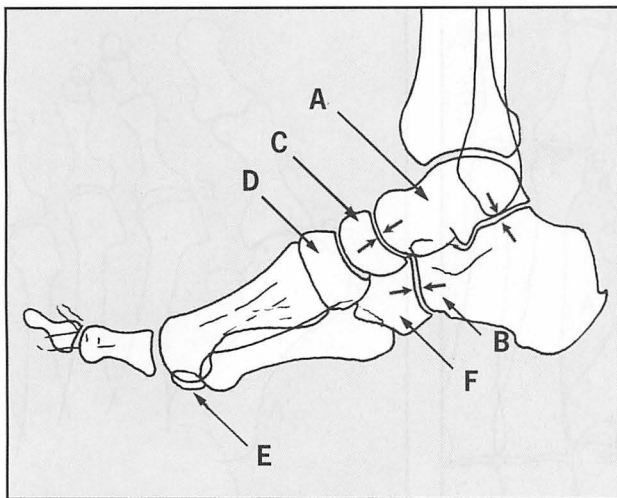
13.110. Radiographs (4): Note, if present, (A) metatarsus primus varus; (B) first metatarsal 'exostosis'; (C) hallux valgus; (D) joint narrowing or cyst formation, suggestive of osteoarthritis, rheumatoid arthritis or gout; (E) metatarsophalangeal joint subluxation secondary to hallux valgus or to rheumatoid arthritis.



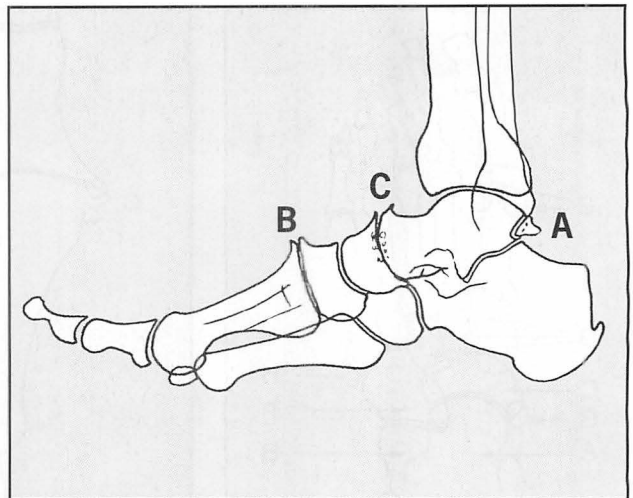
13.111. Radiographs (5): In the child, note any increased density of the navicular, suggestive of Kohler's disease. The bone may appear reduced in size.



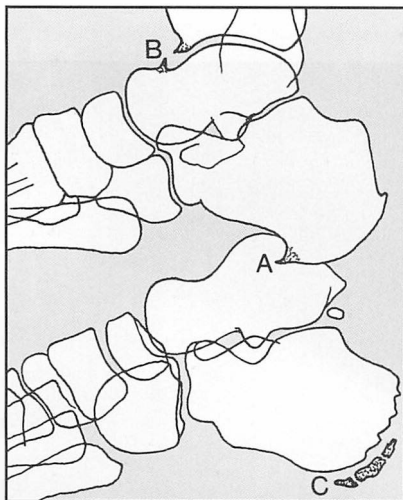
13.112. Radiographs (6): Normal lateral radiograph of the foot.



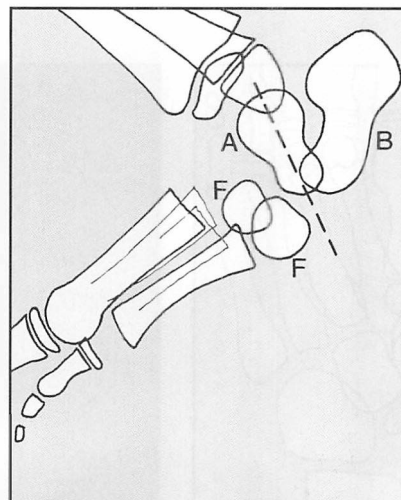
13.113. Radiographs (7): In the lateral radiograph it is often difficult to trace the outline of individual metatarsals owing to superimposition, although the first and fifth are usually quite clear: (A) talus, (B) calcaneus, (C) navicular, (D) medial cuneiform, (E) sesamoid, (F) cuboid. Note the talonavicular and calcaneocuboid joints.



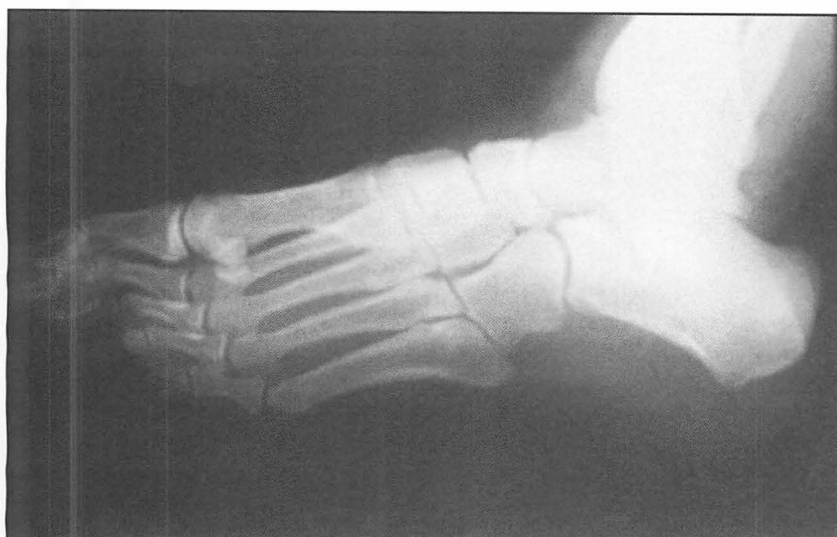13.114. Radiographs (8): Note, if present, (A) the accessory os trigonum (often mistaken for a fracture), (B) cuneiform exostosis, (C) narrowing of the midtarsal joint, and other changes suggestive of midtarsal rheumatoid or osteoarthritis.



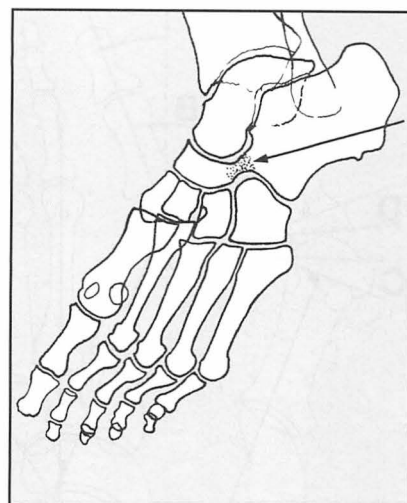
13.115. Radiographs (9): Note, if present in the adult, (A) calcaneal spur, sometimes associated with plantar fasciitis, (B) footballer's ankle, (C) in the child, increased density and fragmentation of the calcaneal epiphysis, seen in Sever's disease.



13.116. Radiographs (10): Congenital vertical talus, which is associated with dislocation of the talonavicular joint, has a classic radiographic appearance. Note the direction of the long axis of the talus. (A) Talus; (B) calcaneus; (F) both centres of ossification of the cuboid.

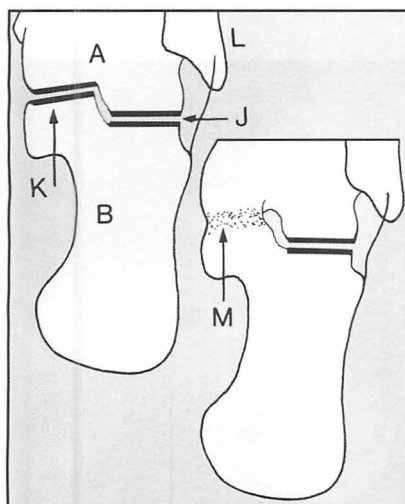


13.117. Radiographs (11): Normal oblique radiograph of the foot.

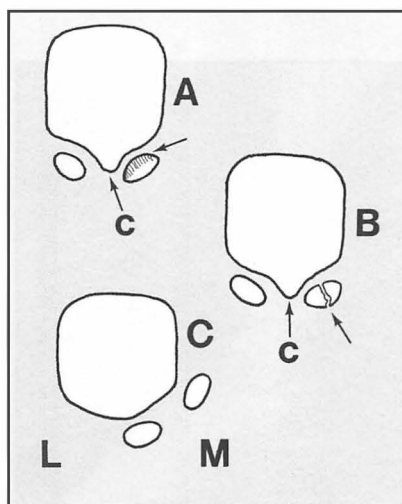


13.118. Radiographs (12):

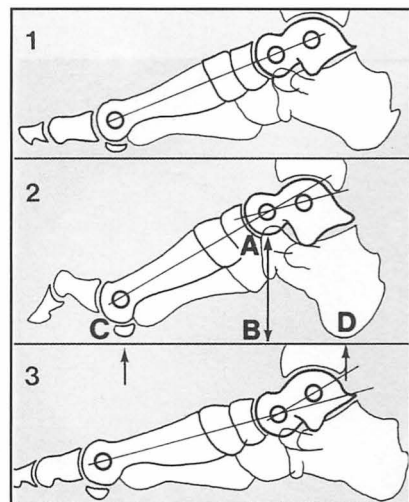
Calcaneonavicular bar or synostosis (and the commonest of the tarsal coalitions) is best seen in oblique projections of the foot, and is found in association with spastic flat foot.



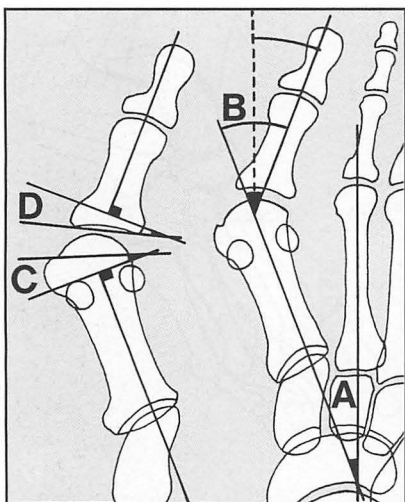
13.119. Radiographs (13): An axial or tangential projection of the heel shows (A) talus, (B) calcaneus, (J) posterior talocalcaneal joint, (K) sustentaculum tali, (L) base of fifth metatarsal. A talocalcaneal synostosis (M), sometimes found in spastic flat foot, may be demonstrated by this view.



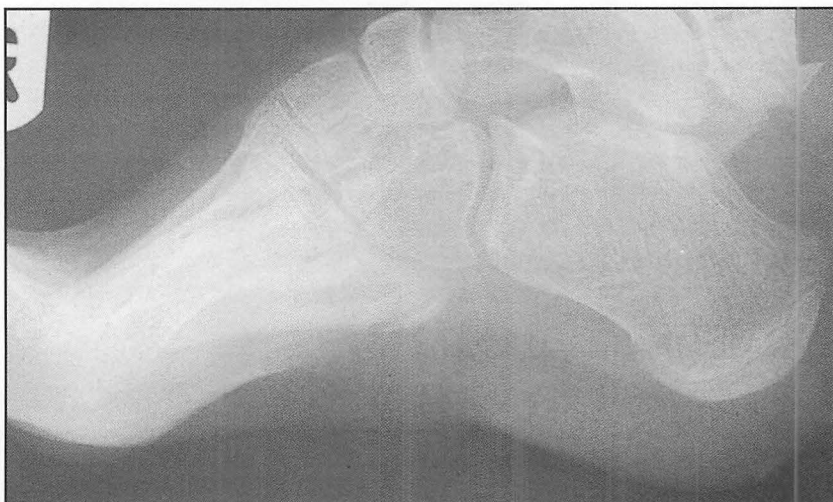13.120. Radiographs (14): A tangential projection may be used when the sesamoid bones are suspect, showing, for example, (A) osteochondritic changes, (B) stress fracture, (C) dislocation and loss of the crista (c), seen most commonly in association with advanced hallux valgus.



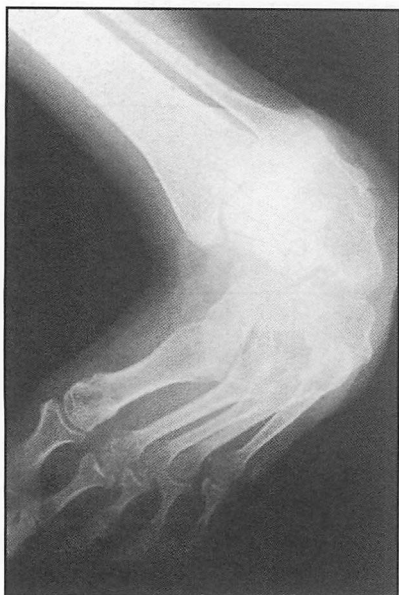13.121. Radiographs (15): A weightbearing lateral projection is of value in assessing deformities involving the medial longitudinal arch and the toes. The axes of the talus and first metatarsal normally coincide, and the height of the arch may be assessed by noting the ratio AB/CD: (1) normal, (2) pes cavus, (3) pes planus.



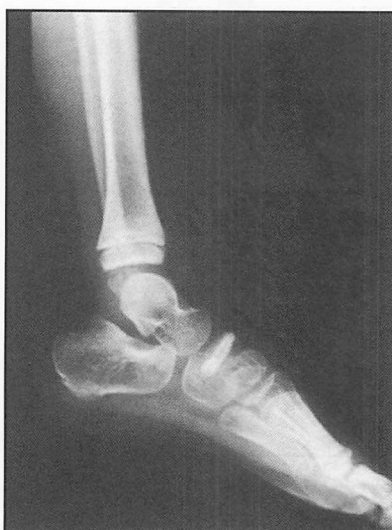13.122. Radiographs (16): In assessing hallux valgus, note (A) the *intermetatarsal angle* (the '1/2 angle') is normally 9° or less – more suggests metatarsus primus varus; (B) the so-called *hallux valgus angle*, is normally 16° or less. (*True valgus* of the hallux is B–A.) The normal *distal metatarsal articular* and *proximal phalangeal articular angles* (C and D) are respectively 15° and 5° (or less).)



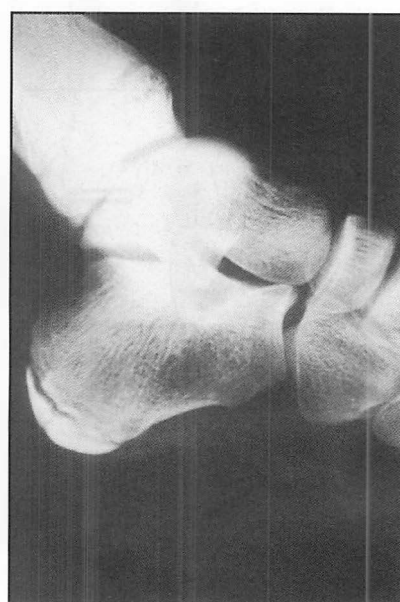
13.123. Radiographs of the foot: Examples of pathology (1): Note the accentuation of both the medial and lateral longitudinal arches of the foot.
Diagnosis: pes cavus.



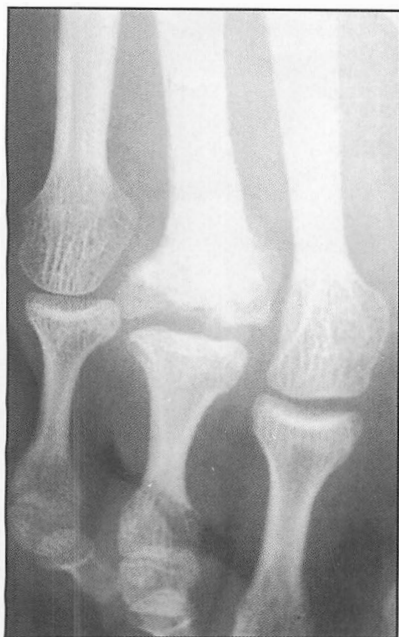13.124. Pathology (2): There is gross deformity of the tarsus, with accompanying deformity of the foot.
Diagnosis: untreated club foot.



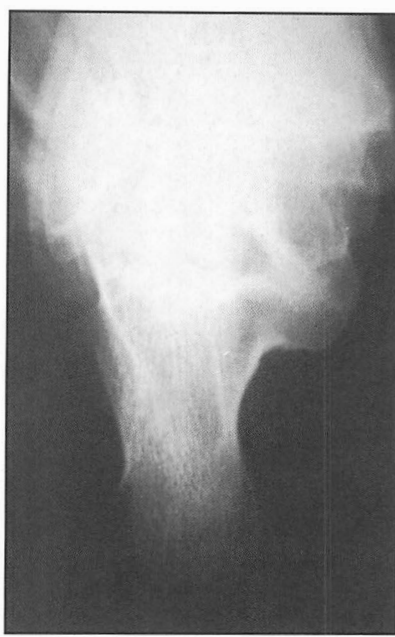
13.125. Pathology (3): There the marked increased density and flattening of the navicular.
Diagnosis: Kohler's disease.



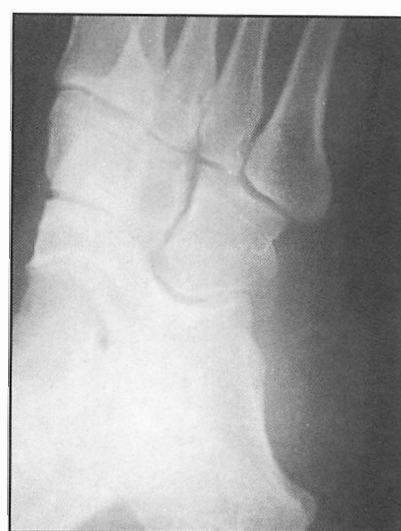
13.126. Pathology (4): There is increased density and fragmentation of the calcaneal epiphysis.
Diagnosis: Sever's disease.



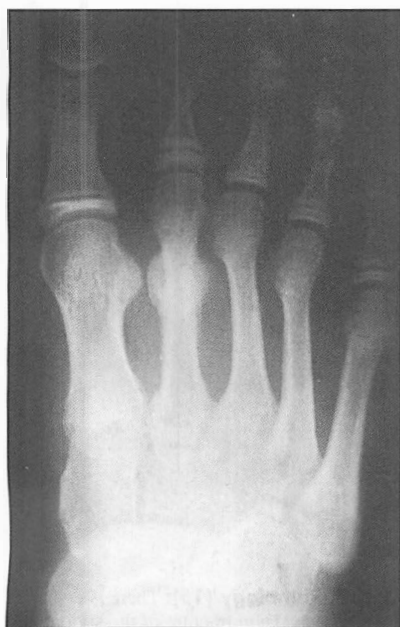13.127. Pathology (5): There is marked destruction of the second metatarsal head, with broadening and loss of concavity in the base of the proximal phalanx.
Diagnosis: Freiberg's disease.



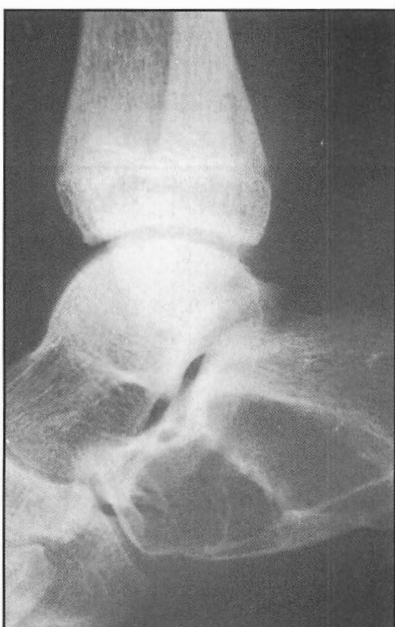
13.128. Pathology (6): This is an axial (tangential) projection of a patient found to have a painful rigid flat foot. The medial part of the subtalar joint, between the sustentaculum tali of the calcaneus and the talus on the right side of the radiograph is not apparent.
Diagnosis: talocalcaneal synostosis (coalition) in the region of the sustentaculum tali.



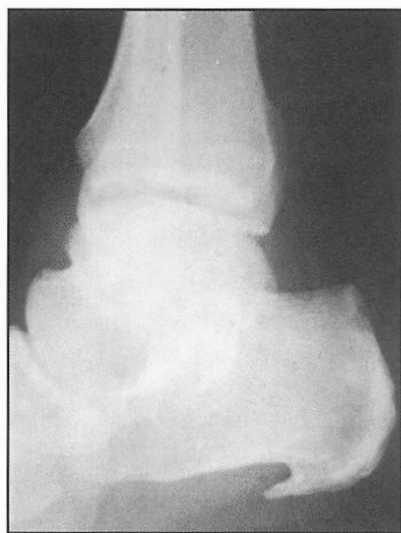13.129. Pathology (7): This oblique radiograph shows a thick bridge of bone uniting the calcaneus with the navicular. The patient had a spastic flat foot.
Diagnosis: calcaneonavicular synostosis (calcaneonavicular coalition; calcaneonavicular bar).



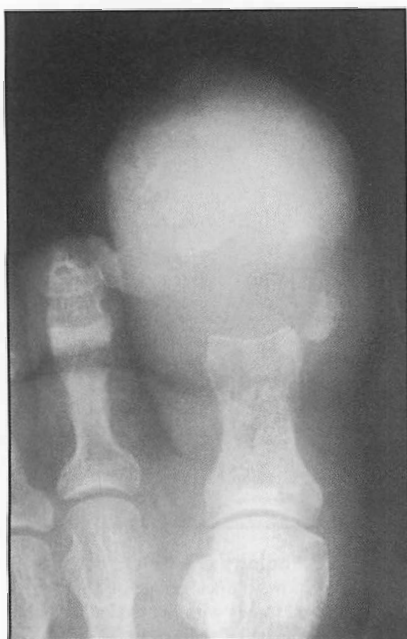13.130. Pathology (8): The patient, a probationer nurse, gave a 5-week history of anterior foot pain, and the radiograph of her foot shows new bone formation in the second metatarsal shaft.
Diagnosis: healing march fracture.



13.131. Pathology (9): There is distortion of the normal architecture of the calcaneus associated with the presence of two large cystic spaces in the bone.
Diagnosis: the appearances are typical of a simple, multilocular bone cyst.

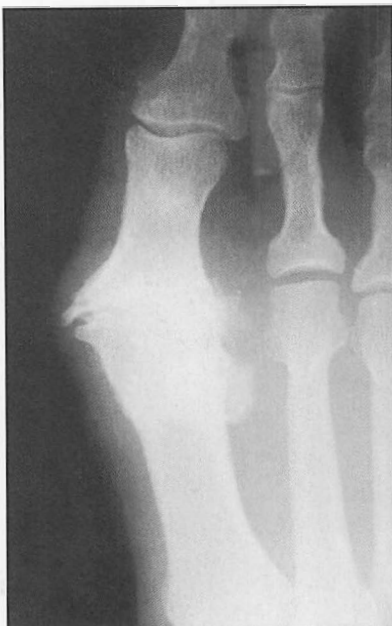

13.132. Pathology (10): There was complaint of pain on the posteromedial aspect of the foot, and the inferior surface of the calcaneus is elongated.
Diagnosis: plantar fasciitis associated with a large exostosis or calcaneal spur.



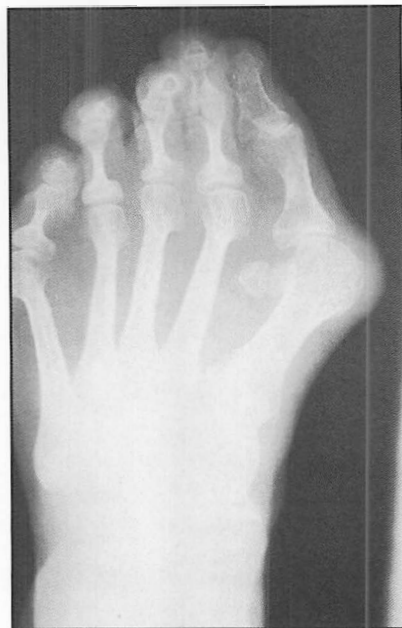13.133. Pathology (11): The terminal phalanx has virtually disappeared, and there is gross soft tissue swelling of the toe which was associated with great pain.

Diagnosis: the appearances are due to a severe nail infection which has spread locally, leading to a destructive osteitis.



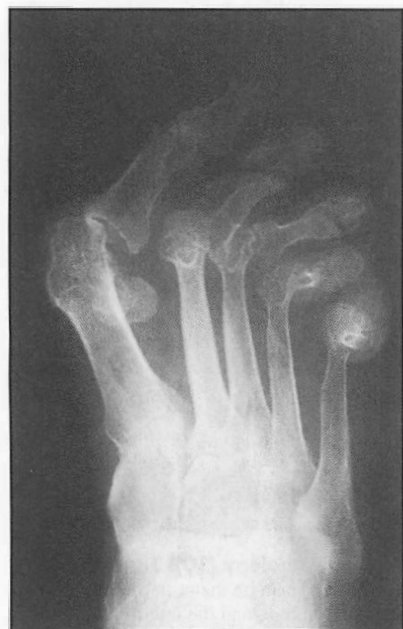13.134. Pathology (12): The metatarsophalangeal joint of the great toe is narrowed, and there is marked osteoarthritic lipping on both sides of the joint. Little movement was present.

Diagnosis: advanced hallux rigidus.



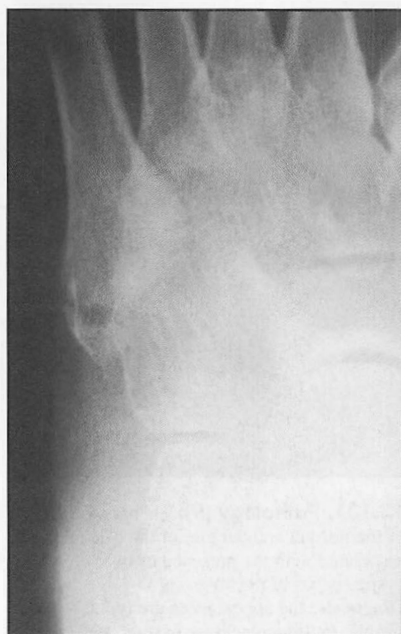13.135. Pathology (13): The first metatarsal is short and medially inclined. The forefoot is broadened. The great toe is tilted laterally, and the head of the first metatarsal is uncovered and prominent. The two phalanges of the great toe are rotated.

Diagnosis: gross hallux valgus deformity associated with a metatarsus primus varus. There is pronation of the great toe, and splaying of the forefoot.



13.136. Pathology (14): There are valgus deformities of all the toes. The MP joints of all the lesser toes are dislocated, and the sesamoid bones are displaced laterally. The bones are somewhat osteoporotic.

Diagnosis: rheumatoid arthritis.



13.137. Pathology (15): There is evidence of a united avulsion fracture of the styloid process of the fifth metatarsal base. There is widespread decalcification and disturbance of bone texture, with clinically marked swelling and stiffness of the foot.

Diagnosis: Sudeck's atrophy (complex regional pain syndrome, post-traumatic osteodystrophy) secondary to local trauma.

INDEX

Note: This index is in letter-by-letter order whereby spaces and hyphens between words are excluded from alphabetization (e.g. De Quervain follows Deltoid muscle). 'Mc' entries have been filed as Mc, not Mac.

A

- Abdominal aorta 293
- Abdominal examination 293
in back pain 154
- Abdominal reflexes, testing 153
- Abductor lurch (Trendelenburg) 186
- Abductor pollicis longus, tenosynovitis 91
- Abscess
Brodie's 246, 251
spinal 137
- Acetabulum
developmental dislocation of hip 166, 167
dysplastic hip 167–168
slope 167–168
- Achilles tendon *see* Tendo calcaneus
- Achondroplasia 104, 141
hand 115
- Acromioclavicular joint 50
degeneration 52
dislocation/subluxation 55–56, 67, 70
osteoarthritis 54
prominent 58
tenderness 59
- Adson's test 41
- Age
back pain and back complaints 145
foot conditions 282
hip pathology 176
shoulder pathology 57
- Aird's test 151
- Allen test 123
- American Shoulder and Elbow Surgeons 57
- Anaesthetic injection 70
- Ankle 255–270
anatomical features 256–257
articular surfaces 266–267
avascular necrosis 268
bony ankylosis 269
Charcot's disease 269
crepitus 267
examination 261–263
inspection 261
footballer's 259, 266, 302
infections 269
instability, functional 257
ligaments 256–257
inferior tibiofibular 256, 257, 262–263
injury 257
inspection 261–262
lateral 257, 261–262, 268
medial 257–258
stress testing 262
tears 261, 262, 268
loose bodies 259
movements 263–264, 265
myotomes 27
osteoarthritis 259, 269
osteocondritis 259
osteocondritis dissecans 268
pain 259, 260
pathology 268–269
radiographs 267–268
rheumatoid arthritis 259
sinus scars 261
soft tissue injury 257
sprains 257, 259
Sudeck's atrophy 268
tenderness 261
tendons
- Achilles tendon *see* Tendo calcaneus
insertional tendinitis 258
rupture 264
snapping peroneal 259, 266
tendinopathy 264
tenosynovitis 258–259, 265–266
tuberculosis 259, 268
- Ankylosing spondylitis
hip 171, 176, 191
investigation 153
knee 212
spine 46, 136, 157, 161
- Annulus fibrosis 130, 131
- Anterior drawer test 228
- Anterior interosseous nerve syndrome 92
- Anterior metatarsalgia 279
- Anterior tibial compartment syndrome 246
- Anterior tibial pulse 292
- Anthrax 114
- Apical infections, finger 114
- Apley's grinding test 234
- Apprehension test
knee 232
patella 235
shoulder 63
- Arches of foot *see* Foot, arches
- Arm, thoracic outlet syndrome 40
- Arthritis
elbow 85
gonococcal *see* Gonococcal arthritis
hand 119
hip 169–170, 176, 197
infective 197
acute pyogenic (hip) 169–170
septic 85
wrist 106
sacroiliac joint 162
wrist 106
see also Osteoarthritis; Rheumatoid arthritis
- Arthrography 215
- Arthroplasty
Charnley low-friction 172, 195
hip *see* Hip replacement
Keller's 278, 279
- Arthroscopy 8, 215
- Aspiration
elbow 87
hip 187
knee 238–239
shoulder 70
wrist 107
- Atlantoaxial joints 44
- Atlantoaxial subluxation 47
- Atlanto-occipital joints 44
- Avascular necrosis 198
ankle 268
femoral head 198
hip 190
Perthes' disease 168
talus 269
wrist fracture 105
- Axillary nerve examination 19
- Calvé's disease 136
different age groups 145
clinical examination 133
coccyx 144
history taking 131–133
age/occupation 131
areas 132–133
motor involvement 132
onset 132
previous history 132
radiation of pain 132
inspection 146–148
mechanical 143–144
movements 149–150
palpation 148
pathology 161–164
prolapsed disc 142
radiography 154–160
spondylolysis and spondylolisthesis 139
- Baker's cysts 203
- Ballotement test 220
- Bamboo spine 157, 161
- Barlow's test 166, 188
- Barré-Lieou syndrome 36
- Batchelor plaster 167
- 'Beat knee' 213
- Bevor's sign 153
- Biceps tendon
instability 56, 64
test 64
integrity of long head 64
ruptured 56
tendinitis 56
- Bladder, neurological control 32
- Bone
cysts 69, 305
scans 8
sclerosis 83
shortening 177–181
tumours 37, 69, 171, 198
giant cell tumour 69
hand 113
hip 171
metastatic 69, 114, 139, 199
tibia 246
vibration syndromes 110
see also specific bones
- Bony sclerosis, elbow 83
- Bouchard's nodes 113
- Boutonnière deformity 112, 116
- Bow leg (genu varum) 212–213, 224–225, 243
- Bowstring test 151
- Brachial artery 74
- Brachial plexus 11–32
axillary 14–15
cervical 12–14
injury 13, 16–17
acute trauma 14, 17
assessment 17–18
complete avulsion 16
cord branches 14
long-standing lesions 17
nerve root branches 13–14, 16
partial avulsion 16
prognostic signs 19
trunk branches 14
types 16
see also specific nerves
- Brodie's abscess 246, 251

B

- Back pain
causes 131

- Bruising 2, 3
 knee 217, 224
 Bunion 277, 287
 Bunnell–Littler test 121
 Bursae
 knee 202, 203–204
 infrapatellar 203
 prepatellar 203
 semimembranosus 203, 236
 suprapatellar 203
 olecranon 76, 80
 subdeltoid 53
 Bursitis
 foot 277
 infrapatellar 213
 knee 213, 217
 olecranon 76, 80
 prepatellar 213, 217
 Butcher's wart 114
 Buttrressing
 hip 193
 spine 158
- C**
- Café-au-lait spots 147
 Caisson disease 68
 Calcaneal exostosis 278
 Calcaneal spur 302, 305
 Calcaneonavicular synostosis 303, 305
 Calcaneus 273
 Calf pain 247
 Callus
 foot 287, 289
 under great toe 287
 soles 279
 toes 277
 Calvé's disease 136, 156, 161
 Cancer *see* Tumours
 Capasso's method 159
 Capsulitis, idiopathic adhesive 53
 Caries sicca 55
 Carpal instabilities 93–94, 105
 assessment 102
 dynamic 93
 static 93
 Carpal tunnel syndrome 92
 examination 96, 99–101, 100
 radiographs 103
 Carpometacarpal joint
 crepitus 122
 osteoarthritis 113
 testing 121, 122
 Catterall classification 169, 192
 Cauda equina syndrome 140
 Cervical myelopathy 41–42
 cord compression 41
 examination 41
 radiography 45
 spondylotic 35
 Cervical osteoarthritis *see* Cervical
 spondylosis
 Cervical rib 35
 syndrome 40–41
 unilateral 47
 Cervical spine 33–48
 ankylosing spondylitis 46
 congenital fusion 46
 crepitus 40
 curvature 45, 47
 deformity 47
 dislocation 46
 unilateral facet 45, 46
 displacement 45, 46
 extension 39
 injury 47
 flexion 39
 injury 43
 lateral 39, 40
 fracture 45, 47
 inspection 38
 instability 43
 lipping, anterior 46
 movements 39–40
 myelopathy *see* Cervical myelopathy
 neoplasms 37
 osteitis 37
 osteoarthritis *see* Cervical spondylosis
 pain 34
 shoulder pain 52, 63
 see also Back pain; Neck pain
 palpation 38
 pathology 45–47
 radiography 42–45
 rheumatoid arthritis 37
 rotation 40
 thoracic outlet syndrome 40–41
 vertebrae 44
 vertical fissure 45
 whiplash 35–36
 Cervical spondylosis 34–35
 examination 38–40, 45–47
 neurological involvement 34
 pain 34
 shoulder 52
 presentation 34
 radiography 46
 treatment 34
 Chair test, elbow 81
 Charcot's disease 241
 ankle 269
 elbow instability 75
 knee 213
 shoulder 70
 Charnley low-friction arthroplasty (LFA)
 172, 195
 Children
 back pain 145
 developmental hip dislocation *see*
 Developmental dislocation of hip
 (DDH)
 elbow radiograph 84
 foot conditions 275–277
 irritable hip 168–169
 scoliosis 148, 160
 Chondroma
 hand 113
 ossifying, shoulder 68
 Chondromalacia patellae 210–211, 234, 240
 Chondromatosis, synovial 241
 Chondrosarcoma 69
 Circulation
 foot 292–293
 testing in back pain 154
 Claudication, neurogenic 141
 Clavicle 50
 deformity 58
 pathology 56
 tenderness 59
 Claw foot *see* Pes cavus (claw foot)
 Claw toe 280, 288
 Clergyman's knee 213, 217
 Club foot 275–276, 276, 283
 radiography 284, 304
 Cobb method 135, 159
 Coccydynia 144, 154
 Coccyx 144
 Collagen abnormality 93
 Collateral ligaments
 elbow 74
 knee 202, 206–207
 Colles' fracture 90
 adverse effect of slings 53
 complications 90, 94–96, 104, 107
 malunion 107
 Compartment syndrome, anterior tibia 246
 Complex regional pain syndrome *see*
 Sudeck's atrophy
 Computed tomography (CT) 7–8
 Congenital abnormalities
 cervical spine, fusion 46
 coxa vara 197
 dislocated hip *see* Developmental
 dislocation of hip (DDH)
 foot 275
 lumbosacral articulation 163
 radioulnar synostosis 84
 scoliosis 133, 156, 157
 synostosis 83
 wrist 104
 Congenital dislocation of hip (CDH) *see*
 Developmental dislocation of hip
 (DDH)
 Conoid ligament, tear 56
 Coracoacromial ligament 52
 Cord compression *see* Spinal cord
 compression
 Corns, toes 288
 Coronoid fossa 74
 Costovertebral joints, ankylosing spondylitis
 136
 Coxa valgus 190
 Coxa vara 170, 190
 congenital 197
 Crepitus 5
 ankle 267
 cervical spine 40
 foot 296
 hip 181
 shoulder 63
 wrist 99
 Cruciate ligaments
 anterior 202, 207–208
 posterior 202–203, 208, 229–230
 radiological analysis 229–231
 visualization 231
 Cubital tunnel 76
 Cubitus valgus 75, 82
 Cubitus varus 75, 82
 Cuneiform exostosis 278
 Curly toe 280, 288, 290
 Cutaneous nerve, lateral 32
 Cyanosis, foot 293
 Cysts
 Baker's 203
 bone 69, 305
 implantation dermoid 113
 menisci 209, 217, 234
 mucous 113

D

- Deltoid muscle
 power 65
 shoulder abduction 51
 wasting 58
- De Quervain's disease 91, 99
 wrist examination 95, 96, 99
- Dermatomes examination 16, 28
- Dermoid cysts, implantation (hand) 113
- Developmental dislocation of hip (DDH)
 166
 adults 167
 examination 188–189
 high-risk groups 166
 late-diagnosed 166
 older children 167, 188, 189
 radiography 194, 196, 197
 screening 166
 splints 166
 treatment principles 167
- Diabetes mellitus, flexion of fingers 117
- Diaphyseal aclasis 217, 239
 tibia 251
- Diffuse idiopathic skeletal hyperostosis
 (DISH; Forestier's disease) 46,
 136–137
- Digital (plantar) neuroma 280, 294, 295
- Disc prolapse *see* Prolapsed intervertebral disc (PID)
- Discs *see* Intervertebral disc
- DISH (diffuse idiopathic skeletal hyperostosis, Forestier's disease) 46, 136–137
- Dislocation/subluxation
 cervical spine 45, 46
 hip replacement and 172
 patella 210, 240
 recurrent 238
 shoulder
 acromioclavicular joint 55–56, 67, 70
 recurrent 54–55, 69
 sternoclavicular joint 57
 see also under Shoulder
 talonavicular joint 302
 tibial condylar 208, 231
 see also Developmental dislocation of hip (DDH)
- Disposable sharp point 9
- Dorsalis pedis artery 292
- Dorsiflexion–eversion test (tarsal tunnel syndrome) 295
- Down's syndrome 115
- Drawer sign, of Gerber and Ganz 63
- Drawer test
 glenohumeral instability 64
 suspected plantar neuroma 295
- Drop foot 264
- Duchenne sign 186
- Dupuytren's contracture
 foot 289
 hand 110, 117, 118
- Dysplasia, hip 167–168

E

- Edinburgh method 188
- Effusion, knee 204, 219–221

- Egyptian foot 275
- Ehlers–Danlos syndrome 93
 elbow instability 75
 knee hypertension 223
 wrist hypermobility 97
- Elbow 73–88
 anatomical features 74–75
 aspiration 87
 assessment
 carrying angle 78
 functional 57, 58–71
 movements 79–80
 neurological 17
 bony sclerosis 83
 displacement 85
 extension 79
 flexion 79
 fracture 83, 85, 86
 function 75
 golfer's *see* Golfer's elbow
 gunshot wound 85
 gunstock deformity 78
 hyperextension 79
 inspection 78
 instability 74, 75, 82
 joint space narrowing 83
 loose bodies 76–77, 83, 86, 87
 myositis ossificans 77, 83, 84
 myotomes 15
 osteoarthritis 76–77, 86
 osteochondritis 87
 osteochondritis dissecans 76–77
 palpation 80–81
 pathology 84–87
 pronation/supination 74, 79–80
 pulled 76
 radiography 82–84, 83–87
 rheumatoid arthritis 77
 septic infective arthritis 85
 swelling 78
 tennis *see* Tennis elbow
 tuberculosis 77, 86
- Elderly patients
 back pain 145
 hip pain 171
- Elson's middle slip test 124
- Enchondroma, hand 118, 126
- Eosinophilic granuloma 161
- Epiphysis, spine 160
- Episodic blanching 110
- Equipment, examination requirements 8–9
- Erb's (upper obstetrical) palsy (E) 14, 17
- Erysipeloid 114
- Erythrocyte sedimentation rate (ESR), assessment 154
- Ewing's tumour 253
- Examination principles 1–10
 further investigations 7–9
 inspection *see* Inspection
 movements *see* Movements
 palpation 3–4
 radiographic examination 6–7
 special tests 6
 see also Joint examination; Neurological assessment; Radiography; individual joints/regions
- Exostoses 278
 radiography 6
- shoulder crepitus 63
 snapping scapula 56
 subungual 296
 tailor's 286
- Extensor digitorum communis, injury 124
- Extensor pollicis brevis 91
- Extensor pollicis longus 124
- Extensor tenosynovitis 91
- External rotation recurvatum test 232

F

- Falls, neck extension injuries 36
- Fasciitis, plantar 280, 293, 305
- Fat pad injury, knee 211
- Feagin and Cooke test 228
- Feet *see* Foot
- Femoral epiphysis
 displacement 198
 Perthes' disease 168–169
 slipped 170, 193, 198
- Femoral fracture, hip replacement 173
- Femoral head
 avascular necrosis 198
 DDH *see* Developmental dislocation of hip (DDH)
 dysplastic hip 167–168
 epiphysis *see* Femoral epiphysis
 radiography 190
- Femoral neck
 anteversion 185
 neck-shaft angle 191
 osteoid osteoma 198
- Femoral nerve 29
- Femoral pulse 293
- Femoral shaft, Ewing's tumour 253
- Fibula
 bone destruction 253
 bone formation 253
 myositis ossificans 253
 osteitis 252
 osteoclastoma 253
- Finger(s)
 Boutonnière deformity 112, 116
 congenital contraction 117
 dermatomes 16
 examination 116–117
 flexion 110
 and contractures 110, 117
 grip, testing 125
 hypertrophy 115
 mallet 111, 115
 movements 119, 120
 abduction 123
 myotomes 15, 16
 neurological assessment 17
 spindling 114
 swan-neck deformity 116
 trigger 112
 ulnar deviation 118
 see also Hand; Thumb; specific joints
- Fixed flexion deformity 4, 177
- Flat foot (pes planus) 276, 282, 291, 299–300, 303
 adult 279
 peroneal (spastic) 278
 shoe wear 299, 300
- Flexor pollicis longus 124

Flexor retinaculum, division 92
 Flip test 151
 Fluid displacement test 220
 Fluorodeoxyglucose (FDG)-positron emission tomography 8
 Foot 271–306
 adolescent conditions 277–278
 adult conditions 278–281
 anatomical features 272–275
 anterior metatarsalgia 279
 appearance 285
 arches 274
 abnormally high 276–277
 anterior 274
 flat foot 276
 flattening in adults 279
 formation 276
 lateral longitudinal 274
 medial 274, 290–291
 transverse 274
 bone cyst 305
 calcaneal spur 302, 305
 calcaneonavicular synostosis 303, 305
 childhood conditions 275–277
 circulation 292–293
 claw foot *see* Pes cavus (claw foot)
 club foot *see* Club foot
 congenital abnormality 275
 crepitus 296
 cyanosis 293
 diagnosis of complaints 281, 282
 diminution of sensation 153, 295
 dorsal inspection 95, 286
 drop 264
 eversion 290
 examination stages 285
 exostoses 278, 286
 flat *see* Flat foot
 Freiberg's disease 280, 287, 304, 305
 gait 285, 292
 genu valgum (knock knee) and 290
 gout 281, 296
 heel *see* Heel
 infections 281, 306
 inspection 286–289
 intoeing 276, 289
 inversion 272, 290
 investigations 285
 Kohler's disease 277, 301, 304
 March fracture 280, 294, 305
 Marfan's disease 286
 midtarsal joint 273
 movements 285, 297–299
 planes 272
 supination and pronation 297
 neuroma 280, 294, 295
 osteoarthritis 302
 pain, differential diagnosis 282
 palpation 285
 plantar fasciitis 280, 293, 305
 plantigrade 289
 posture 285, 289–292
 radiographs 284, 300–306
 rheumatoid arthritis 281, 294, 301, 302, 306
 sesamoiditis 296
 Sever's disease 277, 302, 304
 shoes 299–300
 skew foot 276

sole
 inspection 288, 289
 sensory loss 295
 splay foot 279, 290, 300
 subtalar movements 272–273
 subungual exostosis 296
 Sudeck's atrophy 306
 talocalcaneal synostosis 305
 tarsal tunnel syndrome 281, 295–296
 tarsometatarsal movements 273
 temperature 292
 tenderness 293–294, 296
 tendons 275
 tripod action 272
 trophic ulceration 288
 verruca pedis (plantar wart) 280, 289
see also Toe(s)
 Footballer's ankle 259, 266, 302
 Foot print 299
 Forefoot
 pain 282
 tenderness 294
 Forestier's disease 46, 136–137
 Fowler's operation 280
 Fracture(s)
 cervical spine 45, 47
 Colles' *see* Colles' fracture
 elbow 83, 85, 86
 femur 173
 malunion 107
 March 280, 294, 305
 olecranon 85
 osteochondral 259
 patella 205
 scaphoid 105
 shoulder 69
 spine 141, 161
 stress *see* Stress fracture
 styloid process of radius 106
 thumb 127
 tibia 246–247, 251, 252
 uncovertebral joints 36
 vertebral bodies 36, 137
 wrist 105, 106
 Colles' *see* Colles' fracture
 differential diagnosis 96
 Freiberg's disease 280, 287, 294, 305
 radiography 301, 305
 Frölich syndrome 170
 Frozen shoulder 53

G

Gage's sign 199
 Gait 5, 177
 examination 292
 foot 285, 292
 inspection 177
 intoeing (hen-toed) 276, 289
 shuffling 177
 stomping 177
 waddling 189
 Gamekeeper's thumb 121, 127
 Ganglia 90–91
 hand 113, 118
 inspection 95
 Genu recurvatum 213, 223, 239

Genu valgum (knock knee) 213, 224, 234
 valgus flat foot with 290
 Genu varum (bow leg) 212–213, 224–225, 243
 Gerber and Ganz, drawer sign 63
 Giant cell tumour, of bone 69
 Gibbus 135, 146
 Glenohumeral joint 50
 instability 63–64
 osteoarthritis 54, 68
 shoulder abduction 51
 Glomus tumours, hand 113
 Gluteal muscles, testing 187
 Golfer's elbow 75
 examination 82
 palpation 80
 Goniometer 9
 Gonococcal arthritis 55, 58
 knee 205
 Gout 281, 296
 great toe tenderness 296
 Grasping, testing 125
 Gravity test, posterior tibial instability 229
 Great toe
 callus under 287
 hallux valgus *see* Hallux valgus
 infections 280
 inspection 286, 287
 movements 298
 nails 280
 inspection 287
 pain 282
 pronation 306
 tenderness 296
 see also Hallux rigidus; Hallux valgus
 Greek foot 275
 Grip, testing 125
 strength testing 126
 Gunshot wound 85
 Gunstock deformity 78
 elbow 78

H

Haemarthrosis, knee 204, 221, 226
 Hagland deformity 264
 Hallux flexus 279, 287
 Hallux rigidus 278–279, 287
 crepitus 296
 movement limitation 298
 radiography 301, 306
 shoe wear 300
 Hallux valgus 277–278, 294, 303, 304
 inspection 286
 radiography 301, 306
 shoe wear 300
 tenderness 296
 Hammer toe 280, 288
 Hand 109–128
 arthritis 119
 Bouchard's nodes 113
 Boutonnière deformity 112, 116
 cervical myelopathy and 42
 chondroma 113
 circulation test 123
 Dupuytren's contracture 110, 118
 enchondroma 118

Hand (*contd.*)

- functional assessment 125–126
- flexion examination 116–117
- ganglions 113, 118
- hypertrophy 115
- implantation dermoid cysts 113
- infections 114, 124–125, 126
- inspection 115–118
- ischaemic contractures 117
- joint instability 127
- joint thickening/swelling 123
- movements 119–123
- mucous cysts 113
- osteoarthritis 113, 118, 127
- osteoid osteoma 113
- palpation 119
- paraesthesia 92
- pathology 126–127
- radiography 126–127
- rheumatoid arthritis 112–113
- swan-neck deformity 116
- swelling 115
- swellings 118
- tendon injury 111–112, 123–124
 - extensor division/rupture 112, 116
 - profundus division 112, 123
 - sheath lesions 111–112
- thoracic outlet syndrome 40
- tumours 113–114, 118, 126
 - metastatic 114
- vibration syndromes 110–111, 123
- Volkman's ischaemic contracture 117
- Z deformity 116
- see also* Finger(s); Thumb

Harris system 174

Heberden's nodes 113, 118, 127

Heel

- eversion 297
- examination 291
- inspection 286
- inversion 272, 290, 297
- pain 282
- posture 273–274, 291–292
- tenderness 293

Hemivertebra 164

Herring lateral pillar classification, Perthes' disease 192

Hip 165–200

- abduction 183
- adduction 184
- age distribution of common pathology 176
- ankylosing spondylitis 171, 176, 191
- anteversion of femoral neck 185
- arthritis 169–170, 176, 197
- aspiration 187
- assessment 174–176
 - activity level 175
 - inspection 177
 - scoring system 174–176
 - shoes/socks 175
 - sitting to standing 175
 - stairs 175
- avascular necrosis 190
- bony ankylosis 191
- congenital dislocation *see* Developmental dislocation of hip (DDH)
- considerations 171–172
- crepitus 181

developmental dislocation *see*

Developmental dislocation of hip (DDH)

- dysplasia 167–168
- examination 178–181
 - in knee pain 236
- extension 182
- flexion 182–183
- flexion contracture 172
- fusion testing 186
- infections 169–170
- irritable 168–169
- joint space, decreased/increased 191
- movements 182–186
 - in suspected prolapsed disc 150
- myotomes 27
- neck-shaft angle 191
- osteoarthritis 170–171, 176, 181, 191, 199
 - primary 170
 - secondary 170–171
- osteoid osteoma 198
- pain 171, 174
- palpation 181
- pathology 195–200
- pyogenic arthritis 169–170
- radiography 188, 189–190, 194–199
- Reiter's syndrome 171, 176
- replacement *see* Hip replacement
- rheumatoid arthritis 171–172, 176
- rotation 184–185
- shortening 177–181
- slipped femoral epiphysis 170, 193, 198
- snapping 171
- tuberculosis 169, 176
- tumours 171, 176
- walking capacity 175–176
- work level 174–175

Hip replacement 195–196

- complications 172–174
 - component failure 172–173, 195
 - dislocation 172
 - femur fracture 173
 - loosening and infection 173–174, 195

Histamine test 18

Hoffmann's test 41

Horner's syndrome 14, 17

Housemaid's knee 213, 217

Hurler's syndrome 115

Hyperhidrosis, sole of foot 288

Hypermobility, testing 97

wrist 97

Hyperparathyroidism 197

Hypothenar wasting, unilateral 118

I

Iliopsoas

- snapping hip 171
- strains 181

Iliotibial tract, snapping hip 171

Imaging techniques 7–8

functional 8

see also specific techniques

Implantation dermoid cysts 113

Infection(s)

- ankle 269
- apical, hand 114
- arthritis 197

foot 281, 306

great toe 280

hand 114, 124–125, 126

sites 114

hip 169–170

knee 204–205, 215, 242

midpalmar 114, 125

occupational 114

shoulder 55, 70, 71

tibia 251

web space 114, 125

wrist 93, 106

see also specific infections

Infrapatellar bursitis 213

Infraspinatus, testing 65

Inspection 2

ankle 261

back pain/spine 146–148

cervical spine 38

elbow 78

foot 286–289

hand 115–118

hip 177

knee extensor mechanism 219

quadriceps 218

shoulder 58

tibia 249

wrist 94–95

Interphalangeal joints

flexion, assessment 117

movements 119, 120, 121

osteoarthritis 113

Interspinous ligaments, calcification 161

Intertarsal angle 304

Intervertebral disc 130, 131

calcification 163

high, lesions 152

lipping in disc lesions 156

prolapsed *see* Prolapsed intervertebral disc

(PID)

protrusions 131

radiography 155

'slipped' 131

Intoeing 276, 289

Ischial tuberosity, palpation 181

J

Jakob's reversed pivot shift test 232

Jerk test 231

shoulder 64

Joint examination 1–7

bruising 2, 3

crepitus 5

discoloration 2

equipment 8–9

further investigations, arrangement 7–9

inspection 2

motor/sensory levels scale 6

movement range 4–5, 5

abnormal planes 5

active/passive 4

restriction 4

trick 4

oedema 2, 3

palpation 3–4

shape/posture alteration 2, 3

special tests 6

swelling 2, 3
 temperature change 3, 4
 tenderness 4
see also individual joints
 Joint hypermobility 97
 Jumper's knee 235

K

Keller's arthroplasty 278, 279
 Kienbock's disease 91, 105
 'Kissing spines' 140, 156
 Klippel-Feil syndrome 37, 42, 52
 Klumpke's (lower obstetrical) palsy (K) 14, 17
 Knee 201–244
 alignment disturbance 212–213
 anatomical features 202–204
 ankylosing spondylitis 212
 anterior drawer test 228
 anterior pain syndromes 210–211
 articular surfaces
 affections 212
 inspection 236
 aspiration 238–239
 bony erosions 216
 bruising 217, 224
 bursae 202, 203–204
 bursitis 213, 217
 clergyman's 213, 217
 diagnosis of complaints 213–216
 age/sex 213–214, 214
 discoloration 217
 effusions 204, 219–221
 synovitis 204
 examination 219–222
 extension 222–223
 extensor mechanism 205–206, 222–223
 examination 219
 loss of full extension 205
 weakness 205
 fat pad injury 211
 flexion 223
 genu recurvatum 213
 genu valgum (knock knee) 213, 224, 234, 290
 genu varum (bow leg) 212–213, 224–225
 'giving way' 214
 gonococcal arthritis 205
 haemarthrosis 204, 221, 226
 history taking 214
 housemaid's 213, 217
 hyperextension 213, 223
 infections 204–205, 215, 242
 inspection 217–218
 instability 225
 rotatory 208, 225, 228
 valgus stress 225–227
 varus stress 227–228
 internal derangement 215
 investigations 215–216
 joint capsule 206–207
 jumper's 235
 ligaments 202–203, 206
 cruciate *see* Cruciate ligaments
 examination 222, 229–231
 injuries, terminology 206
 lateral 202, 207

 medial 202, 206–207
 posterior 203
 radiological analysis 229–231
 rupture 241
 tenderness 222
 locking 214
 loose bodies 211, 241
 lumps 217
 mechanical problems 214
 meniscus *see* Meniscus of knee
 movements 222–224
 myotomes 27
 osteoarthritis 212, 237, 240, 241, 242
 osteocondritis dissecans 211, 222, 240
 osteogenic sarcoma 242
 pain 215, 216, 235, 236
 patella *see* Patella
 pathology 239–243
 popliteal region, inspection 236
 provocative exercises 214
 pseudogout 242
 pyarthrosis 204–205, 221
 radiography 229–230, 236–243
 Reiter's syndrome 212
 retropatellar syndromes 210–211
 rheumatoid arthritis 212, 215–216, 242
 rickets 243
 sinus scars 217
 skin marks 217
 swelling 204, 214, 217
 synovial membrane inspection 221
 temperature 217–218
 tenderness 221–222
 tibia vara 243
 tuberculosis 205, 215, 242
 Knock knee (genu valgum) 213, 224, 234, 290
 Kohler's disease 304
 foot 277, 301, 304
 radiography 304
 Kyphosis 135, 155
 angular 135, 155, 161
 assessment 159
 causes 146
 inspection 146
 senile 137, 146, 155, 164
 tibial 247

L

Lachman test 229
 active 228
 prone 228
 Lateral tomography 8
 Leg *see* Lower limbs
 L'hermitte's test 42
 Ligaments
 in Ehlers-Danlos syndrome 93
 see also individual ligaments
 Limbs
 lower *see* Lower limbs
 pain 248
 segmental and peripheral nerves 11–32, 12, 13, 19
 upper, thoracic outlet syndrome 40
 Long thoracic nerve 65
 Loose bodies
 ankle 259

 elbow 76–77, 83, 86, 87
 knee 211, 241
 Looser's zones 242
 'Loose shoulder' 54
 Losee pivot shift test 231
 Lower limbs
 examination 250
 inspection 249
 pain 246–247
 causes 247, 248
 posterior aspect 247
 ruptured plantaris tendon 247
 thrombophlebitis 247
 peripheral nerves 28
 shortening 177–181
 apparent 178
 true 177–178, 181
 see also Tibia
 Lumbar spine 129–164
 angular curvature 155
 ankylosing spondylitis 136
 arthritis 140
 Calvé's disease 136, 156, 161
 curvature 133, 146
 see also Scoliosis
 disc calcification 155
 disc prolapse 141–142
 see also Prolapsed intervertebral disc (PID)
 DISH (diffuse idiopathic skeletal hyperostosis) 46, 136–137
 flattening 146
 flexion 149–150
 inspection 146
 lordosis
 increased 135, 177
 loss 135, 146
 movements 131
 Paget's disease 137
 pyogenic osteitis 138–139
 radiography 156
 rotation 150
 spina bifida *see* Spina bifida
 spondylolisthesis 139–140, 156, 158, 162
 complications 141
 spondylolysis 139–140, 159
 tuberculosis *see* Tuberculosis (TB)
 see also Back pain; *specific conditions*
 Lumbosacral articulation 163
 congenital abnormality 163
 radiography 157
 Lunate, spontaneous avascular necrosis *see* Kienbock's disease
 Lunotriquetral instability 102

M

Madelung's deformity 90, 105
 Magnetic resonance imaging (MRI) 8
 knee investigation 215
 neurological assessment 18
 Malignant pustule (anthrax) 114
 Mallet finger/thumb 111, 115
 Mallet toe 280, 288
 March fracture 280, 294, 305
 Marfan's disease 97
 fingers 115
 foot 286

- McKenzie's sign 261
 McMurray manoeuvre 233
 McMurray's osteotomy, hip 171
 'Medial foot strain' 279
 Medial tibial syndrome (shin splints) 247
 Median nerve 13, 14, 74
 compression 106
 proximal to wrist 92
 testing 99, 100
 wrist 92
 elbow 74
 examination 25–27
 motor division, testing 100
 sensory distribution 24
 Medical Research Council (MRC)
 motor/sensory levels scale 6
 muscle contraction scale 5
 Meniscus of knee 202, 203
 bucket-handle tears 209
 clicks 233
 congenital discoid 208
 cysts 209, 217, 234
 degenerative lesions in adults 209
 examination 232–234
 lesions 208–209, 233
 tears in young adults 209
 Metacarpophalangeal joint
 movements 119, 121
 nodular thickening 117
 stability testing 121
 Metaphyseal aclasis 239
 Metastatic bone disease 69
 hand 114
 hip 199
 spine 139
 Metatarsal(s)
 base, fifth 278
 head, fifth 278
 Metatarsal articular angle 304
 Metatarsalgia
 anterior 279
 Morton's 280, 294
 Metatarsophalangeal joint
 osteoarthritis 278–279
 silicone replacement 278
 Methylene diphosphonate, technetium tagged 8
 Midcarpal instability 102
 Midpalmar infections 114, 125
 Midtarsal joint 273
 Milwaukee brace 134, 135
 Mitchell operation 278
 Monteggia fracture dislocation of elbow 86
 Morquio–Brailsford's disease 97
 Morton's metatarsalgia 280, 294
 Motor distributions
 femoral nerve 29
 peroneal nerve, common (lateral popliteal) 29
 radial nerve 19
 sciatic nerve 31
 tibial nerve (medial popliteal) 30
 ulnar nerve 21
 Motor involvement
 back pain 132
 joint examination 6
 sciatic nerve lesions 31
 thoracic motor root dysfunction 153
 Movements
 ankle 263–264
 assessment 4–5
 back pain 149–150
 cervical spine 39–40
 elbow 79–80
 foot 285, 297–299
 hand 119–123
 hip 182–186
 knee 222–224
 range 4
 shoulder 59–62
 wrist 96
 see also individual joints
 Mucous cysts 113
 Mulder's sign 294
 Muscle
 contraction strength 5
 wasting 2, 3
 Myositis ossificans 196
 elbow 77, 83, 84
 tibia 253
 Myotomes
 ankle 27
 elbow 15
 examination 15–16, 27
 fingers 15, 16
 hip 27
 knee 27
 shoulder 15
 wrist 15
 Myxoedema, hand 115
- ## N
- Nails
 examination 118
 great toe 281
 Neck, extension injuries 35–36
 Neck pain 34
 acute in young adults 34
 extension injuries 35–36
 radiography 43
 severe 36
 postural 34
 see also Cervical spine
 Neer impingement sign 63
 Neer impingement test 63
 Neonatal instability of hip (NIH) 166, 187
 Neoplasms *see* Tumours
 Nerve(s)
 lateral 13, 14, 32
 lesions 16, 17
 medial 13
 peripheral 11–32
 lower limbs 28
 posterior 13, 14–15
 segmental 11–32
 distribution 15
 thoracic, long 65
 see also Brachial plexus; individual nerves
 Nerve roots 13–14
 Neurofibromatosis 147
 Neurological assessment 11–32
 bladder control 32
 determination of injury type 17, 18
 prolapsed intervertebral disc (PID) 142
 radiography 18
 sensory loss 18
 thoracic outlet syndrome 41
 see also Brachial plexus; individual nerves; specific joints
 Nucleus pulposus 130, 131
 herniation 135
 protrusion 141
- ## O
- Occupational infection, hand 114
 O'Donoghue's triad 207
 Olecranon, fracture 85
 Olecranon bursitis 76, 80
 Olecranon fossa 74
 Ollier's disease 113, 126
 Onychogryphosis 280
 Ortolani's test 166, 187
 Os fibulare 267
 Osgood–Schlatter's disease 205–206, 240, 251
 tibial tenderness 250
 Ossification, wrist 104
 see also Myositis ossificans
 Osteitis
 cervical spine 37
 pyogenic, lumbar spine 138–139
 Staphylococcal infection 55
 tibia 246, 252, 253
 wrist 106
 Osteoarthritis
 ankle 259, 269
 complications 141
 elbow 76–77, 86, 87
 palpation 81
 foot 302
 hand 113, 118, 127
 hip 170–171, 176, 181, 191, 199
 knee 212, 237, 240, 241, 242
 metatarsophalangeal joint 278–279
 shoulder 54, 68
 spine 140, 156, 157, 163
 cervical *see* Cervical spondylosis
 thumb 113
 wrist 91, 105
 Osteochondral fracture 259
 Osteochondritis
 ankle 259
 elbow 87
 metatarsal head 280
 talus 266
 Osteochondritis dissecans 259
 ankle 268
 elbow 76–77, 83, 86, 87
 knee 211, 222, 240
 palpation 81
 Osteochondritis tali 267
 Osteochondrosis, spine (Scheuermann's disease) 135–136, 155, 161
 Osteoclastoma
 shoulder 69
 tibia 253
 Osteogenesis imperfecta 97
 Osteogenic sarcoma 242
 Osteoid osteoma 113, 171
 hand 171
 hip 198
 pedicle, back pain 134

Osteonecrosis *see* Avascular necrosis
 Osteophytes
 cervical, avulsion 36
 cervical spondylosis 35
 uncovertebral joints 45
 Osteotomy, McMurray's 171

P

Paget's disease 156, 163, 191, 198
 complications 141
 spine 137
 tibia 251, 252
 Pain
 ankle 260
 back *see* Back pain
 complex regional pain syndrome *see*
 Sudeck's atrophy
 foot 282
 forefoot 282
 great toe 282
 heel 282
 hip 171, 174
 knee 215, 216, 235, 236
 limbs 248
 lower limbs *see* Lower limbs
 neck *see* Neck pain
 sciatic 142
 shoulder *see* Shoulder, pain
 Palmar fascia, thickening 110
 Palmar grasp, testing 125
 Palpable fluid wave test 221
 Palpation 3–4
 back pain 148
 cervical spine 38
 elbow 80–81
 foot 285
 hand 119
 hip 181
 shoulder 58–59
 wrist 95–96
 Palsy, ulnar nerve 75–76
 Paraesthesia, hand 92
 Paraplegia, metastatic lesions of spine 139
 Paratendinitis 258
 Achilles 258
 Paronychia 114, 124
 Pars interarticularis 158
 Patella
 bipartite 239
 chondromalacia 210–211
 dislocation 210, 240
 congenital 210
 recurrent 238
 examination 234–235
 fractures 205
 instability 209–210
 movement 235
 pathology 239–241
 retropatellar syndromes 210–211
 tenderness 235
 Patella alta 213, 239
 Patellar ligament
 rupture 205
 tenderness 222
 Patella tap test 220
 Patellofemoral angle 238
 Patellofemoral instability 209–210

Patrick's test 183
 Pavlov ratio 45
 Pellegrini–Steida disease 207, 237, 242
 Pelvic tilting 178
 Pelvis, triradiate 196
 Peroneal nerve, common (lateral popliteal)
 264
 deformity 30
 motor/sensory distributions 29
 tests 30
 Peroneal tendon, snapping 259, 266
 Perthes' disease 168–169, 190–192, 198–199
 age effects 176
 classification 169
 treatment aims 169
 Pes cavus (claw foot) 276–277, 282, 291,
 293, 300
 radiography 304
 shoe wear 300
 Pes planus *see* Flat foot
 Phalen's test 100
 Pharyngeal shadow displacement 43
 Pilonidal sinus 114
 Pinch grip 125
 Pin prick test 27
 Pivot shift test 231
 Jakob's reversed 232
 Plantar fasciitis 280, 293, 305
 Plantaris tendon, ruptured 247, 250
 Plantar (digital) neuroma 280, 294, 295
 Plantar wart 280, 289
 Popliteal artery 293
 Popliteal nerve, lateral *see* Peroneal nerve,
 common (lateral popliteal)
 Popliteal region, examination 236
 Positron emission tomography (PET) 8
 Posterior tibial artery 293
 Posterolateral drawer test 231
 Post-traumatic osteodystrophy *see* Sudeck's
 atrophy
 Posture 2
 examination 289–292
 foot problems and 285, 289–292
 heel 273–274, 291–292
 neck pain 34
 scoliosis 133
 Prepatellar bursitis 213, 217
 Prolapsed intervertebral disc (PID)
 141–143, 162, 164
 contained 141
 differential diagnosis 143
 hip pain 176
 investigations 150–153, 160
 lumbar spine 141–142
 neurological disturbance 142
 pain 142
 palpation 148
 radiography 155
 sequestered 141
 thoracic spine 142
 treatment 142–143
 see also Vertebrae
 Prostate carcinoma 69
 Protrusio acetabuli 199
 Proximal phalangeal articular angle 304
 Pseudarthrosis, tibia 247–248, 251
 Pseudogout 242
 Psoas spasm 172
 Psoriasis, toe nail growth 280

Pulled elbow 76
 Pulp infections 114, 124
 Pulses
 checking in back pain 154
 femoral 293
 foot 292
 Pyarthrosis 204–205, 221
 Pyogenic arthritis 169–170
 sacroiliac joint 162
 Pyogenic osteitis 138–139

Q

Q angle 224, 234
 finding 235
 Quadriceps
 examination 218
 ligament/tendon rupture 205
 tenderness 222
 tendinitis 206
 wasting 205, 207
 weakness 153
 Quadriceps angle *see* Q angle
 Quinti varus deformity 288

R

Radial nerve 74
 examination 20–21
 motor distribution 19
 sensory distribution 20
 Radiocarpal joint 99
 Radiography
 additional 7
 ankle 267–268
 AP and lateral tomography 8
 back pain 154–160
 cervical spine 42–45
 comparison films 7
 elbow 82–84, 83–87
 examination 6–7
 foot 284, 300–306
 frog lateral projection (Loewenstein) 192
 hand 126–127
 hip 188, 189–190, 194–199
 knee 229–230, 236–243
 localized views 7
 neurological assessment 18
 oblique projections 7
 shoulder 66–68
 stress films 7
 tibia 251–253
 wrist 102–107
 Radionecrosis 54, 68
 Radioulnar joint
 congenital synostosis 84
 crepitus 99
 laxity, distal 101
 Radius, styloid process, fracture 106
 Rectangular foot 275
 Reiter's syndrome
 hip 171, 176
 knee 212
 Relocation test, glenohumeral instability 63
 Retropatellar syndromes 210
 osteoarthritis 240
 Retrospondylolisthesis 156

Reverse Lasegue test 152
 Rheumatoid arthritis (RA)
 ankle 259
 cervical spine 37, 43, 47
 elbow 75, 77
 foot 281, 294, 301, 302, 306
 hand 112–113, 118
 hip 171–172, 176
 knee 212, 215–216, 242
 shoulder 54
 spine 140
 wrist 91–92, 96
 Rheumatoid nodules, hand 118
 Rhomboids 18
 Rib hump 147
 Rickets 191, 225, 251, 252
 knee 243
 wrist 105
 Risser jacket 135
 Risser's sign 160
 Romanus lesions 156
 Roos test 41
 Rotator cuff 51
 arthropathy 53
 calcification 66
 compression 52
 examination 63
 tears 52–53, 60

S

Sacroiliac joint
 ankylosing spondylitis 136
 investigation 153–154
 pyogenic arthritis 162
 tenderness over 148
 'Sagging rope' sign 199
 Salter-Thompson classification 169
 Sarcoma, osteogenic, knee 242
 Scaphoid
 examination 96
 fracture 105
 Scapholunate instability 93, 102
 Scapula 50, 58
 high 56
 movement 50
 neurological assessment 18
 pathology 56
 shoulder abduction 51
 snapping 56
 winged 56
 Scapulothoracic joint 50
 Scheuermann's disease 135–136, 155, 161
 Schmorl's nodes 131, 135, 142, 155, 156, 161
 Schöber's method 149
 modified 149
 Sciatic nerve 31
 Sciatic pain 142
 Scoliosis 133–135, 147, 177
 compensatory 133
 congenital 133, 156, 157
 curve assessment 159
 development 134
 idiopathic 134, 148, 161
 infantile 148, 160
 inspection 147
 investigations 134
 metabolic 133
 neuropathic 133
 non-structural 133
 paralytic 133
 postural 133
 primary and secondary curves 134
 prognosis 134
 radiography 157
 sciatic 133
 structural 133, 147, 164
 treatment 134–135
 Screening tests
 developmental dislocation of hip (DDH)
 166
 tibia 250
 wrist 96
 Semimembranosus bursae 203, 236
 Senile kyphosis 137, 146, 155, 164
 Sensory conductance 18
 Sensory distributions
 femoral nerve 29
 median nerve 24
 peroneal nerve, common (lateral popliteal)
 29
 radial nerve 20
 tibial nerve (medial popliteal) 30
 ulnar nerve 21
 Sensory disturbance
 joint examination 6
 neurological assessment 18
 sciatic nerve 31
 Sesamoiditis 296
 Sever's disease 277, 293, 302, 304
 radiography 302, 304
 Sharp point, disposable 9
 Shenton's line 190
 Shin splints 247
 Shoes 299–300
 Shoulder 49–72
 abduction 51, 59–60
 acromioclavicular dislocation 55–56
 adduction 60, 61
 age related to injury 57
 anaesthetic injection 70
 anatomy 50
 aspiration 70
 biceps tendon 56
 caisson disease 68
 calcifying supraspinatus tendinitis 53–54,
 68
 cervical spine and
 cervical spondylosis 52
 examination 63
 Charcot's disease 70
 chondrosarcoma 69
 clavicle and 56
 coracoacromial ligament 52
 crepitus 63
 dislocation
 anterior 54–55
 posterior 55
 radiography 67
 recurrent 54–55, 67, 69
 sternoclavicular joint 57
 drooping 35
 elevation/depression 62
 enchondroma 68
 extension 61, 62
 flexion 61
 fracture 69
 'frozen' 53
 functional assessment 57, 58–71
 idiopathic adhesive capsulitis 53
 impingement syndrome 52
 infections 55, 70, 71
 inspection 58
 instabilities 54–55
 loose 54
 mechanical problems 71
 metastatic prostate carcinoma 69
 movements 59–62
 myotomes 15
 neurological assessment 17
 ossifying chondroma 68
 osteoarthritis 54, 68
 osteoclastoma 69
 pain 52, 63
 arc syndromes 71
 dislocation 55
 palpation 58–59
 pathology 68–70
 common 52
 radiography 66–68
 radionecrosis 54, 68
 rheumatoid arthritis 54
 rotation 50, 61–62
 rotator cuff *see* Rotator cuff
 scapula *see* Scapula
 special investigations 70
 Sprengel's 37, 58
 subacromial joint 52
 swelling 58
 tuberculosis 55, 70
 Silicone granuloma 278
 Simian stance 146
 Sinding–Larsen–Johansson syndrome 205,
 222, 235
 Single-photon emission controlled
 tomography (SPECT) 8
 Sinus scars
 ankle 261
 knee 217
 Skew foot 276
 Skin
 knee marks 217
 nutrition examination 118
 Slipped femoral epiphysis 170, 193, 198
 Snapping joints
 ankle 259, 266
 hip 171
 scapula/shoulder 56
 Soft tissue
 injuries of ankle 257
 inspection, leg 249
 Soles of feet *see* Foot, sole
 Southwick's method 193
 SPECT 8
 Speed test 64
 Spina bifida 140–141, 156, 157
 inspection 147
 Klippel–Feil syndrome 56
 Spina bifida occulta 141, 164
 Spinal canal, stenosis *see* Spinal stenosis
 Spinal cord 12
 Spinal cord compression
 cauda equina syndrome 140
 cervical myelopathy 41
 thoracic 153, 154
 tuberculosis (TB) 137–138

Spinal nerve roots 13–14
 Spinal nerves, segmental 12
 Spinal stenosis 141, 146
 cervical 35
 differential diagnosis 143
 Spine
 age-related complaints 145
 anatomical features 130–131
 ankylosing spondylitis 46, 136, 157, 161
 anterior clefts 160
 anterior notches 160
 bamboo 157, 161
 cervical *see* Cervical spine
 curvature 133
 abnormal 47
 reversed 45
 see also Kyphosis; Scoliosis
 disc prolapse *see* Prolapsed intervertebral disc (PID)
 epiphysis 160
 fracture 161
 complications 141
 'kissing spines' 140, 156
 lipping *see* Vertebrae, lipping
 lumbar *see* Lumbar spine
 movements 149–150
 assessment 146
 extension 150
 flexion 149–150
 lateral flexion 150
 rotation 150
 osteoarthritis 140, 156, 157, 163
 cervical *see* Cervical spondylosis
 osteochondrosis 135–136
 palpation 148
 percussion 148
 pyogenic osteitis 138–139
 radiography 154–160
 rheumatoid arthritis 140
 surgery complications 141
 thoracic *see* Thoracic spine
 tuberculosis *see* Tuberculosis
 tumours 37
 metastatic lesions 139
 vascular tracks 160
 vertebrae *see* Vertebrae
 see also Back pain; Spinal cord
 compression; *specific disorders*
 Splay foot 279, 290, 300
 Spondylolisthesis 139–140, 156, 158, 159, 162
 complications 141
 Spondylolysis 139–140, 159
 Sprains
 ankle 257, 259
 wrist 96
 Sprengel's shoulder 37, 58
 Standing apprehension test 232
 Staphylococcus
 osteitis 55, 246
 pyogenic arthritis of hip 169–170
 Sternoclavicular joint 50
 dislocation 57
 prominent 58
 tenderness 59
 Straight leg-raising test 151, 250
 Stress fracture 246–247
 tibia 246–247, 252
 Subacromial joint, compression beneath 52

Subdeltoid bursa, inflammation 53
 Subluxation *see* Dislocation/subluxation
 Subscapularis, testing 61
 Subtalar movements 272, 273, 298
 Subungual exostosis 296
 Sudeck's atrophy 90
 ankle 268
 foot 306
 wrist 95, 96, 106
 Sulcus sign 64
 Superficial peroneal nerve compression
 syndrome 296
 Superior calcaneal exostoses 293
 Suprascapular nerve 65
 Supraspinatus tendon
 calcification 66
 calcifying tendinitis 53–54, 68
 rotator cuff tears 52
 testing 65
 Surgery
 American Shoulder and Elbow Surgeons 57
 hip replacement *see* Hip replacement
 spinal 141
 Swan-neck deformity 116
 Synostosis, congenital 83
 radioulnar 84
 Synovial chondromatosis 241
 Synovitis
 knee 204
 transient 168
 villonodular 204
 see also Tenosynovitis
 Syphilis 114, 247
 leg pain 250
 Syringomyelia 134, 147

T

Tabes dorsalis 247
 Talipes *see* Club foot; Flat foot
 Talipes calcaneus 276
 Talipes equinovarus *see* Club foot
 Talocalcaneal synostosis 305
 Talonavicular joint, dislocation 302
 Talus
 avascular necrosis 269
 congenital vertical 302
 osteochondritis 259, 266
 see also Ankle
 Tape measure 8–9
 Tarsal tunnel syndrome 281, 295–296
 Tarsometatarsal movements 273
 Taylor–Palmear scale 111
 Technetium bone scan 8
 Tenderness
 acromioclavicular joint 59
 ankle 261
 clavicle 59
 foot 293–294, 296
 forefoot 294
 great toe 296
 heel 293
 joint examination 4
 knee 221–222
 patella 235
 patellar ligament 222
 quadriceps 222
 sacroiliac joint 148
 sternoclavicular joint 59
 tibia 222, 250
 Tendinitis 258
 Achilles 258
 biceps 56, 64
 calcifying supraspinatus 53–54, 68
 insertional 258
 palpation 58
 quadriceps 206
 Tendinopathy 264
 Tendinosis 258
 Tendo calcaneus 258, 259–260
 acute traumatic rupture 258
 shortening 259–260
 tendinopathy 258, 264
 Thomson test 265
 Tendon hammer 9
 Tendon injuries, hand 123
 Tendon sheath infections, hand 114
 Tendon sheath lesions, hand 111–112
 Tennis elbow 75
 examination 81–82
 palpation 80
 Tenosynovitis
 abductor pollicis longus/extensor pollicis brevis 91
 acute frictional 91
 ankle 258–259, 265–266
 extensor (wrist) 91
 see also De Quervain's disease
 Thenar space infections 114, 125
 Thigh, lateral cutaneous nerve 32
 Thomas's test (hip) 182
 Thomsen's test (elbow) 82
 Thomson test (ankle) 265
 Thoracic motor root dysfunction 153
 Thoracic nerve, long 65
 Thoracic outlet syndrome 35, 40
 examination 40–41
 Thoracic spine 129–164
 ankylosing spondylitis 136
 arthritis 140
 Calvé's disease 136, 156, 161
 cord compression, testing 153
 curvature 133, 155
 kyphosis *see* Kyphosis
 scoliosis *see* Scoliosis
 disc calcification 155
 disc prolapse *see* Prolapsed intervertebral disc (PID)
 DISH (diffuse idiopathic skeletal hyperostosis) 46, 136–137
 fixed curvature 135
 flexion 149–150
 inspection 146
 lateral flexion 51
 movements 131
 normal convexity angle 135
 Paget's disease 137
 pyogenic osteitis 138–139
 radiography 156
 rotation 150
 Scheuermann's disease 135–136, 155, 161
 spina bifida 140–141, 147, 156, 157, 164
 tuberculosis *see* Tuberculosis (TB)
 see also Back pain; *specific conditions*
 Thrombophlebitis 247

- Thumb 113
 abduction 122
 avulsion fracture 127
 gamekeeper's 121, 127
 mallet 111, 115
 movements 122
 assessment 119, 121
 trigger 112
 Z deformity 116
see also Finger(s)
- Tibia 245–254
 anterior compartment syndrome 246
 avulsion of tuberosity 205
 condylar subluxations 208
 assessment 231
 deformities 247–248, 252
 bowing 247
 kyphosis 247
 tibia vara 225, 243
 displacement at knee 225
 Ewing's tumour 253
 fracture 251, 252
 infections 251
 inspection 249
 medial tibial syndrome (shin splints) 247
 myositis ossificans 253
 osteitis 246, 252, 253
 osteoclastoma 253
 Paget's disease 251, 252
 pathology 252–253
 pseudarthrosis 247–248, 251
 radiography 251–253
 screening tests 250
 stress fracture 246–247
 swelling 249
 tabs dorsalis 247
 tenderness 222, 250
 torsion 247, 249–250
 tubercle, tenderness 222
 tumours 246, 251, 253
- Tibial condylar subluxations 208, 231
 Tibial nerve (medial popliteal) 30, 31
 Tibial torsion 247, 249–250
 Tibia vara 225, 243
 Tinel's sign 18, 100, 295
 Toe(s) 275
 claw 280, 288
 curling 280, 288, 290
 great ("big") toe *see* Great toe
 hallux rigidus *see* Hallux rigidus
 hallux valgus *see* Hallux valgus
 hammer 280, 288
 ingrowing nails 296
 inspection 286–287, 287–288
 intoeing 276, 289
 mallet 280, 288
 movements 299
- Torticollis 38
 Tourniquet test, tarsal tunnel syndrome 296
 Transient synovitis 168
 Trapezoid ligament, tear 56
 Trauma
 fractures *see* Fracture(s)
 plexus lesions 14, 17
- Trendelenburg lurch 186
 Trendelenburg's test 186
 Trick movement 4
 Trigger finger/thumb 112
 Trochlea 74
- Tuberculosis (TB)
 ankle 259, 268
 elbow 77, 86
 hand 114
 hip 169, 176
 knee 205, 215, 242
 shoulder 55, 70
 spine 137–138, 155, 157, 160, 162
 clinical/radiological features 138
 extrinsic causes 137–138
 increasing incidence 137
 intrinsic causes 138
 investigations 138
 onset 137
 treatment 138
 wrist 91, 93, 96, 106
- Tumours
 hand 113–114, 118, 126
 hip 171, 176
 knee 242
 prostate carcinoma 69
 shoulder 69
 spine 37, 139
 tibia 246, 251, 253
see also specific tumours
- U**
- Ulna 74
 prominence, on inspection 94
- Ulnar nerve 74
 examination 22–24, 82
 motor distribution 21
 neuritis 76
 palsy 75–76
 sensory distribution 21
 sites affected 21
- Ulnar tunnel syndrome 76, 92–93
 examination 96, 101
- Ultrasound 8
- Uncovertebral joints
 fractures 36
 osteophytes 45
- V**
- Valgus stress instability 225–227
 Van Rosen method 188
 Varus stress instability 227–228
 Verruca pedis (plantar wart) 280, 289
- Vertebrae 44
 anterior wedging 135, 137
 collapse 42
 deformity 133
 disc space narrowing 43
 displacement 42
 elements 130
 fusions 42, 43
 lateral wedging 44
 lippling
 anterior/posterior 43, 163
 disc lesions 156
 radiography 155
 relationships 130
see also Prolapsed intervertebral disc (PID)
- Vertebral artery, in cervical spondylosis 35
 Vertebral bodies 131
 compression fractures, cervical 36
 fractures 137
 ossification, DISH 136–137
 radiography 155
 wedging, Scheuermann's disease 135
- Vertebral notches 160, 161
 Vertebra plana 156, 161
- Vibration syndromes 110–111
 bone involvement 110
 differential diagnosis 111
 hand 123
 nerve involvement 110
 stage classifications 111
- Villonodular synovitis 204
 Volkmann's ischaemic contracture 117
- W**
- Web space infections 114, 125
 Whiplash 35–36
 partial 36
 symptoms 36
 treatment 36
- Wilson's test 222
 Winged scapula 56
 Wound healing, in Ehlers–Danlos syndrome 93
- Wrist 89–108
 achondroplasia 104
 aspiration 107
 carpal instabilities 93–94
 congenital deformity 104
 crepitus 99
 dorsiflexion 96, 97
 fracture 105, 106
 Colles' *see* Colles' fracture
 malunion 106, 107
 ganglia 90–91, 95
 hypermobility 97
 infective arthritis 106
 inspection 94–95
 movements 96
 myotomes 15
 neurological assessment 17
 ossification 104
 osteitis 106
 osteoarthritis 91, 105
 palmar flexion 97
 palpation 95–96
 pronation/supination 98
 radial deviation 98
 radiography 102–107
 rheumatoid arthritis (RA) 91–92, 96
 rickets 105
 sprain 96
 swelling 94–95
 tuberculosis 91, 93, 96, 106
 ulnar deviation 98
- X**
- X-rays *see* Radiography
- Z**
- Z deformity, thumb 116

Summary of joint movements (Main screening tests are in italics)

The fingers

MP joints, flexion	90°	
MP joints, passive hyperextension	up to 45°	
proximal, IP joints, flexion	100°	
distal IP joints, flexion	80°	
combined movements		<i>the fingertips should be able to touch the palm, and then 'tuck in'</i>

The thoraco-lumbar spine

thoracic spine flexion	45°	<i>increase of 3 cm in a 30 cm length</i>
lumbar spine flexion	60°	<i>increase of 5 cm or more in a 15 cm length</i>
combined lateral flexion to each side	30°	
thoracic spine rotation to each side	40°	

The hip

flexion	120°	<i>limited by thigh contacting abdomen</i>
extension	5°–20°	
abduction	40°	
adduction	25°	
internal rotation at 90° flexion	45°	
external rotation at 90° flexion	45°	
internal rotation in extension	35°	
external rotation in extension	45°	

The knee

flexion	135°+	<i>limit when heel touches buttock</i>
---------	-------	--

The ankle

dorsiflexion	15°
plantarflexion	55°

The foot

inversion of heel	20°
eversion of heel	10°
total supination at forefoot level	35°
total pronation at forefoot level	20°

The great toe

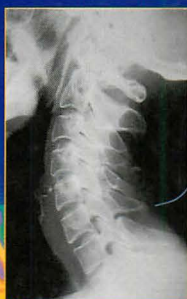flexion at MP joint	40°
extension at MP joint	65°
flexion at IP joint	60°
extension at IP joint	0°

Continued from inside front cover

FIFTH EDITION

CLINICAL ORTHOPAEDIC EXAMINATION

Ronald McRae



CHURCHILL
LIVINGSTONE

This is a new edition of a book which has established itself as a standard guide to orthopaedic examination. The author's own unique line diagrams are accompanied by clear and unambiguous text, and guidance is given on what to look for in radiographs. Anatomical details, perhaps studied in the past by the reader but easily forgotten, are summarised in a helpful way.

For this new edition, the line diagrams have been improved and additional information included on such topics as thoracic outlet syndrome, shoulder instabilities, shoulder cuff problems and knee instabilities.

Clinical Orthopaedic Examination is ideal for medical students, trainees in orthopaedics and physiotherapists.

"... the book should be in the possession of every medical student, general practitioner and junior orthopaedic doctor."

Journal of Bone and Joint Surgery



CHURCHILL
LIVINGSTONE

An imprint of Elsevier Science



fleshandbones.com

The new body of information in medicine
A resource for students and instructors

ISBN 0-443-07407-0



9 780443 074073