

## REVIEW ARTICLE

## CURRENT CONCEPTS

# Venous Thromboembolic Disease and Pregnancy

Paul E. Marik, M.D., and Lauren A. Plante, M.D., M.P.H.

**P**ULMONARY EMBOLISM AND DEEP-VEIN THROMBOSIS ARE THE TWO COMPONENTS of a single disease called venous thromboembolism. Approximately 30% of apparently isolated episodes of pulmonary embolism are associated with silent deep-vein thrombosis, and in patients presenting with symptoms of deep-vein thrombosis, the frequency of silent pulmonary embolism ranges from 40 to 50%.<sup>1,2</sup> Venous thromboembolism is both more common and more complex to diagnose in patients who are pregnant than in those who are not pregnant. The incidence of venous thromboembolism is estimated at 0.76 to 1.72 per 1000 pregnancies, which is four times as great as the risk in the nonpregnant population.<sup>3,4</sup> A meta-analysis showed that two thirds of cases of deep-vein thrombosis occurred in the antepartum period and were distributed relatively equally among all three trimesters.<sup>5</sup> In contrast, 43 to 60% of pregnancy-related episodes of pulmonary embolism appear to occur in the puerperium.<sup>4,6,7</sup>

Pulmonary embolism is the leading cause of maternal death in the developed world. Current estimates of deaths from pulmonary embolism are 1.1 to 1.5 per 100,000 deliveries in the United States and Europe.<sup>4,8,9</sup> In the United Kingdom, venous thromboembolism accounts for one third of all maternal deaths.<sup>8,9</sup> Delayed diagnosis, delayed or inadequate treatment, and inadequate thromboprophylaxis account for many of the deaths due to venous thromboembolism.<sup>8,9</sup> Successful strategies for the management of venous thromboembolism in nonpregnant patients have been established. However, many of the recommendations for the treatment of pregnant patients who have venous thromboembolism are not based on high-quality data; rather, they are derived from observational studies and extrapolation from studies involving nonpregnant patients. The purpose of this review is to provide a practical approach to the diagnosis, management, and prevention of venous thromboembolism in pregnant patients.

## RISK FACTORS FOR VENOUS THROMBOEMBOLISM

Pregnancy is classically thought to be a hypercoagulable state. Fibrin generation is increased, fibrinolytic activity is decreased, levels of coagulation factors II, VII, VIII, and X are all increased, free protein S levels are decreased, and acquired resistance to activated protein C is common.<sup>10</sup> Uncomplicated pregnancy is accompanied by substantial hemostatic activation as indicated by increased markers of coagulation activation, such as prothrombin fragment F1+2 and D-dimer.<sup>11</sup> Also, reduction in venous flow velocity of approximately 50% occurs in the legs by 25 to 29 weeks of gestation and lasts until approximately 6 weeks after delivery, at which time it returns to normal nonpregnancy flow-velocity rates.<sup>12,13</sup> In addition, the presence of inherited thrombophilias and the antiphospholipid syndrome, as well as a previous history of thrombosis, increase the risk for venous thromboembolism during pregnancy and the postpartum period.<sup>4</sup>

From the Division of Pulmonary and Critical Care Medicine (P.E.M.), the Department of Obstetrics and Gynecology (L.A.P.), and the Department of Anesthesiology (L.A.P.), Thomas Jefferson University, Philadelphia. Address reprint requests to Dr. Marik at Pulmonary and Critical Care Medicine, Thomas Jefferson University, 834 Walnut St., Suite 650, Philadelphia, PA, 19107, or at paul.marik@jefferson.edu.

N Engl J Med 2008;359:2025-33.

Copyright © 2008 Massachusetts Medical Society.

**Table 1. Estimated Prevalence of Congenital Thrombophilia and the Associated Risk of Thromboembolism during Pregnancy in a European Population.\***

Risk Factor	Prevalence %	Odds Ratio
Factor V Leiden mutation		
Heterozygous	2.0–7.0	9
Homozygous	0.2–0.5	34
Prothrombin G20210A mutation		
Heterozygous	2.0	7
Homozygous	Rare	26
Antithrombin deficiency (<80% activity)	<0.1–0.6	5
Protein C deficiency (<75% activity)	0.2–0.3	5
Protein S deficiency (<65% activity)	<0.1–0.1	3

\* Data are from the Haemostasis and Thrombosis Task Force,<sup>21</sup> Robertson et al.,<sup>22</sup> and Nelson and Greer.<sup>23</sup>

Additional risk factors include black race, heart disease, sickle cell disease, diabetes, lupus, smoking, multiple pregnancy, age greater than 35 years, obesity, and cesarean delivery (especially emergency cesarean section during labor).<sup>4,14-17</sup> Because of their high prevalence, age greater than 35 years, obesity, and cesarean delivery contribute most substantially to rates of venous thromboembolism rates. There is a striking predisposition for deep-vein thrombosis to occur in the left leg (approximately 70 to 90% of cases), possibly because of exacerbation of the compressive effects on the left iliac vein due to its being crossed by the right iliac artery.<sup>18</sup> The incidence of isolated deep-vein thrombosis in the iliac vein is thought to be higher in pregnant women than in nonpregnant women. This complicates the diagnosis of deep-vein thrombosis in symptomatic pregnant women, because compression ultrasonography, the test of choice in nonpregnant subjects with suspected deep-vein thrombosis, does not reliably detect iliac deep-vein thrombosis. Isolated iliac-vein thrombosis may present with abdominal pain, back pain, and swelling of the entire leg; however, patients may also be asymptomatic and have no findings on physical examination.<sup>19,20</sup>

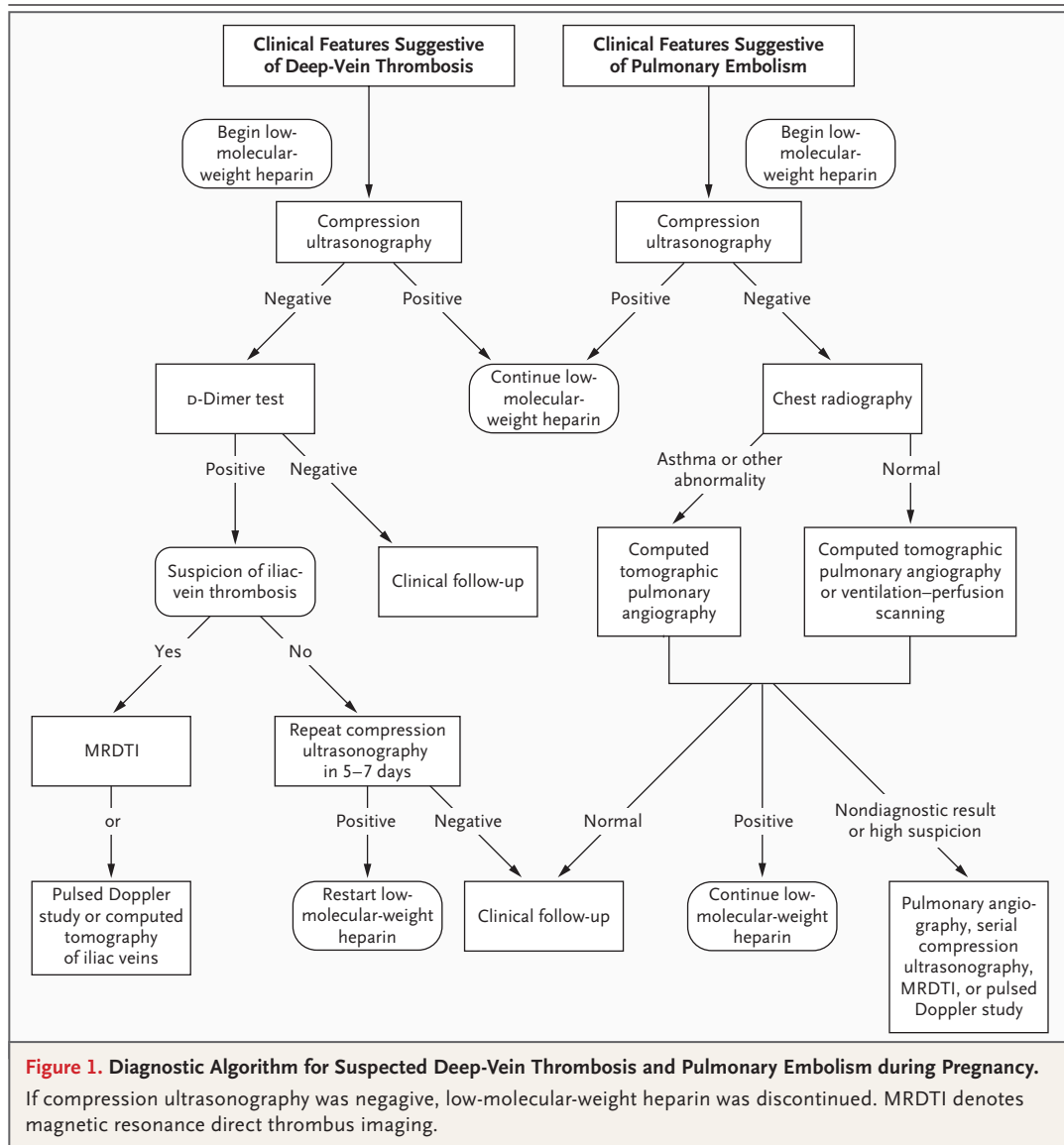
#### HERITABLE THROMBOPHILIA AND VENOUS THROMBOEMBOLISM

A thrombophilia is defined as a disorder of hemostasis that predisposes a person to a thrombotic event.<sup>21</sup> The prevalence of the inherited

thrombophilias depends on the population studied (Table 1).<sup>21-23</sup> Data suggest that at least 50% of cases of venous thromboembolism in pregnant women are associated with an inherited or acquired thrombophilia.<sup>24,25</sup> In combination, the inherited thrombophilias are common (affecting 15% of Western populations) and underlie approximately 50% of cases of venous thromboembolism in pregnancy; however, venous thromboembolism occurs in only 0.1% of pregnancies. Therefore, the presence of a thrombophilia alone, even in the context of the hypercoagulable state of pregnancy, does not consistently result in a thrombotic event. Given the rarity of venous thromboembolism and the high incidence of inherited thrombophilias, universal screening of pregnant women is not cost-effective.<sup>26,27</sup> Thrombophilia screening is of limited value in women who have acute venous thromboembolism during pregnancy, because it does not alter the immediate clinical management of the disease, and both pregnancy and thrombosis affect the circulating level of many of the coagulation factors. However, thrombophilia screening should be considered after the end of pregnancy and once the use of anticoagulant agents has been stopped, since the results may affect the management of subsequent pregnancies.

#### DIAGNOSIS OF VENOUS THROMBOEMBOLISM

Clinical suspicion is critical for the diagnosis of venous thromboembolism. However, many of the classic signs and symptoms of deep-vein thrombosis and pulmonary embolism, including leg swelling, tachycardia, tachypnea, and dyspnea, may be associated with a normal pregnancy. Common strategies for predicting pulmonary embolism have not been validated in pregnancy.<sup>28</sup> Venous thromboembolism is confirmed in less than 10% of pregnant women in whom the diagnosis is suspected, as compared with approximately 25% of nonpregnant patients.<sup>29</sup> However, since sudden death is not uncommon in pregnant patients who have features compatible with venous thromboembolism, all pregnant women with signs and symptoms suggestive of venous thromboembolism should have objective testing performed expeditiously. Treatment with low-molecular-weight heparin or unfractionated heparin is recommended until the diagnosis is ruled out by objective testing, unless treatment is strongly contraindicated.<sup>30</sup>



Compression ultrasonography is a noninvasive test with a sensitivity of 97% and a specificity of 94% for the diagnosis of symptomatic, proximal deep-vein thrombosis in the general population.<sup>31</sup> This test is without risk and is the test of choice in pregnant patients with suspected venous thromboembolism (Fig. 1). Compression ultrasonography is less accurate for isolated calf- and iliac-vein thrombosis.<sup>32</sup> During ultrasonography, the need for high pressure to compress the femoral vein in the groin or the absence of flow on Doppler studies is suggestive of iliac-vein thrombosis. Magnetic resonance direct thrombus imaging, which does not involve radiation exposure and is not harmful to the fetus, has a high sensitivity and specificity for the diagnosis

of iliac-vein thrombosis.<sup>20,33</sup> A pulsed Doppler study of the iliac vein and computed tomographic (CT) scanning may be useful for detecting iliac-vein thrombosis when magnetic resonance imaging (MRI) is not available.<sup>34,35</sup> CT scanning, unlike either ultrasonography or MRI, is associated with fetal radiation exposure.

Levels of D-dimer increase with the progression of a normal pregnancy. However, the interpretation of the D-dimer level depends on which test is used to perform the assay and the cutoff values used. Current recommendations suggest that a D-dimer test should be used in combination with other tests.<sup>30,36</sup> Chan and coworkers showed that a negative test with a highly specific assay in the first and second trimesters had a negative pre-

**Table 2. Recommended Initial Dose of Low-Molecular-Weight Heparin for the Treatment of Venous Thromboembolism According to Body Weight in Early Pregnancy.\***

Low-Molecular-Weight Heparin	Body Weight in Early Pregnancy			
	<50 kg	50–69 kg	70–90 kg	>90 kg
Enoxaparin	40 mg twice a day	60 mg twice a day	80 mg twice a day	100 mg twice a day
Dalteparin	5000 U twice a day	6000 U twice a day	8000 U twice a day	10,000 U twice a day
Tinzaparin	175 U/kg once daily	175 U/kg once daily	175 U/kg once daily	175 U/kg once daily

\* Data are from Bates et al.<sup>29</sup> and the Royal College of Obstetricians and Gynaecologists.<sup>54</sup>

dictive value of 100%; the sensitivity and specificity of a positive test were 100% and 60%, respectively.<sup>37</sup> However, a negative D-dimer test may not necessarily rule out venous thromboembolism.<sup>38</sup> A negative D-dimer test may be helpful if compression ultrasonography is normal, whereas a positive D-dimer test requires additional diagnostic testing.

Patients with suspected pulmonary embolism and normal findings on compression ultrasonography require additional diagnostic imaging (Fig. 1). A chest radiograph should be obtained to rule out alternative diagnoses and to guide further diagnostic testing. Ventilation–perfusion lung scanning or computed tomographic pulmonary angiography (CTPA) should be performed.<sup>30</sup> Ventilation–perfusion lung scanning delivers a higher fetal dose of radiation than does CTPA (640 to 800  $\mu$ Gy vs. 3 to 131  $\mu$ Gy); perfusion scanning alone will reduce the radiation exposure.<sup>30,39,40</sup> However, the radiation dose delivered to mothers is higher with CTPA than with scintigraphy (2.2 to 6.0 mSv vs. 1.4 mSv).<sup>39,40</sup> Women with suspected venous thromboembolism should be advised that ventilation–perfusion scanning carries a slightly higher risk of childhood cancer in offspring than does CTPA (1 case in 280,000 vs. <1 in 1 million) but carries a lower risk of maternal breast cancer (the lifetime risk is up to 13% greater with CTPA than with ventilation–perfusion scanning).<sup>30</sup>

#### MANAGEMENT OF VENOUS THROMBOEMBOLISM DURING PREGNANCY

The treatment and prophylaxis of venous thromboembolism in pregnancy center on the use of unfractionated heparin or low-molecular-weight heparin because of the fetal hazards associated

with warfarin, which is known to cross the placenta.<sup>41</sup> Warfarin embryopathy is characterized by midface hypoplasia, stippled chondral calcification, scoliosis, short proximal limbs, and short phalanges; it affects 5% of fetuses that are exposed to the drug between 6 and 9 weeks of gestation.<sup>42</sup> The use of warfarin in the second trimester and early in the third trimester is associated with fetal intracranial hemorrhage and schizencephaly.<sup>43,44</sup> Neither unfractionated heparin nor low-molecular-weight heparin crosses the placenta, and thus there is no possibility of teratogenesis or fetal hemorrhage with these drugs.<sup>45</sup>

Although for many years unfractionated heparin was the standard anticoagulant used during pregnancy and into the puerperium, current guidelines now recommend low-molecular-weight heparin.<sup>29,30,41</sup> The advantages of low-molecular-weight heparin include a reduced risk of bleeding, predictable pharmacokinetics allowing weight-based dosing without the need for monitoring, and a reduced risk of heparin-induced thrombocytopenia and heparin-induced osteoporotic fractures.<sup>29,46–48</sup> The management of isolated calf-vein thrombosis is controversial, with no established guidelines. However, since most iliofemoral thromboses originate from calf-vein thromboses, full anticoagulation with low-molecular-weight heparin is suggested for symptomatic patients. The use of retrievable vena caval filters should be considered only for patients in whom anticoagulation is contraindicated or in whom extensive venous thromboembolism develops within 2 weeks before delivery.<sup>49</sup>

In the nonpregnant patient with venous thromboembolism, low-molecular-weight heparin is usually administered once daily with the use of a weight-adjusted dose regimen. Opinion is divided as to the optimal regimen for low-molecular-weight heparin in pregnant women. Because of

increased renal excretion, the half-life of low-molecular-weight heparin decreases in pregnancy.<sup>50,51</sup> Consequently, a twice-daily weight-based regimen has been recommended<sup>29,30,41,46,52,53</sup> (Table 2); however, many clinicians use once-daily dosing to simplify administration. Clinical experience suggests that in most patients, monitoring anti-factor Xa activity and making dose adjustments are not required except in patients at the extremes of body weight and those with altered renal function.<sup>52,53</sup>

Cutaneous allergic reactions to low-molecular-weight heparin are rare and include pruritus, urticarial rashes, erythematous plaques, and very rarely, skin necrosis. These reactions are reported to be more common during long-term use in pregnant women than during short-term use in nonpregnant persons.<sup>55,56</sup> Cross-reactivity occurs in about a third of women who are switched from one preparation of low-molecular-weight heparin to another. Limited experience with fondaparinux, a synthetic pentasaccharide and direct inhibitor of factor Xa, suggests that it may be a safe alternative in women with cross-reactivity among several low-molecular-weight heparins.<sup>57</sup> Although placental transfer of fondaparinux was not observed in an *in vitro* model,<sup>58</sup> limited clinical experience suggests that fondaparinux passes the placental barrier *in vivo*, resulting in low but measurable anti-factor Xa activity in umbilical-cord blood.<sup>59</sup> The Food and Drug Administration has designated fondaparinux as being in pregnancy category B (i.e., reproduction studies in animals have failed to demonstrate a risk to the fetus, and there are no data from adequate and well-controlled studies involving pregnant women).

Bed rest is generally not recommended for patients with deep-vein thrombosis, except for those with phlegmasia.<sup>60</sup> Low-risk, nonpregnant patients with deep-vein thrombosis have been treated successfully with low-molecular-weight heparin on an outpatient basis.<sup>61</sup> Such an approach can be considered in selected pregnant patients.

---

#### ANTICOAGULANT THERAPY DURING LABOR AND DELIVERY

---

The management of anticoagulation at the end of pregnancy is challenging, since the onset of labor is not predictable and both vaginal delivery and cesarean delivery are associated with blood

loss and are frequently conducted with the patient under regional anesthesia. If spontaneous labor occurs in women who have undergone full anticoagulation, neuraxial anesthesia should not be used because of the risk of spinal hematoma.<sup>29,62</sup> This problem can be overcome by scheduling elective induction of labor or cesarean section.

Current guidelines of the American Society of Regional Anesthesia and Pain Medicine suggest that spinal anesthesia may be performed 12 hours after administration of the last dose of prophylactic low-molecular-weight heparin and 24 hours after the last dose of therapeutic low-molecular-weight heparin (given either once or twice daily).<sup>63</sup> Intravenous unfractionated heparin should be stopped 6 hours before placement of a neuraxial blockade, and a normal activated partial-thromboplastin time should be confirmed.<sup>63</sup> Women who continue taking low-molecular-weight heparin should be advised that once they are in established labor, no further heparin should be taken. Because of the relatively high chance of cesarean delivery and the difficulty in predicting the onset of labor, many obstetricians are reluctant to treat a woman with low-molecular-weight heparin all the way through her pregnancy, since the agent's effects cannot be expeditiously reversed. Patients commonly are switched to subcutaneous unfractionated heparin for the last few weeks of pregnancy, although the benefit of this approach has not been validated by clinical studies. However, since the pharmacokinetics and pharmacodynamics of subcutaneous unfractionated heparin are unpredictable during the third trimester of pregnancy, meticulous monitoring of the activated partial-thromboplastin time, with dosage adjustment as needed, is required.<sup>64</sup> Furthermore, contrary to popular belief, the pharmacokinetics of subcutaneous unfractionated heparin and low-molecular-weight heparin are quite similar.<sup>65</sup> These factors, together with the safety concerns regarding the use of unfractionated heparin, limit the benefit of this approach.<sup>66</sup>

Treatment with low-molecular-weight heparin may be resumed within 12 hours after delivery in the absence of persistent bleeding.<sup>41</sup> The initiation of prophylactic low-molecular-weight heparin should be delayed for at least 12 hours after the removal of an epidural catheter.<sup>63</sup> After neuraxial anesthesia, therapeutic low-molecular-weight heparin should be administered no ear-

lier than 24 hours postoperatively or post partum and in the presence of adequate hemostasis.<sup>63</sup> Anticoagulation therapy with either low-molecular-weight heparin or warfarin is recommended for at least 6 weeks post partum and for a total of at least 6 months.<sup>29</sup> Before treatment is discontinued, the risk of thrombosis should be assessed. The post-thrombotic syndrome occurs in up to 60% of patients after a deep-vein thrombosis and is a cause of serious complications.<sup>67,68</sup> Compression stockings reduce the risk of the post-thrombotic syndrome by about 50% and should be worn on the affected leg for up to 2 years after the acute event.<sup>30,68</sup>

---

#### THROMBOLYTIC THERAPY

---

Although experience with thrombolytic therapy in pregnancy is limited, the use of thrombolytic agents may be lifesaving in patients with massive pulmonary embolism and severe hemodynamic compromise.<sup>69</sup> There is concern that thrombolytic therapy will lead to placental abruption, but this complication has not been reported. Although thrombolytic therapy within 10 days after cesarean section or delivery is contraindicated, successful thrombolysis has been reported within 1 hour after vaginal delivery and within 12 hours after cesarean section.<sup>70</sup>

---

#### MANAGEMENT OF PULMONARY EMBOLISM IN LATE PREGNANCY AND LABOR

---

Patients presenting with pulmonary embolism in late pregnancy should be treated with supplemental oxygen (to achieve an oxygen saturation of >95%) and intravenous heparin and should be transferred to a major medical center that has a maternal–fetal, neonatal, and cardiothoracic unit for high-risk patients. In hemodynamically stable patients, a temporary vena caval filter should be placed once the diagnosis has been confirmed.<sup>49</sup> As soon as the patient goes into active labor or a cesarean section is considered, the heparin should be stopped (and reversed with protamine if necessary). A cesarean section should not be performed while the patient is in a fully anticoagulated state; this can lead to uncontrolled bleeding and maternal death.

The care of the pregnant patient who has massive pulmonary embolism either at term or when suspicion of compromised fetal status

would call for expeditious cesarean delivery is complex and requires a coordinated treatment strategy by the obstetrician, intensivist, cardiothoracic surgeon, anesthesiologist, and interventional radiologist. The approach to the management of a massive pulmonary embolism should be individualized and adapted to changing circumstances; it could include cardiopulmonary bypass with surgical embolectomy followed by cesarean section or percutaneous mechanical clot fragmentation and placement of an inferior vena caval filter. Although thrombolytic therapy is considered to be contraindicated, successful outcomes with the use of thrombolytic therapy during labor have been reported.<sup>71,72</sup>

---

#### THROMBOPROPHYLAXIS DURING PREGNANCY AND THE PUERPERIUM

---

Women who have had a thromboembolic event have a much higher risk of a recurrent episode during pregnancy than women without such a history.<sup>73,74</sup> The risks of venous thromboembolism are even higher in the puerperium. Graduated compression stockings are recommended ante partum and post partum for all women who have had a previous venous thromboembolism.<sup>29</sup> Similarly, postpartum pharmacologic thromboprophylaxis for at least 6 weeks (low-molecular-weight heparin or warfarin) is recommended for all women who have had a previous venous thromboembolism.<sup>29</sup> Aspirin is not recommended for thromboprophylaxis.<sup>75</sup>

The indications for antepartum pharmacologic prophylaxis are more controversial,<sup>23,29,76</sup> and the risks and benefits should be evaluated for each patient, with the patient involved in the decision-making process. Pregnant women with two or more previous episodes of venous thromboembolism and those with high-risk thrombophilias (e.g., antithrombin deficiency, the antiphospholipid syndrome, compound heterozygosity for prothrombin G20210A variant and factor V Leiden, or homozygosity for prothrombin G20210A variant or factor V Leiden), regardless of whether they have a history of venous thromboembolism, should receive antenatal thromboprophylaxis (Table 3).<sup>29</sup> Antenatal anticoagulation may not be required for women whose previous venous thromboembolism was not related to pregnancy and was associated with a risk factor that is no longer present, as long as such women do not have additional risk factors or thrombophilia.<sup>54,73,74,76,77</sup>

**Table 3. Recommended Antenatal Prophylactic Doses of Low-Molecular-Weight Heparin According to Body Weight and Risk.\***

Low-Molecular-Weight Heparin	Body Weight			Very High Risk
	<50 kg	50–90 kg	>90 kg	
Enoxaparin	20 mg daily	40 mg daily	40 mg every 12 hr	0.5–1.0 mg/kg every 12 hr
Dalteparin	2500 U daily	5000 U daily	5000 U every 12 hr	50–100 U/kg every 12 hr
Tinzaparin	3500 U daily	4500 U daily	4500 U every 12 hr	4500 U every 12 hr

\* Data are from Bates et al.<sup>29</sup> and the Royal College of Obstetricians and Gynaecologists.<sup>30</sup>

**Table 4. Risk Assessment for Thromboembolism in Patients Who Undergo Cesarean Section.\*****Low risk: early ambulation**

Cesarean delivery for uncomplicated pregnancy with no other risk factors

**Moderate risk: low-molecular-weight heparin or compression stockings**

Age >35 yr

Obesity (BMI >30)

Parity >3

Gross varicose veins

Current infection

Preeclampsia

Immobility for >4 days before operation

Major current illness

Emergency cesarean section during labor

**High risk: low-molecular-weight heparin and compression stockings**

Presence of more than two risk factors from the moderate-risk section

Cesarean hysterectomy

Previous deep-vein thrombosis or known thrombophilia

\* BMI denotes body-mass index (the weight in kilograms divided by the square of the height in meters).

### THROMBOPROPHYLAXIS AFTER CESAREAN SECTION

Venous thromboembolism after cesarean section is uncommon but causes serious complications and may be fatal. The incidence of pulmonary embolism is reported to be higher after cesarean section than after vaginal delivery, by a factor of 2.5 to 20, and the incidence of fatal pulmonary embolism by a factor of 10.<sup>78,79</sup> According to the Confidential Enquiry into Maternal Death in the United Kingdom, more than three quarters of the postpartum deaths caused by venous thromboembolism were associated with cesarean delivery.<sup>8,78</sup> Although adequately powered prospective, randomized, controlled studies have shown thromboprophylaxis to be highly effective in reducing the incidence of venous thromboembolism after moderate-to-high-risk general, urologic, and gynecologic surgery, no such studies have been performed after cesarean section.<sup>75</sup> The Royal College of Obstetricians and Gynaecologists and the American College of Chest Physicians provide recommendations for risk assessment and thromboprophylaxis after cesarean section (Table 4).<sup>29,80</sup>

To our knowledge, the duration of thromboprophylaxis after cesarean section has not been studied. This issue is particularly important in view of the practice of early discharge from the hospital after a cesarean section, since the overall incidence of peripartum deep-vein thrombosis is highest during the first postpartum week.<sup>3</sup> The decision to use thromboprophylaxis should be made on the basis of each patient's risk assessment, with continuation of low-molecular-weight heparin and the use of compression stockings for up to 6 weeks in selected high-risk patients in whom important risk factors persist after delivery.<sup>29</sup> Other high-risk patients (e.g.,

For pregnant women with a single idiopathic episode of venous thromboembolism and for those with a single previous venous thromboembolism and a low-risk thrombophilia, antenatal thromboprophylaxis is considered optional, although close clinical surveillance throughout pregnancy is essential for those women who opt not to receive thromboprophylaxis.<sup>29</sup> Thromboprophylaxis should also be considered for morbidly obese patients (body-mass index [the weight in kilograms divided by the square of the height in meters], >40) and those confined to bed, particularly if other risk factors are also present.<sup>9</sup>

those who are obese or have had an emergency cesarean delivery) could reasonably be discharged to home while continuing to take low-molecular-weight heparin for a brief period, although we are aware of no published studies that quantify the benefit of this approach.

No potential conflict of interest relevant to this article was reported.

## REFERENCES

1. Turkstra F, Kuijter PM, van Beek EJ, et al. Diagnostic utility of ultrasonography of leg veins in patients suspected of having pulmonary embolism. *Ann Intern Med* 1997;126:775-81.
2. Meignan M, Rosso J, Gauthier H, et al. Systematic lung scans reveal a high frequency of silent pulmonary embolism in patients with proximal deep venous thrombosis. *Arch Intern Med* 2000;160:159-64.
3. Heit JA, Kobbervig CE, James AH, et al. Trends in the incidence of venous thromboembolism during pregnancy or postpartum: a 30-year population-based study. *Ann Intern Med* 2005;143:697-706.
4. James AH, Jamison MG, Brancazio LR, Myers MR. Venous thromboembolism during pregnancy and the postpartum period: incidence, risk factors, and mortality. *Am J Obstet Gynecol* 2006;194:1311-5.
5. Ray JG, Chan WS. Deep vein thrombosis during pregnancy and the puerperium: a meta-analysis of the period of risk and leg of presentation. *Obstet Gynecol Surv* 1999;54:265-71.
6. Simpson EL, Lawrenson RA, Nightingale AL, et al. Venous thromboembolism in pregnancy and the puerperium: incidence and additional risk factors from a London perinatal database. *BJOG* 2001;108:56-60.
7. James AH, Tapson VF, Goldhaber SZ. Thrombosis during pregnancy and the postpartum period. *Am J Obstet Gynecol* 2005;193:216-9.
8. The National Institute for Clinical Excellence. Why mothers die 2000-2002 — report on confidential enquiries into maternal deaths in the United Kingdom. London: Royal College of Obstetricians and Gynaecologists Press, 2003.
9. The Confidential Enquiry into Maternal and Child Health (CEMACH). Saving mothers' lives: reviewing maternal deaths to make motherhood safer — 2003-2005: the seventh report on confidential enquiries into maternal deaths in the United Kingdom. London: CEMACH, 2007.
10. Brenner B. Haemostatic changes in pregnancy. *Thromb Res* 2004;114:409-14.
11. Eichinger S, Weltermann A, Philipp K, et al. Prospective evaluation of hemostatic system activation and thrombin potential in healthy pregnant women with and without factor V Leiden. *Thromb Haemost* 1999;82:1232-6.
12. Macklon NS, Greer IA, Bowman AW. An ultrasound study of gestational and postural changes in the deep venous system of the leg in pregnancy. *Br J Obstet Gynaecol* 1997;104:191-7.
13. Macklon NS, Greer IA. The deep venous system in the puerperium: an ultrasound study. *Br J Obstet Gynaecol* 1997;104:198-200.
14. *Idem*. Venous thromboembolic disease in obstetrics and gynaecology: the Scottish experience. *Scott Med J* 1996;41:83-6.
15. Lindqvist P, Dahlbäck B, Marsál K. Thrombotic risk during pregnancy: a population study. *Obstet Gynecol* 1999;94:595-9.
16. Knight M. Antenatal pulmonary embolism: risk factors, management and outcomes. *BJOG* 2008;115:453-61.
17. Larsen TB, Sørensen HT, Gislum M, Johnsen SP. Maternal smoking, obesity, and risk of venous thromboembolism during pregnancy and the puerperium: a population-based nested case-control study. *Thromb Res* 2007;120:505-9.
18. Ginsberg JS, Brill-Edwards P, Burrows RF, et al. Venous thrombosis during pregnancy: leg and trimester of presentation. *Thromb Haemost* 1992;67:519-20.
19. Merhi Z, Awonuga A. Acute abdominal pain as the presenting symptom of isolated iliac vein thrombosis in pregnancy. *Obstet Gynecol* 2006;107:468-70.
20. Rodger MA, Avruch LI, Howley HE, Olivier A, Walker MC. Pelvic magnetic resonance venography reveals high rate of pelvic vein thrombosis after cesarean section. *Am J Obstet Gynecol* 2006;194:436-7.
21. Haemostasis and Thrombosis Task Force, British Committee for Standards in Haematology. Investigation and management of heritable thrombophilia. *Br J Haematol* 2001;114:512-28.
22. Robertson L, Wu O, Langhorne P, et al. Thrombophilia in pregnancy: a systematic review. *Br J Haematol* 2006;132:171-96.
23. Nelson SM, Greer IA. Thrombophilia and the risk for venous thromboembolism during pregnancy, delivery, and puerperium. *Obstet Gynecol Clin North Am* 2006;33:413-27.
24. Greer IA. Thrombosis in pregnancy: maternal and fetal issues. *Lancet* 1999;353:1258-65.
25. Rosendaal FR. Venous thrombosis: a multicausal disease. *Lancet* 1999;353:1167-73.
26. Clark P, Twaddle S, Walker ID, Scott L, Greer IA. Cost-effectiveness of screening for the factor V Leiden mutation in pregnant women. *Lancet* 2002;359:1919-20.
27. Wu O, Robertson L, Twaddle S, et al. Screening for thrombophilia in high-risk situations: a meta-analysis and cost-effectiveness analysis. *Br J Haematol* 2005;131:80-90.
28. Wells PS, Anderson DR, Bormanis J, et al. Value of assessment of pretest probability of deep-vein thrombosis in clinical management. *Lancet* 1997;350:1795-8.
29. Bates SM, Greer IA, Pabinger I, Sofaer S, Hirsh J. Venous thromboembolism, thrombophilia, antithrombotic therapy, and pregnancy: American College of Chest Physicians evidence-based clinical practice guidelines (8th edition). *Chest* 2008;133:Suppl:844S-886S.
30. Thromboprophylaxis during pregnancy, labour and after vaginal delivery. Guideline no. 37. London: Royal College of Obstetricians and Gynaecologists, 2004. (Accessed October 10, 2008, at [http://www.rcog.org.uk/resources/Public/pdf/Thromboprophylaxis\\_no037.pdf](http://www.rcog.org.uk/resources/Public/pdf/Thromboprophylaxis_no037.pdf).)
31. Kearon C, Julian JA, Newman TE, Ginsberg JS. Noninvasive diagnosis of deep venous thrombosis: McMaster Diagnostic Imaging Practice Guidelines Initiative. *Ann Intern Med* 1998;128:663-77. [Erratum, *Ann Intern Med* 1998;129:425.]
32. Eskandari MK, Sugimoto H, Richardson T, Webster MW, Makaroun MS. Is color-flow duplex a good diagnostic test for detection of isolated calf vein thrombosis in high-risk patients? *Angiology* 2000;51:705-10.
33. Fraser DG, Moody AR, Morgan PS, Martel AL, Davidson I. Diagnosis of lower-limb deep venous thrombosis: a prospective blinded study of magnetic resonance direct thrombus imaging. *Ann Intern Med* 2002;136:89-98.
34. Frede TE, Ruthberg BN. Sonographic demonstration of iliac venous thrombosis in the maternity patient. *J Ultrasound Med* 1988;7:33-7.
35. Zerhouni EA, Barth KH, Siegelman SS. Demonstration of venous thrombosis by computed tomography. *AJR Am J Roentgenol* 1980;134:753-8.
36. Nijkeuter M, Huisman MV. Diagnosing pulmonary embolism in pregnancy: is there a role for D-dimer as a stand-alone test? *Crit Care Med* 2006;34:2701-2.
37. Chan WS, Chunilal S, Lee A, Crowther M, Rodger M, Ginsberg JS. A red blood cell agglutination D-dimer test to exclude deep venous thrombosis in pregnancy. *Ann Intern Med* 2007;147:165-70.
38. To MS, Hunt BJ, Nelson-Piercy C. A negative D-dimer does not exclude venous thromboembolism (VTE) in pregnancy. *J Obstet Gynaecol* 2008;28:222-3.
39. Groves AM, Yates SJ, Win T, et al. CT pulmonary angiography versus ventilation-perfusion scintigraphy in pregnancy: implications from a UK survey of doctors'



- knowledge of radiation exposure. *Radiology* 2006;240:765-70.
40. Winer-Muram HT, Boone JM, Brown HL, Jennings SG, Mabile WC, Lombardo GT. Pulmonary embolism in pregnant patients: fetal radiation dose with helical CT. *Radiology* 2002;224:487-92.
41. Duhl AJ, Paidas MJ, Ural SH, et al. Antithrombotic therapy and pregnancy: consensus report and recommendations for prevention and treatment of venous thromboembolism and adverse pregnancy outcomes. *Am J Obstet Gynecol* 2007;197(5):457.e1-457.e21.
42. Wesseling J, van Driel D, Heymans HS, et al. Coumarins during pregnancy: long-term effects on growth and development of school-age children. *Thromb Haemost* 2001;85:609-13.
43. Lee HC, Cho SY, Lee HJ, Kim CJ, Park JS, Chi JG. Warfarin-associated fetal intracranial hemorrhage: a case report. *J Korean Med Sci* 2003;18:764-7.
44. Pati S, Helmbrecht GD. Congenital schizencephaly associated with in utero warfarin exposure. *Reprod Toxicol* 1994;8:115-20.
45. Forestier F, Daffos F, Capella-Pavlovsky M. Low molecular weight heparin (PK 10169) does not cross the placenta during the second trimester of pregnancy study by direct fetal blood sampling under ultrasound. *Thromb Res* 1984;34:557-60.
46. Greer IA, Nelson-Piercy C. Low-molecular-weight heparins for thromboprophylaxis and treatment of venous thromboembolism in pregnancy: a systematic review of safety and efficacy. *Blood* 2005;106:401-7.
47. Warkentin TE, Greinacher A, Koster A, Lincoff AM. Treatment and prevention of heparin-induced thrombocytopenia: American College of Chest Physicians evidence-based clinical practice guidelines (8th edition). *Chest* 2008;133:Suppl:340S-380S.
48. Pettilä V, Leinonen P, Marckola A, Hiilesmaa V, Kaaja R. Postpartum bone mineral density in women treated for thromboprophylaxis with unfractionated heparin or LMW heparin. *Thromb Haemost* 2002;87:182-6.
49. Baglin TP, Brush J, Streff BM. Guidelines on the use of vena cava filters. *Br J Haematol* 2006;134:590-5.
50. Casele HL, Laifer SA, Woelkers DA, Venkataraman R. Changes in the pharmacokinetics of the low-molecular-weight heparin enoxaparin sodium during pregnancy. *Am J Obstet Gynecol* 1999;181:1113-7.
51. Sephton V, Farquharson RG, Topping J, et al. A longitudinal study of maternal dose response to low molecular weight heparin in pregnancy. *Obstet Gynecol* 2003;101:1307-11.
52. Greer IA. Anticoagulants in pregnancy. *J Thromb Thrombolysis* 2006;21:57-65.
53. Rodie VA, Thomson AJ, Stewart FM, Quinn AJ, Walker ID, Greer IA. Low molecular weight heparin for the treatment of venous thromboembolism in pregnancy: a case series. *BJOG* 2002;109:1020-4.
54. Thromboembolic disease in pregnancy and the puerperium: acute management. Guideline no. 28. London: Royal College of Obstetricians and Gynaecologists, 2007. (Accessed October 10, 2008, at [http://www.rcog.org.uk/resources/public/pdf/green\\_top\\_28\\_thromboembolic\\_minorrevision.pdf](http://www.rcog.org.uk/resources/public/pdf/green_top_28_thromboembolic_minorrevision.pdf).)
55. Bank I, Libourel EJ, Middeldorp S, Van Der Meer J, Büller HR. High rate of skin complications due to low-molecular-weight heparins in pregnant women. *J Thromb Haemost* 2003;1:859-61.
56. Verdonkschot AE, Vasmel WL, Middeldorp S, van de Schoot JT. Skin reactions due to low molecular weight heparin in pregnancy: a strategic dilemma. *Arch Gynecol Obstet* 2005;271:163-5.
57. Gerhardt A, Zotz RB, Stockschlaeder M, Scharf RE. Fondaparinux is an effective alternative anticoagulant in pregnant women with high risk of venous thromboembolism and intolerance to low-molecular-weight heparins and heparinoids. *Thromb Haemost* 2007;97:496-7.
58. Lagrange F, Vergnes C, Brun JL, et al. Absence of placental transfer of pentasaccharide (Fondaparinux, Arixtra) in the dually perfused human cotyledon in vitro. *Thromb Haemost* 2002;87:831-5.
59. Dempfle CE. Minor transplacental passage of fondaparinux in vivo. *N Engl J Med* 2004;350:1914-5.
60. Trujillo-Santos J, Perea-Milla E, Jiménez-Puente A, et al. Bed rest or ambulation in the initial treatment of patients with acute deep vein thrombosis or pulmonary embolism: findings from the RIETE registry. *Chest* 2005;127:1631-6.
61. Segal JB, Streiff MB, Hoffman LV, Thornton K, Bass EB. Management of venous thromboembolism: a systematic review for a practice guideline. *Ann Intern Med* 2007;146:211-22.
62. Kopp SL, Horlocker TT. Anticoagulation in pregnancy and neuraxial blocks. *Anesthesiol Clin* 2008;26:1-22.
63. Horlocker TT, Wedel DJ, Benzon H, et al. Regional anesthesia in the anticoagulated patient: defining the risks (the second ASRA Consensus Conference on Neuraxial Anesthesia and Anticoagulation). *Reg Anesth Pain Med* 2003;28:172-97.
64. Brancazio LR, Reperti KA, Stierer R, Laifer SA. Pharmacokinetics and pharmacodynamics of subcutaneous heparin during the early third trimester of pregnancy. *Am J Obstet Gynecol* 1995;173:1240-5.
65. Morris TA, Jacobson A, Marsh JJ, Lane JR. Pharmacokinetics of UH and LMWH are similar with respect to antithrombin activity. *Thromb Res* 2005;115:45-51.
66. Kishimoto TK, Viswanathan K, Ganguly T, et al. Contaminated heparin associated with adverse clinical events and activation of the contact system. *N Engl J Med* 2008;358:2457-67.
67. McColl MD, Ellison J, Greer IA, Tait RC, Walker ID. Prevalence of the post-thrombotic syndrome in young women with previous venous thromboembolism. *Br J Haematol* 2000;108:272-4.
68. Brandjes DP, Büller HR, Heijboer H, et al. Randomised trial of effect of compression stockings in patients with symptomatic proximal-vein thrombosis. *Lancet* 1997;349:759-62.
69. Leonhardt G, Gaul C, Nietsch HH, Buerke M, Schleusser E. Thrombolytic therapy in pregnancy. *J Thromb Thrombolysis* 2006;21:271-6.
70. Stefanovic BS, Vasiljevic Z, Mitrovic P, Karadzic A, Ostojic M. Thrombolytic therapy for massive pulmonary embolism 12 hours after cesarean delivery despite contraindication? *Am J Emerg Med* 2006;24:502-4.
71. Fagher B, Ahlgren M, Astedt B. Acute massive pulmonary embolism treated with streptokinase during labor and the early puerperium. *Acta Obstet Gynecol Scand* 1990;69:659-61.
72. Hall RJ, Young C, Sutton GC, Cambell S. Treatment of acute massive pulmonary embolism by streptokinase during labour and delivery. *BMJ* 1972;4:647-9.
73. De Stefano V, Martinelli I, Rossi E, et al. The risk of recurrent venous thromboembolism in pregnancy and puerperium without antithrombotic prophylaxis. *Br J Haematol* 2006;135:386-91.
74. Pabinger I, Grafenhofer H, Kaider A, et al. Risk of pregnancy-associated recurrent venous thromboembolism in women with a history of venous thrombosis. *J Thromb Haemost* 2005;3:949-54.
75. Geerts WH, Bergqvist D, Pineo GF, et al. Prevention of venous thromboembolism: American College of Chest Physicians evidence-based clinical practice guidelines (8th edition). *Chest* 2008;133:Suppl:381S-453S.
76. Brill-Edwards P, Ginsberg JS, Gent M, et al. Safety of withholding heparin in pregnant women with a history of venous thromboembolism. *N Engl J Med* 2000;343:1439-44.
77. Simioni P, Tormene D, Prandoni P, Girolami A. Pregnancy-related recurrent events in thrombophilic women with previous venous thromboembolism. *Thromb Haemost* 2001;86:929.
78. Bonnar J. Can more be done in obstetric and gynecologic practice to reduce morbidity and mortality associated with venous thromboembolism? *Am J Obstet Gynecol* 1999;180:784-91.
79. Greer IA. Epidemiology, risk factors and prophylaxis of venous thromboembolism in obstetrics and gynaecology. *Baillieres Clin Obstet Gynaecol* 1997;11:403-30.
80. Report of the RCOG Working Party on Prophylaxis against Thromboembolism in Gynaecology and Obstetrics 1995. London: Royal College of Obstetrics and Gynaecology, 1995.

Copyright © 2008 Massachusetts Medical Society.