



## The management of incisional hernia

ANDREW KINGSNORTH

Department of Surgery, Derriford Hospital, Plymouth, UK

### ABSTRACT

Many thousand laparotomy incisions are created each year and the failure rate for closure of these abdominal wounds is between 10–15%, creating a large problem of incisional hernia. In the past many of these hernias have been neglected and treated with abdominal trusses or inadequately managed with high failure rates. The introduction of mesh has not had a significant impact because surgeons are not aware of modern effective techniques which may be used to reconstruct defects of the abdominal wall. This review will cover recent advances in incisional hernia surgery which affect the general surgeon, and also briefly review advanced techniques employed by specialist surgeons in anterior abdominal wall surgery.

### KEYWORDS

Incisional hernia – Abdominal wall – Repair

### CORRESPONDENCE TO

**Andrew Kingsnorth**, Consultant Surgeon, Derriford Hospital and Professor of Surgery, Peninsula Medical School, Level 7, Derriford Hospital, Plymouth PL6 8DH, UK

T: +44 (0)1752 763017; F: +44 (0)1752 763007; E: [andrew.kingsnorth@phnt.swest.nhs.uk](mailto:andrew.kingsnorth@phnt.swest.nhs.uk)

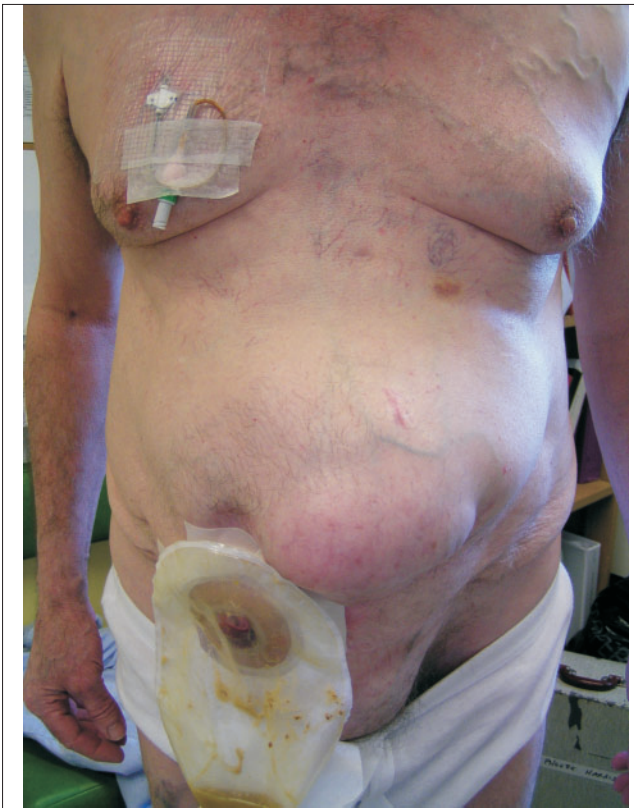Medline (1980–2005) and Embase were searched using the search terms ‘hernia’ and ‘incisional’ alone and in combination. Publications were selected mostly in the past 5 years, but did not exclude commonly reference and highly regarded older publications. The reference list of articles was also searched, identified by the search strategy and those selected that were relevant. Selected review articles and meta-analyses were included because they provide comprehensive overviews that may be beyond the scope of this article.

### Overview

The introduction of prosthetic mesh revolutionised the treatment of groin hernia but, to date, has had little impact on the treatment of incisional hernia.<sup>1</sup> The risk factors for the development of incisional hernia include obesity, diabetes, emergency surgery, postoperative wound dehiscence, smoking and postoperative wound infection.<sup>2,3</sup> The risks of repairing an incisional hernia which should be explained to the patient when obtaining consent include seroma formation, wound infection, injury to intra-abdominal structures and recurrence.<sup>4</sup> Major complications which can occur in repair of large incisional hernias include mesh infection and enterocutaneous fistula which may result in prolonged morbidity and require re-operation (Fig. 1). It is now accepted that only the smallest (less than 3 cm) incisional hernias should be repaired with primary

tissue approximation with sutures and this topic will not be discussed further.<sup>5</sup> Small incisional hernias with time develop into larger incisional hernias due to the continuous presence of intra-abdominal hydrostatic pressure of 15 cm of water, diaphragmatic contractions occurring with respiration, increases in abdominal pressure occurring with coughing and straining realising pressures of over 80 cm of water and myofascial retraction of the lateral muscles. As a result, the abdominal cavity contracts and the right of domicile for the herniated visceral mass is lost.<sup>6</sup> Due to several previous operations, many of these patients have poor-quality abdominal wall musculature which, coupled with multiple co-morbid medical problems, present a surgical and anaesthetic challenge.

Surgeons appear to have a reluctance to operate on incisional hernias perhaps because of the poor general condition of the patients but perhaps also due to lack of knowledge of how to deal with the various defects occurring as a result of incisions of the anterior abdominal wall and the operative techniques required. For instance, although it is estimated that 13% of laparotomy incisions fail in The Netherlands, only 4% of patients undergoing a laparotomy will go through additional surgery to repair an incisional hernia.<sup>7</sup> Suture repair is likely to produce results twice as bad as mesh repair and the current techniques that surgeons are using to repair incisional hernias with prosthetic mesh continue to yield recurrence rates of greater than 20%.<sup>8</sup>



**Figure 1** Serious morbidity from attempted incisional hernia repair showing recurrent hernia, enterocutaneous fistula, (short bowel syndrome) and long-term TPN.

Where endoscopic access is a viable option for intra-abdominal surgery, it should be used on the grounds that laparoscopic access results in considerably fewer wound hernias and postoperative episodes of small bowel obstruction.<sup>9</sup> Collagen disorders such as abdominal aortic aneurysm and Ehlers-Danlos syndrome greatly increase the risk of abdominal wall hernias.<sup>5,10</sup>

Because large areas of prosthetic mesh are utilised in the repair of large incisional hernias, it is probably this area of surgery that will benefit maximally from the development of bio-compatible meshes with near physiological functional properties that produce the lowest possible foreign body reaction and be of the minimum necessary tensile strength.<sup>11</sup>

### The management plan

Langer and colleagues,<sup>12</sup> in a comparative, retrospective study of over 400 incisional hernia operations over a 25-year period, estimated that the most important prognostic factor is the surgeon's experience. For a surgical team to offer a complete service for abdominal wall reconstruction, the following techniques should be mastered: prosthetic materials, abdominal components' separation, tissue

expansion, vacuum-assisted closure devices, local and distant muscle flaps, and free tissue transfer. This usually means that the abdominal surgeon will be working in partnership with plastic surgeons.<sup>15</sup> Rohrich *et al.*<sup>15</sup> have devised an algorithm for this approach to abdominal wall reconstruction. Dumainian and Denham<sup>14</sup> have brought laparoscopic surgery into this algorithm. These authors have stated that a transverse size of 10 cm is the upper limit for the laparoscopic approach, but some authors have pushed this limit to 15 cm. Laparoscopic incisional hernia repair and the sliding myofascial rectus flap (components' separation technique) are diametrically opposed solutions to the same clinical problem. However, the Ramirez operation can successfully repair hernias as large as 35 cm in transverse diameter achieving abdominal wall closure and no subsequent abdominal compartment syndrome. Which middle-sized hernias of between 10–15 cm in transverse diameter should be repaired with the laparoscope is still open for debate. Those over 15 cm in transverse dimension usually require an open supplementary components' separation operation. Absolute contraindications for the laparoscopic operation include patients who have had a previous incisional hernia repair (due to the usual dense adhesions encountered), those with loss of domain (because the contents of the hernia sac cannot be reduced), open wounds (insufflation is impossible) and where additional gastrointestinal surgery is required.

### Prevention and prophylaxis

Wound failure after abdominal wall closure is surgeon-dependent.<sup>15</sup> Several meta-analyses have recently been performed to reveal optimal techniques for closure of abdominal incisions. Hodgson and colleagues<sup>16</sup> determined that lower recurrence rates occurred with the use of non-absorbable materials utilising a continuous suture. van't Riet and colleagues<sup>17</sup> revealed similar outcomes with continuous or interrupted techniques and that a slowly absorbable suture was as effective as a non-absorbable suture. Finally, Rucinski and colleagues<sup>18</sup> concluded that a continuous mass (all layers) closure with absorbable monofilament suture material was the optimal technique. Several authors have supplemented primary abdominal wall closure with prosthetic mesh to reduce the incidence of wound failure. After aortic aneurysm repair and obesity surgery, the incidence of wound failure can be reduced to nearly zero.<sup>19,20</sup> Recent studies by Israelsson and colleagues<sup>21</sup> have demonstrated that the routine use of lightweight mesh when constructing a stoma should become routine practice.

### Pre-operative preparation

Where an abdominal wall hernia is complex and clinical assessment is considered to be insufficient (particularly in

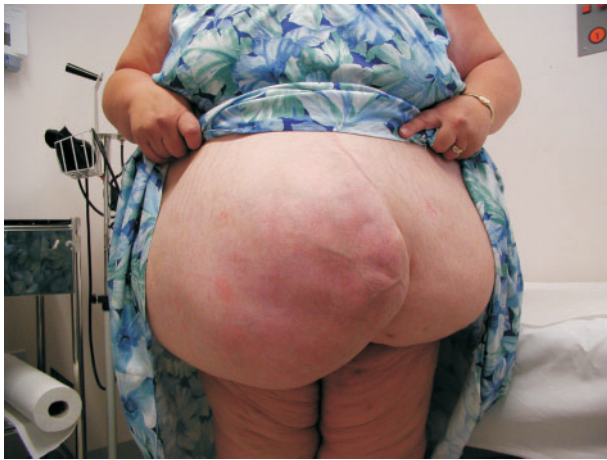

Figure 2 Incisional hernia with significant loss of domain.

multiply recurrent hernias with multiple defects), then imaging with CT scanning can be particularly helpful.<sup>22,23</sup> Occult defects are accurately delineated, the contents of the sac defined and an estimate can be made of the percentage of the abdominal contents that have lost domain. Significant loss of domain, which may result in abdominal compartment syndrome if the contents were to be reduced into the remaining peritoneal cavity, is considered to be approximately 20% and such hernias are particularly difficult to repair with complete closure of the abdominal wall myofascial layers (Fig. 2). Morena<sup>24</sup> and Mason<sup>25</sup> described pneumoperitoneum as a potential means of overcoming the problem of loss of domain by increasing the size of the remaining peritoneal cavity prior to surgery. This technique, however, has not been widely adopted because of its complexity and lack of efficacy.

The benefits of antibiotic prophylaxis in incisional hernia repair has not been put to the test of a randomised, controlled trial. However, Rios and colleagues,<sup>26</sup> in a non-randomised study, detected a small diminution with antibiotic prophylaxis using a pre-operative dose of amoxicillin and clavulenic acid, and, if the operation lasted longer than 2 h, another intra-operative dose was given intravenously. Trophic ulcers present in a small number of very large incisional hernias; they are usually situated at the most dependent area of the abdominal wall and occur as a result of ischaemia.<sup>27</sup> Such ulcers are usually infected with *Staphylococcus aureus* and should be treated vigorously with local wound care to eliminate gross infection before surgery (Fig. 3).

### The laparoscopic approach

Laparoscopic incisional hernia repair is in its infancy.<sup>28</sup> Goodney and colleagues<sup>28</sup> identified 85 studies comparing

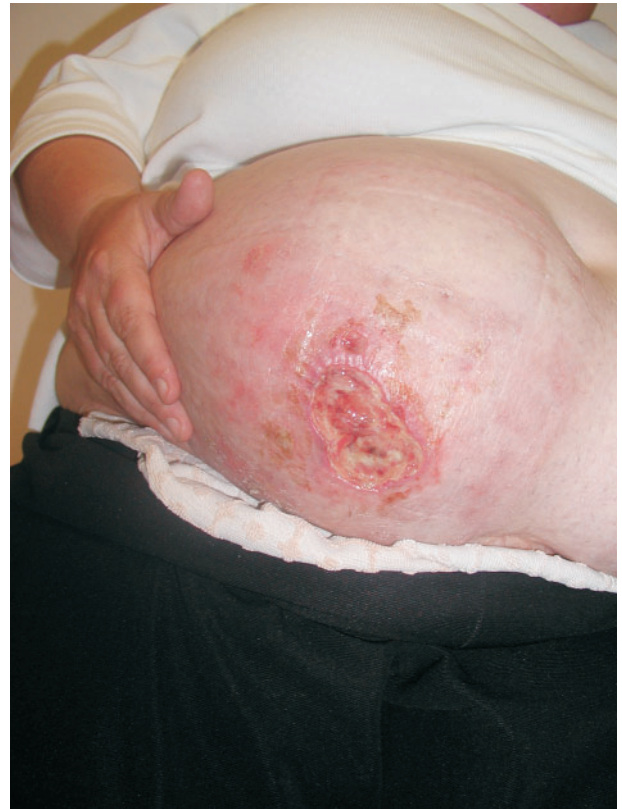

Figure 3 Trophic ulcer in skin overlying long-standing hernia.

open and laparoscopic techniques from a structured Medline search. Only eight of these studies met inclusion criteria for the study of the three main outcome measures – peri-operative complications, operative time and length of hospital stay. This resulted in an overall comparison of 390 patients having open repair and 322 with laparoscopic repair. Peri-operative complications and length of stay were reduced in the laparoscopic group. LeBlanc *et al.*,<sup>29</sup> the first to describe laparoscopic incisional herniorrhaphy, reported results at an average follow-up of 51 months in the first 100 patients. Major complications occurred in 4.1% of the patients with a recurrence of 9.3%. The major obstacles to success were mesh fixation which was achieved either with staples and tacks or through-and-through sutures to ensure secure peripheral fixation. The learning curve for the operation can be quite long and hazardous.<sup>30</sup> Bencini and Sanchez<sup>30</sup> reported four bowel entries in their first 32 cases together with three recurrences. The largest series to date of nearly 400 cases was reported by Franklin and colleagues<sup>31</sup> who operated over a 10-year period with an overall postoperative complication rate of 10.1% and recurrence rate of 2.9%. Most surgeons will underlay the defect with no attempt to achieve fascial closure. Franklin *et*

*al.*,<sup>51</sup> however, described limited percutaneous closure of large defects and Chelala and colleagues<sup>52</sup> strongly believe that the linea alba should be reconstructed for functional and mechanical purposes to reduce extrusion of mesh within the hernial defect and reduce seroma formation. The closure of the defect is achieved either by intracorporeal non-reabsorbable monofilament stitches or transperitoneal extracorporeal U-reverse stitches to re-approximate the linea alba. Because mesh is in contact with bowel following the underlay techniques used in laparoscopic repair, adhesion formation is a risk.<sup>53</sup> Even with careful interposition of omentum, this occurs in at least one-third of patients.

### Open prosthetic mesh techniques

Before the introduction of mesh, natural tissues were employed to repair large defects of the abdominal wall.<sup>54</sup> More than 50 years ago, Stock<sup>55</sup> realised the potential of the recent developments of plastics for the repair of large hernias. This was the result of a casual observation that increasing quantities of fancy shoes with nylon mesh uppers were appearing on the Hong Kong market and led him to investigate the use of this material as a potential repair material for hernias. His initial cases were successful and led Notaras<sup>56</sup> to report on the use of Mersilene mesh, a braided polyester fibre, for the repair of incisional hernia. Notaras used techniques which are still in use today: he implanted the mesh deep to the rectus muscles (sublay) with its edges at least 2.5 cm beyond the edges of the defect and administered antibiotics prophylactically with the use of closed suction drainage postoperatively.<sup>56</sup> Other methods of deployment of prosthetic mesh include the prefascial subcutaneous or onlay method and the inlay method where the fascial edges are not approximated and the mesh lies in contact with the underlying viscera. Korenkov and colleagues<sup>57</sup> reported on the results of an experts' meeting which summarised the results of the prefascial onlay prosthetic repair (seven studies) and the retromuscular sublay technique (eleven studies). The complication rates and the recurrence rates were in the same range for both techniques but there has never been a randomised study to investigate which is superior in the hands of general surgeons. The sublay technique is, however, more complicated to perform and is less versatile because it is only suitable for midline hernias. Korenkov and colleagues<sup>57</sup> also devised a classification system for incisional hernias which can be useful in comparative studies (Table 1).

#### The inlay technique

Polypropylene mesh anchors to all adjacent tissues and, therefore, has the propensity for inducing extensive adhesions to viscera if placed in a position where they become adjacent to bowel such as the inlay technique.

Erosion of the mesh may then occur into the intestines which is a well-recognised drawback of this technique. However, the group from Angers, France have reported a series of 350 patients operated between 1982 and 1999 in which the intraperitoneal placement of Dacron mesh was used as an aponeurotic graft.<sup>58</sup> A 10-cm underlap was used when the mesh is placed in the peritoneal cavity and securing sutures 3–4 cm apart of non-absorbable material placed through the entire anterior abdominal wall. This repair is then covered by a musculo-aponeurotic abdominoplasty fashioned by incising the anterior lamina of the rectus sheath 4 cm from its medial edge and reflecting it inwards and suturing the edges together. No fistulae were reported in this series with a postoperative mortality of 0.6%, 2% wound infections and 2% deep-seated infections that necessitated removal of the mesh. These outstanding results have not been repeated elsewhere and a smaller retrospective analysis carried out by de Vries Reilingh and colleagues<sup>59</sup> compared the inlay technique with onlay and sublay. In this series, the recurrence rate of

**Table 1 Classification for incisional hernias**

LOCALISATION
1. Vertical
1.1 Midline above or below umbilicus
1.2 Midline including umbilical right or left
1.3 Paramedian right or left
2. Transverse
2.1 Above or below umbilicus right or left
2.2 Crossed midline or not
3. Oblique
3.1 Above or below umbilicus right or left
4. Combined (midline + oblique; midline + parastomal, <i>etc.</i> )
SIZE (= real fascial gap)
1. Small (< 5 cm in width or length)
2. Medium (5–10 cm in width or length)
3. Large (> 10 cm in width or length)
RECURRENCE
1. Primary
2. Recurrence (1, 2, 3, <i>etc.</i> )
REDUCIBILITY AT THE HERNIA GATE
1. Reducible with or without obstruction
2. Irreducible with or without obstruction
SYMPTOMS
1. Asymptomatic
2. Symptomatic



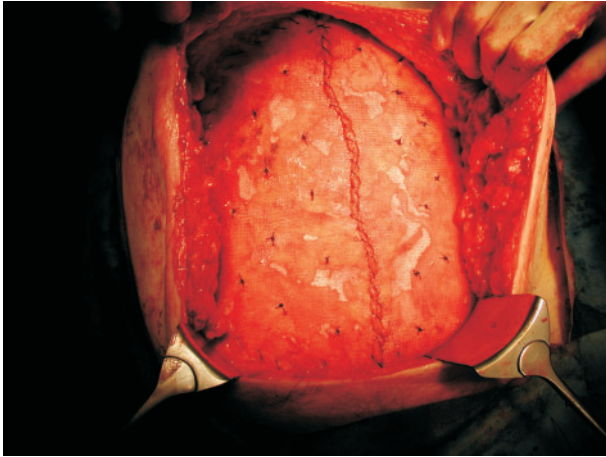


Figure 4 Onlay mesh fixed with multiple continuous and quilting sutures.

inlay was 44% and 2 of 25 patients receiving inlay developed enterocutaneous fistulae at the edges of the mesh where constant friction had caused damage to the bowel. Inlay techniques are not generally recommended unless there is a substantial defect in the tissue that cannot be bridged with plastic procedures of the natural layers of the abdominal wall (see below).

#### The onlay technique

The onlay technique (Fig. 4) in which the mesh is placed over the abdominal wall closure in the subcutaneous prefascial space was refined and popularised by Chevrel.<sup>40</sup> This technique is versatile and lends itself to repair of structures other than defect in the midline of the abdominal wall. Chevrel also described relaxing incisions in the anterior rectus sheath and the use of glues in an attempt to reduce seroma formation. Other groups, however, have not had the same success and San Pio and colleagues<sup>41</sup> performed the onlay technique with an 8–10 cm overlap with 10% of patients having relaxation of muscles of the anterior abdominal wall. The recurrence rate at 5-year follow-up was 15% and two patients died in the peri-operative period, one from pneumonia and one from bowel perforation.

#### Sublay technique

Another French group, Rives and colleagues,<sup>42</sup> devised and popularised this technique (Fig. 5) in which the mesh is placed over the closed posterior rectus sheath and peritoneum. The rectus muscles are then allowed to fall into their natural position overlying the mesh and then the anterior rectus sheath is closed (Fig. 2). Welty and colleagues<sup>43</sup> became the main protagonists for this technique and experimented

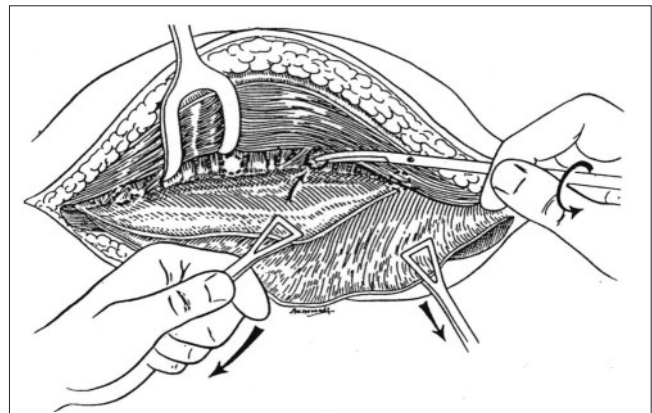


Figure 5 Preparing the space behind the rectus muscle for a sublay mesh.

with materials other than polypropylene exhibiting larger pore sizes in an attempt to produce a low-weight mesh. This is a complex operation and is only applicable to midline hernias and, in the lower one-third of this region, the mesh is only protected from bowel by tenuous peritoneum. Clinical trials are awaited to see which of the three mesh techniques provides the best results in the hands of general surgeons. The application of tissue glues between the muscle layers or between the fascial layers and subcutaneous tissue after incisional hernia repair with polypropylene mesh has the potential to reduce wound complications, such as seroma, and result in shorter hospital stay and less wound care.<sup>44</sup> The results of randomised trials are awaited.

#### Components' separation technique

This operation (Fig. 6), devised by Ramirez and colleagues,<sup>45</sup> allows a flap of the rectus muscle, anterior rectus sheath and internal oblique transversus to be advanced in the midline a maximum of 10 cm, *i.e.* incisional hernia gaps of 20 cm can be closed. The external oblique is released from its attachment to the rectus muscle and a plane dissected between the external and internal oblique aponeuroses. An additional step is the complete release of the rectus abdominus muscle from its anterior and posterior sheaths by incising the posterior rectus sheath at its medial border – the so-called sliding door technique.<sup>46</sup> An obvious prerequisite for this technique is the presence of undamaged rectus muscles. However, this technique will allow the tensionless approximation of the rectus muscles in large and recurrent hernias precluding the problem of abdominal compartment syndrome.<sup>47</sup> Many surgeons recommend the additional application of synthetic mesh in an onlay position to supplement the attenuated layers of the

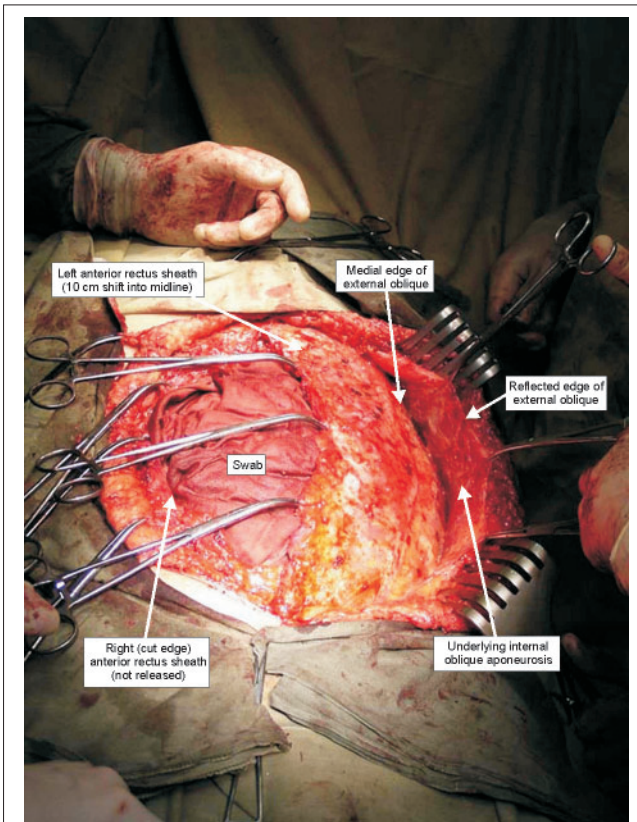


Figure 6 A 10-cm shift of the left rectus muscle into the midline after components separation of the external oblique aponeurosis from its attachment to the lateral border of the rectus muscle.

anterior abdominal wall.<sup>48</sup> In a relatively large series of 43 patients, de Vries Reilingh and colleagues<sup>49</sup> were unable to reproduce the good results of Ramirez and recorded recurrent hernia in 32% of patients at 15-month follow-up.

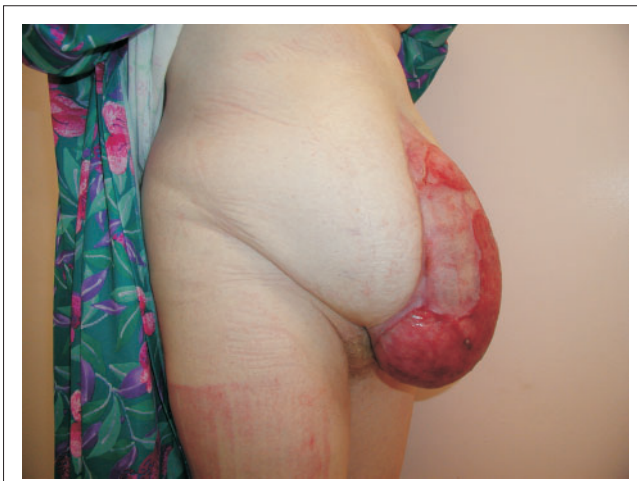

Figure 7 Granulating laparostomy wound.

### Tissue expansion assisted closure

An alternative method to components' separation is the use of tissue expanders placed in the subcutaneous or submuscular space for a period of months in order to achieve tissue expansion prior to hernia repair.<sup>50</sup> This technique is particularly useful in defects of the abdominal wall occurring after major trauma, tumour ablation or congenital abnormalities.

### Contaminated wounds

In the acute situation, temporary closure of open abdominal wounds can be achieved by the modified sandwich vacuum pack technique.<sup>51</sup> A 3-l plastic irrigation bag is sutured to the wound edges and continuous high-pressure suction applied to achieve temporary abdominal wall closure. This is the so-called laparostomy (Fig. 7) popularly used in cases of intra-abdominal sepsis, visceral oedema or compartment syndrome. Closure of laparostomy wounds can then be

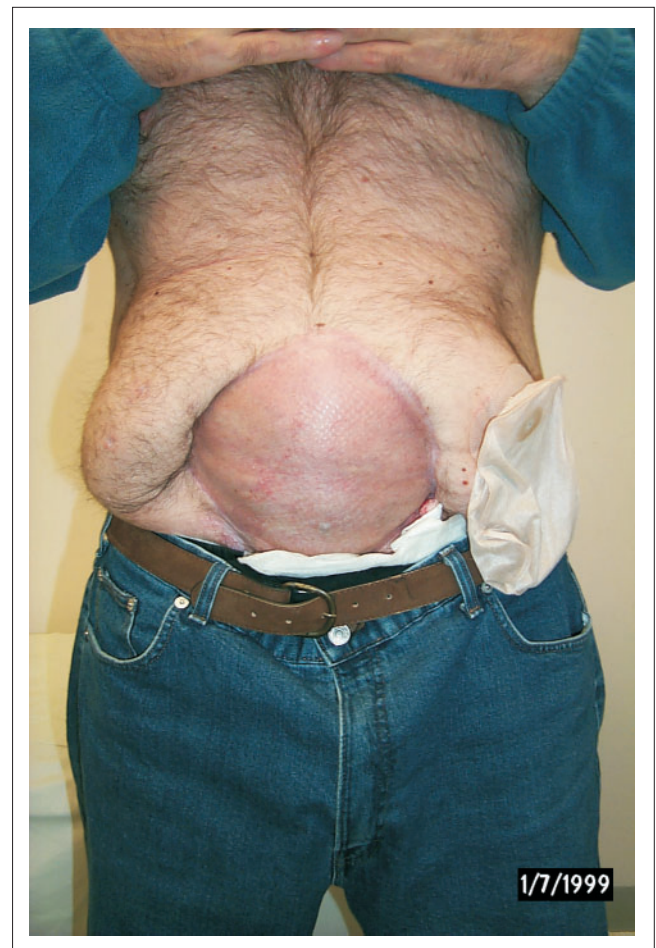

Figure 8 Split skin graft applied to laparostomy wound (and co-existing stoma constructed after anastomotic leak and sepsis).

achieved in two ways: (i) in stages by removing the plastic irrigation bag, allowing the wound to granulate, applying split skin grafts (Fig. 8) and finally attempting definitive reconstruction; or (ii) in a one-stage operation using the components' separation method.<sup>52,53</sup> The adoption of either of these methods, however, requires advanced skills in abdominal wall reconstruction and should only be undertaken by skilled teams of surgeons.

### Loss of domain

Loss of domain (residence) implies that a proportion of the abdominal contents reside permanently (in a hernia sac – the second abdominal cavity) outside their natural compartment; returning these contents will require significant physiological adaptation (mainly respiratory) if the volume exceeds more than 15–20% of this compartment.<sup>54</sup> Such hernias are a challenging surgical problem and require careful patient selection and surgical technique with a team involving anaesthetists and plastic surgeons, postoperative care in ITU and careful pre-operative preparation including considerable weight loss. The components' separation technique is a valuable adjunct in patients with loss of domain.

### Unusual sites

Parastomal hernia affects 1.8–28.3% of end ileostomies and up to 6.2% of loop ileostomies. Following colostomy formation, the rates are 4.0–48.1% and 0.3–31%, respectively.<sup>55</sup> Direct tissue repair or stoma relocation have recurrence rates of up to 50% although the use of mesh lowers this considerably to between 0–25%.<sup>56</sup> However, mesh placed in this onlay position around the stoma as a circumferential onlay can cause problems of erosion into the stoma or fistula formation in up to 5% of patients.<sup>57</sup> Jones *et al.*<sup>21</sup> have recently reported the use of prophylactic mesh in the prevention of parastomal hernia by the placement of a lightweight sublay mesh at the time of stoma formation.

Lumbar hernias are another particularly difficult hernia to repair because of the location over the flat lateral muscles of the abdominal wall often accompanied by concomitant nerve damage resulting in muscle atrophy.<sup>59</sup> The technique described by Carbonell solves the problem of repairing this type of hernia with the use of bone anchors.

A similar concept has been applied to the repair of iliac crest hernias occurring through donor sites for bone grafts.<sup>60–62</sup> Herniation occurs where the full thickness of the iliac bone has been removed and fixation of mesh can be achieved by an anchor device utilised in orthopaedic surgery.

Subxiphoid incisional hernias occurring after median sternotomy are a problem occurring after wound infection.<sup>63</sup> Mesh repair with fixation to rib periosteum is recommended although this hernia may be particularly suitable to

laparoscopic repair because of the good working space in the epigastric region.

Trocar site hernia has recently been reviewed by Tonouchi and colleagues.<sup>64</sup> Sixty-three reports were reviewed and, as a result, a classification system was devised dividing these hernias into three types:

1. Early onset occurring immediately after the operation with a high susceptibility to small bowel obstruction due to Richter's type hernia.
2. Late onset hernias occurring more than 30 days after operation or up to several months, presenting as a local abdominal bulge and rarely causing small bowel obstruction.
3. A special type in which the whole trocar site dehisces with protrusion of intestine and/or omentum. The incidence is estimated to be between 0.65–2.8% with an increasing risk for larger trocar sites.

The authors recommend that all 10-mm trocar sites should be closed under direct vision and also smaller trocar sites that have been forcibly dilated, for instance, to remove the gall bladder.

Traumatic abdominal wall hernias are rare and represent only about one in 10,000 hernias.<sup>65</sup> They are commonly misclassified and should only be regarded as traumatic if they appear soon after the episode of trauma when there has been no skin penetration or no previous herniation at this site. There is often an association with a tear in the intestinal mesentery.

Patients with incisional hernias in kidney transplant incisions present special problems.<sup>66</sup> The external oblique muscles are usually intact while the hernia sac is located between the deeper layers of the abdominal wall. Surgical exploration must, therefore, be meticulous and the recommended mesh placement technique after repair is by the onlay method.

Repair of large abdominal wall hernias in premenopausal women presents special problems because of the requirement to allow subsequent pregnancy with elasticity and expansion of the abdominal wall. In these cases, it may be better to avoid mesh and use sutured repair such as the shoelace technique.<sup>67</sup>

### The future

The application of three-dimensional stereography to measure abdominal wall mobility and function is improving our understanding of abdominal wall compliance prior to surgery and after the placement of prosthetic mesh.<sup>68</sup> Knowledge of the maximum tensile strength and the dynamics of distension will enable the design of prosthetic mesh materials which are more physiologically compatible



than those currently used.<sup>69</sup> However, it is the surgeon and the techniques used that are of paramount importance in the repair of abdominal incisional hernias.

## References

- Flum DR, Harvath K, Koepsell T. Have outcomes of incisional hernia repair improved with time? – a population-based analysis. *Ann Surg* 2003; **237**: 129–35.
- Wong SY, Kingsnorth AN. Prevention and surgical management of incisional hernias. *Int J Surg Invest* 2001; **3**: 407–14.
- van't Riet M, deVos van Steenwijk PJ, Bonjer HJ, Steyerberg EW, Jeekel J. Incisional hernia after repair of wound dehiscence: incidence and risk factors. *Ann Surg* 2004; **70**: 281–6.
- Society for Surgery of the Alimentary Tract. Guidelines: Surgical repair of incisional hernias. *J Gastrointest Surg* 2004; **8**: 369–70.
- Kingsnorth A, LeBlanc K. Hernias: inguinal and incisional. *Lancet* 2003; **302**: 1561–71.
- Israelsson LA. The surgeon as a risk factor for complications of midline incision. *Eur J Surg* 1998; **164**: 353–9.
- Burger JWA, Luijendijk RW, Hop WCJ, Halm JA, Verdaasdonk EGG, Jeekel J. Long-term follow-up of a randomised controlled trial of suture versus mesh repair of incisional hernia. *Ann Surg* 2004; **240**: 578–85.
- Luijendijk RW, Hop WCJ, van den Tol MP, de Lange DC, Braaksma MM, Jermans N *et al*. A comparison of suture repair with mesh repair for incisional hernia. *N Engl J Med* 2000; **343**: 392–8.
- Duepre H-J, Senagore AJ, Delaney P, Fazio YW. Does means of access affect the incidence of small bowel obstruction and ventral hernia after bowel resection: laparoscopy versus laparotomy. *J Am Coll Surg* 2003; **197**: 177–81.
- Giroto JA, Malaisrie C, Bulkely G, Manson PN. Recurrent ventral herniation in Ehlers-Danlos syndrome. *Plast Reconstr Surg* 2000; **106**: 1520–6.
- Schumpelick V, Klinge U. Prosthetic implants for hernia repair. *Br J Surg* 2003; **90**: 1457–8.
- Langer C, Schaper A, Liersch T, Kulle B, Flosman M, Füzési L *et al*. Prognosis factors in incisional hernia surgery: 25 years' of experience. *Hernia* 2005; **9**: 16–21.
- Rohrich RJ, Lowe JB, Hackney FL, Bowman JL, Hobar PC. An algorithm for abdominal wall reconstruction. *Plast Reconstr Surg* 2000; **105**: 202–16.
- Dumainian GA, Denham W. Comparison of repair techniques for major incisional hernias. *Am J Surg* 2003; **185**: 61–5.
- Yahouchy-Chouillard E, Aura T, Picone O, Etienne J-C, Fingerhut A. Incisional hernias: I – Related risk factors. *Dig Surg* 2003; **20**: 3–9.
- Hodgson NCF, Malthaner RA, Ostbye T. The search for an ideal method of abdominal fascial closure: a meta-analysis. *Ann Surg* 2000; **231**: 436–42.
- van't Riet M, Steyerberg EW, Nellensteyn J, Boryer HJ, Jeekel J. Meta-analysis of techniques for closure of midline abdominal incisions. *Br J Surg* 2002; **80**: 1350–6.
- Rucinski J, Margolis M, Panangopoulos G, Wise L. Closure of the abdominal midline fascia: meta-analysis delineates the optimal technique. *Am Surg* 2001; **67**: 421–6.
- Rogers M, McCarthy R, Earnshaw JJ. Prevention of incisional hernia after aortic aneurysm repair. *Eur J Vasc Endovasc Surg* 2003; **26**: 519–22.
- Strzelczyk J, Czupryniak L, Loba L, Wasiak J. The use of polypropylene mesh in midline incision closure following gastric by-pass surgery reduces the risk of postoperative hernia. *Lang Arch Surg* 2002; **387**: 294–7.
- Jones A, Cengiz Y, Israelsson LA. Preventing parastomal hernia with a prosthetic mesh. *Arch Surg* 2004; **139**: 1356–8.
- Stabile Ianora AA, Midiri M, Vinci R, Rotondo A, Angelelli N. Abdominal wall hernias: imaging with spiral CT. *Eur Radiol* 2000; **10**: 914–9.
- Toms AP, Dixon AK, Murphy JMP, Jamieson NV. Illustrated review of new imaging techniques in the diagnosis of abdominal wall hernias. *Br J Surg* 1999; **86**: 1243–50.
- Morena IG. Chronic eventration and large hernias. *Surgery* 1947; **22**: 945–53.
- Mason EE. Pneumoperitoneum in the management of giant hernia. *Surgery* 1956; **39**: 143–8.
- Rios A, Rodriguez JM, Munitz V, Alcaraz P, Perez Flores D, Parrilla P. Antibiotic prophylaxis in incisional hernia repair using a prosthesis. *Hernia* 2001; **5**: 148–52.
- Flament JB, Avisse C, Palot JP, Pluot M, Burde A, Rives J. Trophic ulcers in giant incisional hernias – pathogenesis and treatment: a report of 33 cases. *Hernia* 1997; **1**: 71–6.
- Goodney PP, Birkmeyer CM, Birkmeyer JD. Short-term outcomes of laparoscopic and open ventral hernia repair. *Arch Surg* 2002; **137**: 1161–5.
- LeBlanc KA, Booth WV, Whitaker JM, Bellanger DE. Laparoscopic incisional and ventral herniorrhaphy: our initial 100 patients. *Hernia* 2001; **5**: 41–5.
- Bencini L, Sanchez LJ. Learning curve for laparoscopic ventral hernia repair. *Am J Surg* 2004; **187**: 378–82.
- Franklin ME, Gonzalez JJ, Glass JL, Manjarrez A. Laparoscopic ventral and incisional hernia repair: an 11-year experience. *Hernia* 2004; **8**: 23–7.
- Chelala E, Gaede F, Douillez V, Dessihy M, Alle JL. The suturing concept for laparoscopic mesh fixation in ventral and incisional hernias: preliminary results. *Hernia* 2003; **7**: 191–6.
- Bingener J, Kazantsev GB, Chopra S, Schivesinger WH. Adhesion formations after laparoscopic ventral incisional hernia repair with polypropylene mesh: a study using abdominal ultrasound. *J Soc Laparoendosc Surg* 2004; **8**: 127–31.
- Wangenstein OH. Repair of recurrent and difficult hernias and other large defects of the abdominal wall employing the iliotibial tract of fascia lata as a pedicled flap. *Surg Gynecol Obstet* 1934; **58**: 450–9.
- Stock FE. Repair of large hernias with nylon mesh. *Lancet* 1954; **1**: 395–6.
- Notaras MJ. Experience with Mersilene mesh in abdominal wall repair. *Proc R Soc Med* 1974; **67**: 1187–90.
- Korenkov M, Paul A, Sauerland S, Neugebauer E, Arndt M, Chevrel JP *et al*. Classification and surgical treatment of incisional hernia. Results of an experts' meeting. *Lang Arch Surg* 2001; **386**: 65–73.
- Hamy A, Dessaux P, Mucci-Hennekinne S, Radriamanajo S, Regenet N, Arnaud J-P. Surgical treatment of large incisional hernias by an intraperitoneal Dacron mesh and an aponeurotic graft. *J Am Coll Surg* 2003; **196**: 531–4.
- de Vries Reilingh TS, van Geldere D, Langenhorst BLAM, de Jong D, van der Wilt GT, van Goor H *et al*. Repair of large midline incisional hernias with polypropylene mesh: comparison of three operative techniques. *Hernia* 2004; **8**: 56–9.
- Chevrel JP. Traitement des grandes eventrations medians par plastic en paletot et prothese. *Nouv Presse Med* 1979; **8**: 695–6.
- San Pio JR, Damsgaard TE, Momsen D, Villadsen I, Larsen J. Repair of giant incisional hernias with polypropylene mesh: a retrospective study. *Scand J Plast Reconstr Surg Hand Surg* 2003; **37**: 102–6.
- Rives J, Lardennois B, Pire JC, Hibon J. Les grandes eventrations: importance du 'volet abdominal' et des troubles respiratoires qui lui sont secondaires. *Chirurgie* 1973; **99**: 547–63.



43. Welty G, Klinge U, Klosterhalfen B, Kasperk R, Schumpelick N. Functional impairment and complaints following incisional hernia repair with different polypropylene meshes. *Hernia* 2001; **5**: 142–7.
44. Fernandez RL, Garcia JS, Ortego PD, Martin FJL, Ruiz de Adana JC, Limones ME. Tissucol application in dermolipectomy and incisional hernia repair. *Int Surg* 2001; **86**: 240–5.
45. Ramirez OM, Ruas E, Dellon AL. 'Components separation' method for closure of abdominal-wall defects: an anatomic and clinical study. *Plast Reconstr Surg* 1990; **86**: 519–26.
46. Kuzbari R, Worsseg AP, Tairyeh G, Deutinger M, Kuderna C, Metz V *et al*. Sliding door technique for the repair of midline incisional hernias. *Plast Reconstr Surg* 1998; **101**: 1235–44.
47. Munegato G, Brandolese R. Respiratory physiopathology in surgical repair for large incisional hernias of the abdominal wall. *J Am Coll Surg* 2001; **192**: 298–304.
48. Shestak KC, Edington HJD, Johnson RR. The separation of anatomic components technique for the reconstruction of massive midline abdominal wall defects: anatomy, surgical technique, applications and limitations revisited. *Plast Reconstr Surg* 2000; **105**: 731–8.
49. de Vries Reilingh TS, van Goor H, Rosman C, Benselmans MHA, de Jong D, van Nieuwenhoven EJ *et al*. 'Components separation technique' for the repair of large abdominal wall hernias. *J Am Coll Surg* 2003; **196**: 32–7.
50. Tran NV, Petty PM, Bite U, Clay RP, Johnson CH, Arnold PG. Tissue expansion-assisted closure of massive ventral hernias. *J Am Coll Surg* 2003; **196**: 484–8.
51. Navsaria PH, Bunting M, Omoshoro-Jones J, Nicol AJ, Kohn D. Temporary closure of open abdominal wounds by the modified sandwich-vacuum pack technique. *Br J Surg* 2003; **90**: 718–22.
52. Fabian TC, Croce MA, Pritchard E, Minard G, Hickerson ML, Howell RL *et al*. Planned ventral hernia: staged management for acute abdominal wall defects. *Ann Surg* 1994; **219**: 643–53.
53. van Geffen HJAA, Simmermadner RKJ, van Vroonhoven TJMV, van der Werken C. Surgical treatment of large contaminated abdominal wall defects. *J Am Coll Surg* 2005; **201**: 206–12.
54. Kingsnorth AN, Sivarajasingham N, Wong S, Butler M. Open mesh repair of incisional hernias with significant loss of domain. *Ann R Coll Surg Engl* 2004; **86**: 363–6.
55. Carne PWG, Robertson GM, Frizelle FA. Parastomal hernia. *Br J Surg* 2003; **90**: 784–93.
56. Janes A, Cengiz Y, Israelsson LA. Preventing parastomal hernia with a prosthetic mesh. *Arch Surg* 2004; **139**: 1356–8.
57. Steele SR, Lee P, Martin MJ, Mullenix PS, Sullivan ES. Is parastomal hernia repair with polypropylene mesh safe? *Am J Surg* 2003; **185**: 436–40.
58. Franks ME, Hrebinko RL. Technique of parastomal hernia repair using synthetic mesh. *Urology* 2001; **57**: 551–3.
59. Carbonell AM, Kercher KW, Sigman L, Matthews BD, Sing RF, Kneisl JS *et al*. A novel technique of lumbar hernia repair using bone anchor fixation. *Hernia* 2005; **9**: 22–5.
60. Boyne NP, Lambrianides AL, Pollard C. Incisional hernia through iliac crest bone graft donor sites. *Aust NZ J Surg* 2002; **72**: 156–7.
61. Kanshik R, Attri AK. Incisional hernia from iliac bone grafting site – a report of two cases. *Hernia* 2003; **7**: 227–8.
62. Patten LC, Awad SS, Berger DH, Fagan SP. A novel technique for the repair of lumbar hernias after iliac crest bone harvest. *Am J Surg* 2003; **188**: 85–8.
63. Mackey RA, Brody FJ, Berber E, Chand B, Henderson JM. Subxyphoid incisional hernias after median sternotomy. *J Am Coll Surg* 2005; **201**: 71–6.
64. Tonouchi H, Ohinori Y, Koboyashi M, Kusunoki M. Trocar site hernia. *Arch Surg* 2004; **139**: 1248–56.
65. Kumar A, Hazrah P, Bal S, Seth A, Parshed R. Traumatic abdominal wall hernia: a reappraisal. *Hernia* 2004; **8**: 277–80.
66. Birolini C, Mazzucchi E, Mutiyama E, Nahas W, Rodrigues AJ, Arap S *et al*. Prosthetic repair of incisional hernia in kidney transplant patients. A technique with onlay polypropylene repair. *Hernia* 2001; **5**: 31–5.
67. Abrahamson J, Gorman J. Pregnancy and ventral hernia. *Hernia* 2000; **4**: 187–91.
68. Muller M, Klinge U, Conze J, Schumpelick V. Abdominal wall compliance after Marlex mesh implantation for incisional hernia repair. *Hernia* 1998; **2**: 113–7.
69. Junge K, Klinge U, Drescher A, Giboni P, Niewcera M, Schumpelick N. Elasticity of the anterior abdominal wall and impact for reparation of incisional hernias using mesh implants. *Hernia* 2001; **5**: 113–8.